

Available online at www.sciencedirect.com

ScienceDirect

journal homepage: www.elsevier.com/locate/radcr

Case Report

Unintended intra-arterial injection of contrast of an intracranial CT angiography

Han Zhang, MD, FRCR, Sumeet Kumar, MBBS, DMRD, DNB, FRCR*

Neuroradiology, Level B1, National Neuroscience Institute, 11 Jalan Tan Tock Seng, Singapore 308433, Singapore

ARTICLE INFO

Article history:

Received 25 August 2018

Revised 30 August 2018

Accepted 3 September 2018

Available online 6 October 2018

Keywords:

Computed tomography angiography

Intra-arterial injection

ABSTRACT

Computed tomography angiography (CTA) is widely used to evaluate intracranial vascular disease. We report a case of intracranial CTA with unintended intra-arterial (IA) injection of contrast due to IA placement of an intravenous cannula, which results in a selective left vertebral artery IA CTA. Knowledge of anatomy is essential in analyzing the whole study and identifying the error. In clinical practice, it is important to avoid and recognize a wrongly placed intravenous cannula. And bolus tracking protocol might play a role as a gatekeeper.

© 2018 The Authors. Published by Elsevier Inc. on behalf of University of Washington.

This is an open access article under the CC BY-NC-ND license.

(<http://creativecommons.org/licenses/by-nc-nd/4.0/>)

Introduction

Computed tomography angiography CTA is a well-established technique to evaluate intracranial vascular disease [1,2]. intravenous (IV) contrast is used and images can be acquired on different phases with different indications. CTA with intra-arterial (IA) injection of contrast is usually part of an interventional procedure, performed via an IA catheter inserting through radial or femoral artery [3]. Here, we report a case of routine CTA with unintended IA injection of contrast, which results in odd and foxing imaging outcome.

Case report

A 48-year-old man presented with incoherence and was unable to stand without assistance. Computed tomography (CT) brain showed acute left parietotemporal lobe

intraparenchymal hematoma. And subsequent CTA revealed an arteriovenous malformation in left temporal region as the culprit lesion, which was confirmed with 4 vessels cerebral angiogram, with no other lesion detected. Left temporal arteriovenous malformation resection, clot evacuation, and cranioplasty were performed and the patient was monitored in neurointensive care unit.

The first postsurgical CTA was done 1 day after surgery. The patient was still intubated and arrived at the CT room on trolley. There is a 20G “IV” cannula setting in neuro intensive care unit in left antecubital fossa with the tip pointing toward the heart. The CTA was performed with the coverage from vertex to skull base as per department protocol. Using a pressure injector, 70 mL of omnipaque 350 was injected through the “IV” cannula at the rate of 4 mL/s, and the timing was 25 seconds for arterial phase and 75 seconds for delayed phase. On “arterial phase,” there was enhancement of the left distal vertebral artery, left medulla, and lower pons which was left posterior inferior cerebellar artery territory, left cerebellar hemisphere, basilar artery, right lateral, and superior

* Corresponding author.

E-mail addresses: han.zhang@mohh.com.sg (H. Zhang), sumeet.kumar@singhealth.com.sg (S. Kumar).

<https://doi.org/10.1016/j.radcr.2018.09.005>

1930-0433/© 2018 The Authors. Published by Elsevier Inc. on behalf of University of Washington. This is an open access article under the CC BY-NC-ND license. (<http://creativecommons.org/licenses/by-nc-nd/4.0/>)

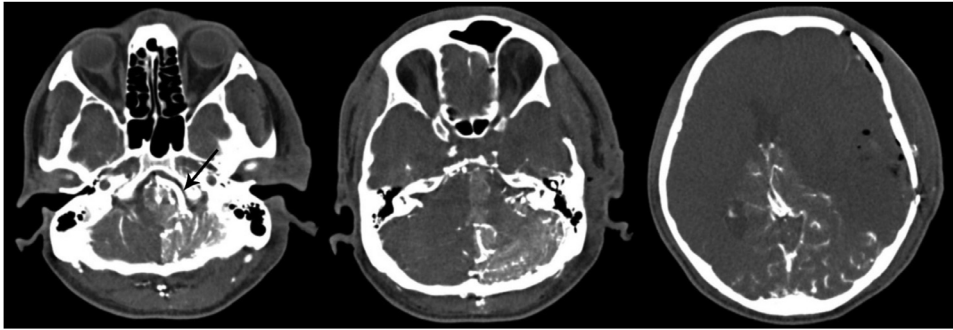


Fig. 1 – “Arterial phase” of CTA showed enhancement of the left distal vertebral artery (arrow), left PICA territory, left cerebellar hemisphere, basilar artery, right AICA and SCA territories, and bilateral PCA territories.

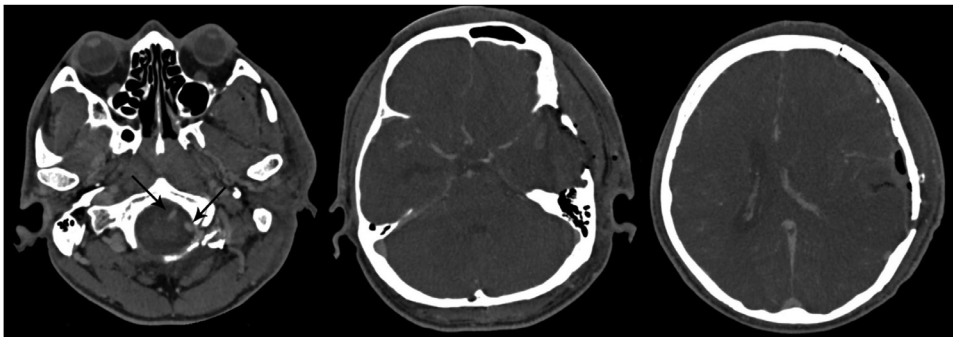


Fig. 2 – “Delayed phase” of CTA showed enhancement of all the arteries and veins, including bilateral vertebral arteries (arrows).

cerebellar hemisphere which was right anterior inferior cerebellar artery and superior cerebellar artery territories, and bilateral posterior cerebral artery territories. There was already contrast in the venous drainage of corresponding areas. The rest of the brain was not enhanced (Fig. 1). On “delayed phase,” there was enhancement of all the intracranial arteries and veins (Fig. 2).

The whole picture was in keeping with a selective left vertebral artery IA CTA. The radiographer provided the information that “the backflow from the cannula was very strong and ejected out” when connecting the injector to the left cubital “IV” cannula before the CT scan. Deduction of IA placement of the “IV” cannula was made. The patient had been sent back. The ward doctor checked the “IV” cannula, which already occluded and was removed. A new left cubital IV cannula was inserted and tested, and another CTA was done 6 hours later. Expected normal enhancement of the anterior and posterior circulations was achieved. No residual nidus was seen at the surgical bed.

The patient was followed up for signs of ischemia and had an uneventful course. He recovered well and was discharged for rehabilitation.

Discussion

IA placement of IV cannula occasionally happens in clinical practice [4]. Using wrongly placed cannula for contrast

injection may cause different imaging outcome. The site of the cannula, the nature of the scan, and the protocol all need to be considered.

The anatomy is essential in our case. The cannula was in the left cubital area, possibly in the left radial/ulnar/brachial artery. With pressure injection of the contrast, there was reflux of contrast proximally to the left brachial artery and subclavian artery, and thence into left vertebral artery following the anatomic path (Fig. 3). No direct contrast reached the left common carotid artery and brachiocephalic trunk, which were proximal to the left subclavian artery, and hence were not opacified. Since the contrast reached the left vertebral artery earlier than normal IV injection, a selective left vertebral artery IA CTA was captured on the “arterial phase.” On “delayed phase,” the contrast mixed with the blood pool and the whole brain was enhanced.

Right-sided cannula into an artery at the antecubital fossa may result in different imaging outcome. Anatomically, the left common carotid artery and left subclavian artery are distal to the brachiocephalic trunk. If the reflux was not strong enough to overcome the brachiocephalic trunk blood flow, a delayed selective right vertebral artery, and right common carotid artery IA CTA would be seen. If the reflux was strong enough to reach the aortic arch, then the whole brain would enhance, with the phase more delayed than expected (Fig. 3).

IA placement of IV cannula always needs to be avoided, recognized, and corrected to prevent complications [5]. Risk factors include morbid obesity, lack of cooperation, lack of vigilance, dark skin, pre-existing vascular anomalies, and thoracic

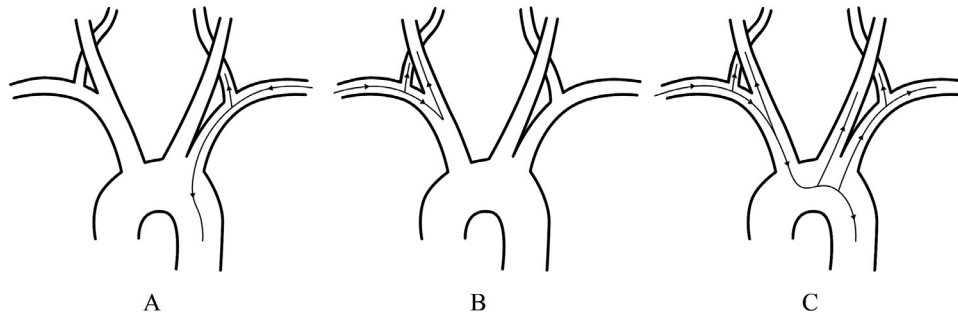


Fig. 3 – Expected flow of contrast. Left upper limb IA injection (A); right upper limb IA injection with the reflux not strong enough to overcome the brachiocephalic trunk blood flow (B); right upper limb IA injection with the reflux strong enough to reach the aorta (C).

outlet syndrome [6]. The brachial artery is the commonest site for wrongly placement and this has been attributed to a high bifurcation of the artery above the antecubital fossa, resulting in insertion into the brachial or the aberrant ulnar artery [7,8]. To avoid IA placement of IV cannula, distal veins in forearm or dorsum of the hand may be preferred, as these veins are more superficial and farther away from main arteries. Backflow is an important clue. Strong and pulsatile backflow is highly suggestive of IA placement which clinicians, radiographers, and nurses should bear in mind. If there is any doubt, blood gas is a fast, simple, and reliable test. Ultrasound is also helpful for confirmation. In our case, blood gas was not done as the cannula was already occluded when the problem was raised, and ultrasound was also not performed.

Bolus tracking protocol might play a role as a gatekeeper [9]. The region of interest can be put at the mid aortic arch. Left-sided cannula IA injection would not be triggered as no contrast would reach the mid aortic arch. On right-sided IA injection with reflux not strong enough to overcome the brachiocephalic trunk blood flow, the scan would not be triggered as well. On right-sided IA injection with strong enough reflux to reach the aortic arch, the scan would be triggered and expected arterial phase would still be obtained. Thus, unnecessary radiation could be saved for patients.

Conclusion

We report a case with unintended left cubital IA injection of contrast resulting in selective left vertebral artery IA CTA of the brain. This is a rare case which shows one of the problems related to IA-placed IV cannula. Health professionals should be able to recognize a wrongly placed IV cannula. And bolus tracking protocol might play a role as a gatekeeper.

REFERENCES

- [1] Alberico RA, Patel M, Casey S, Jacobs B, Maguire W, Decker R. Evaluation of the circle of Willis with three-dimensional CT angiography in patients with suspected intracranial aneurysms. *AJNR Am J Neuroradiol* 1995;16(8):1571–8 discussion 1579–80.
- [2] Gandhi D. Computed tomography and magnetic resonance angiography in cervicocranial vascular disease. *J Neuroophthalmol* 2004;24(4):306–14.
- [3] Gandhi D, Pandey A, Ansari SA, Gemmete JJ, Thompson BJ, Mukherji SK. Multi-detector row CT angiography with direct intra-arterial contrast injection for the evaluation of neurovascular disease: technique, applications, and initial experience. *AJNR Am J Neuroradiol* 2009;30(5):1054–8.
- [4] Sen S, Chini EN, Brown MJ. Complications after unintentional intra-arterial injection of drugs: risks, outcomes, and management strategies. *Mayo Clin Proc* 2005;80(6):783–95.
- [5] Devulapalli C, Han KD, Bello RJ, LaPorte DM, Hepper CT, Katz RD. Inadvertent intra-arterial drug injections in the upper extremity: systematic review. *J Hand Surg Am* 2015;40(11):2262–8 e5.
- [6] Lirk P, Keller C, Colvin J, Colvin H, Rieder J, Maurer H, et al. Unintentional arterial puncture during cephalic vein cannulation: case report and anatomical study. *Br J Anaesth* 2004;92(5):740–2.
- [7] Bergan JohnJ, Yao JamesST. *Vascular Surgical Emergencies*. Orlando: Grune & Stratton; 1987.
- [8] Van der Post CWH. A case of mistaken injection of pentothal sodium into an aberrant ulnar artery. *S Afr Med J* 1942(16):182–184.
- [9] Lubicz B, Levivier M, Francois O, Thoma P, Sadeghi N, Collignon L, et al. Sixty-four-row multisection CT angiography for detection and evaluation of ruptured intracranial aneurysms: interobserver and intertechnique reproducibility. *AJNR Am J Neuroradiol* 2007;28(10):1949–55.