

# Calvarial metastasis from endometrial carcinoma: Case report and review of the literature

Paolo C. Cecchi, Reinhard Kluge<sup>1</sup>, Andreas Schwarz

Operative Unit of Neurosurgery, <sup>1</sup>Service of Pathology, Regional General Hospital, Bolzano, Italy

## ABSTRACT

Hematogenous bone metastases from endometrial carcinoma are not frequent and their treatment is a matter of debate. We describe an extremely rare case of calvarial metastasis from endometrial carcinoma in an 80-year-old woman treated by means of one-step surgical radical resection and heterologous cranioplasty, along with a review of the literature regarding epidemiology, clinico-radiological features, prognosis, and management of skull metastases.

**Key words:** Bone metastasis, calvaria, endometrial carcinoma, skull metastasis

## Introduction

Endometrial cancer is the most common gynecologic malignancy and the fourth most common cancer diagnosis in women.<sup>[1]</sup> The disease usually spreads by local or lymphatic dissemination.<sup>[2]</sup> Distant metastases are less common and usually involve liver and lung,<sup>[3]</sup> whereas bone is rarely affected, especially at diagnosis.<sup>[4]</sup> In this report, we describe a case of bone metastasis of the cranial vault from endometrial carcinoma in an 80-year-old woman, along with a review of the pertinent literature regarding all major aspects of epidemiology, diagnosis, and management of skull metastases.

## Case Report

An 80-year-old woman, with a remote history of breast carcinoma (15 years before), underwent laparotomic hysterectomy with bilateral oophorectomy, pelvic lymphadenectomy, and omentectomy for an endometrial carcinoma (clear-cell type, pT2b, NO, MO, G3, RO, VO, LO; FIGO IIb) at the end of 2008. Six weeks later, she received external fractionated radiotherapy (1.8 Gy fraction for a total dose of 50.4 Gy) on the pelvic area. Three years later, she

developed a rapid expansive painless right temporo-parietal mass, non-pulsating, covered by normal cutis. A computed tomography (CT) scan of the head [Figure 1] revealed an osteolytic lesion of the calvaria in the temporo-parietal area, suspicious for a metastasis. In January 2012, the patient underwent macroscopic radical resection of the tumor of the skull, invading the superior part of the temporalis muscle, with craniectomy and immediate acrylic cranioplasty. Underlying dura was removed and duraplasty with heterologous material was accomplished. Histological investigation documented a metastasis from carcinoma with clear-cell appearance in accordance with an endometrial origin [Figure 2]. Subcutaneous tissue was not infiltrated as well as the galea and dura (histological confirmation). Postoperative course was uneventful. Given the radical resection, confirmed by a CT scan of the head [Figure 3], no adjuvant treatment was prescribed at that time. Bone scintigraphy revealed no other suspicious lesions of the skeleton. At 4 months follow-up, the patient is alive and neither clinical nor radiological signs of local recurrence are present.

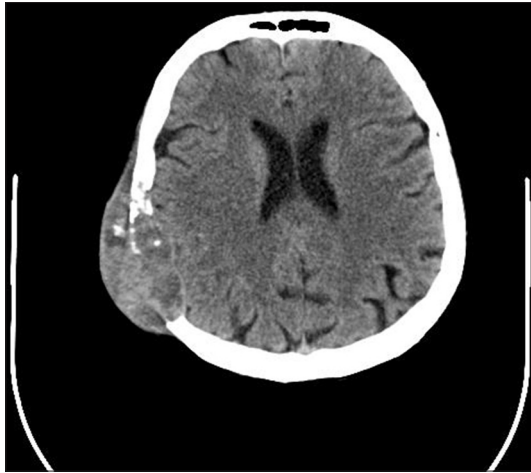## Discussion

Bone metastases from endometrial carcinoma are uncommon, being clinically evident in no more than 15% of patients<sup>[5]</sup> and only in 2-6% of cases at diagnosis.<sup>[4]</sup> In a recent review of this topic,<sup>[6]</sup> only 0.35% of women with endometrial cancer were suspected to have a bone metastasis (21 out of 6144 cases), with a histological confirmation in 57% of them. Fourteen out of 21 patients (66.6%) were in stage III-IV, and only in 29% of cases bone involvement was present at diagnosis (the median time from diagnosis to bone metastasis was 10 months). Median number of bone metastasis was 3, and interestingly, the most frequent histological subtype was endometrioid rather than the more aggressive clear-cell or papillary serous carcinomas. Median time to death after diagnosis of bone

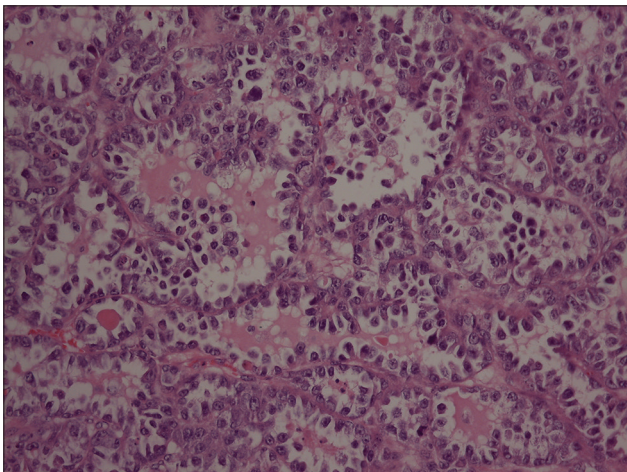
Access this article online	
Quick Response Code:	Website: www.asianjns.org
	DOI: 10.4103/1793-5482.146648

### Address for correspondence:

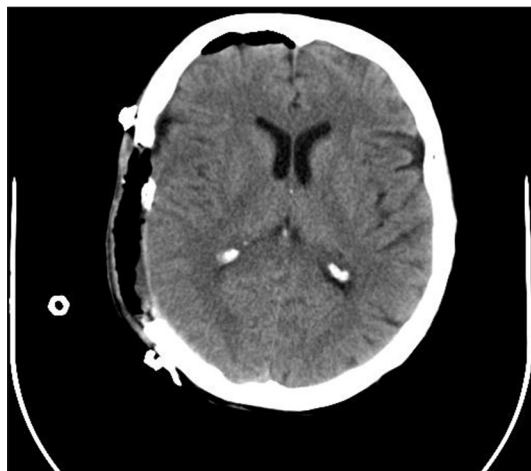Dr. Paolo Cipriano Cecchi, Operative Unit of Neurosurgery, Regional General Hospital, Via Boehler, Bolzano, Italy.  
E-mail: [cecchi.pc@libero.it](mailto:cecchi.pc@libero.it)



**Figure 1:** Pre-operative CT scan of the head showing a large osteolytic lesion of the right calvaria



**Figure 2:** Histological specimen documenting a clear-cell carcinoma of a possible endometrial origin



**Figure 3:** Post-operative CT scan of the head displaying the complete resection of the metastatic lesion replaced by a heterologous cranioplasty

metastasis was 10 months. The most common locations are pelvis, spine, and lower-extremities bones, but other sites have been rarely reported (ribs, facial bones, and skull). Sporadic

cases of secondary skull involvement from cutaneous scalp localization have been reported;<sup>[2,7]</sup> however, to the best of our knowledge, there are no previous detailed description of purely bone metastasis of the skull from endometrial carcinoma in the literature.

The cranium is the site of blood-borne metastases of various malignancies mainly by direct hematogenous spread and rarely by retrograde seeding through the Batson's valveless venous plexus that connects pelvic structures with the skull through epidural and dural veins (especially in prostate cancer).<sup>[8,9]</sup> In a recent review of a large series of skull metastases (175 cases), including many cases of calvarial lesions, the most frequent source was breast cancer (55%) both for calvarial and skull-base metastases, followed by lung (14%) and prostate (6%).<sup>[10]</sup> In another report with a larger patient population (279) affected only by skull-base lesions, the most frequent primary tumor was prostate (38.5%), followed by breast (20.5%) and lymphoma (8%).<sup>[8]</sup> The association of skull and brain metastasis has been reported in 30% of cases, mainly in patients with lung (33%) or breast (19%) neoplasms, but never in patients with prostate carcinoma.<sup>[10]</sup>

The development of a skull metastasis is generally a late event in the course of a cancer disease due to the systemic progression of the tumor,<sup>[8]</sup> with a median interval between diagnosis of the primary neoplasm and detection of a skull metastasis of 4 years (mean 6 years).<sup>[10,11]</sup> Calvarial metastases may cause a painless local swelling as well as focal pain, and when invading the dural and intradural space, signs/symptoms of increased intracranial pressure, seizures, meningeal irritation, and focal neurological disturbances may emerge.<sup>[10]</sup> Skull-base metastases usually determine various combinations of cranial nerves' signs and pain. Greenberg *et al.*<sup>[12]</sup> identified five different clinical syndromes related to the localization of the lesions: Orbital, parasellar, middle-fossa, jugular foramen, and occipital condyle syndrome.

Magnetic resonance imaging (MRI) using T2- and T1-weighted sequences before and after administration of gadolinium (along with fat suppression techniques) is the best method to detect skull metastases.<sup>[8,10,13,14]</sup> The typical picture consists of a hypointense lesion (substitution of diploic hyperintense fat signal) on non-enhanced T1-weighted images with a variable appearance on T2-weighted images and a variable amount of enhancement after gadolinium administration on T1-weighted sequences with fat suppression techniques.<sup>[8,10]</sup> CT scan with bone window is a useful method to show lytic bone lesions, but is less effective than MRI for detecting a contrast-enhancing soft tissue mass and to define boundaries and degree of dural invasion as well as to identify concomitant brain metastases.<sup>[8,10]</sup>

Radionuclide bone scan offers relatively poor sensitivity in detecting purely osteolytic bone

metastases, and fluorodeoxyglucose positron emission tomography (FDG-PET) seems to be associated with a similar diagnostic accuracy.<sup>[10,15]</sup> Differential diagnosis includes primary skull tumors (osteoma, chondroma, chondrosarcoma, chordoma, esthesioneuroblastoma, carcinoma of the nasopharynx) and tumor-like lesions (fibrous dysplasia, hyperostosis, eosinophilic granuloma). In comparison to patients with primary skull tumors, those with skull metastasis presented less frequently with neurologic deficits as well as skull-base lesions. Furthermore, patients with skull metastasis are usually older and with a shorter duration of symptoms as compared to those patients affected by benign tumor-like lesions.<sup>[11]</sup>

As for other types of metastases, the prognosis associated with a skull metastasis is mainly related to the nature and dissemination of the primary tumor.<sup>[8]</sup> The median survival time ranged from 9<sup>[10,11]</sup> to 31 months.<sup>[8]</sup> In the subset of skull-base metastases, the presence of cranial nerve palsies indicate a poorer prognosis with an average of 5 months after the onset of cranial nerve dysfunction.<sup>[8]</sup>

In addition to symptomatic treatments with steroids, bisphosphonates (particularly Zolendronate),<sup>[16]</sup> and analgesics,<sup>[8]</sup> four modalities were used alone or in combination for patients with skull metastases: Radiotherapy, chemotherapy, surgery, and endocrinological therapy.<sup>[10]</sup> Conventional fractionated irradiation, alone or in combination with chemotherapy and/or surgery, is still the most frequent primary therapy providing an excellent relief of pain<sup>[8,17,18]</sup> and often (in up to 90% of cases)<sup>[8]</sup> a regression of cranial nerve dysfunction lasting until death in most cases.<sup>[19]</sup> Nevertheless, it must be reminded that the rate of response is influenced by the timing of radiotherapy: Patients with symptoms lasting less than 1 month have a response rate of 87% in comparison to 25% of those with more than 3 months of clinical history.<sup>[20]</sup> Another important factor influencing the efficacy is the nature of the lesion, with lymphoma and breast cancer having a better response as compared to prostate or non-small-cell lung cancer.<sup>[8,21]</sup> To date, there are no convincing data supporting a schedule different from the classical one (30 Gy in 10 fractions).<sup>[8]</sup> Radiosurgery is a relatively recent option mainly applied for the treatment of skull-base metastases, either as a primary form of therapy or as a secondary chance after a previous standard irradiation with clinical improvement and local tumor control in 61% and 67%, respectively, with an acceptable complication rate.<sup>[22,23]</sup>

Chemotherapy and/or hormonal therapy may be useful, especially in combination with radiation treatment, in some cases of breast or prostate carcinomas.<sup>[8]</sup>

Surgery, generally consisting of a craniectomy with an immediate acrylic replacement, is indicated in selected symptomatic cases (painful masses, massive destruction of the bone with dural/subdural invasion, presence of neurologic

deficit) mainly for single lesions of the calvaria (as in our case), giving the relatively short duration of the session and the low complication rate<sup>[24]</sup> even for those cases overlying or invading the dural venous sinuses.<sup>[25]</sup> With the recent improvements in surgical management of skull-base tumors, resection of selected single metastasis of the base of the skull is feasible and relatively safe, especially for those located in the sellar–parasellar area.<sup>[26]</sup>

## Conclusions

This is a report of an extremely rare case of metastasis of the calvaria from endometrial carcinoma. Metastatic lesions of the skull are not infrequent during the course of solid or hematological tumors, and may cause pain and/or neurological problems. A prompt diagnosis is mandatory in order to define the best individualized treatment algorithm. If so, a good and long-lasting clinical outcome is possible.

## References

1. Jemal A, Siegel R, Ward E, Hao Y, Xu J, Thun MJ. Cancer statistics. *CA Cancer J Clin* 2009;59:225-49.
2. Mustafa MS, Al-Nuaim L, Inayat-Ur-Rahman N. Scalp and cranial bone metastasis of endometrial carcinoma: A case report and literature review. *Gynecol Oncol* 2001;81:105-9.
3. Aalders JG, Abeler V, Kolstad P. Recurrent adenocarcinoma of the endometrium: A clinical and histopathological study of 379 patients. *Gynecol Oncol* 1984;17:85-103.
4. Artioli G, Cassaro M, Pedrini L, Borgato L, Corti L, Cappetta A, *et al.* Rare presentation of endometrial carcinoma with singular bone metastasis. *Eur J Cancer Care (Engl)* 2010;19:694-8.
5. Albareda J, Herrera M, Lopez Salva A, Garcia Donas J, Gonzalez R. Sacral metastasis in a patient with endometrial cancer: Case report and review of the literature. *Gynecol Oncol* 2008;111:583-8.
6. Kehoe SM, Zivanovic O, Ferguson SE, Barakat RR, Soslow RA. Clinicopathologic features of bone metastases and outcomes in patients with primary endometrial cancer. *Gynecol Oncol* 2010;117:229-33.
7. Farooq MU, Chang HT. Intracranial and scalp metastasis of endometrial carcinoma. *Med Sci Monit* 2008;14:CS87-8.
8. Laigle-Donadey F, Taillibert S, Martin-Duverneuil N, Martin-Duverneuil N, Hildebrand J, Delattre J. Skull-base metastases. *J Neurooncol* 2005;75:63-9.
9. Svare A, Fossa SD, Heier MS. Cranial nerve dysfunction in metastatic cancer of the prostate. *Br J Urol* 1988;61:441-4.
10. Mitsuya K, Nakasu Y, Horiguchi S, Harada H, Nishimura T, Yuen S, *et al.* Metastatic skull tumors: MRI features and a new conventional classification. *J Neurooncol* 2011;104:239-45.
11. Stark AM, Eichmann T, Mehdorn HM. Skull metastases: Clinical features, differential diagnosis, and review of the literature. *Surg Neurol* 2003;60:219-25.
12. Greenberg HS, Deck MD, Vikram B, Chu FC, Posner JB. Metastasis to the base of the skull: Clinical findings in 43 patients. *Neurology* 1981;31:530-7.
13. Loevner LA, Yousem DM. Overlooked metastatic lesions of the occipital condyle: A missed case treasure trove. *Radiographics* 1997;17:1111-21.
14. Chong VF, Fan YF. Radiology of the jugular foramen. *Clin Radiol* 1998;53:405-16.
15. Fujimoto R, Higashi T, Nakamoto Y, Hara T, Lyshchik A, Ishizu K, *et al.* Diagnostic accuracy of bone metastases detection in cancer patients: Comparison between bone scintigraphy and whole-body FDG-PET. *Ann Nucl Med* 2006;20:399-408.
16. Rosen LS, Gordon D, Tchekmedyian NS, Yanagihara R, Hirsch V, Krzakowski M, *et al.* Long-term efficacy and safety of zoledronic acid in the treatment of skeletal metastases in patients with nonsmall

- cell lung carcinoma and other solid tumors: A randomized, phase III, double-blind, placebo-controlled trial. *Cancer* 2004;100:2613-21.
17. Moris G, Roig C, Misiego M, Alvarez A, Berciano J, Pascual J. The distinctive headache of the occipital condyle syndrome: A report of four cases. *Headache* 1998;38:308-11.
  18. McAvoy CE, Kamalarajab S, Best R, Rankin S, Bryars J, Nelson K. Bilateral third and unilateral sixth nerve palsies as early presenting signs of metastatic prostate carcinoma. *Eye (Lond)* 2002;16:749-53.
  19. Seymore CH, Peeples WJ. Cranial nerve involvement with carcinoma of prostate. *Urology* 1988;31:211-3.
  20. Vikram B, Chu FC. Radiation therapy for metastases to the base of the skull. *Radiology* 1979;130:465-8.
  21. Ransom DT, Dinapoli RP, Richardson RL. Cranial nerve lesions due to base of the skull metastases in prostate carcinoma. *Cancer* 1990;65:586-9.
  22. Iwai Y, Yamanaka K. Gamma knife radiosurgery for skull base metastasis and invasion. *Stereotact Funct Neurosurg* 1999;72:81-7.
  23. Francel PC, Bhattacharjee S, Tompkins P. Skull base approaches and gamma knife radiosurgery for multimodality treatment of skull base tumors. *J Neurosurg* 2002;97:674-6.
  24. Wecht DA, Sawaya R. Lesions of the calvaria: Surgical experience with 42 patients. *Ann Surg Oncol* 1997;4:28-36.
  25. Michael CB, Gokaslan ZL, DeMonte F, McCutcheon IE, Sawaya R, Lang FF. Surgical resection of calvarial metastases overlying dural sinuses. *Neurosurgery* 2001;48:745-54.
  26. Yi HJ, Kim CH, Bak KH, Kim JM, Ko J, Oh SJ. Metastatic tumors in the sellar and parasellar regions: Clinical reviews of four cases. *J Korean Med Sci* 2000;15:363-7.

**How to cite this article:** Cecchi PC, Kluge R, Schwarz A. Calvarial metastasis from endometrial carcinoma: Case report and review of the literature. *Asian J Neurosurg* 2014;9:242-3.

**Source of Support:** Nil, **Conflict of Interest:** None declared.

