

# Use of bedside ultrasound to diagnose dislodged gastric band

## Abstract

**Introduction:** Obesity levels mean an increased presentation of patients with Laparoscopic adjustable gastric banding (LAGB).

**Method:** Literature search revealed a paucity of information on ultrasonography to diagnose a slipped LAGB.

**Conclusion:** 2D Ultrasonography with a standard low frequency curvilinear probe proved to be a simple, effective method of diagnosing slipped Laparoscopic adjustable gastric banding (LAGB). We suggest the inclusion of routine abdominal ultrasound (after drinking water to improve sensitivity of the test) as part of the routine workup of suspected LAGB slippage.

**Keywords:** clinician ultrasound, gastric band, LAGB, PoCUS.

**Dirk Bass**  
MBBS

**Malek Telfah**  
MBBS, CCPU

**Justin Bowra**  
FACEM, CCPU

Emergency Care Unit  
Sydney Adventist Hospital  
Wahroonga  
New South Wales  
Australia

Correspondence to email  
dirk.bass@gmx.de

## Introduction

Obesity is one of the most significant preventable causes of chronic illness in Australia.<sup>1</sup> Laparoscopic adjustable gastric banding (LAGB) is an operation performed to counter obesity, whereby surgeons place an inflatable silicon device around the upper part of the stomach to create a small 'pouch' that can only hold a small amount of food and thus creating early satiety in the patient.<sup>2</sup> According to a publication by Australian Bureau of Statistics<sup>3</sup> around 13,600 Australians had this procedure in 2008 (excluding public patients in public hospitals). LAGB is associated with unique complications that require early recognition. One of these is slippage of the band either cranially or caudally.<sup>4</sup> We present the first published case report of diagnosis of slipped band diagnosed with bedside ultrasound.

## Methods

A literature search was performed on the following databases (EBSCOhost, CINAHL Plus, MEDLINE) using the following search terms (*lap\*band, lap band, lap band AND Ultrasound, lap band AND Ultras\*, lap band AND US, lap band AND Sono\*, lap band AND echo\**). This yielded a total of 102 studies of which none discussed the use of ultrasound to diagnose slipped LAGB.

## Case presentation

A 59-year-old woman presented to our emergency department (ED) in April 2014 with a five day history of nausea and vomiting, on a background of LAGB insertion in 2010. She had initially attended another emergency department where she was diagnosed with gastritis and discharged with pantoprazole 80mg daily and paracetamol 500mg/codeine 30mg PRN. Her

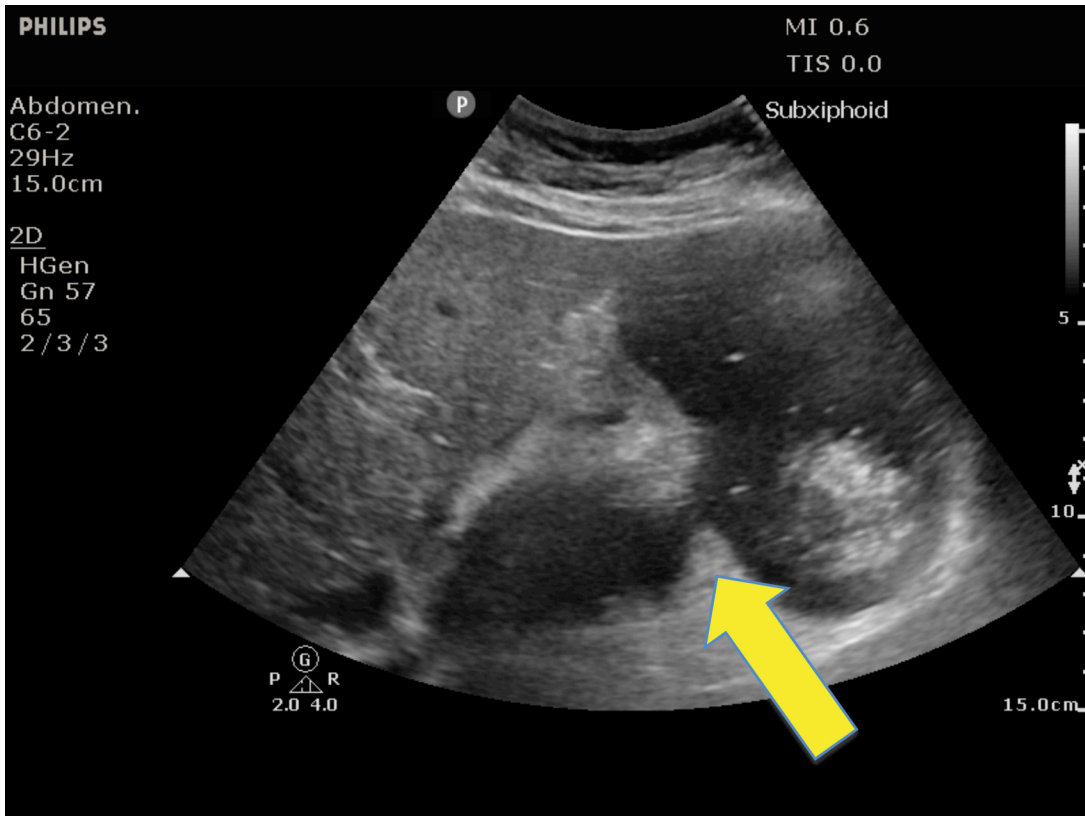
symptoms continued to worsen after discharge, and when she presented to our ED she had been unable to eat for two days.

On physical examination her observations were: heart rate 101 bpm, BP 161/99 mm Hg, afebrile, weight 66.2 kg. Her abdomen was soft with moderate epigastric tenderness. Bowel sounds were present. Her investigations demonstrated a mildly elevated white cell count ( $13.5 \times 10^9/L$ ), neutrophil count ( $12.0 \times 10^9/L$ ), erythrocyte sedimentation rate (53 mm/hr) and C-reactive protein (22.7 mg/L), with otherwise unremarkable blood tests including full blood count, electrolytes and liver function tests, venous blood gas and lactate.

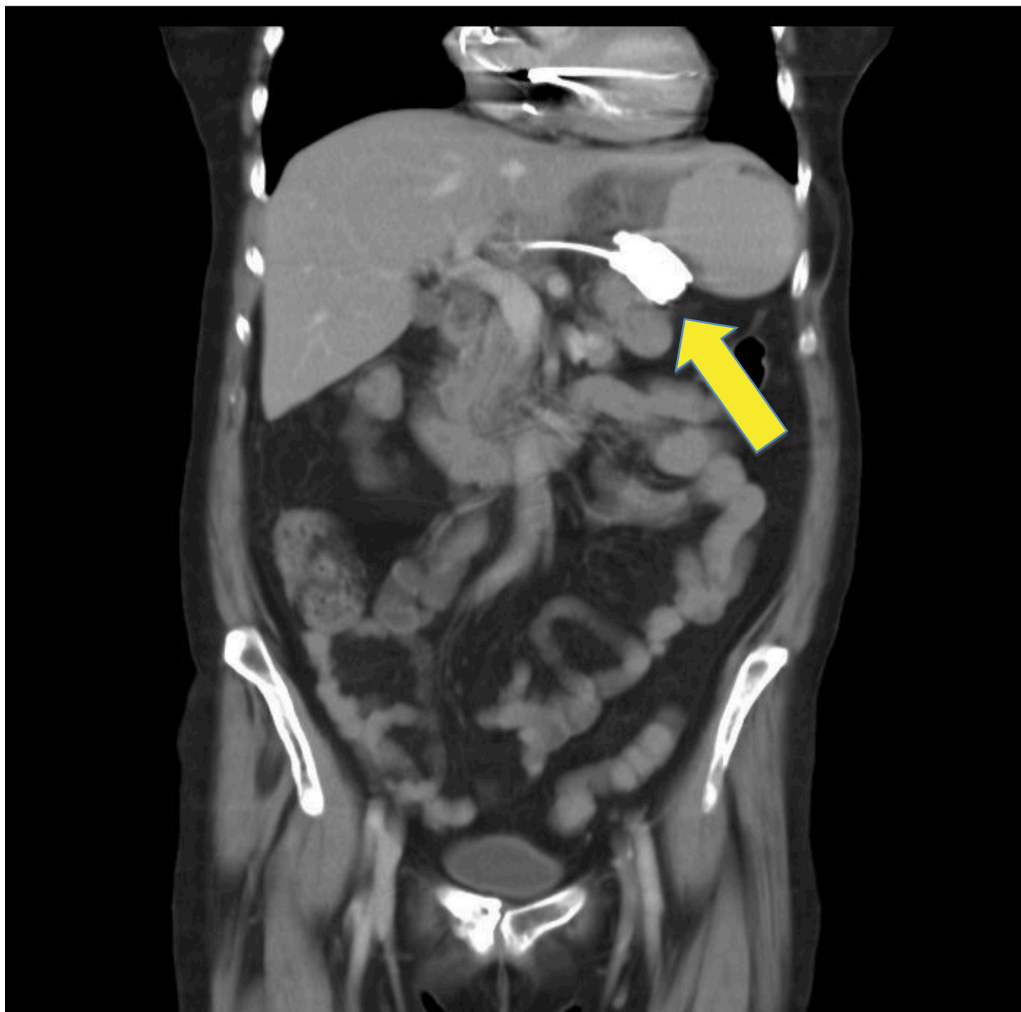Abdominal computer tomography (CT) was arranged with oral contrast (sodium diatrizoate, *Ioscan*<sup>®</sup>). Prior to CT, the emergency trainee doctor on duty (DB) performed B-mode bedside ultrasound (Philips Sparq system, Bothell, WA, USA) with 2–6 MHz curvilinear transducer and demonstrated a fluid-filled stomach with what it appeared to be oral contrast and failure to pass beyond a pathological narrowing. (Figure 1) This was presumed to be due to a slipped LAGB. Subsequently this was confirmed by contrast CT of the abdomen (Figure 2), which was reported as 'dislodged gastric band with gastric obstruction and large gastric pouch.' Specifically the CT report noted:

The gastric band is located along the proximal body of the stomach and there is a 9–10 cm large gastric pouch superolateral to the band. The appearance is in keeping with band slippage. There is secondary dilatation of the fluid-filled distal oesophagus and oral contrast is passed into the stomach distal to the band.

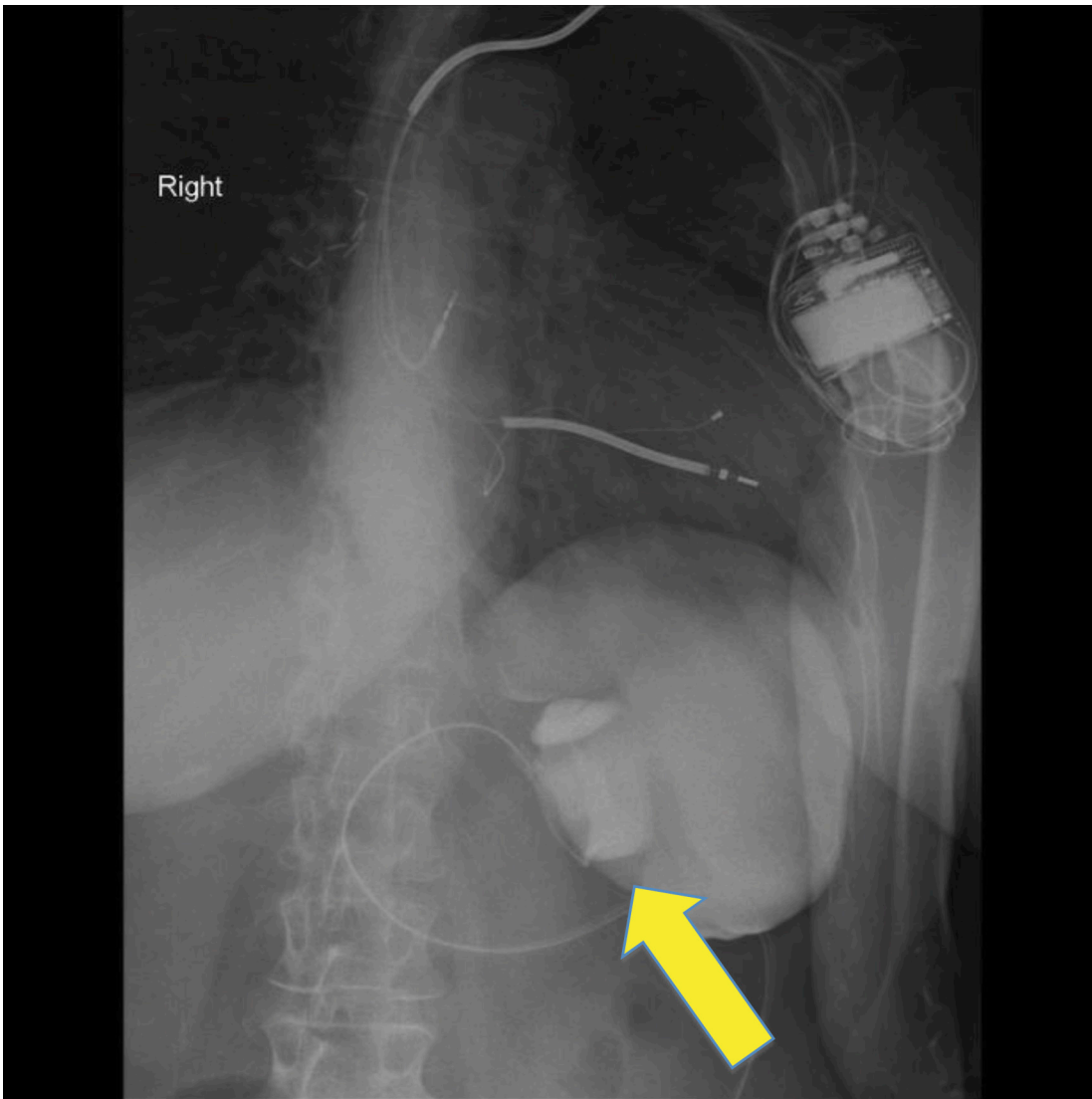
A non-ionic contrast (gastrograffin) swallow



**Figure 1:** B mode ultrasound image, transducer held in transverse orientation midway between xiphisternum and umbilicus. Area of narrowing due to LAGB slippage is indicated by arrow.



**Figure 2:** Coronal image taken from abdominal contrast CT, demonstrating radio-opaque LAGB slippage (arrow corresponds to narrowing seen in Figure 1).



**Figure 3:** Gastrograffin swallow demonstrating radio-opaque LAGB slippage (arrow corresponds to narrowing seen in Figure 1).

**Table 1:** LAGB slip classification (4).

Type	Definition	Mechanism	Management
I	Anterior Slip	Downward migration of band	Surgical
II	Posterior Slip	Posterior stomach wall herniates through band	Surgical
III	Pouch enlargement	Pouch dilation, due to tight band or overeating	Band deflation, re-education
IV	Immediate postoperative prolapse	Band placed too low on the stomach	Surgical
V	Type I or II with gastric necrosis	Band slip with pouch ischemia	Surgical

was also requested by the surgeon, and demonstrated 'no flow of contrast through the region of the band into the distal stomach or small bowel' (Figure 3).

#### **Treatment**

After an unsuccessful attempt to aspirate the gastric port of the LAGB under local anaesthesia, the patient underwent laparoscopic removal the next day.

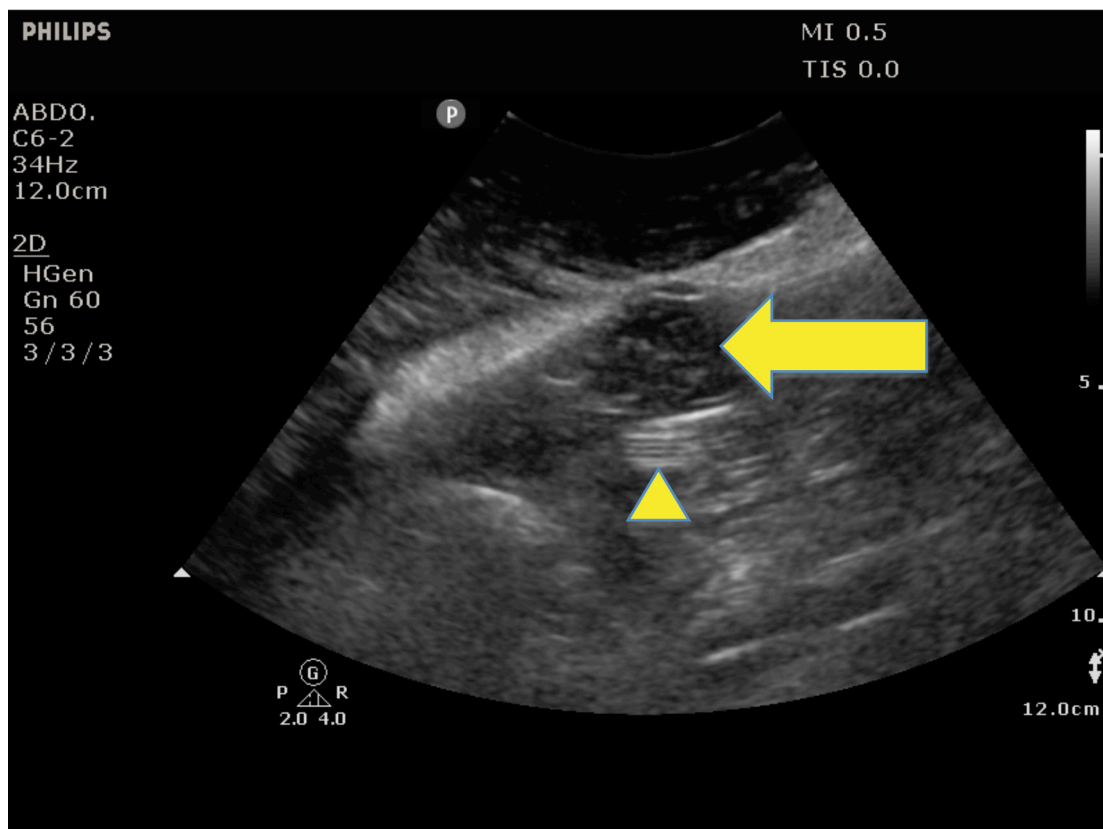
#### **Discussion**

Laparoscopic adjustable gastric banding (LAGB) is considered to be a safe and effective method of weight loss and reduction of comorbidities associated with obesity.<sup>4,5</sup> Enlargement of

the pouch, band slip and erosion, port breakage and port-site infection are the complications most commonly seen with LAGB.<sup>4</sup>

Band slip (a cranial or caudal movement of the band) has 1–22% incidence rate.<sup>6</sup> Since the cross-sectional area of the stomach is larger at the body than at the level of the angle of His (normal band position), complete obstruction of the stomach can occur when the band slips. The band slip can be anterior or posterior depending on which area of the stomach herniates through the band<sup>4</sup> (Table 1).

An anterior slip is most commonly caused by insufficient anterior fixation or disruption of the fixation sutures, vomiting or overeating. A posterior slip is more commonly related to



**Figure 4:** B-mode ultrasound transverse image of patient with uncomplicated LAGB. Note what appears to be reverberation artifact from the echogenic LAGB itself (arrowhead) and the presence of a small amount of fluid in the stomach proximal to the LAGB (arrowed).

surgical failure. In both types of slip, the patient usually presents with dysphagia, vomiting, regurgitation and food intolerance. Prolonged band slippage can cause upper GI-bleeding, perforation or necrosis of the stomach.<sup>4</sup>

Radiographic screening of gastric band slippage in Emergency departments is most commonly performed using erect abdominal x-ray. According to a case controlled study by Swenson, *et al.*<sup>7</sup> X-ray features include:

- Angle (Phi angle) between the vertical axis and the gastric band greater than 58°
- Greater than 3 cm inferior displacement of the superolateral band margin from the diaphragm
- Presence of an air-fluid level above the band
- Presence of an 'O'-shaped configuration of the gastric band on PA film ('O' sign).

Definitive testing is most commonly performed using abdominal contrast CT or gastrograffin swallow assessment, both of which can clearly identify the band slippage.<sup>8</sup>

Abdominal ultrasound is rarely performed for this indication, due to expected difficulties in image quality. However, US is used to localize the LAGB access port as described by Mayes *et al.*<sup>9</sup>, and ultrasound has certain advantages over plain x-ray, CT and gastrograffin swallow. Most importantly, it is noninvasive and free of ionizing radiation and can be performed at the bedside. Ultrasound imaging of a patient with uncomplicated LAGB may reveal scatter from air in the stomach, or a small amount of fluid in a non-distended stomach; the LAGB itself may demonstrate reverberation artifact, or it may be obscured by overlying air in the stomach (Figure 4).

In the case discussed here, the slipped LAGB itself was not identified on ultrasound. Rather, a pathological 'hourglass'

dilatation of the stomach was rendered visible (Figure 1) due to the large amount of oral contrast drunk in preparation for the CT. It is possible that routinely asking patients to drink water before they are scanned would improve the sensitivity of ultrasound in detection of LAGB complications.

### Conclusion

2D Ultrasonography with a standard low frequency curvilinear probe proved to be a simple, effective method of diagnosing slipped LAGB. We suggest the inclusion of routine abdominal ultrasound (after drinking water to improve sensitivity of the test) as part of the routine workup of suspected LAGB slippage.

### Consent

Informed verbal consent was obtained from the patient for publication of this case-report and accompanying images.

Conflict of interest: none declared.

Funding: no funding was sought or received for this study.

### References

- 1 Australian Bureau of Statistics. (ABS), publication no 4719.0: Overweight and Obesity in Adults, Australia. 2004-2005 (ABS cat. no. 4719.0.), available at <http://www.abs.gov.au/ausstats/abs@.nsf/mf/4719.0/>. [cited 30.09.2014].
- 2 Khalafzai RU. Laparoscopic Adjustable Gastric Banding: A Miracle Cure? *Chisholm Health Ethics Bulletin* 2008; 13: 1-4.
- 3 Australian Bureau of Statistics. (ABS), publication no 4102.0: Australian Social Trends. Dec 2009 (ABS cat.no. 4102.0), available at <http://www.abs.gov.au/AUSSTATS/abs@.nsf/Lookup/4102.0Main+Features30Dec+2009>. [cited 30.09.2014].
- 4 Eid I, Birch DW, Sharma AM, Sherman V, Karmali S. Complications associated with adjustable gastric banding for morbid obesity: a

- surgeon's guides. *Can J Surg* 2011; 54: 61–66.
- 5 Titi M, Jenkins JT, Modak P, Galloway DJ. Quality of life and alteration in comorbidity following laparoscopic adjustable gastric banding. *Postgrad Med J* 2007; 83: 487–91.
  - 6 Hady HR, Dadan J, Soldatow M, Ladny RJ, Golaszewski P, Wroblewski E, *et al.* Complications after laparoscopic gastric banding in own material. *Videosurgery and Other Miniinvasive Techniques*. 2012; 7: 166–74.
  - 7 Swenson DW, Pietryga JA, Grand DJ, Chang KJ, Murphy BL, Eggin TK. Gastric band slippage: a case-controlled study comparing new and old radiographic signs of this important surgical complication. *AJR Am J Roentgenol* 2014; 203: 10–16.
  - 8 Beitner M, Kurian MS. Laparoscopic adjustable gastric banding. *Abdom Imaging* 2012; 37: 687–89.
  - 9 Mayes JT, Salameh JR. Ultrasound Guided Localization of Adjustable Gastric Banding Access Port. Poster presentation in the 2009 Scientific Session of the Society of American Gastrointestinal and Endoscopic Surgeons (SAGES); April 22-25, 2009; Phoenix Convention Centre, Arizona, available at <http://www.sages.org/meetings/annual-meeting/abstracts-archive/ultrasound-guided-localization-of-adjustable-gastric-banding-access-port>. [cited 30.09.2014].
-