

An incomplete vascular ring causing respiratory distress



Syeda Samar Sohail^a, Muhammad Tariq^b, Muneer Amanullah^{b,*}

^a Medical College, Aga Khan University, Karachi

^b Division of Cardiothoracic Surgery, Department of Surgery, Aga Khan University Hospital, Karachi

^{a,b} Pakistan

Kommerell's diverticulum is a rare saccular aneurysmal dilation of the descending aorta. We report a case of a 3.5-year-old boy with the extremely rare combination of Kommerell's diverticulum with a right descending aorta and proximal patent ductus arteriosus aneurysm forming an incomplete vascular ring. To our knowledge, this rare case has not been reported to date.

© 2017 The Authors. Production and hosting by Elsevier B.V. on behalf of King Saud University. This is an open access article under the CC BY-NC-ND license (<http://creativecommons.org/licenses/by-nc-nd/4.0/>).

Keywords: Aorta, Congenital heart disease, Kommerell's diverticulum, Vascular ring, Vascular surgery

Introduction

Kommerell's diverticulum is a rare saccular aneurysmal dilation of the descending aorta. There are variants of Kommerell's diverticulum which may occur in combination with congenital heart defects or may occur in isolation [1].

A rare anomaly of a left-sided aortic arch with a right-sided descending thoracic aorta was first reported in 1948 [2]. It occurs when the terminal portion of a left aortic arch crosses the midline to the right and descends along the right paravertebral gutter. This aortic anomaly results from regression of the right aortic arch between the right common carotid artery and the right subclavian artery, with persistence of the distal end of

the primitive right dorsal aorta [2]. We present a case of an incomplete vascular ring due to a rare combination of Kommerell's diverticulum, proximal patent ductus arteriosus aneurysm, and a right descending aorta, resulting in compression of the left main stem bronchus causing respiratory symptoms in the patient. This combination has previously been unreported to the best of our knowledge.

Case report

A 3.5-year-old boy presented to the clinic with a 3-year history of productive cough and dyspnea.

On examination, the child was alert and active. The trachea was centrally located. His respiratory

Disclosure: Authors have nothing to disclose with regard to commercial support.

Received 4 February 2017; accepted 19 April 2017.

Available online 27 April 2017

* Corresponding author at: Congenital Cardiac Surgery, Department of Surgery, Aga Khan University Hospital, Stadium Road, PO Box 3500, Karachi 74800, Pakistan.

E-mail address: muneer.amanullah@aku.edu (M. Amanullah).



P.O. Box 2925 Riyadh – 11461KSA
Tel: +966 1 2520088 ext 40151
Fax: +966 1 2520718
Email: sha@sha.org.sa
URL: www.sha.org.sa



1016-7315 © 2017 The Authors. Production and hosting by Elsevier B.V. on behalf of King Saud University. This is an open access article under the CC BY-NC-ND license (<http://creativecommons.org/licenses/by-nc-nd/4.0/>).

Peer review under responsibility of King Saud University.

URL: www.ksu.edu.sa

<http://dx.doi.org/10.1016/j.jsha.2017.04.005>



Production and hosting by Elsevier

rate was 24 breaths/min with normal vesicular breathing and no added sounds.

A computed tomography (CT) scan revealed a right-sided thoracic aorta and a Kommerell's diverticulum at the site of the ductus ligament at the anteromedial aspect of the aorta, making an obtuse angle with the aortic wall along with a proximal patent ductus arteriosus aneurysm towards the pulmonary artery end. The aneurysm seemed to be causing a pressure effect on the left main stem bronchus with significant stenosing reducing its lumen to <2 mm, resulting in a significantly hyperinflated left upper lobe. This was causing a mass effect with mediastinal shift towards the right.

Bronchoscopy showed a slit-like opening of the left main bronchus (Fig. 1A). Surgery was planned to resect the aneurysm and Kommerell's diverticulum via a left posterolateral thoracotomy through the fourth intercostal space.

The proximal patent ductus arteriosus stump towards the main pulmonary artery was engorged and compressing the left main stem bronchus. The patent ductus arteriosus was isolated and divided, and the stumps on both sides oversewn. The Kommerell's diverticulum was also resected and the base oversewn.

Postoperative bronchoscopy showed >50% increase in the internal luminal diameter of the left main stem bronchial obstruction (Fig. 1B).

The postoperative course was uneventful; the patient recovered promptly and was discharged home.

Discussion

Malformations of the aortic arch are rare; however, they are easily diagnosed. Our report of a Kommerell's diverticulum with a normal left-sided aortic arch, a right descending aorta coupled with a proximal patent ductus arteriosus aneurysm, is extremely rare.

Differential diagnosis is very important in the investigation of infants with chronic respiratory symptoms. Anomalies of the aortic arch must be included among the initial differentials. Vascular ring, aberrant innominate artery, thoracic masses such as bronchogenic cysts, and benign and malignant tumors of the mediastinum can cause tracheal and bronchial obstruction.

Kommerell's diverticulum can occur in a number of aortic arch anomalies that can, but do not always, cause symptoms of airway or esophageal compression. Kommerell's diverticulum originates from the persistent distal end of the inter-

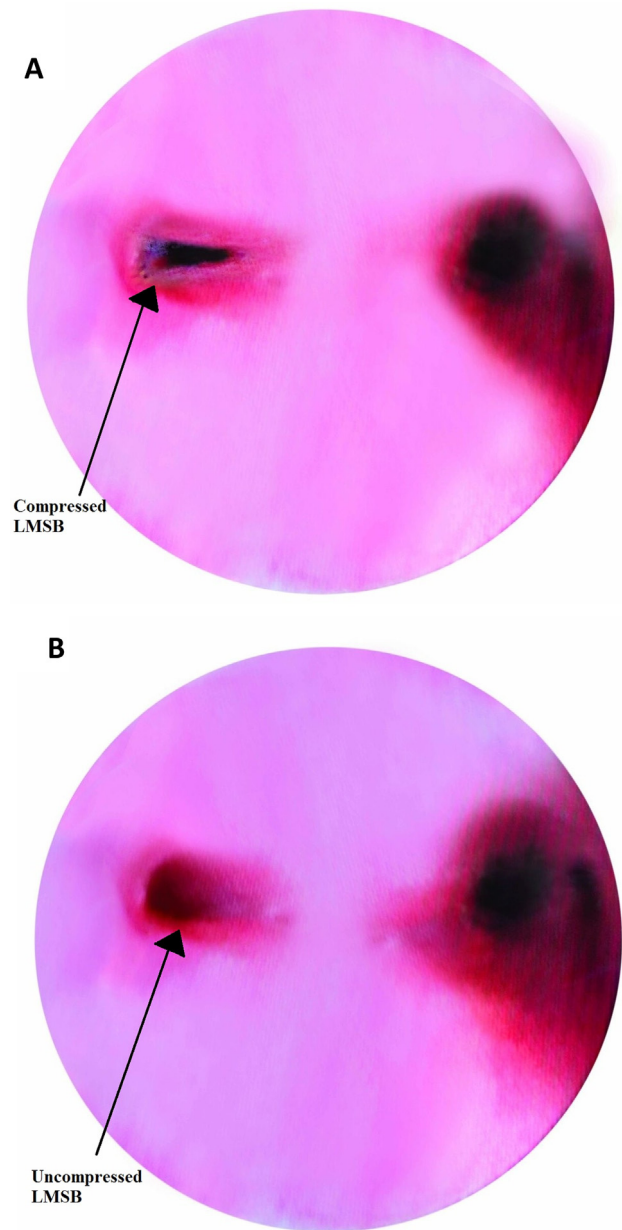


Figure 1. (A) Prior to surgery, bronchoscopy revealed a slit-like opening of the left main stem bronchus (LMSB). (B) Postsurgery, the LMSB shows a >50% increase in the internal luminal diameter.

rupted fourth aortic arch. It is a dilated vascular structure that is found at the origin of an aberrant right or left subclavian artery. Kommerell originally described the diverticulum in a patient with left aortic arch and aberrant right subclavian artery. Kommerell's diverticulum has several variations, one of which is described with a left aortic arch with a right descending aorta and a ductus arteriosus as seen in our patient. The anomaly results from regression of the right aortic arch between the right common carotid and right sub-

clavian arteries and persistence of the primitive right dorsal aorta [1].

Congenital ductus arteriosus aneurysm is a sacular dilation and elongation of the ductus arteriosus. Although the incidence of ductus arteriosus aneurysm is largely unknown, in isolation it has been reported with a rather high incidence of

8.8% in a prospective study. Patients with these anomalies can present with symptoms due to compression of the airway and/or the esophagus amongst others [3].

The clinical presentation of our patient with dyspnea and recurrent chest infections suggested respiratory tract compression by an encircling vascular ring [4]. The basic component of such rings is the anomalous position of the aortic arch and the patent ductus arteriosus which passes from the displaced arch to a normal pulmonary artery. There are many variations of this ring, but all true vascular rings have components on either side of the trachea and occasionally the esophagus [5]. In our case, the patent ductus arteriosus was to the left, as was the aortic arch, but the thoracic aorta descended to the right side of the spine creating an incomplete vascular ring which was further aggravated by the Kommerell's diverticulum and an aneurysm on the proximal aspect of the patent ductus arteriosus by impinging on the left main stem bronchus (Fig. 2A and B). Although mimicking the signs and symptoms of a true vascular ring, this arrangement did not actually encircle the mediastinal structures. Surgical intervention is the only modality of treatment of this anomalous presentation.

Preoperative evaluation of the airway by radiology is important in all cases with vascular anomalies in the mediastinum. CT and magnetic resonance imaging (MRI) are frequently used for diagnosis, with the specific objective of recognizing other forms of extrinsic compression of the airway or esophagus such as mediastinal tumors and cysts [6]. An echocardiogram can also be used for the investigation of associated cardiac malformations, however, it does not allow for a differential diagnosis of vascular rings [7]. With the increased use of diagnostic techniques such as CT scans, MRI, and echocardiography, these anomalies can be diagnosed more frequently.

Patient consent

Consent was received from the patient's guardian for the case report.

Acknowledgments

Dr Asif Hasan, Consultant Paediatric Cardiothoracic Surgeon, Freeman Hospital, Newcastle Upon Tyne Hospitals for his scientific contributions, and Syeda Samar Sohail for the illustrations.

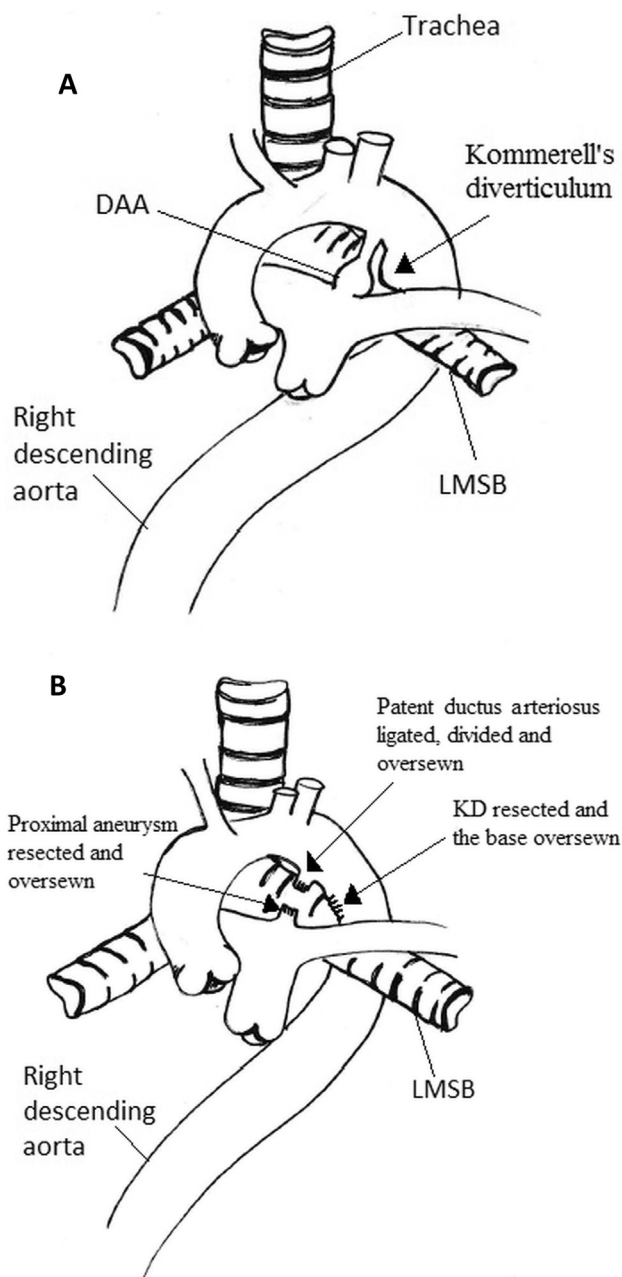


Figure 2. (A) Preoperative diagram of the anomaly. (B) Postoperative diagram. The patent ductus arteriosus was ligated and divided, and the stumps toward the main pulmonary artery and the aorta were oversewn using Prolene 5-0 sutures. Kommerell's diverticulum (KD) was also resected and the base oversewn. DAA = ductus arteriosus aneurysm; LMSB = left main stem bronchus.

References

- [1] Van Son JA, Konstantinov IE, Burckhard F, Kommerell and Kommerell's diverticulum. *Tex Heart Inst J* 2002;29:109–12.
- [2] Paul RN. A new anomaly of the aorta: left aortic arch with right descending aorta. *J Pediatr* 1948;32:19–29.
- [3] Jan S, Hwang B, Fu Y, Chai JW, Chi CS. Isolated neonatal ductus arteriosus aneurysm. *J Am Coll Cardiol* 2002;39:342–7.
- [4] Woods R, Sharp R, Holcomb 3rd G, Snyder CL, Lofland GK, Ashcraft KW, et al. Vascular anomalies and tracheoesophageal compression: a single institution's 25-year experience. *Ann Thorac Surg* 2001;72:434–8.
- [5] Davies M, Guest P. Developmental abnormalities of the great vessels of the thorax and their embryological basis. *Br J Radiol* 2003;76:491–502.
- [6] Van Son JA, Julsrud PR, Hagler DJ, Sim EK, Puga FJ, Schaff HV, et al. Imaging strategies for vascular rings. *Ann Thorac Surg* 1994;57:604–10.
- [7] Backer CL, Mongé MC, Popescu AR, Eltayeb OM, Rastatter JC, Rigsby CK. Vascular rings. *Semin Pediatr Surg* 2016;25:165–75.