

An Unusual Cause of Posterior Reversible Encephalopathy Syndrome

Abstract

Posterior reversible encephalopathy syndrome (PRES) is a clinical radiographic diagnosis of heterogeneous etiologies. The pathogenesis of PRES remains unclear, but may be related to impaired cerebral autoregulation and endothelial dysfunction. We present a case of intravascular nonionic contrast-induced PRES observed after cerebral angiography. The index patient was a follow-up case of large vertebrobasilar artery-dissecting aneurysm for which endovascular coiling was done 6 months back. She improved completely within a week. Contrast-induced PRES is a reversible benign condition, knowledge of which is crucial for appropriate management.

Keywords: Cerebral angiography, nonionic contrast, posterior reversible encephalopathy syndrome

Introduction

Posterior reversible encephalopathy syndrome (PRES) is a clinico-radiological entity characterized by altered sensorium, a seizure with posterior predominant brain white matter vasogenic edema. It is a neurotoxic state caused by diverse clinical entities. Nonionic contrast used in cerebral angiography causing PRES is unusual with limited literature report. We present a case of intravascular dye-induced PRES, a benign treatable condition observed after cerebral angiography. Knowledge of this condition is critical for proper management.

Case Report

Six-month follow-up cerebral angiography was performed in a 54-year-old woman having large vertebrobasilar artery-dissecting aneurysm for which endovascular coiling was done [Figure 1a and b]. During cerebral angiography under local anesthesia, while taking vertebral artery injection, she suddenly became unresponsive. On examination, she had sustained gaze deviation toward the left with tonic posturing of limbs lasting for 1 min followed by postictal phase. Differential etiologies such as dye-induced seizure, iatrogenic embolic phenomenon, or contrast anaphylaxis were considered at first. Immediately, selective cerebral vessel injection was taken which ruled out intraprocedural vessel dissection or clot occlusion. After 10 min, she started

responding to commands, but had bilateral visual obscuration with normal papillary light reaction, indicative of cortical blindness. A clinical possibility of Anton syndrome was also considered. Urgent noncontrast computed tomography head was done which revealed no evidence of bleeding or ischemic changes. Continuous electroencephalography monitoring revealed intermittent epileptiform discharges in bilateral temporal fields with episodes of transient background slowing. Magnetic resonance imaging (MRI) of brain showed bilateral occipital subcortical white matter T2 and fluid-attenuated inversion recovery hyperintensities [Figure 2a and b], suggestive of PRES. Diffuse cortical hyperintensities [Figure 2c and d] were noted in occipital, parietal, and temporal regions (postictal changes). The temporal sequence of events and clinico-radiological finding in our index patient was suggestive that PRES was induced by intravascular nonionic contrast (iohexol). Her symptoms improved completely with intravenous methylprednisolone and antiepileptic drugs.

Discussion

Transient cortical blindness following intravascular nonionic contrast angiography is reported in literature with an incidence of 0.3%–1%, although seizure with PRES-like syndrome is rare.^[1] Differential diagnoses such as iatrogenic embolic phenomenon, dye reaction, or seizure should be considered first as it needs immediate

**Biab Das,
Gaurav Goel,
Anshu Mahajan,
Atma Ram Bansal¹,
Harsh Sapra²,
Ajaya Nanda Jha³**

Departments of
Neurointervention, ¹Neurology,
²Neuroanesthesia and
³Neurosurgery, Institute of
Neuroscience, Medanta The
Medicity, Gurgaon, Haryana,
India

Address for correspondence:

Dr. Gaurav Goel,
Department of
Neurointervention, Institute of
Neuroscience, Medanta The
Medicity, Gurgaon, Haryana,
India.

E-mail: drgauravgoel1@gmail.com

Access this article online

Website: www.asianjns.org

DOI: 10.4103/ajns.AJNS_188_17

Quick Response Code:



How to cite this article: Das B, Goel G, Mahajan A, Bansal AR, Sapra H, Jha AN. An unusual cause of posterior reversible encephalopathy syndrome. Asian J Neurosurg 2018;13:1254-6.

This is an open access journal, and articles are distributed under the terms of the Creative Commons Attribution-NonCommercial-ShareAlike 4.0 License, which allows others to remix, tweak, and build upon the work non-commercially, as long as appropriate credit is given and the new creations are licensed under the identical terms.

For reprints contact: reprints@medknow.com

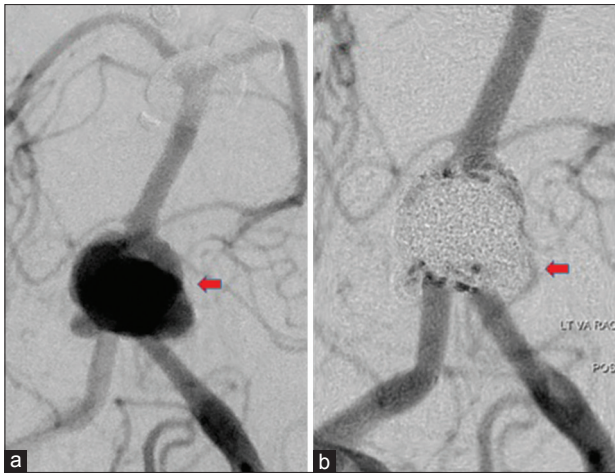


Figure 1: Digital subtraction angiography of cerebral vessel showing fenestrated vertebrobasilar junction aneurysm ([a] precoiling; [b] postcoiling)

care. The patient in our case should also be evaluated for Anton syndrome or PRES. Clinical symptoms and MRI help in differentiating PRES from other causes. The temporal sequences of events and the clinicoradiological finding in our index patient were conclusive that PRES was induced by intravascular contrast. Penetration of blood–brain barrier (BBB) tight capillary junctions and endothelial pinocytosis adversely affects neural membrane.^[2] Neurotoxicity depends on ionic properties, lipid solubility, hyperosmolality, and viscosity.^[3] PRES is a neurotoxic state commonly described in clinical conditions such as preeclampsia/eclampsia, allogeneic bone marrow transplantation, posttransplantation, autoimmune diseases, or after high-dose cancer chemotherapy. Predominant occipital lobe involvement may be explained by relative lack of protective, sympathetically mediated arteriolar vasoconstriction in the posterior circulation during severe hypertension and endothelin release.^[4]

Certain factors such as hypertension may increase the incidence of neurotoxicity of contrast material other than contrast material properties.^[5] It seems that vertebral artery angiography has more chance to have PRES-like syndrome compared to anterior circulation. In our patient, the presence of giant vertebrobasilar artery aneurysm might have made BBB more susceptible to contrast-induced neurotoxic effect. Intravascular iohexol was used as contrast media in our case which is a monomeric nonionic contrast medium with an osmolality of 709 mosm/kg H₂O. Hence, if undiluted contrast is used, the relative higher osmolality (blood osmolality is 300 mosm/kg) may be a contributing factor to an increased BBB permeability.

Usually, patient symptoms including cortical blindness improve completely over days to weeks. Short-course oral prednisolone (1 mg/kg with tapering over 1–2 weeks) or steroid pulse (1000 mg/day for 3 days) in addition to antiepileptic drug in patients having seizure helps in

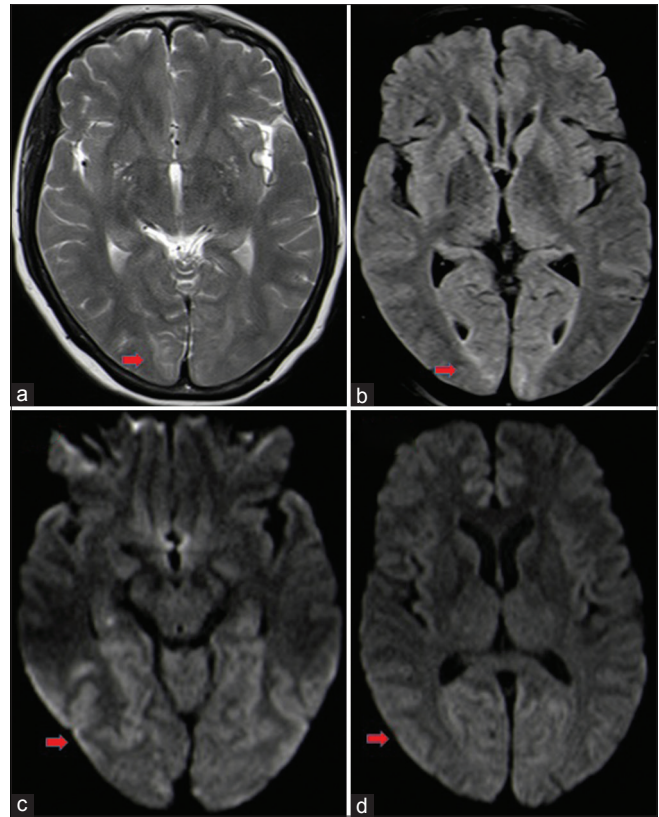


Figure 2: Magnetic resonance imaging brain showing T2 and fluid-attenuated inversion recovery hyperintensities (a and b) in bilateral occipital subcortical white matter, suggestive of posterior reversible encephalopathy syndrome. Diffusion image showing cortical hyperintensities (c and d) in occipital, parietal, and temporal regions (likely postictal changes)

controlling this benign condition. Follow-up imaging can be performed to observe resolution of previous findings.

Conclusion

We believe that reversible acute neurological worsening with PRES-like syndrome during angiography in our patient was due to neurotoxic effect of nonionic contrast media. Intravascular contrast-induced PRES is an unusual self-limiting condition having complete recovery, knowledge of which is crucial for management.

Financial support and sponsorship

Nil.

Conflicts of interest

There are no conflicts of interest.

References

1. Rama BN, Pagano TV, DelCore M, Knobel KR, Lee J. Cortical blindness after cardiac catheterization: Effect of rechallenge with dye. *Cathet Cardiovasc Diagn* 1993;28:149-51.
2. Waldron RL, Brian RN. Effect of contrast media on the blood brain barrier: An electron microscopic study. *Radiology* 1975;116:195-8.
3. Torvik A, Walday P. Neurotoxicity of water-soluble contrast

- media. *Acta Radiol Suppl* 1995;399:221-9.
4. Zwicker JC, Sila CA. MRI findings in a case of transient cortical blindness after cardiac catheterization. *Catheter Cardiovasc Interv* 2002;57:47-9.
 5. Saigal G, Bhatia R, Bhatia S, Wakhloo AK. MR findings of cortical blindness following cerebral angiography: Is this entity related to posterior reversible leukoencephalopathy? *AJNR Am J Neuroradiol* 2004;25:252-6.