




Challenging retrovesical mass in men: report of a rare liposarcoma case with concurrent COVID-19 infection

Indah Jamtani ¹, Adianto Nugroho ¹, Nur Rahadiani ²,
R Samuel W Manangka³

¹Department of Surgery,
Fatmawati Central General
Hospital, Jakarta Selatan, DKI
Jakarta, Indonesia

²Anatomical Pathology
Department, Faculty of
Medicine, Universitas Indonesia/
Cipto Mangunkusumo National
Referral Hospital, Jakarta,
Indonesia

³Radiology Department,
Mayapada Hospital, DKI Jakarta,
Indonesia

Correspondence to
Dr Adianto Nugroho;
adiyusuf97@gmail.com

Accepted 16 February 2021

SUMMARY

We describe a case of retrovesical liposarcoma in a male patient with concurrent COVID-19. A 50-year-old man had lower urinary tract symptoms and dull pain along his right gluteus. Due to COVID-19 infection, management was delayed. During self-isolation, the patient developed urinary retention and his pain level was an eight on the Visual Analogue Scale. A urinary catheter and an epidural catheter were inserted without any difficulty. Abdominal-pelvic MRI revealed a retrovesical mass suspected of liposarcoma with clear borders from surrounding organs. Following two consecutive negative SARS-CoV-2 PCR tests, we proceeded with surgery. Histopathology was dedifferentiated liposarcoma. Postoperatively, the patient suffered reactivation of COVID-19, and he was eventually discharged after two consecutive negative results on the PCR test on Post Operative Day (POD)-10. Retrovesical dedifferentiated liposarcoma is rare and considered as high-grade liposarcoma. Although surgery may exacerbate COVID-19 infection, surgical resection of symptomatic high-grade sarcoma is prioritised and performed as soon as no infection detected.

BACKGROUND

Liposarcomas are the most common soft-tissue sarcomas found in the intra-abdomen. Most intra-abdominal sarcomas are in the retroperitoneum and have non-specific symptoms.¹ Sarcomas originating from the retrovesical space are extremely rare,²⁻⁴ and liposarcoma of the retrovesical space had only been reported three times before.⁵⁻⁷ Here, we describe a case of retrovesical liposarcoma in a male patient with concomitant COVID-19 infection.

CASE PRESENTATION

An otherwise healthy 50-year-old man came in with lower urinary tract symptoms (LUTS), mainly the sensation of incomplete emptying of the bladder for the last month. He had also observed a dull pain along his right gluteus that radiated to his right thigh for 6 months. Further dive into the history, it was revealed that the patient had been feeling quite 'unfit' since the past 2 years. He had observed unspecific symptoms such as tire easily, recurrent cold and low-grade fever, and gradual decrease of appetite. He had dismissed those symptoms as casualty of overworked. He had also had his tonsils removed 1 year prior but never had a full medical check-up and follow-up about his fatigue and vague symptoms. On physical examination, there was no palpable abdominal mass. Ultrasonography (US) revealed a pelvic mass of 13 cm

of diameter compressing the bladder. The mass, initially thought to be of prostatic origin based on a follow-up non-contrast abdominal-pelvic MRI, was scheduled for a transurethral biopsy. However, the patient's preoperative SARS-CoV-2 PCR screening was positive for COVID-19 infection, although asymptomatic, causing a delay of the biopsy while the patient was self-quarantined.

The patient developed urinary retention within ten days of the initial assessment of the disease's course. His pain level increased from a 3 on the Visual Analogue Scale (VAS) to an 8. A urinary catheter was inserted without any difficulty for diversion, and an epidural catheter was placed for pain management.

INVESTIGATIONS

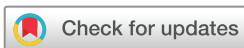Following his hospital admission due to urinary retention, a contrast abdominal-pelvic MRI was decided to re-evaluate the mass's character and its borders with the surrounding structure. The MRI showed a 9×10×14 cm pelvic mass on the right side that had pushed the bladder and urethra anteriorly and to the left side. The mass was a heterogeneous solid mass with a cystic component and central necrosis. It appeared encapsulated and with clear borders from the bladder, prostate and rectum (figure 1). There were multiple lymphadenopathies on the right cranialateral side of the mass. A fat suspension imaging sequence showed no change in the intensity of the tumour (figure 2).

DIFFERENTIAL DIAGNOSIS

We diagnosed the patient with retrovesical soft-tissue sarcoma and a high-grade schwannoma as a differential based on these findings.

TREATMENT

We proceeded with tumour resection surgery following two consecutive negative SARS-CoV-2 PCR tests. Through a lower abdominal midline incision, the mass was found posterior and inferior to the bladder. It was carefully dissected from the bladder and successfully removed in toto along with the prostate capsule (figure 3) and a drain was left in the pelvic floor. The histopathology report came up as dedifferentiated liposarcoma. Tumour mass dominantly composed of a high-grade tumour with a little part of a well-differentiated lipogenous component remains. H&E staining showed a predominantly spindle cell tumour with pleomorphic bizarre-looking nuclei (figure 4).



© BMJ Publishing Group Limited 2021. No commercial re-use. See rights and permissions. Published by BMJ.

To cite: Jamtani I, Nugroho A, Rahadiani N, et al. *BMJ Case Rep* 2021;**14**:e241466. doi:10.1136/bcr-2020-241466

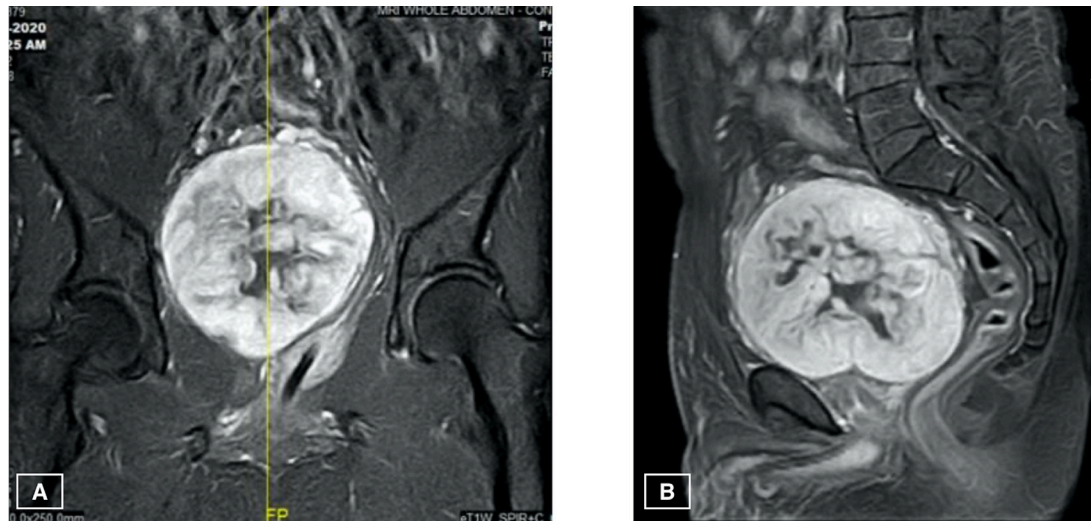


Figure 1 T1WI-FS postcontrast. (A) coronal view showing the mass pushing the prostate and pars-prostatic urethra, catheterised, to the left and, (B) sagittal view showing clear borders of the mass from the prostate, bladder and rectum. T1WI-FS, fat-suppressed T1-weighted imaging.

OUTCOME AND FOLLOW-UP

Apart from reactivation of the COVID-19 infection, the patient's postoperative period was unremarkable. He was in high care unit for the night after the surgery and experienced some shortness of breath that was attributed to intraoperative overzealous fluid resuscitation and postoperative pain. In addition, the postoperative haemoglobin level was 82 g/L. We decided to monitor him another night in the high care unit while transfusing 500 cc of packed red cell before moving him to the ward the next day. No restriction on diet and mobilisation. The patient was out of bed and walking by POD-2 and his appetite was good. By POD-3, the urinary catheter was removed and there was no difficulty in micturition function. Drain was removed by POD-4. We had planned to discharge him by POD-7 after a full body positron emission tomography (PET)-scan, however, a repeat SARS-CoV-2 PCR test, the day before discharge, once again tested positive for COVID-19. He had no symptoms of the disease, and the cycling threshold value was E-gene 32.24 and RdRp gene 34.10. He was moved to an isolation ward and was retested 24 hours after the first test which was negative and another one the following day which was also negative. The patient was eventually discharged at POD-10 after two consecutive negative results on the PCR test. The PET-scan was done 1 week after hospital discharged

and showed no focal hypermetabolic lesion in the pelvic area, neither any metastatic lesion.

The patient had recovered well from the surgery and returned to active daily activities by the second week. He was started on Taxotere and gemcitabine combination chemotherapy for six cycles started 1 month after the surgery. By the time, this report was written the patient had gone back to work and had finished six cycles of chemotherapy and was preparing for radiotherapy as part of disease management. We would like to report a long-term follow-up of this patient in a later date.

DISCUSSION

The retrovesical compartment of the rectovesical space is located between the urinary bladder and the rectum and bound by the rectovesical (Denovillier's) fascia in males and the vagina cervix uteri in a female.^{2,3} Primary tumours, not related to pelvic structures, arising from rectovesical space, are sporadic and had only been reported a few times before.²⁻⁴ In addition, a search of the literature revealed only three retrovesical liposarcoma cases had been reported before.⁵⁻⁷ The histology of those cases were of pleomorphic and myxoid liposarcoma. To our knowledge, dedifferentiated retrovesical

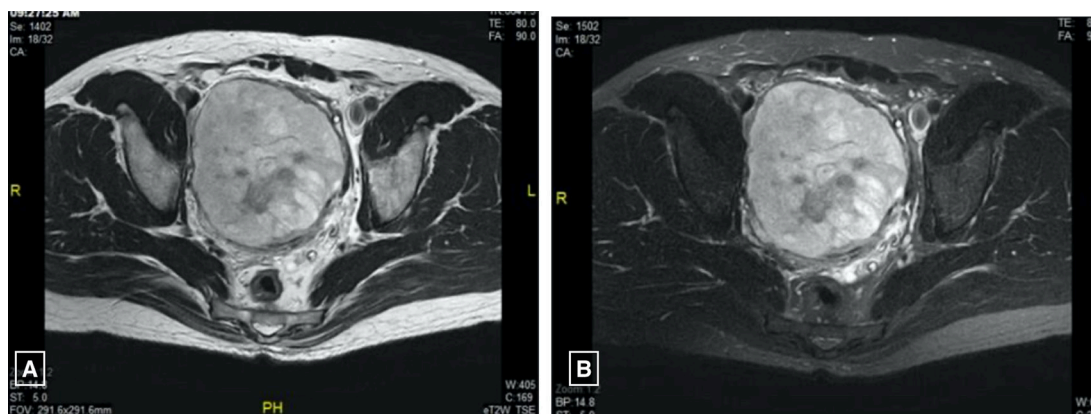


Figure 2 T1WI without contrast axial view (A) without fat suspension (B) fat suspension sequence showing no lower signal intensity in the tumour as typically seen in other fatty tissue. T1WI, T1-weighted imaging.

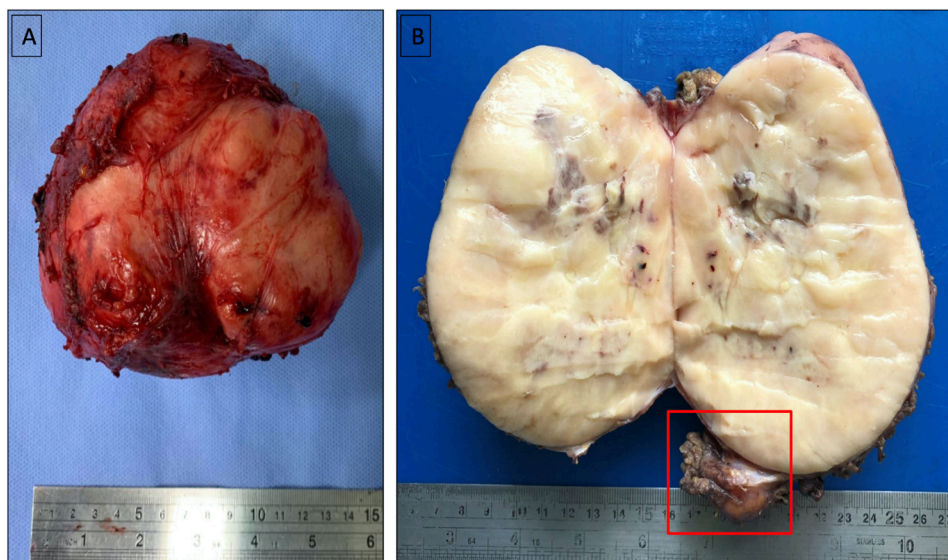


Figure 3 (A) fresh specimen taken out from the patient's body. (B) Cutting section of gross specimen showed a yellowish-tan solid tumour with a marked vascularised and necrosis area. (Note: the remaining fat tissue on the right inferior pole of the specimen, red inbox).

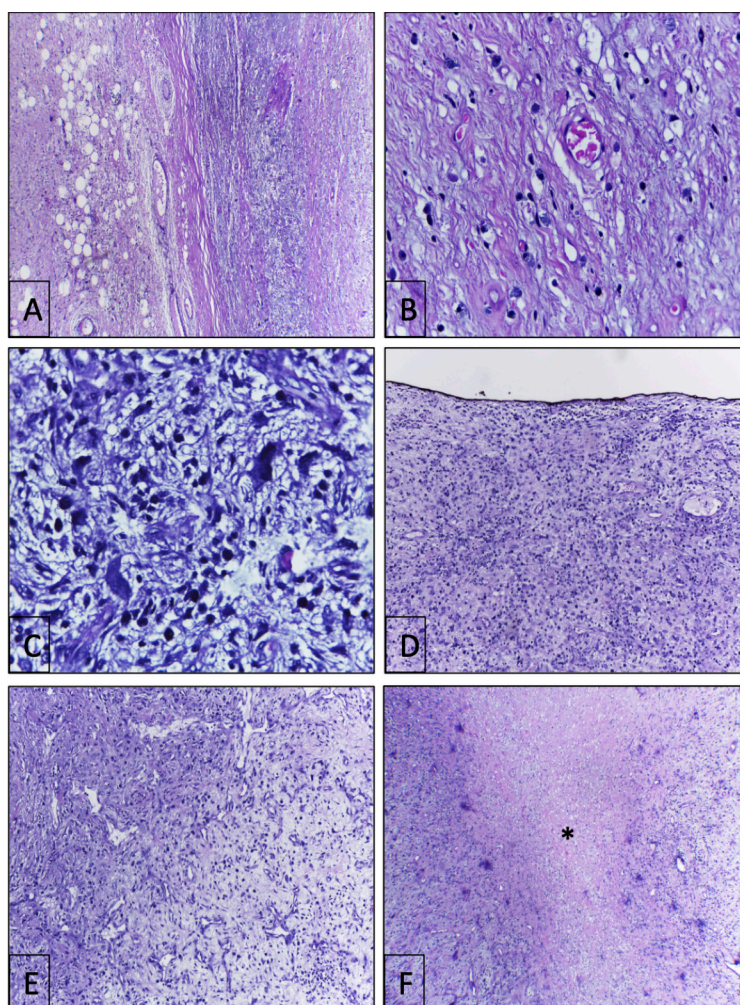


Figure 4 Microscopic findings of the tumour: (A) Tumour composed of well-differentiated component (left side) and high-grade component (right side) separated by a thick collagenous tissue (H&E, $\times 100$). (B) High power views of the well-differentiated element with large atypic nuclei of the fat cells (H&E, $\times 400$). (C) Dedifferentiated element is arranged by pleomorphic bizarre spindle cells (H&E, $\times 400$). (D) Tumour identified at the margin (black ink) (H&E, $\times 100$). (E) Area with numerous vascular channels (H&E, $\times 10$). (F) High-grade component showing a large area of tumour necrosis (asterisk) (H&E, $\times 10$).

Patient's perspective

Perhaps I should start by mentioning that I am myself a surgeon, thus it was quite a surprise that I had had this thing growing inside me and I was oblivious of it. Looking back though, there might have been signs that could be link to this. For the past 2 years I had felt that I tire easily and would experience fatigue more frequently, but I would just push through it. I had made up reasons for being weaker, attributing it to age and my lack of exercise and excessive smoking. I had my tonsils removed just last year, once again thinking that they were the culprit for my deteriorating immune system. Never did I think it was anything more than benign reasons.

Six months prior to this surgery I began to feel numbness and dull pain along my right glut to my right thigh. I had gone to an orthopaedic surgeon thinking it was either a muscle ache or a nerve problem. The surgeon did not find any relevant pathology and recommended physical therapy, which I did. The dull pain was tolerable, but it did not get better. It wasn't long after the ache started that I started noticing changes in my micturition, increased frequency and the sensation of incomplete voiding. I am a 50 years male surgeon, changes in micturition did not surprise me and I took it easy attributing it to benign prostate hypertrophy. Perhaps at some level, I knew the symptoms were related, and perhaps there was more to it. When the LUTS became more severe, I asked a fellow radiologist to peek with an ultrasound. It was after I finished my last surgery for the day and he was still around. He was surprised to see a huge mass compressing the bladder. He had mentioned that my prostate was more than 800 grams and we both were dumbfounded. He persuaded me (not that I needed persuasion) to have an MRI right that moment and we saw the mass clearly.

The COVID-19 infection surprised me more than the mass. I was (and still is) very strict about health safety measures. I had always had my mask on at all times whenever I was in the hospital and I had always had an additional face shield. I spent the exact amount of time needed at work and avoided crowds and other places apart from home and work all together. In fact, I had always been the one tirelessly reminding everyone to be discipline in following the safety protocols. Thus, it was a surprise that I had tested positive for COVID-19. It was like being kick in the gut and slapped on the face at the same time. Who in the world could be this unlucky?

So, I went into self-isolation at home since I was asymptomatic. That was when the pain started to become unbearable and by the second week I woke up and realised I could not urinate. I was more annoyed rather than panicked, I realised it was a process of the disease. I contacted my urologist and got myself into the dedicated COVID-19 ER. That evening they did another PCR swab test on me and it was negative. It was a small relieve. I was prepared for a complete cystoprotatectomy and asked about my urinary diversion options.

I do not fear death, I fear the how. When my time comes, I would like to die doing the thing I love the most, surgery. I imagined closing up a successful surgery and collapsed after placing the last skin closure on the patient. I mentioned this to almost everyone on my surgical team. I was prepared for any morbidity the follows the surgery, but I still want to work and perform surgeries afterwards. I was relieved however, when I woke up and was told that the mass was successfully removed in toto and I did not have to have a urinary bag hanging of my abdomen for the rest of my life.

Continued

Patient's perspective Continued

And just as I thought the ordeal was almost over, I retested positive for COVID-19 and was placed into isolation room. No matter how high spirited and accepting I tried to be, there is a limit for everyone. Still in catabolic state and then placed into isolation did take a toll. It was the support from everyone around me and of course the 2 consecutive negative tests 24 hours after the first one did lift my spirits up. In addition, the PET scan showed a clean resection with no tumour cells detected and no metastatic lesion, perhaps I still have a chance.

This was a major learning moment for me. As surgeons and physicians, we need to always be able to place ourselves in the patient's shoes and this time literally I was wearing them. Although I had always did my best to empathise and spend time to explain the condition and treatment to my patients, I believe there are times that their feelings and fears were dismissed. Casualties of a fast paced and time demanding job. But this whole experience as a patient, undergoing surgery and chemotherapy has widened my horizon once more. I became a part of them, the patients, instead of just being on the other side. I had often answered my patients' questions about chemotherapy with 'I have never undergone it so I could not exactly tell you what it is like but from what my other patients reported this is what it felt like' and 'There is a community of patients with malignancies that undergo chemotherapy, it would be good for you to connect with them and communicate'. Now, I actually could tell them my experience with surgery, recovery and chemotherapy. I hope that this experience makes me into a better surgeon and a better caregiver to my patient.

liposarcoma has never been reported before in the English literature.

Masses in the rectovesical space has no pathognomonic clinical signs and symptoms. Mostly, they are asymptomatic until the mass grows large and compresses adjacent organs. Clinical signs and symptoms are related to those organs, and by the time of diagnosis, the mass would usually be significantly large.^{1 3 4} Our patient had had vague symptoms which could not be pinpointed to one specific area for 2 years, which he had ignored. It was not until he started having dull gluteal aches and LUTS that got worse with time that he sought out medical attention. This delay in medical attention had allowed the tumour to grow in size without any treatment, by which point US revealed a huge extravesical mass compressing the bladder. In combination with LUTS and urinary retention, a pelvic mass on US in a 50-year-old man is most commonly associated with prostatic masses. At first glance, with limited findings, this was thought to be the case in our patient. However, the kontras MRI showed the 9 × 10 × 14 cm pelvic mass detached from the prostate, bladder and rectum.

Primary tumours in the extraperitoneal spaces are most commonly mesenchymal origin, such as soft-tissue sarcomas, of which liposarcoma is the most common subtype.^{1 8 9} Classically, a well-differentiated liposarcoma has high signal intensity on T1 and T2-weighted images on MRI and loses signal intensity on the fat-suppression sequence. In a dedifferentiated type, a sharp demarcation between the lipomatous and non-lipomatous elements could be seen.¹ However, in our case, at the fat suppression sequence, MRI showed no change in the intensity of the tumour at all parts, and no distinguishable borders of fat were seen. This finding led to difficulty in confirming the diagnosis of liposarcoma. The imaging and location indicated

a sarcoma; however, a differential diagnosis of schwannoma was also provided by our radiologist. The histopathology result showed a dedifferentiated liposarcoma where the only lipomatous element found was at the tumour's edge, explaining the puzzling MRI findings.

The five subtypes of liposarcomas are well-differentiated, myxoid, round-cell, pleomorphic and dedifferentiated liposarcoma. Dedifferentiated liposarcoma, commonly found in the retroperitoneum, represents 18% of all liposarcomas. Well and poorly differentiated liposarcoma and non-lipomatous component coexist in dedifferentiated tumours, and histologically, it is considered a high-grade (grade 3) liposarcoma. This characteristic of the lipomatous and non-lipomatous element in one tumour makes histologic diagnosis often time difficult.^{18 9} In our case, almost all of the tumour component was non-lipomatous well-differentiated and high-grade sarcoma with minimal remaining fat component near the capsule. This tumour composition explains the lack of change in intensity at the fat suppression sequence and, on the other hand, aided in confirming the histological diagnosis of dedifferentiated liposarcoma.

Surgical resection is still the primary treatment option for sarcomas, including liposarcoma. A biopsy to confirm the diagnosis and subsequent appropriate neoadjuvant radiotherapy followed by surgical management was planned at first presentation; however, it was sidetracked when the patient was tested positive for COVID-19. Although our patient was asymptomatic for the COVID-19, a multidisciplinary tumour board within the hospital decided to delay the biopsy following the hospital and regional guidelines of elective surgeries in the era of pandemic. Our centre's guide for performing surgeries in confirmed COVID-19 cases follows the national surgery board recommendations, where the thresholds for surgery in COVID-19 pandemic is higher than normal practice: no delays in emergent cases, while elective cases should wait until recovery from COVID-19. Considerations are given to postpone non-urgent procedures in COVID-19 infected patients.¹⁰ Although the pelvic mass was more than 10 cm, a 2-week delay was considered acceptable since the symptoms were still manageable with conservative treatments. Restriction on elective surgeries in patients tested positive COVID-19 serves to protect both the patient and healthcare workers. In addition, his symptoms related to the mass was still manageable at the time and the benefit of delaying the surgery until he was clear of the virus outweighs the risk.

Since our patient had no COVID-19 symptoms, he underwent individual quarantine at his own home and was retested on day 5 and day 10, which were still positive. On the 15th day, the patient came into the Emergency Room (ER) with urinary retention and reported worsening gluteal pain in the past week, to a VAS level of 8, even with pain killers. A urinary catheter was inserted for diversion, and a repeat PCR swab was taken. The PCR test was negative, and another test was done the next day, which was also negative. The MRI results showed no tumour infiltrations to surrounding organs, a surgery to remove the mass in toto was planned without a biopsy and neoadjuvant radiotherapy. The rationale for not waiting for biopsy result was that this tumour was suspected as a mesenchymal origin from the beginning. Thus, biopsy nor frozen section have a limited role in confirming the diagnosis of tumour histological subtype. In addition, the patient had become symptomatic in a short time, owing to a decision of prompt surgical resection without neoadjuvant radiotherapy beforehand. The surgical approach would have remained the same, with or without the biopsy.

In this pandemic, where there is a shortage of resources in certain areas, and the risk of infection is high, cancer patients' management and prioritisation had been reviewed. Soft-tissue sarcomas that need surgery should be prioritised, especially in symptomatic, non-low-grade sarcomas. Low-grade sarcomas with known indolent behaviours such as extraperitoneal well-differentiated sarcomas could be deferred for a short time, provided it was asymptomatic.^{11 12} Since our patient became symptomatic, we proceeded with caution, although the patient had just recovered from COVID-19 infection.

In a recent publication that first reported the outcomes of surgery in COVID-19 infected patients, Lie *et al* reported a much higher need for intensive care unit (44.1%) and higher mortality rate (20.5%) in COVID-19 infected patients that underwent surgeries than in those who did not undergo surgeries. Surgery may accelerate and exacerbate symptoms of COVID-19 and the course of the disease.¹³ This was seen in our patient when a repeat PCR test was positive during the postoperative period. However, the cycling threshold value was relatively high at that time, and two consecutive repeat tests 48 hours after that were negative, leading us to believe that it might not have been reinfection but rather a reactivation, which can happen in an immunosuppressive condition that impairs viral clearance.¹⁴

Dedifferentiated liposarcoma has a higher risk of recurrence, and distant metastasis has a worse prognosis than other subtypes. In one of the most extensive studies of dedifferentiated liposarcoma prognostic factors, Gootee *et al* reported increased age, male gender, retroperitoneal site and tumour ≥ 10 cm, high-grade histological type and the presence of distant metastasis are associated with poorer prognosis. The incidence of metastases has been reported between 15% and 30%, with lungs as the most common site.⁸

Almost all of the risk factors mentioned above are present in our case: male gender, 50 years old, tumour size ≥ 10 cm, extra-peritoneal site and high-grade tumour, thus a complete PET-scan was scheduled, although after surgery. Although sarcomas are not chemotherapy sensitive, some studies reported good outcomes with chemoradiation adjuvant therapy. We planned for adjuvant chemoradiation therapy for our patients.

Learning points

- ▶ Retrovesical dedifferentiated liposarcoma is a rare occurrence and considered a high-grade liposarcoma.
- ▶ Due to its composition, MRI of dedifferentiated liposarcoma does not show change of intensity in fat suppression sequence leading difficulty in diagnosis.
- ▶ Histopathology of dedifferentiated liposarcoma shows well and poorly differentiated liposarcoma and non-lipomatous component coexisting in one tumour.
- ▶ Although surgery may exacerbate the disease's progress in a COVID-19 patient, surgical resection of high-grade sarcoma with symptoms should be prioritised and performed as soon as the infection tested negative.

Contributors AN: Conceived and designed the report, collected the data, contributed data and wrote the paper. IJ: Collected the data and wrote the paper. NR: Conceived and designed the report, collected the data, contributed data. RSWM: Collected the data, contributed data

Funding The authors have not declared a specific grant for this research from any funding agency in the public, commercial or not-for-profit sectors.

Competing interests None declared.

Patient consent for publication Obtained.

Provenance and peer review Not commissioned; externally peer reviewed.

This article is made freely available for use in accordance with BMJ's website terms and conditions for the duration of the covid-19 pandemic or until otherwise determined by BMJ. You may use, download and print the article for any lawful, non-commercial purpose (including text and data mining) provided that all copyright notices and trade marks are retained.

ORCID iDs

Indah Jamtani <http://orcid.org/0000-0002-4809-0063>

Adianto Nugroho <http://orcid.org/0000-0001-9066-8685>

Nur Rahadiani <http://orcid.org/0000-0003-2342-8133>

REFERENCES

- 1 Levy AD, Manning MA, Al-Refaie WB, *et al.* Soft-Tissue sarcomas of the abdomen and pelvis: Radiologic-Pathologic features, part 1-Common sarcomas: from the radiologic pathology Archives. *Radiographics* 2017;37:462–83.
- 2 Pathak S, Soni TP, Gupta AK, *et al.* Retrovesical malignant fibrous histiocytoma: a rare tumor. *BMJ Case Rep* 2017;2017:222612. doi:10.1136/bcr-2017-222612
- 3 Kil MC, Cho BS, Han GS, *et al.* Synovial sarcoma in the rectovesical space: a case report. *J Korean Soc Radiol* 2011;65:167–70.
- 4 Dahms SE, Hohenfellner M, Linn JF, *et al.* Retrovesical mass in men: pitfalls of differential diagnosis. *J Urol* 1999;161:1244–8.
- 5 Das S, Newell MB. Retrovesical liposarcoma. *Br J Urol* 1980;52:163.
- 6 Edson M, Friedman J, Richardson JF. Perivesical liposarcoma: a case report. *Journal of Urology* 1961;85:767–70.
- 7 Polsky MS, Vitenson JH, Wilson JM, *et al.* Retrovesical liposarcoma. *Urology* 1974;3:226–8.
- 8 Gootee J, Aurit S, Curtin C, *et al.* Primary anatomical site, adjuvant therapy, and other prognostic variables for dedifferentiated liposarcoma. *J Cancer Res Clin Oncol* 2019;145:181–92.
- 9 Kim E-S, Jang S-H, Park H-C, *et al.* Dedifferentiated liposarcoma of the retroperitoneum. *Cancer Res Treat* 2010;42:57–60.
- 10 Nugroho A, Arifin F, Wibowo AA, *et al.* Delivery of digestive surgery services during the COVID-19 pandemic: Indonesian Society of digestive surgeons online survey. *Asian J Endosc Surg* 2021. doi:10.1111/ases.12913. [Epub ahead of print: 05 Jan 2021].
- 11 Bartlett DL, Howe JR, Chang G, *et al.* Management of cancer surgery cases during the COVID-19 pandemic: considerations. *Ann Surg Oncol* 2020;27:1717–20.
- 12 Kutikov A, Weinberg DS, Edelman MJ, *et al.* A war on two fronts: cancer care in the time of COVID-19. *Ann Intern Med* 2020;172:756–8.
- 13 Lei S, Jiang F, Su W, *et al.* Clinical characteristics and outcomes of patients undergoing surgeries during the incubation period of COVID-19 infection. *EClinicalMedicine* 2020;21:100331.
- 14 Gousseff M, Penot P, Gallay L. Clinical recurrences of COVID-19 symptoms after recovery: viral relapse. *reinfection or inflammatory rebound?* *J Infect* 2020.

Copyright 2021 BMJ Publishing Group. All rights reserved. For permission to reuse any of this content visit <https://www.bmj.com/company/products-services/rights-and-licensing/permissions/>
BMJ Case Report Fellows may re-use this article for personal use and teaching without any further permission.

Become a Fellow of BMJ Case Reports today and you can:

- ▶ Submit as many cases as you like
- ▶ Enjoy fast sympathetic peer review and rapid publication of accepted articles
- ▶ Access all the published articles
- ▶ Re-use any of the published material for personal use and teaching without further permission

Customer Service

If you have any further queries about your subscription, please contact our customer services team on +44 (0) 207111 1105 or via email at support@bmj.com.

Visit casereports.bmj.com for more articles like this and to become a Fellow