

Collagenopathies—Implications for Abdominal Wall Reconstruction: A Systematic Review

Bridget Harrison, MD*
 Kyle Sanniec, MD*
 Jeffrey E. Janis, MD, FACS†

Background: The etiology of hernia formation is strongly debated and includes mechanical strain, prior surgical intervention, abnormal embryologic development, and increased intraabdominal pressure. Although the most common inciting cause in ventral hernias is previous abdominal surgery, many other factors contribute. We explore this etiology through an examination of the current literature and existing evidence on patients with collagen vascular diseases, such as Ehlers–Danlos syndrome.

Methods: A systematic review of the published literature was performed of all available Spanish and English language PubMed and Cochrane articles containing the key words “collagenopathies,” “collagenopathy,” “Ehlers–Danlos,” “ventral hernia,” and “hernia.”

Results: Three hundred fifty-two articles were identified in the preliminary search. After review, 61 articles were included in the final review.

Conclusions: Multiple authors suggest a qualitative or quantitative defect in collagen formation as a common factor in hernia formation. High-level clinical data clearly linking collagenopathies and hernia formation are lacking. However, a trend in pathologic studies suggests a link between abnormal collagen production and/or processing that is likely associated with hernia development. (*Plast Reconstr Surg Glob Open* 2016;4:e1036; doi: 10.1097/GOX.0000000000001036; Published online 24 October 2016.)

Hernia etiology has been attributed to a miscellany of causes including mechanical strain, prior surgical intervention, abnormal embryologic development, and increased intraabdominal pressure. Whereas the most common inciting cause in ventral hernias is previous abdominal surgery, with an incidence between 3% and 11% after laparotomy procedures,^{1,2} other factors associated with the development of abdominal wall hernias include wound infections,³ increasing age, obesity,⁴ and method of wound closure.⁵ Clearly, the pathophysiology of hernia development is multifactorial, as some indirect hernias do not develop until late in life and not all patients with laparotomy develop hernias after laparotomy. To identify the biologic culprit of hernia formation, multiple authors have suggested a qualitative or quantitative defect in collagen formation

as a common factor. We explore this etiology through an examination of the histopathologic evidence and evaluation of patients with collagen vascular diseases, such as Ehlers–Danlos syndrome and Marfan’s syndrome (Fig. 1).

BACKGROUND

Ehlers–Danlos syndrome is an inherited disorder of connective tissue that has been divided into six types, based on the defect in collagen metabolism.⁶ Named for Henri-Alexandre Danlos and Edvard Ehlers’ 1908 description of the disease, this syndrome is generally associated with skin hyperextensibility, joint laxity, and tissue fragility. Genetic defects have been identified in type I collagen, type III collagen, type V collagen, and lysyl hydroxylase, with variable phenotypic results. In addition to an increase in general surgical complications, such as wound dehiscence, poor scarring, and intra- or postoperative bleeding,^{7,8} patients purportedly also have an increase in inguinal hernias and recurrent ventral hernias.

Whereas Marfan’s syndrome is not defined by defects in collagen synthesis, a mutation in fibrillin in these patients results in abnormalities in the extracellular matrix

From the *Department of Plastic Surgery, University of Texas Southwestern, Dallas, Tex; and †Department of Plastic Surgery, Ohio State University Medical Center, Columbus, Ohio.

Received for publication December 30, 2015; accepted July 26, 2016.

Copyright © 2016 The Authors. Published by Wolters Kluwer Health, Inc. on behalf of The American Society of Plastic Surgeons. All rights reserved. This is an open-access article distributed under the terms of the Creative Commons Attribution-Non Commercial-No Derivatives License 4.0 (CCBY-NC-ND), where it is permissible to download and share the work provided it is properly cited. The work cannot be changed in any way or used commercially.

DOI: 10.1097/GOX.0000000000001036

Disclosure: Jeffrey Janis is a consultant for LifeCell and has received a one-time honorarium for consulting with Bard, Pacira, and KCI. Neither of the other authors has any financial disclosures. The Article Processing Charge was paid for by Jeffrey Janis, MD.

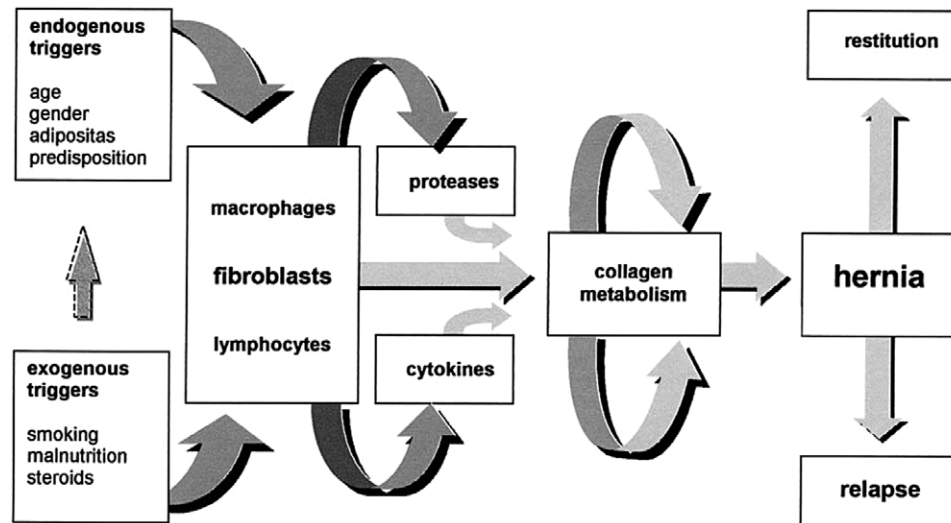


Fig. 1. Pathogenesis of hernia formation. Reprinted with permission from *Surgery* 2004;136:1–4.

and connective tissues. Common phenotypic abnormalities include dolichostenomelia, arachnodactyly, scoliosis, and joint flexibility.⁹ Marfan's syndrome can also result in aortic or mitral prolapse, aortic dissection, spontaneous pneumothorax, and early cataracts or glaucoma. To better understand disorders of collagen production, organization, and degradation, it is paramount to briefly review relevant normal processes before discussing the abnormal processes. Produced by fibroblasts, collagen is the most abundant mammalian protein and the principal component of connective tissue. Its production requires a complex series of steps involving multiple enzymes and cellular organelles to reach a final product. Each of these steps is complex, and any defect in this process can lead to subpar collagen production, which given the multitude of tissues that collagen is present in can lead to many clinical manifestations.

In addition to its production for normal tissue maintenance and turnover, collagen plays a principal role in wound healing. This process is particularly relevant in the healing of postsurgical wounds and signals a potential causative factor in the development of incisional hernias. In response to platelet derived growth factor and other growth factors, fibroblasts begin the synthesis of a provisional matrix composed of type III collagen and glycosaminoglycans.¹⁰ Although collagen in uninjured skin is 80–90% type I and 10–20% type III, initial fibroblast production is preferentially skewed toward type III collagen.¹¹ This type of collagen is critical during the initial wound healing period to allow for colocalization and proper fibrillogenesis to the more common type I collagen.¹²

METHODS

A systematic literature review was performed of the PubMed and Cochrane databases. Article selection was limited to English and Spanish language articles published between January 1, 1946 and June 1, 2014. Abstracts were reviewed by B.H. and K.S. and articles were

reviewed in full if there was any question about meeting inclusion criteria. Inclusion criteria consisted of all articles that discussed the relationship between abdominal wall hernias and quantitative or qualitative abnormalities in collagen. Exclusion criteria included articles that discussed only collagen disorders or only hernias, or only mentioned a possible correspondence between hernias and collagenopathies. Articles that reviewed symptoms of collagenopathies but did not discuss hernias were also excluded. Our initial search terms included “hernia” or “hernia, abdominal” or “hernia, inguinal” or “hernia, ventral” or “hernia, umbilical” or “gastroschisis” or “hernia, femoral” or “hernia, diaphragmatic” or “hernia, diaphragmatic, traumatic” or “hernia, hiatal” or “herniorrhaphy” or “collagen diseases” or “Ehlers–Danlos syndrome” or “cutis laxa” or “marfan syndrome” or “collagenopathy” or “collagen defect” or “collagen type VI” or “collagen type VIII” or “collagen type II” or “collagen type VII” or “collagen type IX” or “collagen type I” or “collagen type” or “collagen type III” or “collagen type V” or “collagen type IV” or “fibrillar collagens” or “collagen”. Despite their potential bias, case reports and animal studies were included due to the limited number of clinical studies thus far available.

SEARCH RESULTS

Our initial search returned 352 published articles. After exclusion criteria were applied, 59 articles were included in the initial review. These articles were reviewed in their entirety by B.H. and K.S. to ensure relevant content for inclusion. Articles not returned in the initial search but with relevant citations in the included articles were also studied for content. A total of 61 articles met all inclusion (Fig. 2). Articles include 1 case-control study, 3 case reports, 37 prospective studies, 5 retrospective studies, 7 reviews, and 5 systematic reviews. Three of the articles were animal studies. The remainder were human studies (Table 1). The variability in outcomes reported does not

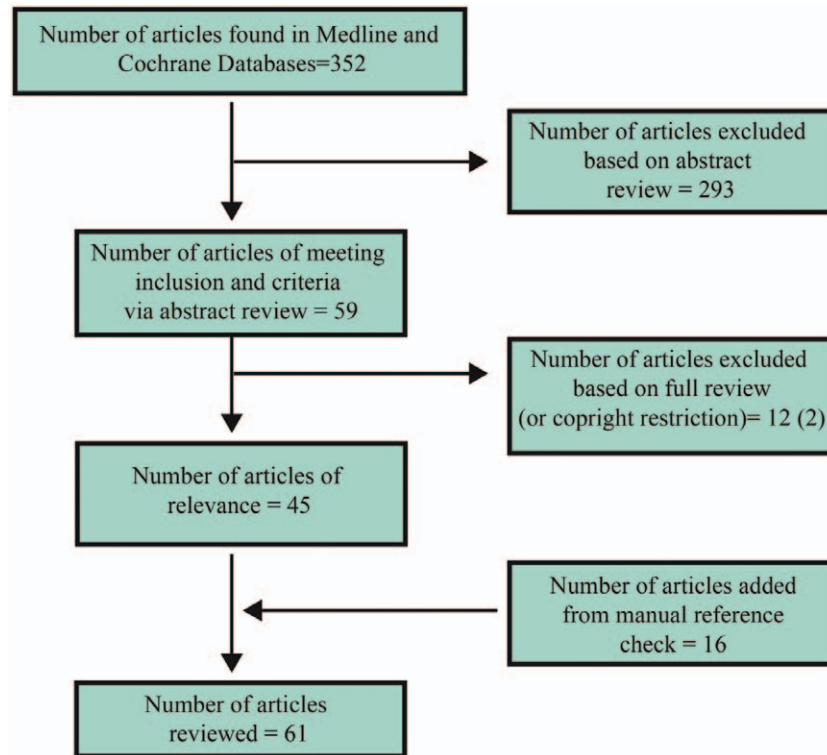


Fig. 2. Identification of studies in the primary literature review.

allow for quantitative analysis, and qualitative comparisons were drawn.

EVIDENCE FOR COLLAGENOPATHIES IN HERNIAS

Inguinal

Reports of hernia formation in patients with collagen vascular diseases suggest a plausible association between abnormal collagen content or structure and the presence of abdominal wall herniation. In patients with direct inguinal hernias, Wagh et al¹³ found that the anterior rectus sheath above the defect is thinner than normal, accounted for by a decrease in hydroxyproline (by 19.2%) and therefore collagen. This may be attributed to a decrease in proliferation of fibroblasts, as shown by culture of fibroblasts taken from the anterior rectus sheath. Collagen values for indirect hernias fell between control levels and patients with direct defects, and the same investigator concluded that adult hernias can be attributed to reduced collagen synthesis by fibroblasts.¹⁴ Perhaps as a consequence of the altered proline ratio and hydroxylation defect, a marked variation in the diameter of fibrils from patients with direct hernia was observed.

Studies performed on the transversalis fascia of patients with hernia have supported abnormalities in collagen content. Conner and Peacock found that combining the effect of chemically induced lathyrism and injury to the internal ring produced progressive enlargement of the ring and herniation in rats. In contrast, isolated lathyrism

or anatomic injury alone did not reliably produce inguinal herniation. This suggests that if even a small anatomic defect exists, a crosslinking deficiency will predispose the patient to inguinal herniation.¹⁵ In a more recent evaluation of human transversalis fascia, its extensibility and elasticity were also significantly increased in patients with direct hernias. This was true in samples from the nonherniated sides as well, suggesting a preclinical pathologic state.¹⁶

Casanova et al¹⁷ found 17.3% less total and 23.7% less type I collagen in the transversalis fascia of patients with indirect inguinal hernias. Reduced collagen and elastin were also found in rectus sheath and peritoneal samples from patients with direct and indirect hernia.¹⁸ The authors suggest that this finding reflects a more generalized, or at least regional, connective tissue disorder.

As detailed above, type III collagen also plays a role in the formation of a regular, repetitive array of fibrils in a normal extracellular matrix. In addition to possible defects in hydroxylation and modification of collagen in patients with hernia, some authors have identified an increase in type III collagen synthesis.¹⁹⁻²¹ A case-control study of 27 patients with inguinal hernia and 24 controls by Meyer et al²² showed a relative increase in the quantity of type III collagen in patients with hernia. This increase in patients with hernia may contribute to irregular synthesis of type I collagen fibrils. As type III collagen is also considered to be the thinner, more immature form of collagen, offering less tensile strength than type I collagen, this altered ratio could theoretically contribute to weakness of fascial or aponeurotic tissues. When this ratio is

Table 1. Systematic Review Articles

Article Title	Year	Animal/Human	No. Subjects	Study Type
Heritable disorders of connective tissue: surgical and anesthetic problems	1967	Human	68	Retrospective
Gastrointestinal complications of the Ehlers-Danlos syndrome	1969	Human	125	Retrospective
Surgical aspects of the Ehlers-Danlos syndrome. A survey of 100 cases	1969	Human	100	Retrospective
Defective collagen synthesis in inguinal herniation	1972	Human	15	Prospective
Some studies on the etiology of inguinal hernia	1973	Animal	108	Prospective
Direct inguinal herniation in men: a disease of collagen	1974	Human	15	Prospective
Defects in the biochemistry of collagen in diseases of connective tissue	1976	Human		Review
Surgical complications of Ehlers-Danlos syndrome in children	1977	Human	0	Review
Defective collagen metabolism in Saudi patients with hernia	1992	Human	151	Prospective
Increases in type III collagen gene expression and protein synthesis in patients with inguinal hernias	1995	Human	24	Prospective
Study of biochemical substrate and role of metalloproteinases in fascia transversalis from hernial processes	1997	Human	36	Prospective
Adult groin hernias: new insight into their biomechanical characteristics	1997	Human	93	Prospective
Increased risk for inguinal hernia in patients with Ehlers-Danlos syndrome	1997	Human	130	Prospective
Hiatus/paraesophageal hernias in neonatal Marfan syndrome	1997	Human	1	Case report
Etiology and pathophysiology of primary and recurrent groin hernia formation	1998	Human		Review
Ehlers-Danlos syndromes: revised nosology, Villefranche, 1997. Ehlers-Danlos National Foundation (USA) and Ehlers-Danlos Support Group (UK)	1998	Human		Review
Expression of the extracellular matrix proteins collagen I, collagen III and fibronectin and matrix metalloproteinase-1 and -13 in the skin of patients with inguinal hernia	1999	Human	23	Prospective
Synthesis of type I and III collagen, expression of fibronectin and matrix metalloproteinases-1 and -13 in hernial sac of patients with inguinal hernia	1999	Human	23	Prospective
Abnormal collagen I to III distribution in the skin of patients with incisional hernia	2000	Human	26	Prospective
Recurrent ventral herniation in Ehlers-Danlos syndrome	2000	Human	20	Retrospective
Collagen I/III and matrix metalloproteinases (MMP) 1 and 13 in the fascia of patients with incisional hernias	2001	Human	26	Prospective
Biochemical study of collagen in adult groin hernias	2001	Human	60	Prospective
Fibroblasts from the transversalis fascia of young patients with direct inguinal hernias show constitutive MMP-2 overexpression	2001	Human	78	Prospective
Biomechanical and morphological types of the linea alba and its possible role in the pathogenesis of midline incisional hernia	2001	Human	93	Prospective
Impaired balance of type I and type III procollagen mRNA in cultured fibroblasts of patients with incisional hernia	2002	Human	22	Prospective
Quantitative analysis of collagen and elastic fibers in the transversalis fascia in direct and indirect inguinal hernia	2002	Human	57	Prospective
Recurrent inguinal hernia: disease of the collagen matrix?	2002	Human	10	Prospective
Analysis of collagen-interacting proteins in patients with incisional hernias	2003	Human	25	Prospective
Inguinal herniation in the adult, defect or disease: a surgeon's odyssey	2004	Human		Review
The biology of hernia formation	2004	Human		Review
Decreased collagen type I/III ratio in patients with recurring hernia after implantation of alloplastic prostheses	2004	Human	78	Prospective
Precoating of alloplastic materials with living human fibroblasts—a feasibility study	2005	Human		Prospective
Prenatal diagnosis of intrathoracic stomach (gastric herniation)	2005	Human	1	Case report
The biology of hernias and the abdominal wall	2006	Human		Review
Impact of collagen subtype proportions in peritoneal tissues on inguinal hernia formation in adults and infants	2006	Human	18	Prospective
Changes in collagen and elastic fiber contents of the skin, rectus sheath, transversalis fascia and peritoneum in primary inguinal hernia patients	2006	Human	29	Prospective
Abnormal primary tissue collagen composition in the skin of recurrent incisional hernia patients	2007	Human	23	Prospective
Quantitative and qualitative analysis of collagen types in the fascia transversalis of inguinal hernia patients	2007	Human	27	Prospective
Qualitative and quantitative evaluation of total and types I and III collagens in patients with ventral hernias	2007	Human	26	Prospective
Role of biomarkers in incisional hernias	2007	Human	24	Prospective
Postoperative incision hernia in patients with abdominal aortic aneurysm and aortoiliac occlusive disease: a systematic review	2007	Human	1132	Systematic review
Matrix mechanical properties of transversalis fascia in inguinal herniation as a model for tissue expansion	2008	Animal		Experimental
Analysis of c-myc, PAI-1 and uPAR in patients with incisional hernias	2008	Human		Prospective
Fibrillin-1 in incisional hernias: an immunohistochemical study in scar and non-scar regions of human skin and muscle fasciae	2008	Human	22	Prospective
Degradation of collagen by metalloproteinase 2 in patients with abdominal hernias	2009	Human	90	Prospective
Looking past the lump: genetic aspects of inguinal hernia in children	2009	Human		Systematic review
Collagen in the transversalis fascia of patients with indirect inguinal hernia: a case-control study	2009	Human	26	Case control

(Continued)

Table 1. (Continued)

Article Title	Year	Animal/Human	No. Subjects	Study Type
The role of matrix metalloproteinases in the pathogenesis of abdominal wall hernias	2009	Human		Review
Expression in SPARC-null mice of collagen type I lacking the globular domain of the alpha1(I) N-propeptide results in abdominal hernias and loss of dermal collagen	2010	Animal	12	Experimental
Serum MMP 2 and TIMP 2 in patients with inguinal hernias	2011	Human	180	Prospective
The ultrastructural differences in rectus sheath of hernia patients and healthy controls	2011	Human	10	Prospective
Collagen type I:III ratio of the gastroesophageal junction in patients with paraesophageal hernias	2011	Human	30	Prospective
The value of copper and zinc levels in hernia formation	2011	Human	58	Prospective
Connective tissue alteration in abdominal wall hernia	2011	Human		Systematic review
Elastic fibers in the anterior abdominal wall	2011	Human	30	Prospective
Abdominal aortic aneurysm and abdominal wall hernia as manifestations of a connective tissue disorder	2011	Human		Systematic review
Ultrastructural differences in rectus sheath of hernia pts and healthy controls	2011	Human	10	Prospective
A large abdominal intercostal hernia in a patient with vascular type Ehlers–Danlos syndrome: a surgical challenge	2012	Human	1	Case report
Surgical failures: is it the surgeon or the patient? The all too often missed diagnosis of Ehlers–Danlos syndrome	2013	Human	25	Retrospective
The inheritance of groin hernia: a systematic review	2013	Human	37,166	Systematic review
Incisional hernia recurrence through genomic profiling: a pilot study	2013	Human	33	Prospective

compared between direct and indirect hernias, no significant difference was found, suggesting a common collagen abnormality in their development.²³ However, Pans et al²⁴ identified no qualitative difference in type I:III collagen ratios between control subjects and patients with hernia.

Ventral Hernias

Ventral hernia formation has also been linked with abnormal collagen synthesis. Reduced collagen synthesis may be directly related to the function of the N-propeptide of collagen I. Twenty percent of mice with deletions encoding this sequence developed abdominal hernias within the first 2 months of life and were found to have thin dermis with fewer large collagen fibers. Fachinelli and Maciel Trindade²⁵ found 20.5% less type I and 18.5% less total collagen content in the linea alba of patients with ventral hernia.

Pathologic changes may not be solely attributed to pathologic collagen fibers, but also to the role of elastic fibers. In an immunohistochemical analysis of the linea alba from patients with abdominal wall hernia, investigators suggested an inverse relationship between the quantity of collagen and elastic fibers. In a combination of epigastric, incisional, and umbilical hernias, the amount of elastin was significantly increased although the structure of the elastic fibers was altered, demonstrating a fragmented, thickened shape in patients with ventral hernia.²⁶

Combined Evidence in Different Etiologies

An analysis of 12 patients with recurrent incisional hernias and 11 control subjects without any history of hernia confirmed a decreased collagen I/III ratio in the skin of patients with hernia (0.88 versus 0.98), but this was not observed in fascial biopsies.²⁷ Multiple studies have shown decreased collagen I/III ratios in mature skin scars from patients with either primary or recurrent incisional hernias compared with mature abdominal skin scars from patients without hernias^{23, 28–31} and in periprosthetic scar of recurrent inguinal and incisional hernias.³² A common

link between all hernias has been found by some studies including differing etiologies. Ozdemir et al³³ included indirect, direct, and incisional hernias in their evaluation of copper and zinc levels. Because some of the enzymes responsible for collagen production and processing require the presence of zinc and copper for proper function, deficiencies in these minerals have been proposed as a contributing factor to hernia formation. Lower tissue levels of copper and zinc were found in all examined hernias, despite having similar plasma levels. The authors suggest a possible dysfunction or excessive consumption of lysyl oxidase as the underlying etiology.³³ This opens a possible role for supplementation of these minerals in postoperative patients, although such intervention has not been proven.

The relative influence of these biologic abnormalities to direct, indirect, or incisional hernias is not currently clear. Although current data tend to support an inherent defect in collagen metabolism and structure, it is not evident that this plays an equivalent role among all hernia etiologies. A 2011 review of 52 papers found more pronounced changes in patients with direct inguinal hernias than in indirect, recurrent, or incisional hernias.³⁴ However, these authors report a consistent increase in immature type III collagen relative to type I collagen, a finding which was not universally found in our review. How these changes result in hernia development is also not well-defined, as a biomechanical study of the transversalis fascia found no significant difference between break stress, strain, or modulus in herniated or nonherniated fascia.³⁵ Neither were significant differences found in average collagen fibril diameter or density.

HERNIAS AND COLLAGEN VASCULAR DISEASE

Numerous defects in collagen synthesis or degradation have been associated with clinical disease (Table 1) and

lend support to primary collagen dysfunction as a fundamental factor in hernia formation.

Ehlers–Danlos Syndrome

Due to the variable manifestations and difficult clinical diagnosis of Ehlers–Danlos syndrome, there are relatively few analyses of the exact incidence of herniation in this population. However, a 1997 survey of 130 affected patients in the Netherlands identified a crude rate ratio of inguinal herniation of 2.5.³⁶ Among 100 patients with Ehlers–Danlos syndrome surveyed in 1969, 11 reported having had an inguinal hernia repair. However, this report did not offer a control group for reference.⁷ A more recent retrospective chart review of patients presenting for recurrent abdominal wall herniation at a tertiary institution found a 10% incidence rate, which was much higher than what the authors expected.³⁷ The literature is otherwise peppered with case reports of large and difficult hernias,³⁸ but does not allow for the evaluation of the case prevalence within the context of this patient population.

Patients with vascular Ehlers–Danlos syndrome have a high incidence of abdominal aortic aneurysms (AAAs), a pathologic dilation of the abdominal aorta also tied to abnormalities in connective tissue. The general population of patients with AAAs is also at high risk for abdominal wall herniation and offers a more easily studied group due to the disease's prevalence. When comparing patients having aortic reconstruction for aortoiliac occlusive disease versus patients with AAAs, studies report postoperative incisional hernias in 10% to 37% of patients with AAAs versus 3% to 19% patients having aortic reconstruction for aortoiliac occlusive disease.³⁹ A meta-analysis of postoperative incisional hernia patients with AAA and aortoiliac occlusive disease undergoing abdominal aortic reconstruction also noted a nearly 3-fold increased risk of postoperative incisional hernia in patients with AAA. They also reported a 3-fold increased risk of inguinal hernia.⁴⁰ Like hernias, aortic aneurysms have been associated with increased activity of matrix metalloproteinase (MMP)-1 and MMP-13.⁴¹ A similar aberration in type III collagen synthesis and turnover has also been observed in the pathogenesis of AAA.⁴²

Repair in collagenopathies is similar to standard hernia repair. In their description of ventral hernia repair in two patients with Ehlers–Danlos syndrome, Grotto et al³⁷ utilized the components separation technique with a polypropylene (Marlex, Bard Davol, R.I.) mesh overlay. Neither patient experienced a recurrence at the time of their publication, but the duration of follow-up is not specified. Based on their level IV evidence, the authors proposed the use of polypropylene in these patients to reduce incidence of wound failure and hernia recurrence by generating additional fibrosis.

Marfan's Syndrome

Data on the incidence of hernias in patients with Marfan's syndrome are lacking, but case reports indicate a higher occurrence of herniation at uncommon sites. Examples of these rarities include intrathoracic stomach (gastric herniation)⁴³ and neonatal hiatal/para-

esophageal hernias.⁴⁴ A review of patients with Marfan's syndrome who underwent aortic aneurysm repair over 26 years revealed a 32% incidence of inguinal hernia.⁴⁵ Other reports vary from 22% to 42%.^{46,47} Slight differences in the pattern of fibrillin-1 deposition in tissue samples from skin and fascia in non-Marfan incisional hernia patients has been observed, but these differences were hardly quantifiable.⁴⁸ Future studies on this limited population will help to clarify the impact of other connective tissue diseases on abdominal wall herniation.

TREATMENT OPTIONS

Despite advances in surgical technique and available surgical adjuncts, such as prosthetic and biologic meshes, surgeons continue to battle with patients who present with recurrent herniation. Optimal repair is even more important in this population of patients with known collagen vascular disease that are inherently set up for higher rates of recurrence.

Newer biologic meshes offer the theoretic advantage of providing a framework on which matrix remodeling and collagen deposition may occur. The data on biologic mesh are still highly debated, and the effect of various processing methods and crosslinking agents may affect the body's response to these materials.⁴⁹ Even with sturdy biology or synthetic support, each interface of fixation requires healing. Although mechanically durable and infection resistant *in vitro*, a biologic mesh placed *in vivo* in a patient population with established abnormalities in collagen deposition and remodeling may generate an altered, suboptimal, or distinct response from that observed in laboratory studies.

A potential target for future exploration is the precoated synthetic material, which incorporates the advantages of synthetic mesh with a fibroblast coating. Although the authors of a 2005 feasibility study suggest a potential decrease in adhesions and fistulas with this material,⁵⁰ their reports of increased type I collagen expression and a low rate of type III collagen production offer an additional advantage in the collagen-deficient abdominal hernia. Other biomaterials are still in development, such as fibroblast-seeded polyglycolic acid scaffolds⁵¹ and mesenchymal stem cell-seeded scaffolds.⁵² Theoretically, introducing the biologic components necessary for normal collagen production and remodeling would offer the best chance at hernia repair and prevention of recurrence. Unfortunately, these specialized advances in tissue engineering have yet to reach the human stages of evaluation and lack evaluation even in uncomplicated patients with hernia.

Additional screening of MMP expression and blood levels might further stratify patients and allow for selection of patients who might benefit from additional technologies. Given the MMP abnormalities described in patients with hernia, such technologies may include administration of MMP inhibitors. This has been evaluated in patients with AAAs,⁵³ cancer,⁵⁴ and arthritis,⁵⁵ but no studies have been performed on patients with hernia. There are several types of pharmacological MMP inhibitors, the most common of which are tetracycline derivatives. Doxycycline is a nonspecific MMP inhibitor and can

be prescribed at low, subantibiotic doses, which limits unwanted side effects. Thus far, however, the use of these drugs is experimental and data are lacking. Genetic profiling is also potentially beneficial for risk stratification, given known abnormalities in collagen gene expression.⁵⁶ However, these developments are far from clinical use.

Until that time when defective fibroblasts and inherited enzyme abnormalities can be replaced with genetic or tissue engineering, the surgeon should optimize repair with available mesh and local tissue and apprise the patient on all inherent risks. Given the above information, patients with hernia, and especially those with inherited collagen vascular disease, likely have altered collagen production and processing, predisposing these patients to a high risk of recurrence. By explaining the biologic defect involved in hernia formation, the patient may be more understanding of this risk. That said, successful repair is possible, even without genetic tests and enzyme alteration, and with proper informed consent, the prepared surgeon can offer mechanical optimization of a complex biomechanical disease.

LIMITATIONS

The inclusion of all hernias, including incisional, ventral, and inguinal, in this review introduces multiple etiologies which may complicate a clear distinction as to a common pathophysiology in collagen formation. Variable stages in healing between multiply operated patients and a primary hernia will also confound collagen formation. In addition, although we included animal studies for completion, their findings may not be universally applicable to humans. The small number of publications on hernias in patients with diagnosed collagen vascular disorders also limits conclusions about outcomes and complications in these patients.

CONCLUSIONS

High-level clinical data clearly explaining the link between collagenopathies and hernia formation are lacking. However, there is a trend in pathologic studies suggesting a link between abnormal collagen production and/or processing that at least plays a role in the development of direct, indirect, and ventral hernias. The contribution of these abnormalities in reference to different anatomic locations and patient populations is variable, but will be important for patient education and continued investigation into therapeutic modalities.

Jeffrey E. Janis, MD, FACS

Department of Plastic Surgery
Ohio State University Medical Center
915 Olentangy River Road, Suite 2100, Room 2119
Columbus, OH 43212
E-mail: Jeffrey.Janis@osumc.edu

REFERENCES

1. Le Huu Nho R, Mege D, Ouaiissi M, et al. Incidence and prevention of ventral incisional hernia. *J Visc Surg*. 2012;149 (5 Suppl):e3-14.
2. Santora TA, Roslyn JJ. Incisional hernia. *Surg Clin North Am*. 1993;73:557-570.
3. Song IH, Ha HK, Choi SG, et al. Analysis of risk factors for the development of incisional and parastomal hernias in patients after colorectal surgery. *J Korean Soc Coloproctol*. 2012;28:299-303.
4. Lau B, Kim H, Haigh PI, et al. Obesity increases the odds of acquiring and incarcerating noninguinal abdominal wall hernias. *Am Surg*. 2012;78:1118-1121.
5. Hodgson NC, Malthaner RA, Ostbye T. The search for an ideal method of abdominal fascial closure: a meta-analysis. *Ann Surg*. 2000;231:436-442.
6. Beighton P, De Paepe A, Steinmann B, et al. Ehlers-Danlos syndromes: revised nosology, Villefranche, 1997. Ehlers-Danlos National Foundation (USA) and Ehlers-Danlos Support Group (UK). *Am J Med Genet*. 1998;77:31-37.
7. Beighton P, Horan FT. Surgical aspects of the Ehlers-Danlos syndrome. A survey of 100 cases. *Br J Surg*. 1969;56:255-259.
8. Fogel S. Surgical failures: is it the surgeon or the patient? The all too often missed diagnosis of Ehlers-Danlos syndrome. *Am Surg*. 2013;79:608-613.
9. Cañadas V, Vilacosta I, Bruna I, et al. Marfan syndrome. Part 1: pathophysiology and diagnosis. *Nat Rev Cardiol*. 2010;7: 256-265.
10. Broughton G 2nd, Janis JE, Attinger CE. The basic science of wound healing. *Plast Reconstr Surg*. 2006;117:12S-34S.
11. Ehrlich HP, Krummel TM. Regulation of wound healing from a connective tissue perspective. *Wound Repair Regen*. 1996;4: 203-210.
12. Liu X, Wu H, Byrne M, et al. Type III collagen is crucial for collagen I fibrillogenesis and for normal cardiovascular development. *Proc Natl Acad Sci USA*. 1997;94:1852-1856.
13. Wagh PV, Leverich AP, Sun CN, et al. Direct inguinal herniation in men: a disease of collagen. *J Surg Res*. 1974;17:425-433.
14. Wagh PV, Read RC. Defective collagen synthesis in inguinal herniation. *Am J Surg*. 1972;124:819-822.
15. Conner WT, Peacock EE Jr. Some studies on the etiology of inguinal hernia. *Am J Surg*. 1973;126:732-735.
16. Pans A, Pierard GE, Albert A, et al. Adult groin hernias: new insight into their biomechanical characteristics. *Eur J Clin Invest*. 1997;27:863-868.
17. Casanova AB, Trindade EN, Trindade MR. Collagen in the transversalis fascia of patients with indirect inguinal hernia: a case-control study. *Am J Surg*. 2009;198:1-5.
18. Ozdogan M, Yildiz F, Gurer A, et al. Changes in collagen and elastic fiber contents of the skin, rectus sheath, transversalis fascia and peritoneum in primary inguinal hernia patients. *Bratisl Lek Listy*. 2006;107:235-238.
19. Friedman DW, Boyd CD, Norton P, et al. Increases in type III collagen gene expression and protein synthesis in patients with inguinal hernias. *Ann Surg*. 1993;218:754-760.
20. Klinge U, Zheng H, Si ZY, et al. Synthesis of type I and III collagen, expression of fibronectin and matrix metalloproteinases-1 and -13 in hernial sac of patients with inguinal hernia. *Int J Surg Investig*. 1999;1:219-227.
21. Kral JG, Levine RG. Increases in type III collagen gene expression and protein synthesis in patients with inguinal hernias. *Ann Surg*. 1995;221:116-117.
22. Meyer AL, Berger E, Monteiro O Jr, et al. Quantitative and qualitative analysis of collagen types in the fascia transversalis of inguinal hernia patients. *Arq Gastroenterol*. 2007;44:230-234.
23. Klinge U, Si ZY, Zheng H, et al. Abnormal collagen I to III distribution in the skin of patients with incisional hernia. *Eur Surg Res*. 2000;32:43-48.
24. Pans A, Albert A, Lapière CM, et al. Biochemical study of collagen in adult groin hernias. *J Surg Res*. 2001;95:107-113.
25. Fachinelli A, Maciel Trindade MR. Qualitative and quantitative evaluation of total and types I and III collagens in patients with ventral hernias. *Langenbecks Arch Surg*. 2007;392:459-464.

26. Fachinelli A, Trindade MR, Fachinelli FA. Elastic fibers in the anterior abdominal wall. *Hernia* 2011;15:409–415.
27. White B, Osier C, Gletsu N, et al. Abnormal primary tissue collagen composition in the skin of recurrent incisional hernia patients. *Am Surg*. 2007;73:1254–1258.
28. Rosch R, Binnebösel M, Junge K, et al. Analysis of c-myc, PAI-1 and uPAR in patients with incisional hernias. *Hernia*. 2008;12:285–288.
29. Rosch R, Junge K, Knops M, et al. Analysis of collagen-interacting proteins in patients with incisional hernias. *Langenbecks Arch Surg*. 2003;387:427–432.
30. Si Z, Bhardwaj R, Rosch R, et al. Impaired balance of type I and type III procollagen mRNA in cultured fibroblasts of patients with incisional hernia. *Surgery* 2002;131:324–331.
31. Klinge U, Si ZY, Zheng H, et al. Collagen I/III and matrix metalloproteinases (MMP) 1 and 13 in the fascia of patients with incisional hernias. *J Invest Surg*. 2001;14:47–54.
32. Junge K, Klinge U, Rosch R, et al. Decreased collagen type I/III ratio in patients with recurring hernia after implantation of alloplastic prostheses. *Langenbecks Arch Surg*. 2004;389:17–22.
33. Ozdemir S, Ozis ES, Gulpinar K, et al. The value of copper and zinc levels in hernia formation. *Eur J Clin Invest*. 2011;41:285–290.
34. Henriksen NA, Yadete DH, Sorensen LT, et al. Connective tissue alteration in abdominal wall hernia. *Br J Surg*. 2011;98:210–219.
35. Kureshi A, Vaiude P, Nazhat SN, et al. Matrix mechanical properties of transversalis fascia in inguinal herniation as a model for tissue expansion. *J Biomech*. 2008;41:3462–3468.
36. Liem MS, van der Graaf Y, Beemer FA, et al. Increased risk for inguinal hernia in patients with Ehlers-Danlos syndrome. *Surgery* 1997;122:114–115.
37. Giroto JA, Malaisrie SC, Bulkely G, et al. Recurrent ventral herniation in Ehlers-Danlos syndrome. *Plast Reconstr Surg*. 2000;106:1520–1526.
38. de Weerd L, Kjæve J, Gurgia L, et al. A large abdominal intercostal hernia in a patient with vascular type Ehlers-Danlos syndrome: a surgical challenge. *Hernia* 2012;16:117–120.
39. Antoniou GA, Georgiadis GS, Antoniou SA, et al. Abdominal aortic aneurysm and abdominal wall hernia as manifestations of a connective tissue disorder. *J Vasc Surg*. 2011;54:1175–1181.
40. Takagi H, Sugimoto M, Kato T, et al. Postoperative incision hernia in patients with abdominal aortic aneurysm and aortoiliac occlusive disease: a systematic review. *Eur J Vasc Endovasc Surg*. 2007;33:177–181.
41. Ailawadi G, Eliason JL, Upchurch GR Jr. Current concepts in the pathogenesis of abdominal aortic aneurysm. *J Vasc Surg*. 2003;38:584–588.
42. Satta J, Juvonen T, Haukipuro K, et al. Increased turnover of collagen in abdominal aortic aneurysms, demonstrated by measuring the concentration of the aminoterminal propeptide of type III procollagen in peripheral and aortal blood samples. *J Vasc Surg*. 1995;22:155–160.
43. Al-Assiri A, Wiseman N, Bunge M. Prenatal diagnosis of intrathoracic stomach (gastric herniation). *J Pediatr Surg*. 2005;40:E15–E17.
44. Parida SK, Kriss VM, Hall BD. Hiatus/paraesophageal hernias in neonatal Marfan syndrome. *Am J Med Genet*. 1997;72:156–158.
45. Finkbohner R, Johnston D, Crawford ES, et al. Marfan syndrome. Long-term survival and complications after aortic aneurysm repair. *Circulation* 1995;91:728–733.
46. Pyeritz RE, McKusick VA. The Marfan syndrome: diagnosis and management. *N Engl J Med*. 1979;300:772–777.
47. Aoyama T, Francke U, Gasner C, et al. Fibrillin abnormalities and prognosis in Marfan syndrome and related disorders. *Am J Med Genet*. 1995;58:169–176.
48. Fricke M, Langer C, Brunner E, et al. Fibrillin-1 in incisional hernias: an immunohistochemical study in scar and non-scar regions of human skin and muscle fasciae. *J Anat*. 2008;212:674–685.
49. Novitsky YW, Rosen MJ. The biology of biologics: basic science and clinical concepts. *Plast Reconstr Surg*. 2012;130(5 Suppl 2):9S–17S.
50. Kapischke M, Prinz K, Tepel J, et al. Precoating of alloplastic materials with living human fibroblasts – a feasibility study. *Surg Endosc*. 2005;19:791–797.
51. Drewa T, Galazka P, Prokurat A, et al. Abdominal wall repair using a biodegradable scaffold seeded with cells. *J Pediatr Surg*. 2005;40:317–321.
52. Zhao Y, Zhang Z, Wang J, et al. Abdominal hernia repair with a decellularized dermal scaffold seeded with autologous bone marrow-derived mesenchymal stem cells. *Artif Organs* 2012;36:247–255.
53. Aziz F, Kuivaniemi H. Role of matrix metalloproteinase inhibitors in preventing abdominal aortic aneurysm. *Ann Vasc Surg*. 2007;21:392–401.
54. Lokeshwar BL. Chemically modified non-antimicrobial tetracyclines are multifunctional drugs against advanced cancers. *Pharmacol Res*. 2011;63:146–150.
55. Pasternak B, Aspenberg P. Metalloproteinases and their inhibitors—diagnostic and therapeutic opportunities in orthopedics. *Acta Orthop*. 2009;80:693–703.
56. Calaluce R, Davis JW, Bachman SL, et al. Incisional hernia recurrence through genomic profiling: a pilot study. *Hernia* 2013;17:193–202.