


ORIGINAL ARTICLE

Ultralow dose computed tomography protocol for hook-wire localization of solitary pulmonary nodules prior to video-assisted thoracoscopic surgery

Bo Liu¹, Jie Fang², Haipeng Jia¹, Zhigang Sun³, Jian Liao⁴, Hong Meng¹, Fengmin Pan¹ & Chunhai Li¹ 

1 Department of Radiology, Qilu Hospital of Shandong University, Jinan, China

2 Department of Respiratory Medicine, Dezhou People's Hospital, Dezhou, China

3 Department of Thoracic Surgery, Jinan Central Hospital Affiliated to Shandong University, Jinan, China

4 Department of Radiology, Xiamen Hospital of Traditional Chinese Medicine, Xiamen, China

Keywords

Ultralow dose; hook-wire; localization; pulmonary nodule; VATS.

Correspondence

Chunhai Li, Department of Radiology, Qilu Hospital of Shandong University, Wenhua Xi Road 107#, Jinan, China.
Tel: +86 185 6008 1620
Fax: +86 531 8216 6037
Email: ekos20@163.com

Received: 19 February 2019;

Accepted: 29 March 2019.

doi: 10.1111/1759-7714.13075

Thoracic Cancer **10** (2019) 1348–1354

Abstract

Background: This study prospectively investigated the efficacy and radiation dose of ultralow dose computed tomography (CT)-guided hook-wire localization (HWL) at 100 kV with tin filtration (100Sn kV) for small solitary pulmonary nodules.

Methods: All HWL procedures were performed on a third generation dual-source CT system. Eighty-eight consecutive patients undergoing CT-guided HWL were randomly assigned to standard dose CT (Group A: $n = 44$; reference 110 kV and 50 mA) or ultralow dose CT (Group B: $n = 44$; ¹⁰⁰Sn kV and 96 mA) protocols. The technical success rate, complications, subjective image quality, and radiation dose were compared between the groups.

Results: The mean volume CT dose index and total dose-length product were significantly lower in Group B compared to Group A (0.32 mGy vs. $3.2 \pm 1.1 \text{ mGy}$ and $12.1 \pm 0.97 \text{ mGy-cm}$ vs. $120 \pm 40.6 \text{ mGy-cm}$; $P < 0.001$). The effective dose in Group B was significantly lower than in Group A ($0.17 \pm 0.01 \text{ mSv}$ vs. $1.68 \pm 0.57 \text{ mSv}$, -89.8% ; $P < 0.001$). The technical success rates were 100% for both groups. There were no significant differences in complication rates between the protocols ($P > 0.05$). The image quality of ultralow dose CT met the requirements for HWL procedure.

Conclusion: Ultralow dose CT-guided HWL of solitary pulmonary nodules performed at ¹⁰⁰Sn kVp spectral shaping significantly reduced the radiation dose compared to standard dose CT, with high technical success and acceptable patient safety.

Introduction

Computed tomography (CT) has become an essential protocol for the evaluation of pulmonary lesions because of its high spatial and inherent contrast resolution of the lung parenchyma. Patients with malignancy will usually undergo several CT scans for follow-up, which may result in considerable radiation dose accumulation. Many studies have reported the potential adverse biological effects of ionizing radiation to the human body, such as cancer risk. Based on the “as low as reasonably achievable” (ALARA) principle, patients should receive the lowest achievable

radiation dose in clinical procedures.¹ The United States Food and Drug Administration has established an initiative to reduce unnecessary radiation exposure from medical imaging.²

Various effective measures have been adopted to minimize dose exposure, including lowering the tube potential and current, automated exposure control, selective in-plane shielding, and iterative image reconstruction.^{3–5} The development of CT hardware and software has led to the introduction of the third-generation dual-source CT with a built-in tin filter for spectral shaping. Tin filter-based

spectral shaping aims to remove the less dose-efficient low-energy photons that predominantly contribute to patient exposure, and does not cause noticeable compromises in image quality.⁶ Michael *et al.* reported that the third-generation CT scanner at 100 kVp with tin filtration (¹⁰⁰Sn kVp) has high sensitivity for the detection of pulmonary nodules and allows for drastic dose reduction at exposure levels comparable to plain film chest X-rays.⁷ The mean effective radiation dose in their study was only 0.13 mSv. Moreover, ultralow dose CT protocol has been successfully applied in CT-guided interventional procedures (e.g. chest biopsy), with high diagnostic accuracy and safety.^{8,9}

Hook-wire localization (HWL) is currently the most commonly used technique for small lung nodule localization prior to video-assisted thoracoscopic surgery (VATS).^{10,11} Presurgical localization of unpalpable nodules can precisely guide surgeons, whereas repetitive CT scanning was previously necessary. The procedure-related radiation dose should be taken into account and should be as low as reasonably achievable;¹² however, relatively few studies have described the use of ultralow or low dose CT protocols for CT-guided HWL.

Thus, the purpose of this study was to prospectively investigate the efficacy and radiation dose of ultralow dose CT-guided HWL for small solitary pulmonary nodules (SPNs) at ¹⁰⁰Sn kV with spectral shaping using a third-generation dual-source CT compared to standard dose CT protocol. We hypothesized that the technical success rates of CT-guided HWL would not be significantly altered by radically lowering the CT dose with the use of the ultralow dose protocol.

Methods

Patients

The institutional review board approved this study and written informed consent was obtained from all patients after detailed explanation of the procedure. Eighty-eight consecutive patients who were referred to our department from August 2016 to February 2019 for HWL prior to VATS were included. The indication for CT-guided HWL was patients with suspected malignant SPNs. The exclusion criteria were: severe emphysema, advanced interstitial pulmonary disease, refractory coagulation dysfunction, positive pressure ventilation, cardiac insufficiency, pleuritis, and a lesion located close to the mediastinal great vessels. Patients with a body mass index (BMI) of > 30 kg/m² were also excluded.

The 88 patients with 88 SPNs were randomly assigned to either standard dose CT (Group A: reference 110 kV and 50mA, *n* = 44) or ultralow dose CT (Group B: ¹⁰⁰Sn

kV and fixed 96 mA, *n* = 44) protocols. Randomization was performed by computer-generated assignment. Group A included 19 men and 25 women at a mean age of 58.8 ± 8.8 years. Group B included 20 men and 24 women at a mean age 57.3 ± 9.8 years. The characteristics of the target SPNs (nodule size, location, type, and distance from pleura to target lesion) were recorded. All nodules were classified as ground glass nodules (GGNs) or solid nodules (SNs). The patient and nodule characteristics of the groups are summarized in Table 1.

Computed tomography scanning protocol

A third-generation dual-source CT scanner (Somatom Force, Siemens Healthcare, Munich, Germany) was employed in this study. A collimation of 88 x 0.6 mm and a slice acquisition of 192 x 0.6 mm by means of a z-flying focal spot were used. The gantry rotation time was 0.5 seconds at a pitch of 1.2. The scan area was limited to the lesion area using inspiratory breath hold to decrease unnecessary dose exposure. Patients were placed in a supine, prone, or decubitus position depending on the location of the lesions. Intravenous access was obtained.

The scanning parameters for the standard dose CT protocol (Group A) were as follows: 110 reference kV and 50 reference mA using automated tube current modulation and automated tube potential selection (CARE kV; Siemens Healthcare). The scanning parameters for the ultralow-dose CT protocol (Group B) were as follows: a fixed tube potential of 100 kV with a fixed tube current-time product of 96 mA and a dedicated 0.6 mm tin filter placed immediately after the X-ray source, resulting in a volume CT dose index of 0.32 mGy. All images from both groups were reconstructed with advanced model-based iterative reconstruction (ADMIRE), as described in detail in a recent study¹³ at a strength level of 5 using a slice thickness of 4 mm with an increment of 1.0 mm. Reconstructions using a dedicated lung convolution kernel (Bl57) and a soft tissue convolution kernel (Br36) were generated. The reconstructed field of view was 400 x 400 mm². The image matrix was 512 x 512 pixels.

The volume CT dose index (CTDI_{vol}) and the dose-length product (DLP) per scan were obtained from the patient dose report. The effective dose (ED) was calculated by multiplying the total DLP by the conversion factor (0.014mSv/mGy-cm).¹⁴

Hook-wire localization (HWL)

One radiologist performed all procedures. The senior radiologist and a thoracic surgeon carefully reviewed the recent chest CT images in order to determine the appropriate puncture route and body position for hook-wire

Table 1 Patient and nodule characteristics

Characteristics	Group A (n = 44)	Group B (n = 44)	P
Male/Female	19/25	20/24	0.83
Age (years)	58.8 ± 8.8	57.3 ± 9.8	0.43
Smoking history	21 (47.7%)	24 (54.5%)	0.52
Mild-moderate emphysema	15 (34.1%)	13 (29.5%)	0.65
BMI (kg/m ²)	26.1 ± 1.31	25.7 ± 1.8	0.24
Nodule size (cm)	1.34 ± 0.52	1.45 ± 0.40	0.29
< 1	9 (20.5%)	5 (11.4%)	
1–2	28 (63.6%)	33 (75.0%)	
> 2	7 (15.9%)	6 (13.6%)	
Nodule location			0.82
Upper and middle	29 (65.9%)	30 (68.2%)	
Lower	15 (34.1%)	14 (31.8%)	
Nodule feature			0.62
GGN	34 (77.3%)	32 (72.7%)	
SN	10 (23.7%)	12 (27.3%)	
Position			0.73
Supine	24 (54.5%)	21 (47.7%)	
Prone	16 (36.4%)	17 (38.6%)	
Decubitus	4 (9.1%)	6 (13.7%)	
Nodule distance to pleural surface (mm)	11.6 ± 6.9	9.84 ± 7.4	0.28
Nodule distance to hook-wire (mm)			0.52
Intra-nodular	21 (47.7%)	18 (40.9%)	
2–10 mm	23 (52.3%)	26 (59.1%)	
HWL duration (minutes)	19.6 ± 4.3	21.4 ± 5.8	0.11
VATS duration (minutes)	49.5 ± 13.4	47.6 ± 9.1	0.45
HWL complications			
Minor pneumothorax	11 (25.0%)	13 (29.5%)	0.63
Hemorrhage	10 (22.7%)	9 (20.5%)	0.79
Dislodgement	0	0	

BMI, body mass index; GGN, ground-glass nodule; HWL, hook-wire localization; SN, solid nodule; VATS, video-assisted thoracoscopic surgery.

placement. A 20 G hook-wire system (Argon Medical Devices, Frisco, TX, USA) was employed to locate all SPNs. The hook-wire is commonly used for breast surgery, but has also been successfully applied in pulmonary nodule localization.

During the procedure, the first chest CT scan was used to determine the optimal puncture site, angle, and depth. The puncture route should avoid traversing important vessels, including the internal mammary, axillary, subclavian, intercostal vessel, and pulmonary vessels. The bulla and interlobar fissure should also be avoided to prevent pneumothorax. After local anesthesia of the puncture route with 2% lidocaine, the introducer of the hook-wire system was inserted into the chest wall with the tip close to the parietal pleura. After verification of the plane and angulation, the introducer was advanced into the lung parenchyma to reach the lesion but not into the lesion to avoid tumor seeding via a puncture

tract. The hook-wire was then released via the introducer. A final chest CT scan was performed to confirm the position of the hook-wire relative to the nodule and identify any postprocedural complications. The tail of the hook-wire was cut near the skin surface and allowed to withdraw into the chest when the lung collapsed during VATS. The HWL procedure time and complications were recorded.

Video-assisted thoracoscopic surgery (VATS)

In all cases, VATS was performed within 1.5 hours after hook-wire placement. Wedge resection of the lesion area was conducted using a stapler device according to the hook-wire localization. After resection, an experienced pathologist examined intraoperative frozen sections. When a frozen specimen revealed lung cancer, if physiologically feasible, lobectomy with mediastinal lymph node dissection was performed via VATS. When a lesion was diagnosed as benign or a metastatic carcinoma, no further surgery was necessary. The specimens were also prepared for postoperative histological examination. The VATS procedural time was recorded.

Subjective image quality

Two interventional radiologists assessed the overall image quality, including the visual region of interest in target lesions and the sharpness of vessels in the proposed needle pathway. A five-point scoring system was used to grade overall image quality: 1 = unacceptable/non-interventional (poor definition of lesion and access); 2 = poor (borderline adequate lesion visualization, but inadequate visualization of safe access, needle tip, or target area); 3 = adequate (adequate definition of lesion, access, and needle tip; slight impact of image noise, sufficient for HWL); 4 = good (good visualization of lesion, access, and needle tip; minimal image noise); and 5 = excellent (excellent definition of lesion, access, and needle tip). Patients with scans with a quality score of 3–5 were considered eligible for HWL.

Statistical analysis

Statistical analyses were performed using SPSS version 15.0. A two-sided P value of < 0.05 was considered statistically significant. Continuous variables were expressed as mean ± standard deviation (SD). Student’s t and Pearson χ² tests were used to analyze continuous and categorical variables between the groups, respectively.

Results

Baseline characteristics

Patient and nodule characteristics are summarized in Table 1. There were no significant differences in mean age ($P = 0.43$), gender distribution ($P = 0.83$), or BMI ($P = 0.24$) between the groups. The mean sizes of the SPNs were 1.34 ± 0.52 cm in Group A and 1.45 ± 0.40 cm in Group B ($P = 0.29$). The SPNs consisted of 77.3% GGNs and 23.7% solid nodules in Group A, and 72.7% GGNs and 27.3% solid nodules in Group B ($P = 0.62$). Lesion location, pleural-to-lesion depth, and patient position during HWL did not differ significantly between the groups (all $P > 0.05$).

HWL procedure

Technical success was achieved in all 88 patients during HWL (Fig 1). The HWL duration was not significantly different between the groups ($P = 0.11$) (Table 1). In Group A, the hook wire directly penetrated the nodule in 21 cases, while in the other 23 cases, the hook wire passed alongside the nodule < 1.0 cm from the lesion margin. In Group B, the hook wire directly penetrated the nodule in 18 cases, while in the other 26 cases, the hook wire passed alongside the nodule < 1.0 cm from the lesion margin. In terms of complications, minor asymptomatic pneumothorax was observed in 11 patients (25%) in Group A compared to 13 patients (29.5%) in Group B ($P = 0.63$). Pneumothorax frequently occurs in patients with emphysema ($P = 0.01$). Limited focal pulmonary hemorrhage along the puncture tract was observed in 10 cases (22.7%) in Group A compared to 9 (20.5%) cases in Group B ($P = 0.79$). No other significant complications occurred.

VATS

All of the target SPNs were accurately positioned and resected under VATS without requiring conversion to open thoracotomy. The median VATS duration in Groups A and B were 49.5 ± 13.4 and 47.6 ± 9.1 minutes ($P = 0.45$), respectively. Seventeen wedge resections and 27 lobectomies were performed in Group A; 15 wedge resections and 29 lobectomies were performed in Group B. Six patients in Group A and five in Group B with primary lung cancer underwent wedge resection because of poor cardiopulmonary function. No hook-wire dislodgement occurred in either group. The final pathological diagnoses of all 88 lesions are reported in Table 2.

Subjective image quality

Subjective image quality of the ultralow dose CT protocol was rated lower compared to the standard dose CT protocol by both readers (3.68 ± 0.6 vs. 4.3 ± 0.7 ; $P < 0.001$). No examination was rated non-interventional for HWL (grade 1).

Radiation dose

The mean overall longitudinal scan length in Group B was a little longer than that in Group A (37.7 ± 3.0 cm vs. 36.9 ± 2.6 cm; $P = 0.26$). Compared to Group A, Group B had significantly lower $CTDI_{vol}$ (0.32 mGy vs. 3.2 ± 1.1 mGy; $P < 0.001$), mean total DLP (12.1 ± 0.97 mGy-cm vs. 120 ± 40.6 mGy-cm; $P < 0.001$), and ED (0.17 ± 0.01 mSv vs. 1.68 ± 0.57 mSv; $P < 0.001$) (Table 3). The radiation ED in Group B decreased by 89.8% compared to Group A.

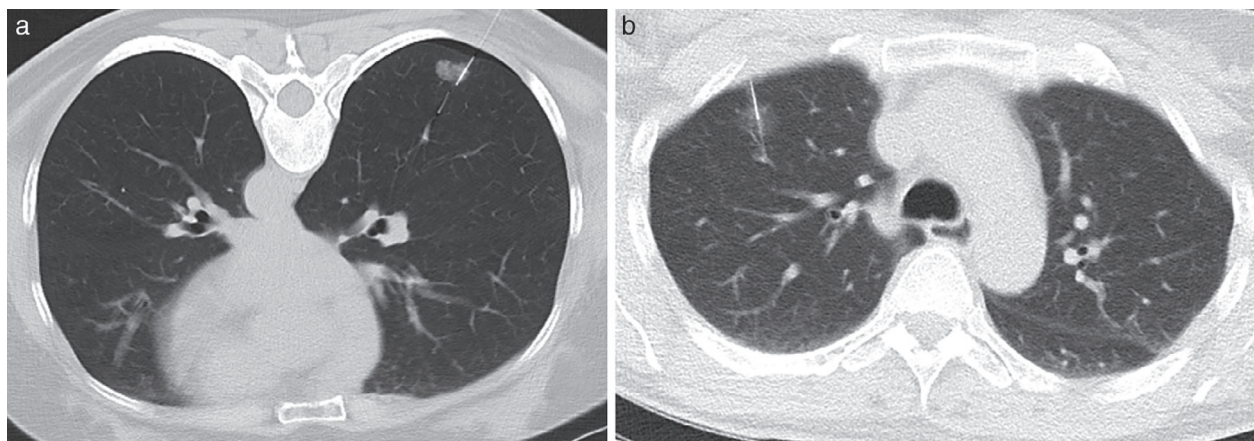


Figure 1 Computed tomography-guided hook-wire localization by two protocols. (a) Standard dose protocol: axial image shows successful hook-wire placement into a pulmonary nodule in the right lower lobe of a 48-year woman. Asymptomatic minor pneumothorax was observed. (b) Ultralow dose protocol: axial image shows successful hook-wire placement into a pulmonary nodule in the right upper lobe of a 58-year woman.

Table 2 Histopathologic results

Variables	Group A (n = 44)	Group B (n = 44)
Malignancy	36 (81.8%)	39 (88.6%)
Adenocarcinoma	28	31
AIS	2	3
MIA	8	5
IA	18	23
Squamous cell carcinoma	3	2
Small cell lung carcinoma	2	1
Metastasis	3	5
Benign	8 (18.2%)	5 (11.4%)
Focal inflammation	5	3
Fibrosis	1	1
Tuberculosis	2	1

AIS, adenocarcinoma in situ; IA, invasive adenocarcinoma; MIA, minimally invasive adenocarcinoma.

Discussion

Our study is the first to investigate the feasibility of ultralow dose CT-guided HWL in SPNs with additional hardening of a 100 kV source spectrum by a 0.6 mm tin filter. Forty-four patients who underwent standard dose and 44 patients who underwent ultralow dose CT protocol were compared. Our preliminary results suggest that although the ultralow dose CT image quality was lower, it was comparable to standard dose CT in terms of both HWL technique success and safety. Moreover, the radiation ED in the ultralow dose CT group radically decreased by 89.8% compared to that of the standard dose group.

Various preoperative localization methods have been developed to identify small pulmonary nodules that cannot be palpated or visualized during VATS surgery, which dramatically reduces the thoracotomy conversion rate. The reported methods include hook-wire, dye localization, microcoil and fiducial markers, contrast medium injection (e.g. barium sulfate and lipiodol), radiotracer, electromagnetic navigation bronchoscopy, and intraoperative ultrasonography.¹⁵ Among these methods, CT-guided HWL is the most commonly used method, with a high technique success rate, low thoracotomy conversion rate, and few post-operative complications. Recently, a modified hook-wire placement technique was successfully applied to locate

multiple pulmonary nodules.¹⁶ The mean success rate of HWL is reported as 0.98 (95% confidence interval 0.97–0.99).¹⁷ In our case, the success rate was 100%, which was consistent with the rate reported by Gruber-Rouh *et al.*¹⁸ Dislodgement is a major disadvantage of the HWL procedure. The hook-wire dislodgement rate is reported as 0–6.9%. Klinkenberg *et al.* reported one case (0.7%) and Chen *et al.* reported two cases (4.9%) of dislodgement in their studies.^{10,19} As discussed in our former study, many effective measures are taken to prevent dislodgement.¹¹ In terms of other complications, pneumothorax is the most common,²⁰ with a reported incidence of 7.5–40%.¹⁵ In our cohort, asymptomatic minimal pneumothorax in 24 patients (27.3%) did not require further intervention. Lung parenchyma hemorrhage was observed in 19 (21.6%) patients, which is consistent with the reported rate of 13.9–36% in the literature.¹⁵ The incidence of above-mentioned complications did not differ between the groups (all $P > 0.05$).

CT-guided intervention, such as biopsy, drainage, and thermal ablation, may be a significant source of radiation exposure in certain patients.²¹ Interventionists should adhere to the ALARA principle during such procedures. Researchers have attempted to reduce radiation doses during CT-guided interventional procedures,^{12,21} mainly focusing on the optimization of tube current and voltage.²² To the best of our knowledge, there is no literature regarding low-dose CT protocol in the HWL procedure. In most HWL studies, the radiation dose has not been reported. Gruber-Rouh *et al.* used 120 kV and 30 mA in their CT protocol to locate pulmonary metastasis by HWL, resulting in a total mean DLP of 336 mGy-cm.¹⁸ Iguchi *et al.* used 120 kV and 20 mA in their CT fluoroscopy for HWL.²⁰ Our study is the first to use ultralow dose CT protocol during the HWL procedure, and our results suggest the feasibility of ultralow dose protocol in HWL, with high technical success.

Moreover, low-dose CT protocols have shown the significant benefit of radiation dose reduction in CT-guided percutaneous transthoracic core needle biopsy (PTNB).^{8,23–25} Use of low tube voltage (80–100 kV) protocol and low tube current (7.5 mA, 20 mA, 25 mA reference) ($P < 0.001$) is reported to significantly reduce mean DLP and ED. We used ultralow dose CT protocol (¹⁰⁰Sn kV and 70 mA) for PCNB in our previous study and observed a dramatic reduction of ED of 92.1%.¹³ Considering that the hook wire is thinner than the biopsy needle (20 G vs. 17 G), we increased the tube current to 96 mA to ensure better image quality. HWL is very similar to the PTNB procedure, both of which use CT images to guide the needle tract to locate pulmonary lesions. The image quality required for diagnostic purposes is not as high as that required for conventional chest CT. In this study, the marked reduction in

Table 3 Radiation dose parameters and subjective image quality

Parameters	Group A	Group B	P
Total scan length (cm)	36.9 ± 2.6	37.7 ± 3.0	0.26
CTDI _{vol} (mGy)	3.2 ± 1.1	0.32	< 0.001
Total DLP (mGy-cm)	120 ± 40.6	12.1 ± 0.97	< 0.001
ED (mSv)	1.68 ± 0.57	0.17 ± 0.01	< 0.001
Subjective image quality	4.31 ± 0.7	3.68 ± 0.6	< 0.001

CTDI_{vol}, volume CT dose index; DLP, dose-length product; ED, effective dose.

radiation dose (ED 89.8%) was achievable using spectral shaping on a third-generation dual-source CT scanner. The ultralow dose CT at ¹⁰⁰Sn kV allowed for an image quality adequate for HWL without decreasing the technical success rate or patient safety.

Our study has several limitations. First, our cohort was relatively small; therefore our results need to be confirmed by further studies with larger patient samples. Second, although subjective assessment of the overall image quality of the two protocols was performed in a randomized order, it must be acknowledged that readers might have recognized the different protocols because of their slightly different image appearance. Third, obesity is a known source of impaired quality in CT and increased image noise²⁶ which may affect the sensitivity and accuracy of procedures. Only patients with a BMI of < 30 kg/m² were included in the study. Future studies may address the use of spectral shaping in obese patients (BMI > 30 kg/m²) to further evaluate the ultralow dose CT protocol. Furthermore, only limited numbers of small GGNs < 1.0 cm were included. Concerns regarding the detectability of these GGNs during HWL should be further elucidated in future studies.

In conclusion, the use of ultralow dose CT protocol during CT-guided HWL of SPNs significantly reduced the radiation dose by 89.8%. Ultralow dose CT is an effective alternative to standard dose CT, with satisfactory technical success and patient safety.

Acknowledgment

This work was supported by the Shandong Provincial Key Research and Development Program (No. 2018GSF118087 and No. 2017GSF218010).

Disclosure

No authors report any conflict of interest.

References

- 1 Mountford PJ, Temperton DH. Recommendations of the International Commission on Radiological Protection (ICRP) 1990. *Eur J Nucl Med* 1992; **19**: 77–9.
- 2 US Food and Drug Administration. White Paper: Initiative to Reduce Unnecessary Radiation Exposure from Medical Imaging. 2010. US FDA, Silver Spring, MD.
- 3 Bankier AA, Tack D. Dose reduction strategies for thoracic multidetector computed tomography: Background, current issues, and recommendations. *J Thorac Imaging* 2010; **25**: 278–88.
- 4 Baummueller S, Winklehner A, Karlo C *et al.* Low-dose CT of the lung: Potential value of iterative reconstructions. *Eur Radiol* 2012; **22**: 2597–606.
- 5 Kalender WA, Buchenau S, Deak P *et al.* Technical approaches to the optimisation of CT. *Phys Med* 2008; **24**: 71–9.
- 6 Dewes P, Frellesen C, Scholtz JE *et al.* Low-dose abdominal computed tomography for detection of urinary stone disease - Impact of additional spectral shaping of the X-ray beam on image quality and dose parameters. *Eur J Radiol* 2016; **85**: 1058–62.
- 7 Messerli M, Kluckert T, Knitel M *et al.* Ultralow dose CT for pulmonary nodule detection with chest x-ray equivalent dose - A prospective intra-individual comparative study. *Eur Radiol* 2017; **27**: 3290–9.
- 8 Smith JC, Jin DH, Watkins GE, Miller TR, Karst JG, Oyoyo UE. Ultra-low-dose protocol for CT-guided lung biopsies. *J Vasc Interv Radiol* 2011; **22**: 431–6.
- 9 Wagner MG, Hinshaw JL, Li Y *et al.* Ultra-low radiation dose CT fluoroscopy for percutaneous interventions: A porcine feasibility study. *Radiology* 2019; **291**: 241–249.
- 10 Chen S, Zhou J, Zhang J *et al.* Video-assisted thoracoscopic solitary pulmonary nodule resection after CT-guided hookwire localization: 43 cases report and literature review. *Surg Endosc* 2011; **25**: 1723–9.
- 11 Li C, Liu B, Jia H, Dong Z, Meng H. Computed tomography-guided hook wire localization facilitates video-assisted thoracoscopic surgery of pulmonary ground-glass nodules. *Thorac Cancer* 2018; **9**: 1145–50.
- 12 Sarti M, Brehmer WP, Gay SB. Low-dose techniques in CT-guided interventions. *Radiographics* 2012; **32**: 1109–19 discussion 19–20.
- 13 Li C, Liu B, Meng H, Lv W, Jia H. Efficacy and radiation exposure of ultra-low-dose chest CT at 100 kVp with tin filtration in CT-guided percutaneous core needle biopsy for small pulmonary lesions using a third-generation dual-source CT scanner. *J Vasc Interv Radiol* 2019; **30**: 95–102.
- 14 Deak PD, Smal Y, Kalender WA. Multisection CT protocols: sex- and age-specific conversion factors used to determine effective dose from dose-length product. *Radiology* 2010; **257**: 158–66.
- 15 Lin MW, Chen JS. Image-guided techniques for localizing pulmonary nodules in thoracoscopic surgery. *J Thorac Dis* 2016; **8**: S749–S55.
- 16 Kadeer X, Wang L, Zhang L, Shi W, Chen C. Modified hook-wire placement technique for localizing multiple pulmonary nodules. *J Surg Oncol* 2018; **118**: 1188–93.
- 17 Park CH, Han K, Hur J *et al.* Comparative effectiveness and safety of preoperative lung localization for pulmonary nodules: A systematic review and meta-analysis. *Chest* 2017; **151**: 316–28.
- 18 Gruber-Rouh T, Naguib NNN, Beeres M *et al.* CT-guided hook-wire localisation prior to video-assisted thoracoscopic surgery of pulmonary lesions. *Clin Radiol* 2017; **72**: 898 e7–e11.
- 19 Klinkenberg TJ, Dinjens L, Wolf RFE *et al.* CT-guided percutaneous hookwire localization increases the efficacy and safety of VATS for pulmonary nodules. *J Surg Oncol* 2017; **115**: 898–904.

- 20 Iguchi T, Hiraki T, Gobara H *et al.* CT fluoroscopy-guided preoperative short hook wire placement for small pulmonary lesions: Evaluation of safety and identification of risk factors for pneumothorax. *Eur Radiol* 2016; **26**: 114–21.
- 21 Lucey BC, Varghese JC, Hochberg A, Blake MA, Soto JA. CT-guided intervention with low radiation dose: Feasibility and experience. *AJR Am J Roentgenol* 2007; **188**: 1187–94.
- 22 Rezazadeh S, Co SJ, Bicknell S. Reduced kilovoltage in computed tomography-guided intervention in a community hospital: Effect on the radiation dose. *Can Assoc Radiol J* 2014; **65**: 345–51.
- 23 Frisch BK, Slebocki K, Mammadov K *et al.* Implementation of ultra-low-dose lung protocols in CT-guided lung biopsies: Feasibility and safety in the clinical setting. *J Int Med Res* 2017; **45**: 2101–9.
- 24 Chang DH, Hiss S, Mueller D *et al.* Radiation dose reduction in computed tomography-guided lung interventions using an iterative reconstruction technique. *Rofo* 2015; **187**: 906–14.
- 25 Adiga S, Athreya S. Safety, efficacy, and feasibility of an ultra-low dose radiation protocol for CT-guided percutaneous needle biopsy of pulmonary lesions: Initial experience. *Clin Radiol* 2014; **69**: 709–14.
- 26 Barrett JF, Keat N. Artifacts in CT: Recognition and avoidance. *Radiographics* 2004; **24**: 1679–91.