

ORIGINAL ARTICLE

Current concepts of immunofluorescence in oral mucocutaneous diseases

Anuradha CH, Malathi N¹, Anandan S², Magesh KT¹

Department of Oral Pathology and Microbiology, SIBAR Institute of Dental Sciences, Takkellapadu, Guntur, ¹Sri Ramachandra Dental College and Hospital, Porur, Chennai, ²Department of Dermatology, Sri Ramachandra Medical College and Hospital, Porur, Chennai, India

Address for correspondence:

Dr. Anuradha CH,
Department of Oral and Maxillofacial Pathology,
Sibar Institute of Dental Sciences, Guntur, India.
E-mail: drramanabv@yahoo.com

ABSTRACT

Aim: To study the immunofluorescence pattern and to assess its reliability as a confirmatory diagnostic test in patients with pemphigus, pemphigoid, lichen planus, and lupus erythematosus and also to assess the disease activity by indirect immunofluorescence (IIF) in patients with pemphigus only. **Materials and Methods:** Twenty-six patients were included in the study group, out of which, 6 patients were clinically and histopathologically diagnosed as pemphigus, completely free of active lesions were subjected to IIF only to assess the disease activity and were grouped separately. Based on the clinical and provisional diagnosis, the remaining 20 patients who had active lesions were subjected to direct immunofluorescence (DIF) and IIF and were divided into four groups. Biopsy specimens were taken from the periphery of the lesions and were examined by both conventional light microscopic and DIF methods. Five milliliters of venous blood was collected from each patient and were subjected to IIF. **Results:** Histopathological diagnosis was consistent with direct immunofluorescence study in 15 cases (75%). The various immunofluorescence patterns observed in our study were consistent with those described by various authors in standard textbooks and articles. **Conclusion:** Histopathology remains gold standard for most of the diseases, it is recognized from this study that not all lesions are amenable to definitive histopathological diagnosis thus; DIF can provide a valuable additional criterion in diagnosis.

Key words: Immunofluorescence, lichen planus, pemphigus

INTRODUCTION

Oral mucocutaneous conditions are a group of disorders which are observed in the dental practice. Oral mucosal manifestations may be the initial feature, or the only sign of such diseases. In other cases, lesions occur in both the skin and mucosae, with severe clinical manifestations involving the tissues.^[1] Vesicles and bullae are clinical manifestations of several different disease processes. Correct diagnosis is critical, since proper treatment and follow-up will depend on which disease is involved. However, vesiculo-bullous lesions frequently present diagnostic problems because the lesions often resemble each other clinically and routine histological examination sometimes cannot differentiate between them.

Thus immunohistology particularly immunofluorescence is increasingly being used with routine histology to accurately diagnose vesiculo-bullous lesions. These conditions are caused by a genetic mutation or are due to an autoimmune response.

MATERIALS AND METHODS

This study was carried out in the Department of Oral Pathology, Sri Ramachandra Dental College & Hospital, Chennai. The study population consisted of 26 patients with oral mucocutaneous diseases who were selected randomly. Of the 26 patients, 6 patients were under pulse therapy who were clinically and histopathologically diagnosed as Pemphigus. These patients were free of active lesions and their disease activity was assessed by indirect immunofluorescence (IIF) who were grouped separately. Based on the clinical and provisional diagnosis, the remaining 20 patients who had active lesions were subjected to both direct immunofluorescence (DIF) and IIF and were divided into four groups. We carried out histopathology study with subsequent immunofluorescent technique to study the pattern of immunofluorescence in each group.

Access this article online**Quick Response Code:****Website:**

www.jomfp.in

DOI:

10.4103/0973-029X.86673

Biopsy specimens approximating 5–9 mm thickness were taken from the periphery of the lesions. They were immediately washed in normal saline and placed in Michel's medium and transported to the laboratory within 24 hours.

Five milliliter of venous blood was collected from each patient. Whole blood was allowed to clot, centrifuged, and the serum was separated and transported to the laboratory.

RESULTS

The study consisted of 26 patients of pemphigus, pemphigoid, lichen planus, and lupus erythematosus. They were grouped as follows:

- Group I – Pemphigus (seven cases, patients with active lesions)
- Group II – Pemphigoid (three cases)
- Group III – Lichen planus (six cases)
- Group IV – Lupus erythematosus (four cases)
- Group V – Pemphigus (six cases, patients on pulse therapy and completely free of active lesions)

Patients in Group I, II, III, and IV were subjected to histopathologic, DIF, and IIF examination, and patients in Group V were subjected to IIF alone.

Group I–V, included patients with age ranging from 28 to 60 years (42.5 years). Group I, II, and V showed male predominance and group III and IV showed female predominance. Group I–IV showed site predilection for buccal mucosa, labial mucosa, tongue, gingival, and palate.

Group – I: Histopathology showed suprabasilar cleft and acantholytic cells superficial to the basal cells which were attached to connective tissue (tombstone appearance). Both acute and chronic inflammatory cells and increased vascularity was seen within the connective tissue. Both direct and indirect immunofluorescence showed fishnet and granular pattern of fluorescence.

Group – II: Histopathology showed subepithelial split, red blood cells (RBCs) and inflammatory cells in the cleft. Diffuse chronic inflammatory cell infiltrate within the connective tissue (CT). DIF showed linear continuous band of fluorescence.

Group – III: Histopathology showed hyperparakeratosis, saw tooth retepegs and, basal cell degeneration. Dense band of chronic inflammatory cells were seen subepithelially. Subepithelial cleft was also seen in few cases. DIF showed linear deposition of fluorescence outlining the basement membrane zone (BMZ) and extending irregularly into the superficial lamina propria as shaggy pattern. IIF showed negative results.

Group – IV: Histopathology showed hyperparakeratosis, thickening of the spinous cell layer, and degeneration of basal cell layer within the epithelium. Subepithelial lymphocytic infiltration within the CT is also seen. DIF showed deposition of one or more immunoreactants in a shaggy or granular band at the BMZ. IIF showed negative results.

Charts 1 and 2 shows the reliability of DIF and IIF as a confirmatory diagnostic test in patients with pemphigus, pemphigoid, lichen planus, and lupus erythematosus.

DISCUSSION

Oral mucosal vesiculobullous and ulcerative lesions can be broadly divided into those conditions with an acute onset and a self-limiting course and those with a chronic course. In general, acute ulcerations seldom present diagnostic problems and, being self-limiting may be ignored by the patient. Chronic ulcerations, however, are often painful and persistent, causing patients to seek diagnosis and treatment. Also, they frequently present diagnostic problems because the lesions may resemble each other clinically and routine biopsies may offer histological similarities and diagnosis of nonspecific inflammation. Thus, immunofluorescence is increasingly being used with routine histology to accurately diagnose these lesions.^[2]

So, this study was conducted with an attempt to diagnose, differentiate, and detect such vesiculo-bullous and ulcerative lesions by immunofluorescence.

Pemphigus

Pemphigus shows male predilection and age above 30 years. Oral cavity was the first site to be involved in up to 70% of cases and is the only site affected in 50% of patients. Buccal mucosa was most commonly involved.^[3-5] Also, in our study

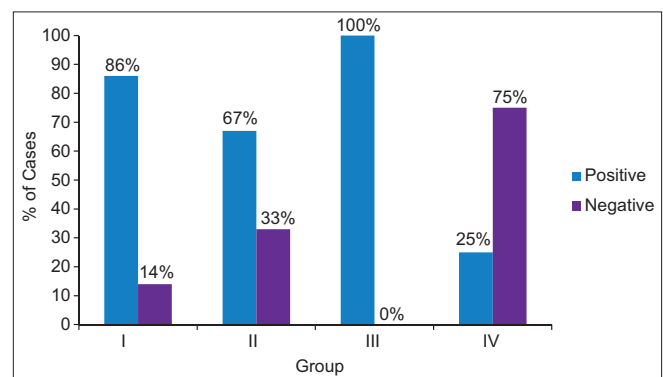


Chart 1: Direct immunofluorescence

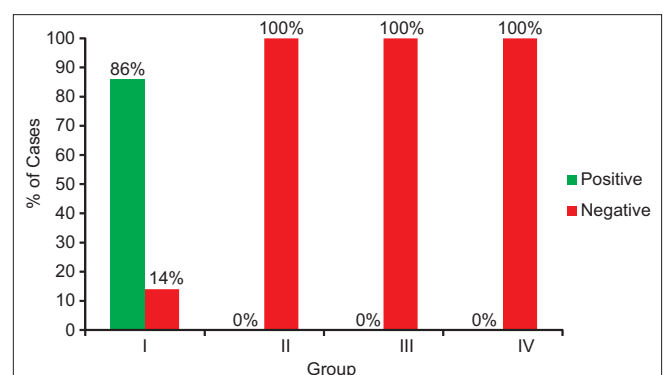


Chart 2: Indirect immunofluorescence

the clinical features were consistent with the above mentioned findings.

Williams in 1989 stated that DIF performed on perilesional tissue reveals a uniform fishnet pattern of binding of IgG localized to the intercellular spaces^[3]. Parlowsky *et al.* in 2003 stated that DIF reveals the deposition of complement (C3) and IgG, IgA, or IgM, within the intercellular spaces of epithelium resulting in a reticular pattern diagnostic of pemphigus.^[6]

In our study also, out of seven patients, six patients showed intercellular fluorescence of IgG (86%) [Figure 1], one case also showed complement (C3) (14%) [Figure 2] resulting in a fishnet or reticular pattern. One case showed negative result in which the histopathological features were nonspecific. Based upon the clinico-pathologic correlation in conjunction with negative DIF result, we suspected Behcet's syndrome. Thus DIF is essential for the diagnosis and must be performed to complement the clinical diagnosis.

Sirois, *et al* in 2000 stated that circulating antibodies (immunoglobulins) are detected in 80%–90% of patients with pemphigus vulgaris (PV). IIF performed on a monkey esophagus demonstrated the presence of circulating IgG auto antibodies that bound to the epithelium with an intercellular staining pattern.^[5] Mutasim *et al.* in 2001 stated that a punctate or granular fluorescence is appreciated at higher magnification. The pattern of fluorescence is same for all types of pemphigus.^[7] Challacombe *et al.* in 2001 stated that assay of serum antibody titers by IIF may also help to guide in prognostication and therapy.^[8]

In our study also, circulating antibodies were detected in six patients (86%), who were symptomatic. IIF performed on monkey esophagus demonstrated the presence of IgG auto antibodies bound to the epithelium with an intercellular staining pattern [Figure 3]. A punctate or granular fluorescence was well appreciated. One case showed negative result which may be due to clinicopathologic correlation of the disease as Behcet's syndrome. Six patients who were on pulse therapy for pemphigus, are completely free of lesions were grouped separately. IIF was performed to assess the disease activity and the results were negative. These negative results indicate less severity of the disease, i.e., good prognosis and helps to taper the drug dosage. This result was consistent with the results of most of the authors.

Pemphigoid

In our study, age of the patient ranged from 35 to 55 years with a mean age of 45 years. Cicatricial Pemphigoid (CP) occurs predominantly in females and bullous pemphigoid (BP) occurs in males. Most commonly involved sites of the oral cavity are buccal mucosa, labial mucosa, gingival and palate. These results were consistent with the results of most of the authors.

Challacombe *et al.* in 2001 stated that DIF using perilesional mucosa showed a linear continuous band at the BMZ usually with IgG and C3 but often with IgA in virtually 100% of patients with clinical characteristics of pemphigoid [BP and mucous membrane pemphigoid (MMP)]. DIF is essential for the diagnosis of MMP and must be performed to complement the clinical findings.^[8] Jordan *et al.* in 2002 stated that deposition of C3 in the BMZ is detected in almost all patients.^[9]

In our study also, two cases showed a linear continuous band of C3 along the BMZ (67%) [Figure 4] and one case also showed fibrin in the same location (33%) [Figure 5]. In one case, the DIF result was negative which may be attributed to the mucosal peeling of the epithelium. These results correlate with the results of above authors.

Weinberg, *et al* in 1999 reported that IIF studies are not reliable and may be negative or low in some cases. There is little correlation between the severity of the disease and the antibody titre, in contrast to Pemphigus Vulgaris in which IIF studies are diagnostic.^[10] Challacombe *et al.* in 2001 stated that the increased detection rate of circulatory antibodies by IIF may be linked to the type of substrate, since salt-split skin was shown to be significantly better than intact skin, oral mucosa, or rabbit or monkey esophagus.^[8]

In our study, IIF performed on monkey esophagus in all the three cases showed negative results which may go in accordance with the results of few authors that selection of substrate plays an important role in the detection of circulating antibodies.

Lichen planus

Like majority of authors, in our study also patients were in the age group of 30–60 years and females were more commonly affected. Buccal mucosa was the site most frequently involved and oral lesions in all the cases were bilateral.

Regezi and Scuibba in 1998 stated that DIF study demonstrated the presence of fibrinogen along the BMZ in 90%–100% of cases.^[11] Jordan *et al.* in 2002, stated that LP show a characteristic pattern of fibrinogen deposition outlining the BMZ and extending irregularly into the superficial lamina propria, described as shaggy or fibrillar pattern. A fine granular deposition of C3 is frequently seen in BMZ.^[8] In our study also, all the cases showed deposition of fibrinogen along the BMZ (100%). Out of six, one case showed the characteristic pattern of fibrinogen deposition outlining the BMZ and extending irregularly into the superficial lamina propria as shaggy pattern [Figure 6], four cases showed linear deposits of fibrin along the BMZ [Figure 7], and one case showed granular deposition of fibrin along the BMZ. Thus DIF can be used as an additional diagnostic tool for lichen planus.

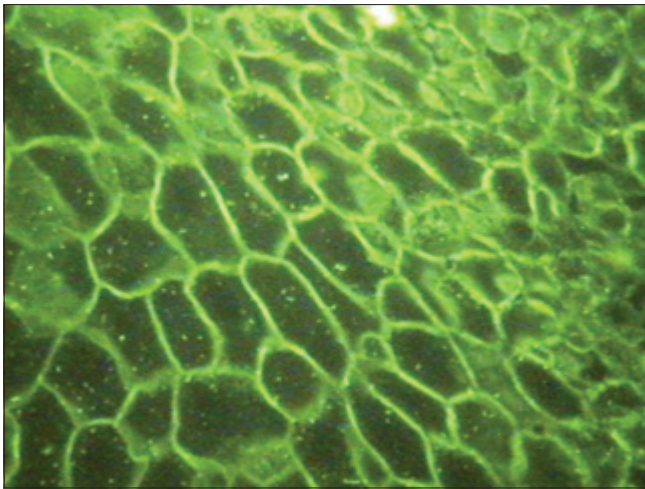


Figure 1: Intercellular space deposition of IgG in the epithelium (DIF) pemphigus

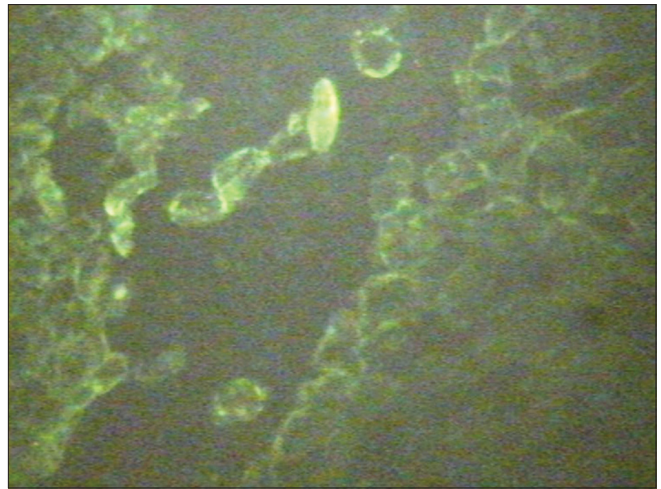


Figure 2: Complement (C3) found scattered in the wall of the bullae (DIF) pemphigus

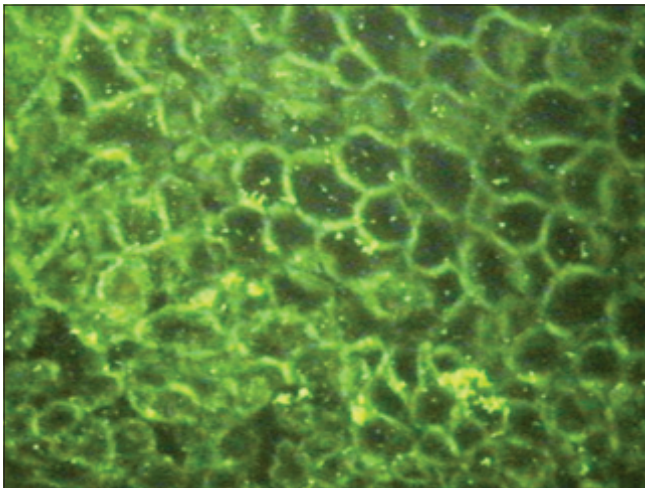


Figure 3: Granular fluorescence of IgG in the intercellular space of spinosum (IIF) pemphigus

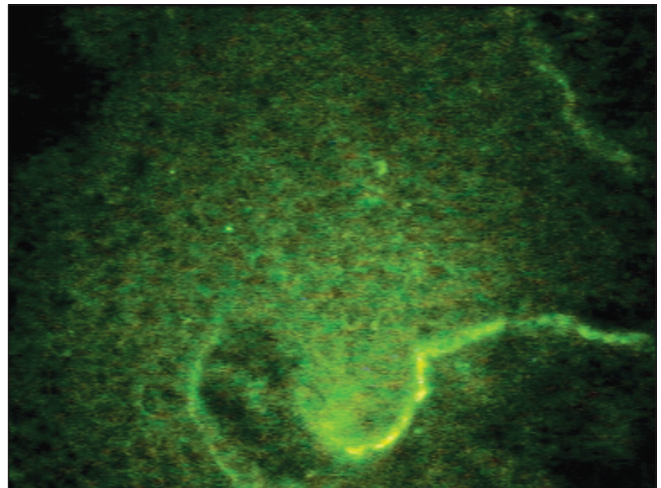


Figure 4: Linear and continuous band of C3 deposit along the basement membrane zone (BMZ) (DIF) pemphigoid

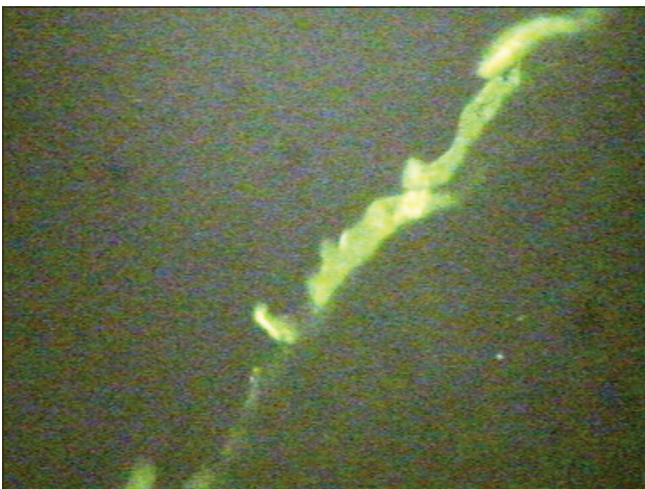


Figure 5: Linear deposits of fibrin along the BMZ (DIF) pemphigoid

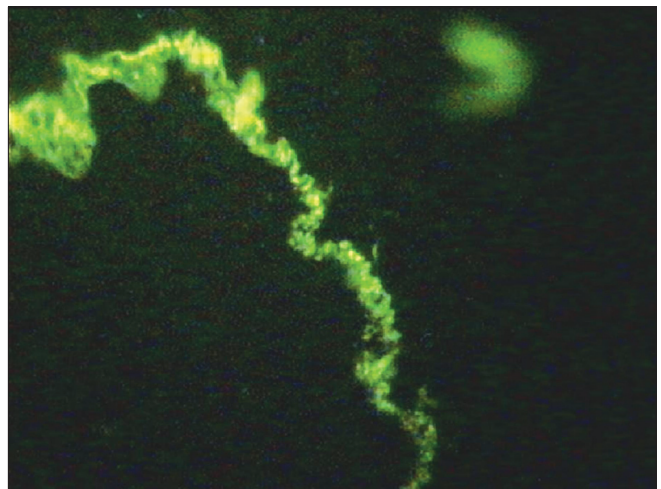


Figure 6: Fibrin deposition along the BMZ extending as irregular strands into the superficial lamina propria (DIF)

IIF may be a useful test if results of histopathologic and DIF examinations are not specific. It was reported that none of the oral lesions showed the characteristic pattern of staining for

Lichen planus specific antigen (LPSA) by IIF. In our study, all the patients showed negativity for IIF.

Lupus Erythematosus

Systemic lupus erythematosus

In our study, both the cases of systemic lupus erythematosus (SLE) occurred in the age group of 20–30 years and both were females. Malar region was involved in only one case. Orally both the cases showed occurrence in the labial mucosa and one case also occurred in the buccal mucosa.

In our study of two cases of SLE, butterfly distribution over the malar region was seen in one case. In both the cases, generalized manifestations such as oral ulcers, GIT abnormalities, arthritis, and CNS abnormalities were present.

Histopathologically, oral lesions of SLE are characterized by hyperkeratosis, alternating atrophy, thickening of the spinous cell layer, and degeneration of basal cell layer within the epithelium. Subepithelial lymphocytic infiltration within the CT is also an important finding.^[12]

In our study, both the cases showed nonspecific histopathologic features. In one case, in which the patient had malar rash and

ANA test was positive, the epithelium was denuded and the deeper stroma showed infiltration by lymphocytes. In other case, the histopathologic features showed acanthosis and slight edema in focal areas in the basal layer. Subepithelial zone showed dense collection of lymphocytes.

DIF testing of lesional tissue shows deposition of one or more immunoreactants (usually IgG, IgM, OR C3) in a shaggy or granular band at the BMZ.^[7] In our study, DIF results for both the cases were negative. These findings may be attributed to inadequate or nonrepresentative specimen sampling.

Approximately 95% of these patients have antibodies directed against multiple nuclear antigens (antinuclear antibodies). Although this is a nonspecific finding, it is useful as a screening study. Antibodies directed against double stranded DNA are noted in 70% patients with SLE and are more specific for the disease.^[7] According to the results of our study, we could conclude that, in SLE cases apart from DIF, the diagnosis should be confirmed by ANA and double stranded DNA test only.

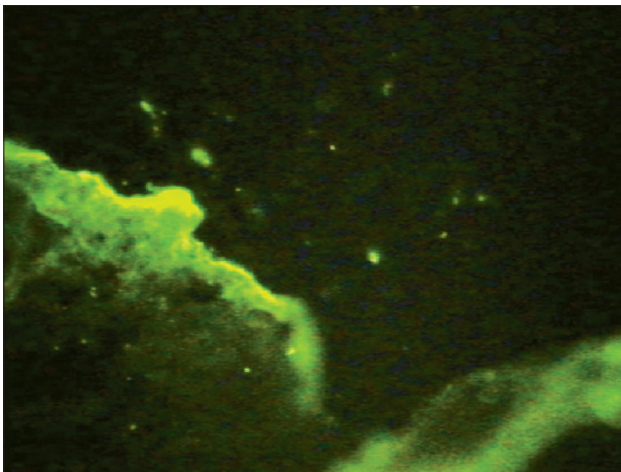


Figure 7: Linear deposits of fibrin along the BMZ (DIF)

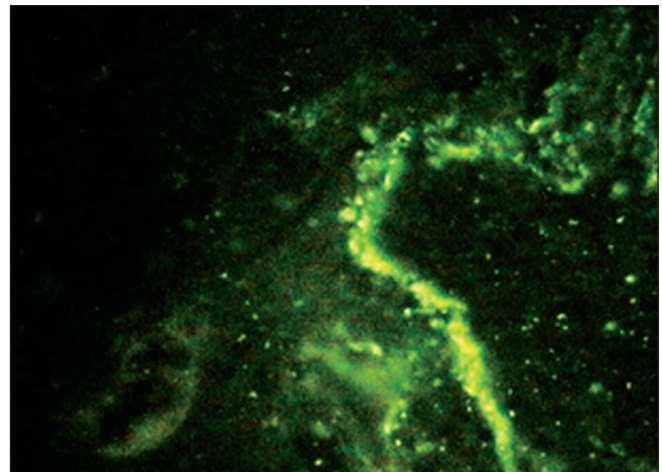


Figure 8: Linear deposition of IgG along the BMZ (DIF)

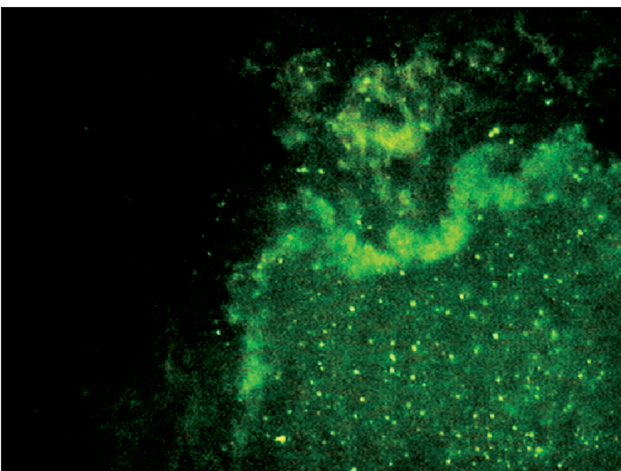


Figure 9: Linear deposition of C3 along the BMZ (DIF)

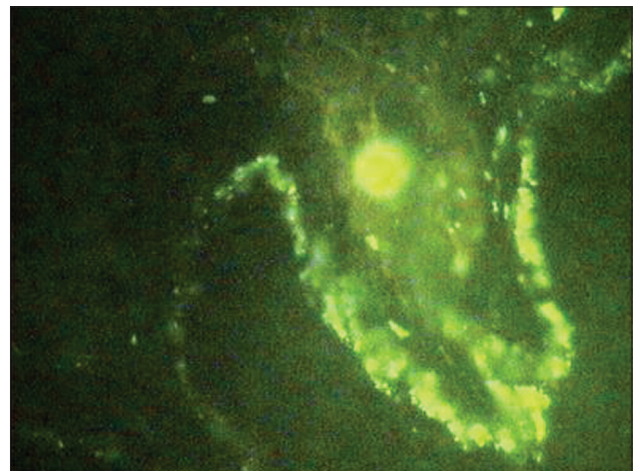


Figure 10: Linear deposition of IgM along the BMZ (DIF)

Discoid lupus erythematosus

In our study of two cases of DLE, one patient is a male aged 32 years and the other is a female aged 29 years. The discoid form of the disease may also assume a typical “butterfly” distribution on the malar regions across the bridge of the nose. In our study, either of the two cases showed this appearance. Vermillion border of the lower lip was involved in both the cases showing painful ulceration due to the crusting or bleeding which is a characteristic of DLE.

In our study of two cases of DLE, only in one case the histopathologic features are suggestive of DLE, showing features of hyperkeratosis, acanthosis, focal areas of liquefaction degeneration of basal layer, and basal zone shows deposits of PAS positive material. Subepithelial areas show focal collection of dense chronic inflammatory cell infiltrate. In another case, the histopathology features were suggestive of actinic cheilitis showing atrophic stratified squamous epithelium, subepithelial zone of mild chronic inflammatory cells and a band of amorphous, a cellular, basophilic change known as solar elastosis.

DIF testing of lesional tissue shows deposition of one or more immunoreactants (usually IgG, or C3) in a shaggy or granular band at the BMZ. Deposition of IgG and IgM along BMZ is seen in 50%–90% of cases. Complement components are present less frequently.^[12,13]

In our study also, DIF testing of one case showed granular deposits of IgG, C3 and faint deposits of IgM along the BMZ (25%) [Figures 8–10]. Thus, DIF can be used as an additional diagnostic tool. DIF of another case showed negative results which was histopathologically suggestive of actinic cheilitis.

Few authors reported that in the recent years, substrate selection also plays a major role in the detection of circulating antibodies. IF performed on human skin showed superior results when compared to oral mucosa. In our study, IIF performed on monkey esophagus substrate in all four cases of lupus erythematosus showed negative results which may be attributed to substrate selection.^[14]

CONCLUSION

Although histopathology remains gold standard for most of the diseases, it is recognized from this study that not all lesions are amenable to definitive histopathological diagnosis.

DIF can provide a valuable additional criterion in diagnosing chronic, ulcerative or erosive diseases of oral mucosa if the biopsy specimens are taken from appropriate sites and have attached epithelium. However, the consistency of DIF cannot

be substantiated due to limited sample size which is attributed to cost effectiveness.

IIF can be used to detect circulating autoantibody in the blood which it does in approximately 80% of patients with pemphigus vulgaris. A negative result, however, does not exclude a diagnosis of PV. While monitoring the circulating pemphigus autoantibody titers via IIF is not an essential part of the diagnosis of PV, it is useful in assessing therapeutic response and predicting relapse.

REFERENCES

- Ramírez-Amador VA, Esquivel-Pedraza L, Orozco-Topete R. Frequency of oral conditions in a dermatology clinic. *Int J Dermatol* 2000;39:501-5.
- Daniels TE, Quadra-White C. DIF in oral mucosal disease; diagnostic analysis of 130 cases. *Oral Surg Oral Med Oral Pathol* 1981;51:38-54.
- Williams DM. Vesiculobullous mucocutaneous disease: Pemphigus vulgaris. *J Oral Pathol Med* 1989;18:544-53.
- Robinson JC, Lozada-Nur F. Ilonafrieden: Oral pemphigus vulgaris. *Oral Surg Oral Med Oral Pathol* 1997;84:349-55.
- Sirois D, Leigh JE, Sollecito TP. Oral pemphigus vulgaris preceding cutaneous lesions: Recognition and diagnosis. *J Am Dent Assoc* 2000;131:1156-61.
- Parlowsky T, Welzel J. Neonatal pemphigus vulgaris: IgG4 autoantibodies to desmoglein 3 induce skin blisters in new born. *J Am Acad Dermatol* 2003;48:623-57.
- Mutasim DF, Adams BB, Cincinnati. Immunofluorescence in dermatology. *J Am Acad Dermatol* 2004;45:803-22.
- Challacombe SJ, Setterfield J, Shirlaw P, Harman K, Scully C, Black MM. Immunodiagnosis of pemphigus and mucous membrane pemphigoid. *Acta Odontol Scand* 2001;59:226-34.
- Jordan RC, Daniels TE, Greenspan JS, Regezi JA. Advanced diagnostic methods in oral and maxillofacial pathology. Part II: Immunohistochemical and immunofluorescent methods. *Oral Surg Oral Med Oral Pathol Oral Radiol Endod* 2002;93:56-74.
- Weinberg MA, Insler MS, Campen RB. Mucocutaneous features of auto immune blistering diseases. *Oral Surg Oral Med Oral Pathol* 1997;84:517-34.
- Regezi and Sciubba. *Oral pathology: Clinical pathologic correlations*. 2nd ed. Missouri: W. B. Saunders Company; 1989. p. 105-10.
- Neville BW, Damn DD, Allen CM, Bouquot JE. *Oral and Maxillofacial Pathology*. 2nd ed. Philadelphia, WB Saunders; 2002. p.541-93.
- Shafer, Hine, Levy. *Diseases of the skin*. In: Shafer, Hine, Levy, editors. *A text book of Oral Pathology*. 4th ed. Philadelphia: WB Saunders Company; 1993. p. 806-53.
- Chan LS, Lapiere JC, Chen M, Traczyk T, Mancini AJ, Paller AS, et al. Bullous systemic lupus erythematosus with autoantibodies recognizing multiple skin basement membrane components, bullous pemphigoid antigen 1, laminin-5, laminin-6, and type VII collagen. *Arch Dermatol* 1999;135:569-73.

How to cite this article: Anuradha CH, Malathi N, Anandan S, Magesh KT. Current concepts of immunofluorescence in oral mucocutaneous diseases. *J Oral Maxillofac Pathol* 2011;15:261-6.

Source of Support: Nil. **Conflict of Interest:** None declared.