

## RESEARCH ARTICLE

# Differences in bleeding patterns and outcome after intracerebral hemorrhage due to vascular malformations

Nazife Dinc<sup>1\*</sup>, Sae-Yeon Won<sup>1</sup>, Nina Brawanski<sup>1</sup>, Michael Eibach<sup>1</sup>, Johanna Quick-Weller<sup>1</sup>, Jürgen Konzalla<sup>1</sup>, Joachim Berkefeld<sup>2</sup>, Volker Seifert<sup>1</sup>, Gerhard Marquardt<sup>1</sup>

**1** Department of Neurosurgery, Goethe University Hospital, Frankfurt, Germany, **2** Department of Neuroradiology, Goethe University Hospital, Frankfurt, Germany

\* [nazife.dinc@kgu.de](mailto:nazife.dinc@kgu.de)



## Abstract

### Background

Atypical intracerebral hemorrhage is a common form of primary manifestation of vascular malformations.

### Objective

The aim of the present study is to determine clues to the cause of bleeding according to hemorrhage pattern (lobar, basal ganglia, infratentorial).

### Methods

We retrospectively evaluated 343 consecutive neurosurgical patients with intracerebral hemorrhage (ICH), who were admitted to our neurosurgical department between 2006 and 2016. The study cohort includes only neurosurgical patients. Patients who underwent treatment by neurologists are not represented in this study. We assessed location of hemorrhage, hematoma volumes to rule out differences and predictive variables for final outcome.

### Results

In 171 cases (49.9%) vascular malformations, such as arteriovenous malformations (AVMs), cavernomas, dural fistulas and aneurysms were the cause of bleeding. 172 (50.1%) patients suffered from an intracerebral hemorrhage due to amyloid angiopathy or long standing hypertension. In patients with infratentorial hemorrhage a malformation was more frequently detected as in patients with supratentorial hemorrhage (36% vs. 16%, OR 2.9 [1.8;4.9],  $p < 0.001$ ). Among the malformations AVMs were most common (81%). Hematoma expansion was smaller in vascular malformation than non-malformation caused bleeding (24.1 cm<sup>3</sup> vs. 64.8 cm<sup>3</sup>, OR 0.5 [0.4;0.7],  $p < 0.001$ ). In 6 (2.1%) cases diagnosis remained unclear. Final outcome was more favorable in patients with vascular malformations (63% vs. 12%, OR 12.8 [4.5;36.2],  $p < 0.001$ ).

## OPEN ACCESS

**Citation:** Dinc N, Won S-Y, Brawanski N, Eibach M, Quick-Weller J, Konzalla J, et al. (2019) Differences in bleeding patterns and outcome after intracerebral hemorrhage due to vascular malformations. PLoS ONE 14(5): e0217017. <https://doi.org/10.1371/journal.pone.0217017>

**Editor:** Stephan Meckel, Universitätsklinikum Freiburg, GERMANY

**Received:** December 12, 2018

**Accepted:** May 2, 2019

**Published:** May 23, 2019

**Copyright:** © 2019 Dinc et al. This is an open access article distributed under the terms of the [Creative Commons Attribution License](https://creativecommons.org/licenses/by/4.0/), which permits unrestricted use, distribution, and reproduction in any medium, provided the original author and source are credited.

**Data Availability Statement:** All relevant data are within the paper and its Supporting Information files.

**Funding:** The authors received no specific funding for this work.

**Competing interests:** The authors have declared that no competing interests exist.

## Conclusion

Localization and bleeding patterns are predictive factors for origin of the hemorrhage. These predictive factors should quickly lead to appropriate vascular diagnostic measures. However, due to the inclusion criteria the validity of the study is limited and multicentre studies with further testing in general ICH patients are required.

## Introduction

Intracerebral hemorrhage (ICH) harbors a mortality rate of up to 50% within the first 30 days. [1,2] Early and aggressive care has an enormous impact on outcome [3,4] and magnetic resonance angiography (MRA) and computed tomography angiography (CTA) are sensitive and required methods for identifying the cause of hemorrhage, such as arteriovenous malformations (AVMs), sinus thrombosis, tumors or moyamoya diseases. [5,6] Digital subtraction angiography (DSA) is considered to be most sensitive in verification of a suspected vascular malformation. Hypertensive blood pressure conditions or amyloid angiopathy are common causes for spontaneous intracerebral hemorrhage. Beside the high rate of mortality and morbidity with high lifetime costs, cognitive impairment and depression appear frequently in patients with spontaneous ICH. [7,8] Other causes for ICH are vascular pathologies, including AVMs. The annual bleeding risk of AVMs amounts 1% to 4% and mostly affects young patients. [2,9,10] Outcome after AVM hemorrhage seems to be more favorable in comparison to the outcome after sICH [11,12], depending on patient characteristics, bleeding patterns, hemodynamic features and hemorrhage size. The aim of our study is to align these predictive factors, which imply bleeding source.

## Methods

### Study design

Patients were recorded in our prospectively maintained database and analyzed retrospectively. The local ethical review board (ethic committee of the Goethe University Hospital Frankfurt, EK No 545/15) approved this study. Since the study design is retrospective, no written consent was provided and necessary by the patients.

All adult patients with intracerebral hemorrhage who were admitted to our department of neurosurgery between January 2006 and April 2016 were considered eligible. Patients with traumatic brain injury, subarachnoid hemorrhage without a hematoma clot, hemorrhage due to a tumor or patients who did not receive angiographic imaging and patients who were admitted to the neurological department were not included in the study analyses. Therefore the study cohort is preselected in only including patients with ICH hemorrhage who were admitted to our neurosurgical department. A considerable number of patients who underwent treatment by neurologists are not represented in this study. MRA, CTA or DSA were required imaging methods for study inclusion criteria. Patient characteristics, such as neurological score at admission (based on the Glasgow Coma Scale: GCS [13]), gender, age, bleeding pattern (subarachnoid hemorrhage: SAH, intraventricular hemorrhage: IVH, intracerebral hemorrhage: ICH), hematoma volume, the use of antiplatelet drugs [AC], history of persistent arterial hypertension [HTN] were recorded and evaluated. Neurological score at admission was assigned to the following groups: good admission state (GCS 13–15) and poor admission state (GCS <7–12). Outcome was measured based on the modified Rankin Scale (mRS) at

discharge and follow up visits after 6 months and stratified as mRS 0–2: favorable vs. mRS 3–6 unfavorable. Table 1 and Fig 1 represent inclusion and exclusion criterias and breakdown of the study cohort.

## Radiological characteristics

Imaging was performed and interpreted by an experienced neuroradiologist. All study patients underwent angiographic imaging for diagnostic purpose. Atypical bleeding pattern were summarized as non-traumatic, non-aneurysmal, non-tumorous bleeding. Hematoma location was registered and classified into supratentorial, infratentorial, lobar and as basal ganglia hemorrhage (Table 2). The bleedings were divided into spontaneous hemorrhages without an underlying vascular malformation (sICH) and hemorrhages due to a vascular malformation (vmICH). Characteristics and type of vascular malformations (AVM, Cavernoma, dural arteriovenous fistula: dAVF, aneurysms) were evaluated. AVMs were graduated according to the Spetzler-Martin classification. The hematoma volume and patient age were evaluated to establish a cut off value of volume and age related to bleeding origin and poor outcome. The CT and MRA scans at admission were used for computer-assisted volumetric measurements. The method was used by an independent clinician. For computer-assisted hematoma volume measurement, the BrainLab elements software (BrainLab Germany Headquarters, Munich, Germany) was used.

## Treatment

The treatment algorithm of intracerebral hemorrhage at our neurosurgical department is as follows: Usually, first admission setting is the closest facility or the emergency department. Patients get transfer to our neurosurgical department when intracerebral hemorrhage was already carried out via brain scan (CT or MRI). The primary objective in our neurosurgical setting is to check and support cardiovascular and ventilatory conditions. Secondary priorities include i.a. medical history, hemostatic abnormalities and medication. Based on interdisciplinary consensus medical management, particularly blood pressure management is carried out at the intensive care unit.[3,6] Continuous cardiopulmonary monitoring including cycled

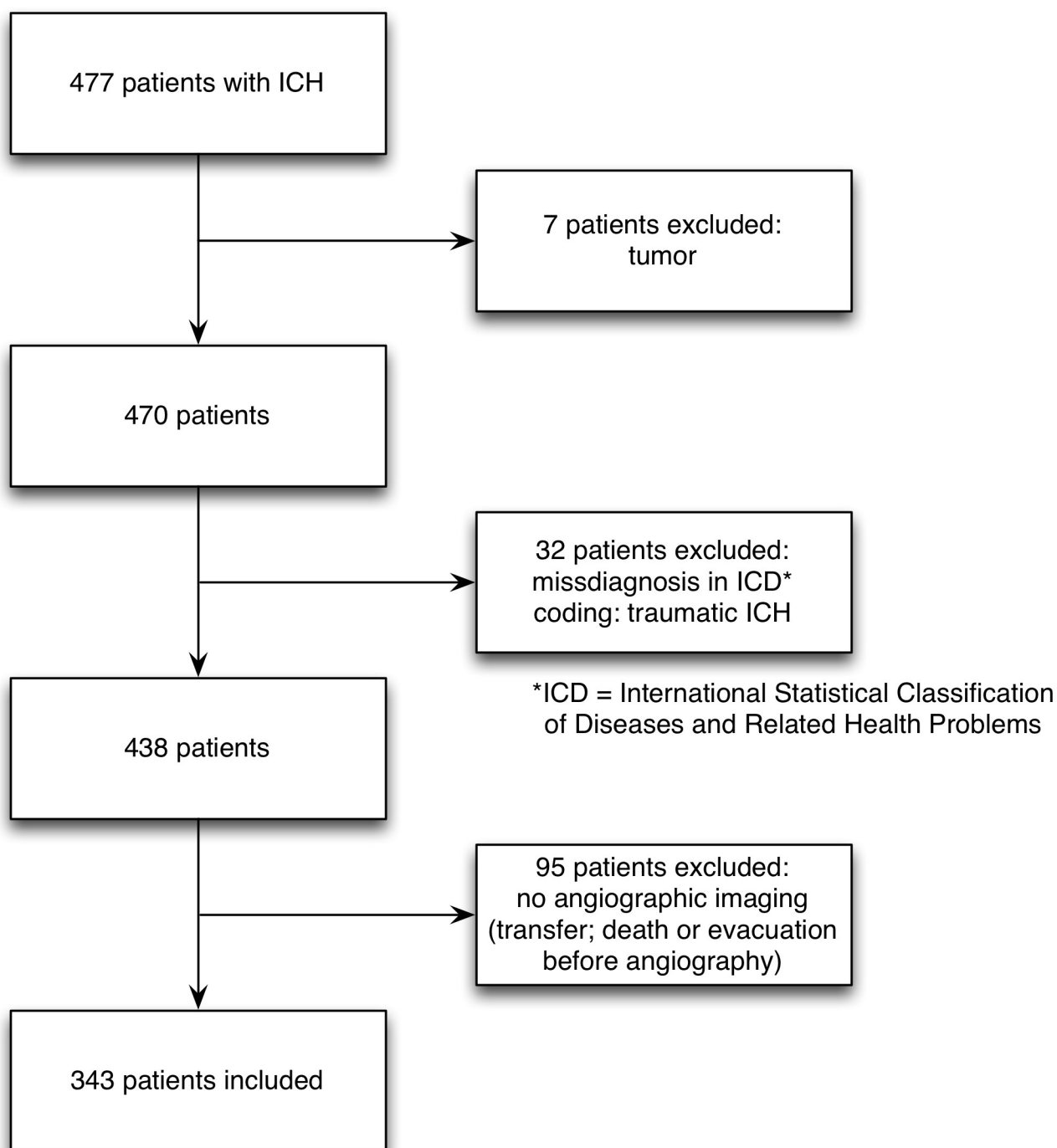
**Table 1. The inclusion and exclusion criteria for the study cohort.**

Inclusion criteria	
1	Age 18 years or older
2	Spontaneous intracerebral hemorrhage
3	Complete data (GCS, follow up/mRS)
4	Angiographic imaging (CTA, MRA, or DSA)
Exclusion criteria	
5	Traumatic hemorrhage (SDH, EDH, traumatic SAH)
6	Isolated SAH (aneurysmal SAH)
7	Incomplete data (GCS, follow up/mRS)
8	Previously known neoplasm or vascular malformation
9	Reliable angiographic imaging can not be performed (due to short-term hospital stay or urgent hematoma evacuation before angiographic imaging)

GCS = Glasgow coma scale; SDH = subdural hematoma; EDH = epidural hematoma, SAH = subarachnoid hemorrhage

<https://doi.org/10.1371/journal.pone.0217017.t001>

## Breakdown of 477 patients in the study cohort



**Fig 1. Flowchart for patients selection.** Flowchart demonstrating the breakdown of 477 patients in the ICH database. 343 patients were enrolled for analysis.

<https://doi.org/10.1371/journal.pone.0217017.g001>

Table 2. Patient characteristics and predictors for vmICH in univariate and multivariate analysis.

Factors	vmICH 171(%)	sICH 172(%)	Univariate analysis		Multivariate analysis	
			OR 95%CI	p value	OR 95% CI	p value
Female	82(48)	86(50)	NS	NS	NS	NS
Male	89(52)	86(50)	-	-	-	-
< 50 years (y)	92(54)	27(16)	6.3(3.8;10.4)	<0.001	4.1(1.8;9.2)	0.001
Mean age (y)	47	63	-	-	-	-
GCS (13–15)	119(70)	51(30)	4.8(2.9;7.9)	<0.001	3.3(1.7;6.3)	<0.001
mRS 0–2**	108(63)	20(12)	11.7(6.6;20.9)	<0.001	12.8(4.5;36.2)	<0.001
HTN*	43(25)	97(56)	0.3(0.2;0.4)	<0.001	NS	NS
Anticoagulation	16(9)	58(34)	0.2(0.1;0.4)	<0.001	0.3 (0.1;0.7)	0.004
ICH location			2.7(1.6;4.6)	<0.001	3.1 (1.6;6.3)	<0.001
Supratentorial	109(64)	144(84)	0.3(0.2;0.6)	<0.001	-	-
Lobar	90(83)	104(72)	-	-	-	-
Deep ganglia	19(17)	40(28)	-	-	-	-
Infratentorial	62(36)	28(16)	2.9(1.8;4.9)	<0.001	-	-
IVH	65(38)	82(48)	NS	NS	NS	NS
Spot sign	22(13)	34(20)	NS	NS	NS	NS
Volume (cm <sup>3</sup> )	24.1	64.8	0.2 (0.1;0.3)	<0.001	0.5 (0.4;0.7)	0.001

\* Chi square Test

\*\*47 patients got lost to follow up, final outcome was available for 296 patients.

<https://doi.org/10.1371/journal.pone.0217017.t002>

automated blood pressure cuff, electrocardiographic telemetry and pulse oxymetry is provided. Intra-arterial monitoring is considered in patients receiving intravenous vasoactive drugs. Since the study period amounts approximately 10 years, ICH guidelines changed within this period. The quality and availability of brain imaging has increased even in non-specialized facilities and patients were transferred more quickly to neurosurgical centers. In particular, due to the rising use of new anticoagulant agents [3] medical treatment for normalization of hemostasis and the use of antidots changed. Furthermore according to the current guidelines for the management of ICH [14,15] urgent treatment such as decompressive craniectomy or hematoma evacuation is necessary in the presence of a space demanding hemorrhage, midline shift or loss of consciousness. Patients with basal ganglia hemorrhage or small hematoma volume in good clinical condition receive medical management. Patients with intraventricular hemorrhage receive an external ventricular drain. Secondary we performed a scan with angiogram (CTA/MRA) 4 to 6 hours later to capture hematoma expansion and detect bleeding origin. A catheter angiogram is considered if radiological and clinical suspicion of an underlying vascular cause is high or if vascular malformation is confirmed in CTA or MRA. When a vascular malformation is detected, the malformation will be treated by microsurgery, endovascular occlusion, radiosurgery, combined or conservatively, based on interdisciplinary consensus. In selected cases treatment of vascular malformations was performed after sufficient rehabilitation, e.g. 4 weeks after the ictus.

### Statistics

Statistical analysis was performed using the statistical software package SPSS (IBM SPSS Statistics for Windows, Version 22; Armonk, New York, USA. IBM Corp.) and the statistical software package BIAS (Version 11.08). Categorical variables were analyzed in contingency tables

using the Fisher exact test, an unpaired t-test was used for parametric statistics. For univariate analysis statistical significance was set at  $p < 0.05$ . Variables with a possible association with a vascular malformation ( $p < 0.1$ ) were entered into a forward stepwise multiple logistic regression analysis. The prognostic value of age and hematoma volume between the two groups was captured by calculating the area under the receiver operating characteristic (ROC) curve, which is a plot of sensitivity of predictions against 1-specificity of predictions. An area under the curve (AUC) of 0.5 indicates no discrimination between the two groups, and an area of 1.0 indicates perfect discrimination.[16]

## Results

### Patient characteristics

We evaluated 343 patients. The study group consisted of 168 women and 175 men with a mean age at first presentation of 55 years (range 19–89). Clinical data and radiological findings considering differences in bleeding origin are summarized in Table 2. In 172 patients a sICH could be detected, 171 patients suffered an ICH due a ruptured vascular malformation. 170 (49.6%) patients showed a good admission state (GCS 13–15) and 173 (50.4%) patients showed a severe ICH (GCS  $< 7$ –12). Patients with a vascular malformation were younger on average (mean: 47 years vs. 63 years; OR 4.1 [1.8;9.2];  $p < 0.0001$ ) and mostly in a better condition at admission than patients with sICH (OR 3.3 [1.7;6.3];  $p < 0.0001$ ). Young age seems to be a statistical significant predictor for an underlying vascular malformation in patients with ICH. A cut off value of less than 55.5 years was calculated for patients with a vascular malformation (AUC = 0.7; 95%CI = [0.69;0.79],  $p < 0.0001$ ). Patients with a vascular malformation rarely had hypertension (OR 0.3 [0.2;0.4];  $p < 0.0001$ ) and the use of antiplatelet drugs (OR 0.3 [0.1;0.7];  $p < 0.004$ ) was less common.

### Radiological findings and Vascular Malformation features

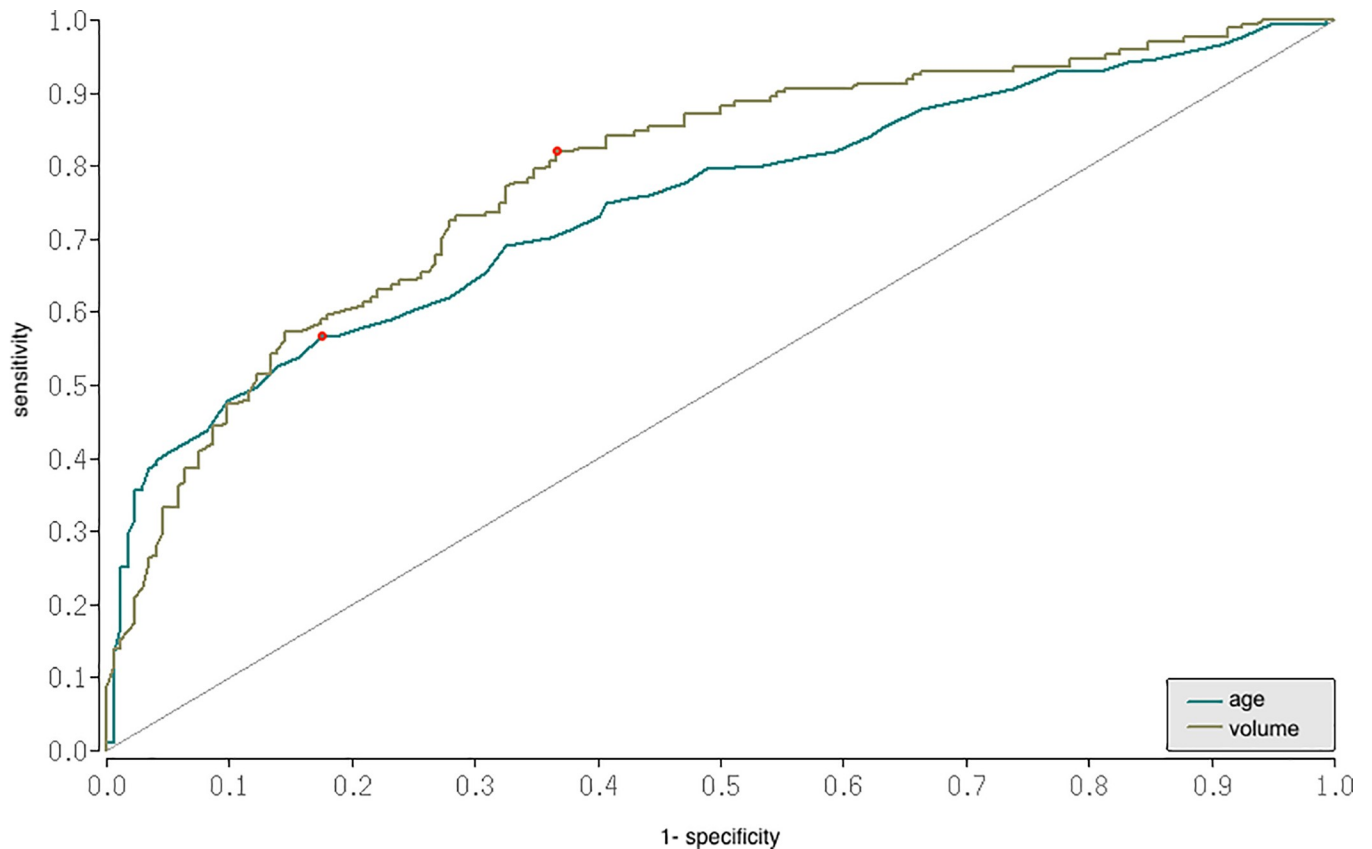
Table 3 depicts the rate and classification of Vascular Malformations (VM). Arteriovenous malformations were the most common cause of vmICH. AVMs were detected in 138 (81%) patients, 70 (51%) AVMs were Spetzler Martin Grade I-II, 55 (40%) AVMs were Spetzler Martin Grade III and 13 (9%) AVMs were Spetzler Martin Grade IV-V. In 18 (10%) patients

**Table 3. Rate and classification of Vascular Malformations: Radiologic findings.**

	No of patients N = 171 (%)
Cavernous malformation	18 (10)
AVM	138 (81)
Spetzler Martin I-II	70 (51)
Spetzler Martin III	55 (40)
Spetzler Martin IV-V	13 (9)
dAVF	9 (5)
Aneurysm	6 (4)
ICA right	2
AcomA	1
MCA right	1
ICA left	1
MCA left	1

ICA = internal carotid artery; AcomA = anterior communicating artery; MCA = middle cerebral artery

<https://doi.org/10.1371/journal.pone.0217017.t003>



**Fig 2. ROC curves for prediction of age and volume.** Receiver operating curves for prediction of age and volume as diagnostic suitable variables for vascular malformations. Patients with vascular malformations were younger. The ROC curve for age yielded an AUC value of 0.7 (95%CI = 0.69;0.79),  $p < .0001$ ;  $p = 0.001$  with a cut off value of 55.5 years. The ROC curve for volume yielded an AUC value of 0.8 (95%CI 0.53 [0.4;0.7];  $p = 0.001$ ) with a cut off value of 35.6  $\text{cm}^3$ . ROC = Receiver Operating Characteristic.

<https://doi.org/10.1371/journal.pone.0217017.g002>

Cavernomas were found, in nine (5%) patients dural AVFs, and six (4%) patients were affected due to a ruptured aneurysm.

sICH was more common supratentorial and more often located in the basal ganglia than vmICH, whereas in infratentorial hemorrhage a vascular malformation was the most common cause of bleeding. (OR 3.1 [1.6;6.3];  $p < 0.0001$ ). Hematoma volume was significant larger in sICH than in vmICH. The ROC curve (Fig 2) yielded an AUC of 0.8 (OR 0.53 [0.4;0.7];  $p = 0.001$ ) with a cut off value of 35.6  $\text{cm}^3$  for bleeding origin.

### Urgent surgery

Urgent treatment such as decompressive craniectomy or hematoma evacuation was necessary in 139 patients (Table 4), mostly due to sICH 93(67%). Such a measure was required in 43 patients with vmICH 46(33%) (OR 3.2 [2.0; 5.0];  $p < 0.001$ ).

**Table 4. Urgent surgery and mortality rate.**

	sICH (%)	vmICH (%)	95% CI	<i>p</i> Value *
Urgent surgery <i>N</i> = 139	93 (67)	46 (33)	3.2 (2.0;5.0)	<0.001
Overall mortality <i>N</i> = 39	28 (72)	11 (28)	2.8 (1.4;5.9)	0.006

\*Chi square

<https://doi.org/10.1371/journal.pone.0217017.t004>

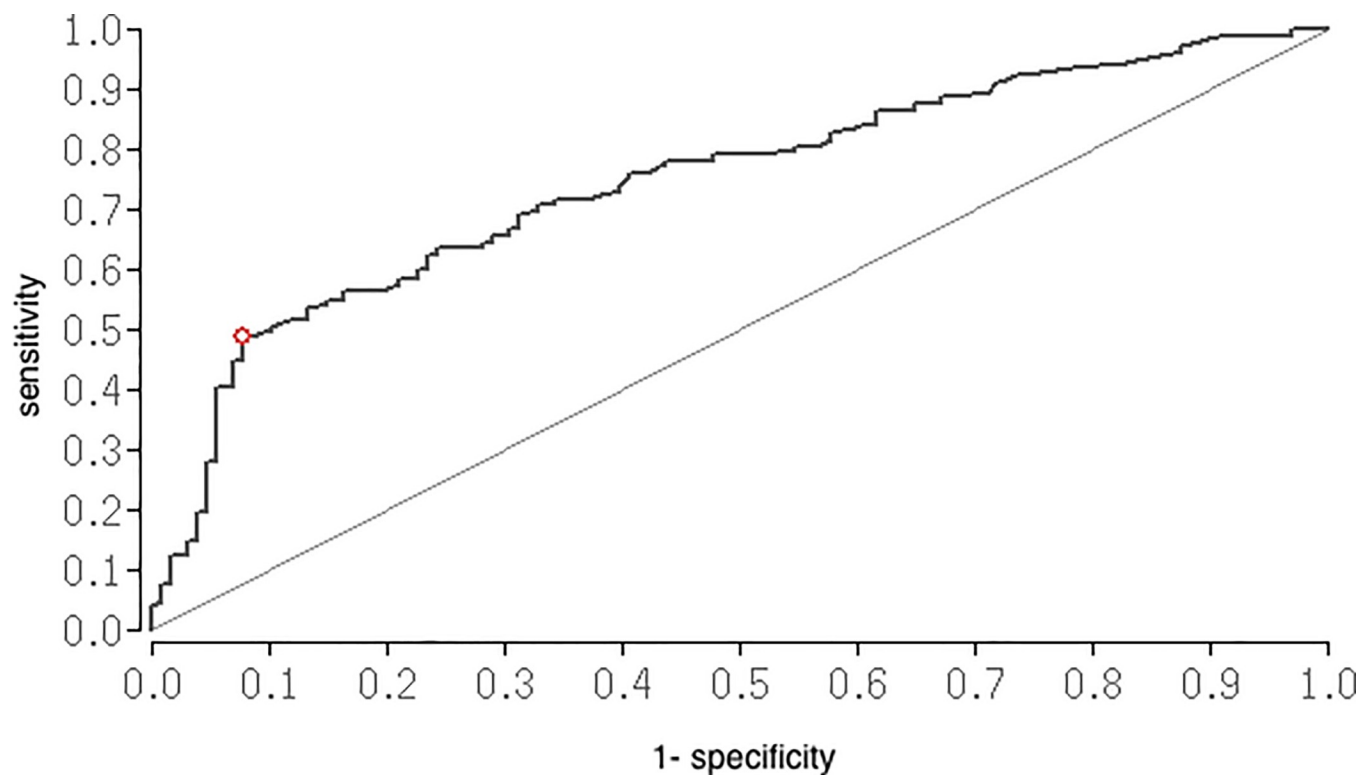
**Table 5. Rate of antiplatelet drugs and association to hematoma volume.**

	No N = 74 (%)	Mean hematoma volume (cm <sup>3</sup> )
Acetylsalicylic acid + Clopidogrel	5 (7)	65.1
Acetylsalicylic acid	29 (39)	62.8
Phenprocoumon	39 (53)	46.9
Rivaroxaban	1 (1)	42.0

<https://doi.org/10.1371/journal.pone.0217017.t005>

### Overall outcome and predictors for poor outcome in Multiple Logistic Regression analysis

Table 5 summarizes the rate of antiplatelet drugs, which were used by our study patients. Patients with antiplatelet drugs had a hematoma volume more than 30cm<sup>3</sup> in 63.5% of cases compared with patients without antiplatelet drugs (40.9%). The use of antiplatelet drugs significantly led to a hematoma volume more than 30cm<sup>3</sup> (OR 2.5 [1.48; 4.28]; p = 0.0006) and predicted primary outcome in univariate analysis (OR 3.19[1.69; 6.00]; p = 0.0001). Patients with the use of Acetylsalicylic acid and Clopidogrel had the highest hematoma volume on average. In ROC analysis, we identified a cut-off value of 45.9cm<sup>3</sup> hematoma volume to predict outcome. The ROC curve (Fig 3) yielded an AUC of 0.8 (95%CI [0.69;0.80]; p<0.0001). Therefore we performed an univariate and multivariate logistic regression analysis to identify independent prognostic variables. In multivariate analysis poor admission state, hematoma volume and bleeding origin were independent predictors for poor outcome. Patients with vascular



**Fig 3. ROC for prediction of hemorrhage volume.** Receiver operating curves for prediction of volume as diagnostic suitable variables for final outcome. The ROC curve yielded an AUC value of 0.8 (95%CI = 0.69; 0.80); p<0.0001 with a cut off value of 45.9cm<sup>3</sup>. ROC = Receiver Operating Characteristic.

<https://doi.org/10.1371/journal.pone.0217017.g003>



Table 6. Univariate and multivariate analysis for primary favorable outcome.

Factors	Univariate analysis		Multivariate analysis	
	OR (95% CI)	p Value	OR (95% CI)	p Value
Age	0.3 (0.2;0.5)	<0.001	3.2 (1.9;5.6)	0.143
HTN	0.3 (0.2;0.5)	<0.001	1.6 (1.05;2.4)	0.965
Anticoagulation	3.19 (1.7;6.0)	<0.001	7.4 (2.9;18.7)	0.405
GCS	14.8 (7.7;28.4)	<0.001	13.16 (7.29;23.73)	<0.001
Vascular malformation	11.7(6.6;20.9)	<0.001	9.3 (4.5;19.5)	<0.001
Volume	0.2 (0.1;0.4)	<0.001	0.19 (0.11;0.31)	<0.001
IVH	2.1 (1.2;3.5)	0.01	0.6 (0.2;1.6)	NS
Urgent treatment	11.0 (5.9;20.4)	<0.001*	2.4(1.1;5.1)	0.02

\*Chi square

<https://doi.org/10.1371/journal.pone.0217017.t006>

malformations showed more often a favorable outcome than patients with sICH (95% CI 9.3 [4.5;19.5];  $p < .0001$ ). The overall mortality rate for the study patients was 11% (39 patients), mostly occurring in patients with sICH (71.8% vs. 28.2%; 95% CI 2.8 [1.4;5.9];  $p = 0.006$ ). Table 6 summarizes the predictive variables for outcome in univariate and multivariate analysis.

## Discussion

### Outcome and prognosis in ICH

Age and clinical condition at ictus have the strongest association with further course and outcome after ICH.[17] These predictive variables are necessary to assess the risk for an underlying vascular malformation in intracerebral hemorrhage and to assess prognostic values. Many studies described scores to provide analysis of long-term prognosis for patients with intracerebral hemorrhage.[18,19] Furthermore the source of bleeding is one more and even crucial cause of poor or favorable outcome.[20] Therefore fast and appropriate diagnosis is required for impacting outcome positively. Bleeding pattern and patients' medical history usually indicate bleeding source. Spontaneous ICH due to hypertension and cerebral amyloid angiopathy are common causes for ICH in elderly patients.[8,21] 40% of our patients presented hemorrhage due to an AVM. In 10% cavernous malformations, dural fistulae and aneurysms were found. Nevertheless, we must emphasize, that a considerable number of patients at our centre were treated by neurologists and were not eligible for this study, as mentioned in the Methods section. The risk of AVM hemorrhage depends on special AVM features, including AVM location and angioarchitecture [22,23] and the annual bleeding risk amounts approximately 1 to 4%.[10,24] While AVM rupture may lead to severe neurologic dysfunction or result in death, [25,26] many studies described differences in outcome after AVM hemorrhage and spontaneous hemorrhage and confirm a better outcome after AVM hemorrhage.[11,12,19]

### Bleeding pattern in VM hemorrhage

We found evident differences in patient characteristics, bleeding pattern and outcome between sICH and vmICH that require different counseling and treatment. Patients with vmICH were younger, healthier and less affected at ictus than patients with sICH. Infratentorial hemorrhage was more often associated with AVM hemorrhage than with sICH. Hematoma volume considerably affects patients outcome and a few studies discussed the high impact of hematoma volume on poor outcome.[27–29] Our study patients with vmICH had more often a small

hematoma size and therefore were less affected. Several studies describe that AVM hematomas were mostly located within the nidus or in the venous side with sparing the healthy brain parenchyma which explains small hematoma size and better outcome.[30–32] The use of antiplatelet drugs was more common in patients with sICH and was significantly associated with a hematoma volume more than 30cm<sup>3</sup>. This was an additional finding and we recommend more studies with targeted research to evaluate the effect of antiplatelet drugs on hemorrhage volume. Regarding hematoma volume previous studies confirmed similar results.[33–35]

### Differences in treatment and outcome in sICH and vmICH

Furthermore there were significant differences in treatment timing and urgency. Patients with sICH were more often treated immediately after ictus and the overall mortality rate was higher. Patients with vmICH were mostly treated after recovery.

Beside age and the use of antiplatelet drugs, medical history, clinical condition at ictus, hemorrhage volume, location and in particular bleeding source were statistically evident predictors for final outcome.

### Generalizability and limitations

The knowledge of potential bleeding source, appropriated diagnostic methods and treatment time may improve young physicians' practices in routine and emergent care and may lead to a high level of using the right and fast treatment methods.[21,36–38] Our findings support prior statements of lower case fatality after hemorrhage due to vascular pathologies, in particular due to AVM hemorrhage compared to outcome findings after sICH.[19,20] The mean age in our study is low compared to other ICH trials. One reason for this is the large number of patients with AVM hemorrhage. The younger age and therefore healthier baseline conditions in patients with vascular pathologies compared to patients with sICH are significant causes for a favorable outcome.

Therefore, it is important to make a reliable diagnosis based on appropriated diagnostics and to treat patients adequately in order to achieve a favorable outcome and for better advising patients and family members. In summary, finding differences in patient characteristics and bleeding pattern according to the bleeding origin is the main objective of our study in order to give clues for fast and reliable diagnostic. Secondly we found differences in outcome in relation to the bleeding origin. Our study is limited by its retrospective design and single centre experience. Since the inclusion criteria required complete follow up data and angiographic imaging, patients without angiographic imaging could not be evaluated. A considerable number of patients undergo treatment by neurologists. Since routine diagnostic algorithm and treatment may differ, we included only patients who were admitted and treated neurosurgically. This is one reason why our cohort was preselected. This preselection is a major limitation and could introduce a selection bias.

### Conclusion

The major aim of our study was to identify predictive factors for underlying pathologies in ICH patients. ICH due to vascular malformation has some predictive features to detect the bleeding origin fast. Due to the inclusion criteria the validity of the study is limited and therefore more multicentre studies with further testing in general ICH patients in a prospective study design are required.

## Author Contributions

**Conceptualization:** Nazife Dinc, Sae-Yeon Won, Nina Brawanski, Johanna Quick-Weller, Jürgen Konzalla, Volker Seifert, Gerhard Marquardt.

**Data curation:** Nazife Dinc, Sae-Yeon Won, Nina Brawanski, Michael Eibach, Johanna Quick-Weller, Joachim Berkefeld.

**Formal analysis:** Nazife Dinc.

**Methodology:** Jürgen Konzalla, Joachim Berkefeld, Volker Seifert.

**Project administration:** Nazife Dinc, Gerhard Marquardt.

**Supervision:** Johanna Quick-Weller, Jürgen Konzalla, Joachim Berkefeld, Volker Seifert, Gerhard Marquardt.

**Validation:** Volker Seifert, Gerhard Marquardt.

**Visualization:** Gerhard Marquardt.

**Writing – original draft:** Nazife Dinc.

**Writing – review & editing:** Nazife Dinc, Michael Eibach, Gerhard Marquardt.

## References

1. Murthy S, Moradiya Y, Dawson J, Lees K, Hanley D, Ziai W, et al. Perihematomal Edema and Functional Outcomes in Intracerebral Hemorrhage: Influence of Hematoma Volume and Location. *Stroke*. 2015; 46(11):3088–3092. <https://doi.org/10.1161/STROKEAHA.115.010054> PMID: 26396030
2. Murthy S, Merkler A, Omran S, Gialdini G, Gudson A, Hartley B, et al. Outcomes after intracerebral hemorrhage from arteriovenous malformations. *Neurology*. 2017; 88(20):1882–1888. <https://doi.org/10.1212/WNL.0000000000003935> PMID: 28424275
3. Hemphill J, Greenberg S, Anderson C, Becker K, Bendok B, Cushman M, et al. Guidelines for the Management of Spontaneous Intracerebral Hemorrhage. *Stroke*. 2015; 46(7):2032–2060. <https://doi.org/10.1161/STR.0000000000000069> PMID: 26022637
4. Moon J, Janjua N, Ahmed S, Kirmani J, Harris-Lane P, Jacob M, et al. Prehospital neurologic deterioration in patients with intracerebral hemorrhage. *Crit Care Med*. 2008; 36(1):172–175. <https://doi.org/10.1097/01.CCM.0000297876.62464.6B> PMID: 18007267
5. Morgenstern P, Hoffman C, Kocharian G, Singh R, Stieg P, Souweidane M. Postoperative imaging for detection of recurrent arteriovenous malformations in children. *J neurosurg Pediatr*. 2016; 17(February):134–140. <https://doi.org/10.3171/2015.6.PEDS14708> PMID: 26517058
6. Morgenstern LB, Hemphill JC, Anderson C, Becker K, Broderick J, Connolly E, et al. Guidelines for the management of spontaneous intracerebral hemorrhage: A guideline for healthcare professionals from the American Heart Association/American Stroke Association. *Stroke*. 2010; 41(9):2108–2129. <https://doi.org/10.1161/STR.0b013e3181ec611b> PMID: 20651276
7. Planton M, Saint-Aubert L, Rapso N, Branchu L, Lyoubi A, Bonneville F, et al. High prevalence of cognitive impairment after intracerebral hemorrhage. *PLoS One*. 2017; 12(6):1–13. <https://doi.org/10.1371/journal.pone.0178886> PMID: 28570698
8. Banerjee G, Carare R, Cordonnier C, Greenberg S, Schneider J, Smith E, et al. The increasing impact of cerebral amyloid angiopathy: essential new insights for clinical practice. *J Neurol Neurosurg Psychiatry*. 2017;jnnp-2016–314697. <https://doi.org/10.1136/jnnp-2016-314697> PMID: 28844070
9. Mohr JP, Caplan LR, Melski JW, Goldstein RJ, Duncan GW, Kistler JP, et al. The Harvard Cooperative Stroke Registry: a prospective registry. *Neurology*. 1978; 28(8):754–762. <http://www.ncbi.nlm.nih.gov/pubmed/567291>. <https://doi.org/10.1212/wnl.28.8.754> PMID: 567291
10. Hernesniemi JA, Dashti R, Juvela S, Väärt K, Niemelä M, Laakso A. Natural history of brain arteriovenous malformations: a long-term follow-up study of risk of hemorrhage in 238 patients. *Neurosurgery*. 2008; 63(5):823–9; discussion 829–31. <https://doi.org/10.1227/01.NEU.0000330401.82582.5E> PMID: 19005371
11. Choi JH, Mast H, Sciacca RR, Hartmann A, Khaw A, Mohr J, et al. Clinical outcome after first and recurrent hemorrhage in patients with untreated brain arteriovenous malformation. *Stroke*. 2006; 37(5):1243–1247. <https://doi.org/10.1161/01.STR.0000217970.18319.7d> PMID: 16614321

12. van Beijnum J, Lovelock CE, Cordonnier C, Rothwell PM, Klijn C, Al-Shahi S. Outcome after spontaneous and arteriovenous malformation-related intracerebral haemorrhage: population-based studies. *Brain*. 2009; 132(Pt 2):537–543. <https://doi.org/10.1093/brain/awn318> PMID: 19042932
13. Teasdale G, Jennett B. Assessment of coma and impaired consciousness. A practical scale. *Lancet (London, England)*. 1974; 2(7872):81–84. <http://www.ncbi.nlm.nih.gov/pubmed/4136544>.
14. Mendelow AD, Gregson BA, Rowan EN, Murray G, Ghohkar A, Mitchel P, et al. Early surgery versus initial conservative treatment in patients with spontaneous supratentorial lobar intracerebral haematomas (STICH II): A randomised trial. *Lancet*. 2013; 382(9890):397–408. [https://doi.org/10.1016/S0140-6736\(13\)60986-1](https://doi.org/10.1016/S0140-6736(13)60986-1) PMID: 23726393
15. Mendelow AD, Gregson BA, Fernandes HM, Murray GD, Teasdale GM, Hope DT, et al. Early surgery versus initial conservative treatment in patients with spontaneous supratentorial intracerebral haematomas in the International Surgical Trial in Intracerebral Haemorrhage (STICH): a randomised trial. *Lancet (London, England)*. 365(9457):387–397. [https://doi.org/10.1016/S0140-6736\(05\)17826-X](https://doi.org/10.1016/S0140-6736(05)17826-X)
16. Ross J, Morgan Q, Publishers K. Book Review: C4. 5: Programs for Machine Learning. 1994; 240:235–240. <https://doi.org/10.3109/02699206.2010.515375>
17. Kuhmonen J, Piippo A, Väärt K, Karatas A, Ishii K, Winkler P, et al. Early surgery for ruptured cerebral arteriovenous malformations. *Acta Neurochir Suppl*. 2005; 94:111–114. <http://www.ncbi.nlm.nih.gov/pubmed/16060249>. PMID: 16060249
18. Gupta VP, Garton ALA, Sisti JA, Christophe BR, Lord AS, Lewis AK, et al. Prognosticating Functional Outcome After Intracerebral Hemorrhage: The ICHOP Score. *World Neurosurg*. 2017; 101:577–583. <https://doi.org/10.1016/j.wneu.2017.02.082> PMID: 28242488
19. Neidert MC, Lawton MT, Kim LJ, Nerva JD, Kurisu K, Ikawa F, et al. International multicentre validation of the arteriovenous malformation-related intracerebral haemorrhage (AVICH) score. *J Neurol Neurosurg Psychiatry*. October 2017. <https://doi.org/10.1136/jnnp-2017-316259> PMID: 28986471
20. Hartmann A, Mast H, Mohr JP, Koennecke HC, Osipov A, Pile-Spellman J, et al. Morbidity of intracranial hemorrhage in patients with cerebral arteriovenous malformation. *Stroke*. 1998; 29(5):931–934. <http://www.ncbi.nlm.nih.gov/pubmed/9596237>. PMID: 9596237
21. Qureshi A. Antihypertensive Treatment of Acute Cerebral Hemorrhage (ATACH): rationale and design. *Neurocrit Care*. 2007; 5(1):56–66. <https://doi.org/10.1385/Neurocrit>
22. Dinc N, Eibach M, Tritt S, Konczalla J, Seifert V, Marquardt G. Special Features in AVMs. Impact of Draining Veins on Hemorrhagic Presentation. 2017; 4.
23. Dinc N, Platz J, Tritt S, Quick-Weller J, Eibach M, Marquardt G, et al. Posterior fossa AVMs: Increased risk of bleeding and worse outcome compared to supratentorial AVMs. *J Clin Neurosci*. 2018; 53:171–176. <https://doi.org/10.1016/j.jocn.2018.04.010> PMID: 29685412
24. Spetzler RF, Martin NA. A proposed grading system for arteriovenous malformations. *J Neurosurg*. 1986; 65(4):476–483. <https://doi.org/10.3171/jns.1986.65.4.0476> PMID: 3760956
25. da Costa L, Wallace MC, Ter Brugge KG, O’Kelly C, Willinsky RA, Tymianski M. The natural history and predictive features of hemorrhage from brain arteriovenous malformations. *Stroke*. 2009; 40(1):100–105. <https://doi.org/10.1161/STROKEAHA.108.524678> PMID: 19008469
26. Brown RD, Flemming KD, Meyer FB, Cloft HJ, Pollock BE, Link ML. Natural history, evaluation, and management of intracranial vascular malformations. *Mayo Clin Proc*. 2005; 80(2):269–281. <https://doi.org/10.4065/80.2.269> PMID: 15704783
27. Christensen MC, Mayer SA, Ferran J-M, Kissela B. Depressed mood after intracerebral hemorrhage: the FAST trial. *Cerebrovasc Dis*. 2009; 27(4):353–360. <https://doi.org/10.1159/000202012> PMID: 19218801
28. Christensen MC, Mayer S, Ferran J-M. Quality of life after intracerebral hemorrhage: results of the Factor Seven for Acute Hemorrhagic Stroke (FAST) trial. *Stroke*. 2009; 40(5):1677–1682. <https://doi.org/10.1161/STROKEAHA.108.538967> PMID: 19265046
29. Delcourt C, Zheng D, Chen X, Hackett M, Arima H, Hata J, et al. Associations with health-related quality of life after intracerebral haemorrhage: pooled analysis of INTERACT studies. *J Neurol Neurosurg Psychiatry*. 2017; 88:70–75. <https://doi.org/10.1136/jnnp-2016-314414> PMID: 27919055
30. Kader A, Young WL, Pile-Spellman J, Mast H, Sciacca RR, Mohr JP, et al. The influence of hemodynamic and anatomic factors on hemorrhage from cerebral arteriovenous malformations. *Neurosurgery*. 1994; 34(5):801–7; discussion 807–8. <https://doi.org/10.1227/00006123-199405000-00003> PMID: 7914356
31. Spetzler RF, Hargraves RW, McCormick PW, Zabramski JM, Flom RA, Zimmerman RS. Relationship of perfusion pressure and size to risk of hemorrhage from arteriovenous malformations. *J Neurosurg*. 1992; 76(6):918–923. <https://doi.org/10.3171/jns.1992.76.6.0918> PMID: 1588424

32. Stapf C, Mast H, Sciacca RR, Choi JH, Kaw AV, Connolly ES, et al. Predictors of hemorrhage in patients with untreated brain arteriovenous malformation. *Neurology*. 2006; 66(9):1350–1355. <https://doi.org/10.1212/01.wnl.0000210524.68507.87> PMID: 16682666
33. Falcone GJ, Brouwers HB, Biffi A, Anderson CD, Battey TW, Ayres AM, et al. Warfarin and statins are associated with hematoma volume in primary infratentorial intracerebral hemorrhage. *Neurocrit Care*. 2014; 21(2):192–199. <https://doi.org/10.1007/s12028-013-9839-9> PMID: 23839705
34. Hokari M, Shimbo D, Asaoka K, Uchida K, Itamoto K. Impact of Antiplatelets and Anticoagulants on the Prognosis of Intracerebral Hemorrhage. *J Stroke Cerebrovasc Dis*. 2018; 27(1):53–60. <https://doi.org/10.1016/j.jstrokecerebrovasdis.2017.05.016> PMID: 29103863
35. Boulouis G, Morotti A, Pasi M, Goldstein JN, Gurol ME, Charidimou A. Outcome of intracerebral haemorrhage related to non-vitamin K antagonists oral anticoagulants versus vitamin K antagonists: a comprehensive systematic review and meta-analysis. *J Neurol Neurosurg Psychiatry*. 2018; 89(3):263–270. <https://doi.org/10.1136/jnnp-2017-316631> PMID: 29030422
36. Rectenwald JE, Upchurch GR. Impact of outcomes research on the management of vascular surgery patients. *J Vasc Surg*. 2007; 45 Suppl A:A131–40. <https://doi.org/10.1016/j.jvs.2007.02.028> PMID: 17544034
37. Broderick JP, Connolly S, Feldmann E, Hanley D, Kase C, Krieger D, et al. Guidelines for the management of spontaneous intracerebral hemorrhage in adults: 2007 update: a guideline from the American Heart Association/American Stroke Association Stroke Council, High Blood Pressure Research Council, and the Quality of Care and Out. *Stroke*. 2007; 38(6):2001–2023. <https://doi.org/10.1161/STROKEAHA.107.183689> PMID: 17478736
38. Broderick J, Brott T, Duldner J, Tomsick T, Huster G. Volume of Intracerebral Hemorrhage A Powerful and Easy-to-Use Predictor of 30-Day Mortality. *Stroke*. 1993; 24(7):987–993. <https://doi.org/10.1161/01.STR.24.7.987> PMID: 8322400