



# Bilateral ovarian torsion with ovarian fusion in the setting of polycystic ovarian syndrome: A case report<sup>☆</sup>

Rachel E. Warwar<sup>\*</sup>, Grant E. Schmidt

Department of Medical Education, Riverside Methodist Hospital, USA

## ARTICLE INFO

### Article history:

Received 4 June 2019

Received in revised form 6 June 2019

Accepted 7 June 2019

### Keywords:

Ovarian torsion

Polycystic ovarian syndrome

Oophoropexy

## ABSTRACT

**Background:** Adnexal torsion requires a high degree of suspicion in women presenting with pelvic pain. Polycystic ovaries are an infrequent cause of ovarian torsion but should be considered in cases without adnexal masses.

**Case:** A 25-year-old woman had a delayed diagnosis of adnexal torsion due to polycystic ovaries despite typical presentation and imaging. A unique finding was ovarian fusion; separation was required in order to resolve the torsion. Oophoropexy was performed to prevent the recurrence of torsion.

**Conclusion:** Ovarian torsion should be suspected in the setting of abdominal pain, enlarged polycystic ovaries, and absent adnexal blood flow on ultrasound. This case demonstrates the resilience of the adnexa and the highly variable time to necrosis in the setting of torsion.

© 2019 The Authors. Published by Elsevier B.V. This is an open access article under the CC BY-NC-ND license (<http://creativecommons.org/licenses/by-nc-nd/4.0/>).

## 1. Introduction

Adnexal torsion is a gynecologic emergency due to the risk of ovarian necrosis associated with delayed diagnosis and treatment. Torsion is responsible for 2.7% of all gynecologic emergencies [1]. There is often association with benign ovarian masses, especially those >5 cm; however, enlargement of the ovary for any reason can increase the risk of torsion [2]. Specifically, large heavy cysts, such as those seen in polycystic ovarian syndrome (PCOS) and following ovarian stimulation, are known risks for torsion [2].

The added weight and change in normal anatomy are thought to cause twisting of the ovary on its own vascular pedicle, the infundibulopelvic ligament, resulting in reduced venous outflow, often with continued arterial inflow due to the thick muscular walls that are less collapsible than the veins [2,3]. This eventually leads to congestion, ischemia, and progressive necrosis with prolonged torsion [3]. Unfortunately, the duration of ischemia causing irreversible damage is unknown and the majority of patients with adnexal torsion have delayed diagnosis [4].

Pelvic ultrasound is the primary mode of evaluation, with the most constant finding being a large ovary (> 4 cm) due to early hemorrhage and edema [2]. Other common features on ultrasound are the 'string of pearls' sign, a coexistent mass within the affected ovary, free pelvic fluid, and a twisted vascular pedicle [2]. The addition of color doppler can aid in diagnosis if absent arterial flow is noted; however, the flow

manifestations are highly variable and can indicate seemingly normal flow even in the presence of torsion [2].

It is widely accepted that urgent diagnostic laparoscopy is the preferred diagnostic and therapeutic intervention in cases of suspected torsion. Cohen et al. demonstrated that in 66 women undergoing emergency laparoscopies performed for suspected torsion, only 44% were confirmed to have adnexal torsion [5]. However, given the high risk of permanent ovarian damage and the implications for future fertility, diagnostic laparoscopy is still recommended as the first-line intervention in cases of suspected torsion [4].

The following case demonstrates a unique presentation of chronic ovarian torsion in the setting of polycystic ovaries, initially diagnosed and suspected to be bilateral endometriomas. This case has representative features of torsion on ultrasound, but also demonstrates the resilience of the adnexa after months of torsion. Finally, there is demonstration of oophoropexy as means of permanent treatment and prevention of recurrence in a patient with polycystic ovaries.

## 2. Case

A 25-year-old nulliparous woman presented to the emergency department with pelvic pain and was diagnosed with bilateral adnexal masses with lack of arterial blood flow in the right ovary on transvaginal ultrasound (Figs. 1, 2). Despite lack of color flow, it seemed that torsion was missed due to suspicion instead for endometriomas and pelvic pain secondary to endometriosis. The patient was morbidly obese with amenorrhea on medroxyprogesterone injections (Depo-Provera) for contraception and a history of irregular menses. She was discharged home from the emergency department but followed up by her gynecologist, who obtained tumor markers which were normal. Laparoscopy

<sup>☆</sup> This case report was presented at the Ohio University Heritage College of Medicine Case Reports Conference as a poster in February 2019.

<sup>\*</sup> Corresponding author at: 3535 Olentangy River Road, Columbus, Ohio 43214, USA.  
E-mail address: [Rachel.warwar@ohiohealth.com](mailto:Rachel.warwar@ohiohealth.com) (R.E. Warwar).

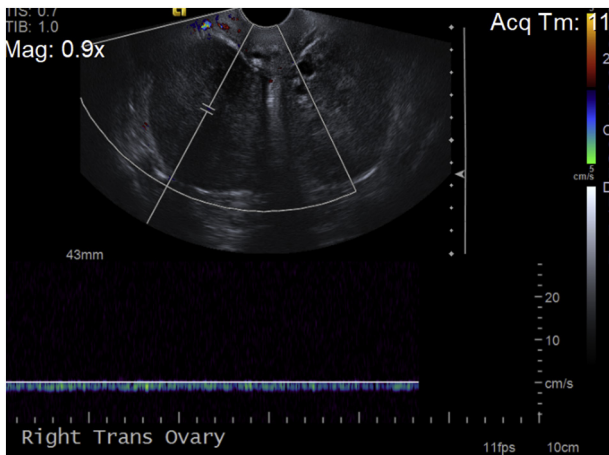


Fig. 1. Enlarged right ovary with absent arterial blood flow.

was ultimately performed one month from time of initial imaging and demonstrated bilaterally enlarged ovaries along with ovarian fusion. There was significant adhesive disease rendering blunt laparoscopic dissection difficult; therefore the decision was made to terminate the procedure. The patient was then referred to a specialist in reproductive endocrinology and infertility for removal of the cysts and lysis of adhesions for what was still suspected to be severe endometriosis.

The patient was seen approximately two months after initial diagnosis. She underwent a second laparoscopic procedure three months from the time of original imaging. Upon entrance into the abdomen and insufflation, both adnexa were found to be densely adherent to one another in posterior cul-de-sac along a 3 cm margin (Fig. 3). Closer inspection revealed apparent portions of both ovaries and tubes with scarring but no endometrioma or other cysts. Both ovaries, although more so on the right, were noted to have thick, cystic walls consistent with polycystic ovaries. The right ovary was observed to be torsed several times around the infundibulopelvic ligament (Figs. 4, 5). The ovaries were separated from each other using bipolar cautery and scissors. The right ovary was elevated into the mid-pelvis, untwisted and oophoropexy was performed to posterior wall of uterus near insertion of uteri-ovarian ligament with 2–0 silk sutures.

The left ovary was dissected free from cul-de-sac; however, its torsion was limited and removal of the ovary from sidewall was not likely to improve anatomic status. The fallopian tube was approximately a half twist on this side. In view of stability on this side and no evidence of

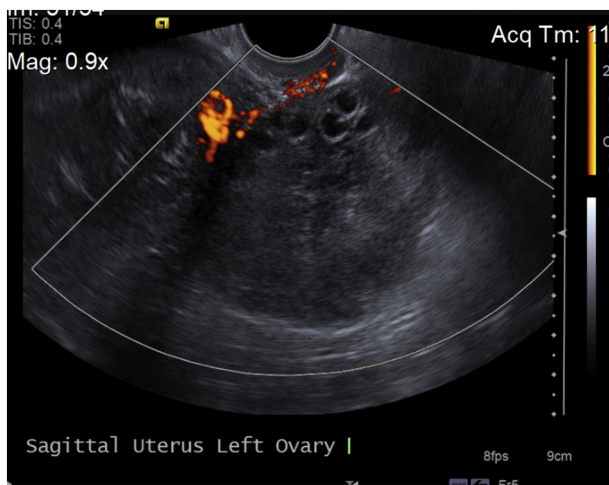


Fig. 2. Enlarged left ovary with peripherally spaced follicles.

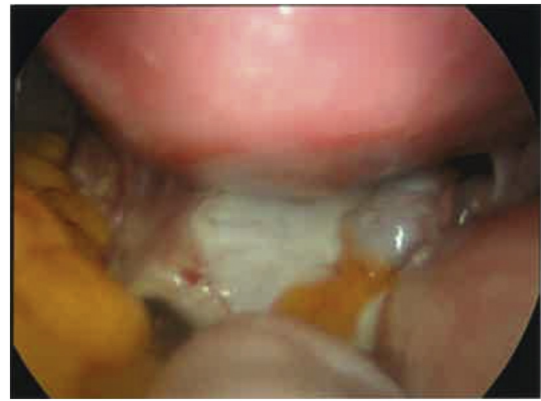

Fig. 3. Bilateral ovaries fused together in the posterior cul-de-sac.

ovarian damage or necrosis, further dissection was felt not to be appropriate or safe.

The patient did well post-operatively. Ultrasound approximately 9 months post-operatively demonstrated persistent enlargement of the right ovary but normal doppler blood flow. The left ovary was normal size, also with normal doppler blood flow. No serum measurements of ovarian reserve were performed at the follow-up visit as the patient was not interested in a fertility workup. Further records and follow-up with her primary gynecologist were not available.

### 3. Discussion

This case serves as a reminder that a high degree of suspicion in women presenting with acute onset abdominal or pelvic pain is necessary to efficiently diagnose and treat patients with adnexal torsion. This patient underwent surgical management one month after initial presentation as the initial diagnosis of torsion was not suspected. Due to the delay, it is likely there was prolonged inflammation due to the torsion which caused the ovaries to fuse together along with diffuse adhesive disease throughout the pelvis. The fusion prevented the ovaries from de-torsing on their own. The adhesive disease likely prohibited the initial surgeon from appropriately diagnosing the torsion due to poor visualization. However, even though the delay in final diagnosis was upwards of three months, both ovaries appeared to have adequate blood flow and were not necrotic in appearance, warranting de-torsion and conservative management.

There are three clinical take-home points from the current case. First, although torsion is most commonly associated with an adnexal mass or lesion on the ovary, there are unique conditions in which torsion should not be forgotten: ovarian hyperstimulation following fertility treatment and polycystic ovarian syndrome. Polycystic ovaries have been implicated in up to 7% of patients with torsion [6]. PCOS also

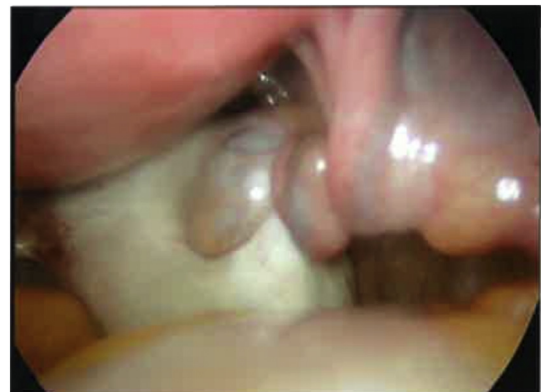
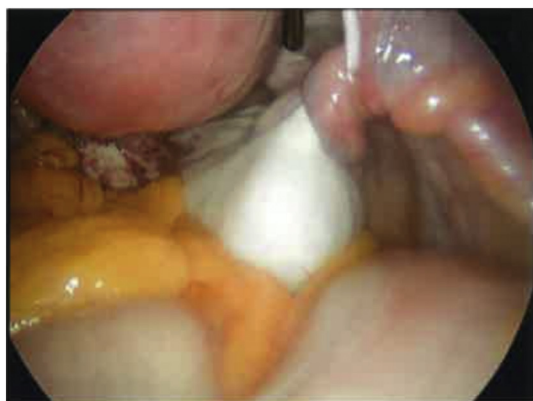
Fig. 4. Right ovary with torsion of infundibulopelvic ligament.



**Fig. 5.** Right ovarian torsion after separation of fused ovaries.

represents a potentially non-modifiable risk of recurrent torsion. In one case report, a 28-year-old with PCOS experienced unilateral ovarian torsion seven times in an eight-year period [3].

Second, few studies have been able to demonstrate any predictive factors for ovarian necrosis. The color, size, and edema of twisted adnexa are likely secondary to venous-lymphatic stasis, and do not reflect true damage to ovarian tissue [4,7]. There is some evidence in rats that necrosis can begin as soon as 36 h after torsion begins [8]. However, several studies have demonstrated ovarian preservation of function in 88–100% of cases of human torsion [4]. Other reports of ovarian function despite apparently ischemic-hemorrhagic appearance of torsed adnexa have been documented, favoring de-torsion rather than removal of the adnexa [9]. Several authors have demonstrated no difference in antral follicle count in small numbers of patients who underwent conservative detorsion of adnexa [10,11].

Third, a consideration in the final management decision concerns the prevention of future torsion. For many cases, the ovary is temporarily weighted with a mass or cyst that is often removed at the time of initial surgery, thereby also removing the likely etiology of the torsion. However, for a significant number of patients, including the premenarchal or adolescent population, there is no removable ovarian pathology at the time of torsion and therefore the risk of recurrence after de-torsion is significant [12]. Those with polycystic ovaries have a similar risk of recurrent episodes of torsion, as the causal pathologic mechanism likewise remains after simple de-torsion. This prompts further management with oophoropexy in preventing recurrence.

Further studies are necessary to determine the long-term effects on ovarian function and fertility after both preservation of adnexa with prolonged torsion and oophoropexy.

### Contributors

Rachel E. Warwar drafted the manuscript.  
Grant E. Schmidt revised the manuscript.  
Both authors saw and approved the final manuscript.

### Funding

No funding was sought or secured in relation to this case report.

### Patient Consent

Obtained.

### Provenance and Peer Review

This case report was peer reviewed.

### Declaration of Competing Interest

The authors declare that they have no conflict of interest regarding the publication of this case report.

### Acknowledgements

Rachel E. Warwar would like to thank Dr. Nicole Book for being an important component in assisting with the publication of the manuscript and for her encouragement and support in the writing of the manuscript.

### References

- [1] L.T. Hibbard, Adnexal torsion, *Am. J. Obstet. Gynecol.* 152 (4) (1985) 456–461.
- [2] H.C. Chang, S. Bhatt, V.S. Dogra, Pearls and pitfalls in diagnosis of ovarian torsion, *Radiographics* 28 (5) (2008) 1355–1368.
- [3] P.C. Brady, A.K. Styer, Laparoscopic uteroovarian ligament truncation and uterosacral oophoropexy for idiopathic recurrent ovarian torsion: case report and review of literature, *Fertil. Res. Pract.* 1 (2) (2015).
- [4] G. Oelsner, D. Shashar, Adnexal torsion, *Clin. Obstet. Gynecol.* 49 (3) (2006) 459–463.
- [5] S.B. Cohen, B. Weisz, D.S. Seidman, et al., Accuracy of the preoperative diagnosis in 100 emergency laparoscopies performed due to acute abdomen in non-pregnant women, *J. Am. Assoc. Gynecol. Laparosc.* 8 (2001) 92–94.
- [6] Z. Tsafrir, J. Hasson, I. Levin, E. Solomon, B.J. Lessing, F. Azem, Adnexal torsion: cystectomy and ovarian fixation are equally important in preventing recurrence, *Eur. J. Obstet. Gynecol.* 162 (2) (2012) 203–205.
- [7] C. Mazouni, F. Bretelle, J.P. Menard, B. Blanc, M. Gamberre, Diagnosis of adnexal torsion and predictive factors of adnexal necrosis, *Gynecol. Obstet. Fertil.* 33 (3) (2005) 102–106.
- [8] O. Taskin, M. Birincioglu, A. Aydin, A. Buhur, F. Burak, I. Yilmaz, J. Wheeler, The effects of twisted ischaemic adnexa managed by detorsion on ovarian viability and histology: an ischaemia-reperfusion rodent model, *Hum. Reprod.* 13 (1998) 2823–2827.
- [9] K. Chu, Q. Zhang, N. Sun, H. Ding, L. Wen, Conservative laparoscopic management of adnexal torsion based on a 17 year follow up experience, *J. Int. Med. Res.* 46 (4) (2018) 1685–1689.
- [10] G. Bozdag, B. Demir, P.T. Calis, D. Zengin, B. Dilbaz, The impact of adnexal torsion on antral follicle count when compared with contralateral ovary, *J. Minim. Invasive Gynecol.* 21 (4) (2014) 632–635.
- [11] C. Yasa, O. Dural, E. Bastu, M. Zorlu, O. Demir, F.G. Ugurlucan, Impact of laparoscopic ovarian detorsion on ovarian reserve, *J. Obstet. Gynecol.* 43 (2) (2017) 298–302.
- [12] E. Ashwal, L. Hirsch, H. Krissi, R. Eitan, S. Less, A. Wiznitzer, Y. Peled, Characteristics and management of ovarian torsion in premenarchal compared with postmenarchal patients, *Obstet. Gynecol.* 126 (3) (2015) 515–520.