



Cavernous malformations of the central nervous system: An international consensus statement

ARTICLE INFO

Handling Editor: Dr W Peul

Keywords

Cavernous malformation

Consensus

Deep-seated

Developmental venous anomaly

Stereotactic radiosurgery

Surgery

ABSTRACT

Introduction: Cavernous malformations (CM) of the central nervous system constitute rare vascular lesions. They are usually asymptomatic, which has allowed their management to become quite debatable. Even when they become symptomatic their optimal mode and timing of treatment remains controversial.

Research question: A consensus may navigate neurosurgeons through the decision-making process of selecting the optimal treatment for asymptomatic and symptomatic CMs.

Material and methods: A 17-item questionnaire was developed to address controversial issues in relation to aspects of the treatment, surgical planning, optimal surgical strategy for specific age groups, the role of stereotactic radiosurgery, as well as a follow-up pattern. Consequently, a three-stage Delphi process was ran through 19 invited experts with the goal of reaching a consensus. The agreement rate for reaching a consensus was set at 70%.

Results: A consensus for surgical intervention was reached on the importance of the patient's age, symptomatology, and hemorrhagic recurrence; and the CM's location and size. The employment of advanced MRI techniques is considered of value for surgical planning. Observation for asymptomatic eloquent or deep-seated CMs represents the commonest practice among our panel. Surgical resection is considered when a deep-seated CM becomes symptomatic or after a second bleeding episode. Asymptomatic, image-proven hemorrhages constituted no indication for surgical resection for our panelists. Consensus was also reached on not resecting any developmental venous anomalies, and on resecting the associated hemosiderin rim only in epilepsy cases.

Discussion and conclusion: Our Delphi consensus provides an expert common practice for specific controversial issues of CM patient management.

1. Introduction

Cavernous malformations (CMs) are well-circumscribed, low-flow, acquired vascular lesions characterized by thin-walled sinusoidal channels, with no intervening normal parenchyma. They have been estimated to affect approximately 0.5% (ranging from 0.2% to 0.9%) of the general population, while the majority of the cases, up to 70%, are asymptomatic (Washington et al., 2010). According to a population-based study by Flemming et al. (2017), the prevalence of cerebral CMs (CCMs) was 1 in 200 patients. However, the authors found that only 1 in 2700 had symptoms (Flemming et al., 2017). Consequently, only a small proportion of people with CMs come to medical attention.

In many cases the management of CMs, when necessary, remains highly debatable (Rauschenbach et al., 2022a; Herten et al., 2021; Santos et al., 2020). It is generally accepted that the risks of any therapeutic intervention should be out-weighed by the expected clinical benefit (Dammann et al., 2021). Any therapeutic strategy should take into consideration the natural history of the disease (Santos et al., 2021a, 2021b, 2022a; Dammann et al., 2017a). Intraparenchymal hemorrhage presenting with clinical symptomatology constitutes the

most serious complication and the reason for treatment in the majority of cases. It is well known that the risk of hemorrhage is higher in patients with a history of a previous bleeding (Dammann et al., 2016; Santos et al., 2023; Santos et al., 2022b; Horne et al.). However, CM-related hemorrhages usually displace rather than damage the surrounding parenchyma and the clinical course of these hemorrhages is relatively benign. Therefore, there is good clinical recovery, and the overall functional outcome in most cases is favorable, in the absence of any recurrent bleeding (Taslami et al., 2016).

Despite the rapidly growing knowledge, relevant clinical questions and areas of controversy persist, which continue to impact the management of CMs. In our current study, we attempted to establish a Delphi consensus on the treatment of these relatively rare but challenging vascular lesions. This consensus data is intended to guide neurosurgeons in the treatment decision-making process, to define the actual therapeutic options, and determine the optimal timing for intervention based on experts opinion.

<https://doi.org/10.1016/j.bas.2023.102707>

Received 14 June 2023; Received in revised form 19 October 2023; Accepted 4 November 2023

Available online 10 November 2023

2772-5294/© 2023 The Authors. Published by Elsevier B.V. on behalf of EUROSPINE, the Spine Society of Europe, EANS, the European Association of Neurosurgical Societies. This is an open access article under the CC BY-NC-ND license (<http://creativecommons.org/licenses/by-nc-nd/4.0/>).

2. Methods

2.1. Consensus description

The present study was completed in two phases. Initially, we formulated a questionnaire, which addressed as many controversies as possible, regarding CM management. The controversies were identified based on a meticulous review of the relevant literature. We then conducted a three-stage Delphi consensus process using a web-based survey to formulate recommendations for the management of CMs. A response rate of 80% or greater would validate our consensus. The threshold for inter-reviewer agreement was set at 70%. The current consensus did not include patients or patient data and therefore required no Institutional Review Board approval.

2.2. A priori assumptions

Our consensus focused on the treatment of CMs, either with surgical excision or with stereotactic radiosurgery. We did not address pathologies other than CMs, except for coexisting developmental venous anomalies (DVAs) and the surrounding hemosiderin rim. Likewise, we did not address areas other than the treatment of CMs, such as the epidemiology, pathogenesis, diagnosis, or prognosis.

2.3. Questionnaire development

Three authors (AGB, AK, AT) reviewed the relevant literature on the management of CMs to identify potential controversies. A lead author (KNF) resolved any disagreements among the authors. None of the developers participated in answering the questionnaire. The authors identified several controversial topics, including i) potential treatment modifiers, ii) adjuvant pharmacotherapy, iii) additional diagnostic modalities required for surgical planning, iv) optimal treatment modality, v) treatment of the associated hemosiderin rim, vi) optimal treatment of the coexisting DVAs, vii) follow-up timetable, and viii) role of stereotactic radiosurgery. Furthermore, the developed management questions were stratified by patient age [children and young adults (<35 years), middle-aged patients (36–65 years), and elderly (>65 years)], clinical presentation (asymptomatic, after the first hemorrhage, and after the second hemorrhage), and lesional anatomic location (eloquent cortex, basal ganglia, brainstem and spinal cord). We considered in our consensus as eloquent cortical areas, the primary motor, somatosensory, visual, and auditory cortex, as well as the Broca's and the Wernicke's areas (Radiopaedia; Kahn et al., 2017). In total, the questionnaire included 17 semi-closed questions (supplementary material). For 13 questions, the respondent could give a short alternative answer, whereas for the remaining four questions, the respondent had the option of formulating a longer response/proposal. Among them, four questions allowed respondents to provide more than one possible answer.

2.4. Panelists

The lead author invited the panelists by e-mail. Panelists included known experts in the treatment of CMs, with a documented clinical and academic interest and experience on the topic. In addition, authorities with surgical background or experience in stereotactic radiosurgery from Europe or the United States, who have been involved in guideline and/or consensus development, were included. A minimum of 10-year clinical practice was required for participation. None of the panelists were involved in the initial identification of the examined controversial issues.

2.5. The delphi process

After reviewing the relevant literature, we created 17 questions in a Word document. In the first round, the senior authors mailed the first

draft to the panelists to get their feedback on the content of the questionnaire. Then, all responses were edited and comments, changes, and suggestions incorporated into the web-based questionnaire. In the second round, the questionnaire was created using Google Forms and emailed to the panelists. They answered the survey online and anonymously, and their responses were recorded. We highlighted the comments in the short and long semi-closed questions. If more than three respondents addressed the same comment, the questionnaire was rephrased to include the comment as an additional choice, and then the second round was re-ran. The panelists met during the "LINC III" meeting in Athens, Greece, and the results were presented for analysis and discussion. In the third and final round, we drafted a statement based on the survey results and sent it to the panelists for their approval on style, format, and wording.

2.6. Statistical analysis

We summarized the results using counts and percentages, while the results were presented in pie- and bar-charts. The statistical analysis was conducted automatically by the software Google Forms.

3. Results

3.1. Basic consensus characteristics

From 19 invited panelists, 17 experts responded to the survey and consistently participated in all three rounds. Thus, the survey reached a response rate as high as 89.5%. All respondents answered the complete survey except for Questions 3, 5, and 17 (15, 7, and 16 respondents, respectively).

Question 1: Clinical modifiers of treatment

Our panel of experts agreed that it is of utmost importance to consider the patient presenting symptoms (17/17), followed by a hemorrhage recurrence (14/17), and the patient's age (13/17). Familial predisposition (7/17) does not seem to be an essential factor to consider when planning CM treatment.

Question 2: Imaging modifiers of treatment

Our panelists agreed that it is helpful to consider the lesion size (16/17), and its anatomic location (15/17). There was no agreement in considering the total number of lesions (8/17), nor the presence of a coexisting DVA (9/17).

Question 3: Additional imaging or electrophysiological work-up

The experts agreed (13/15) that the use of advanced MRI modalities, including diffusion tensor imaging (DTI) and diffusion-weighted imaging (DWI), remains the most valuable tool. However, electroencephalography (6/15), and/or invasive electrophysiological investigation (4/15) were not recommended for management planning.

Question 4: Prophylaxis using anti-thrombotics/thrombolytics for systemic diseases

The panel of our experts did not recommend against using anti-thrombotics/thrombolytics when this is deemed necessary (14/17).

Question 5: Adjunct pharmacotherapy

Our panel reached no consensus on the use of any adjunctive pharmacological treatment such as β -blockers, statins, acetic salicylic acid, or fasudil.

Question 6: Optimal management of asymptomatic (incidental) CM in children and young adults

The experts agreed that observation remains the optimal management option in lesions located at eloquent cortical (12/17), and deep-seated areas (12/17). However, they did not reach an agreement on the optimal treatment for asymptomatic CMs in non-eloquent areas (11/17).

Question 7: Optimal management of asymptomatic (incidental) CM in middle-aged adults

Our current study participants agreed that observation remains the optimal management option in lesions located at eloquent cortical (12/17), and in deep-seated areas (12/17). However, there was no agreement on the optimal treatment for asymptomatic CMs in non-eloquent areas (11/17).

Question 8: Optimal management of asymptomatic (incidental) CM in elderly

Our panel of experts agreed that observation remains the optimal treatment in lesions located at eloquent cortex (15/17), in deep-seated areas (15/17), and in non-eloquent areas (15/17).

Question 9: Optimal timing for the surgical excision of deep-seated CM

For lesions located at the basal ganglia or thalamus, the panel of experts agreed that the optimal timing for surgical resection is when they become symptomatic or after the second hemorrhage (14/17). Similarly, for lesions located at the brainstem, the panel agreed that the optimal timing is when they become symptomatic or after the second hemorrhage (14/17). On the other hand, there was no agreement amongst the experts regarding the optimal timing for surgical resection of spinal cord lesions.

Question 10: Alternative options in managing incidentally discovered CM hemorrhage

The experts agreed that observation (14/17) is indicated for clinically silent hemorrhages. Interestingly, 10/17 of the participants recommended observation independent of the MRI findings, while a minority (4/17) proposed intervention, when there is any change in the size of the hemorrhage.

Question 11: Optimal management of DVAs associated with a CCM

Our panelists agreed (15/17) that avoiding surgical removal remains the optimal approach for coexisting DVAs.

Question 12: The optimal management of the hemosiderin rim

The participants agreed that the associated hemosiderin rim should be removed only in patients presenting with epilepsy (13/17).

Question 13: Optimal timing of early postoperative imaging follow-up

No consensus was reached regarding postoperative imaging. The relative majority (7/17) suggested obtaining a brain MRI on the first postoperative day, followed by three experts suggesting an MRI in the first postoperative week, while three others advocated performing one within the first postoperative month.

Question 14: Optimal timing of intermediate postoperative imaging follow-up

The relative majority of our participants suggested performing an MRI annually for the first three years (6/17) or with the presentation of any new neurological symptomatology (6/17). However, the percentage of agreement did not allow the establishment of a valid consensus recommendation.

Question 15: Optimal timing of late postoperative imaging follow-up

The relative majority of the participants suggested performing an MRI with the onset of any new neurological symptomatology (7/17). Many of the participants take into consideration the number of lesions, and/or the presence of any genetic factors (6/17). However, the percentage of agreement did not allow the establishment of a valid consensus recommendation.

Question 16: The role of SRS in CCM in eloquent areas

Eight experts (8/17) from our panel agreed that SRS has no role in the management of eloquent area CCMs. However, the percentage of agreement did not allow the establishment of a valid consensus recommendation.

Question 17: The role of SRS in CM in deep-seated areas

Eight experts (8/16) from our panel agreed that SRS has no role in managing deep-seated CMs. However, the percentage of agreement did not allow the establishment of a valid consensus recommendation.

A summary of the most important points is depicted in [Fig. 1](#).

4. Discussion

4.1. Background

The management of CMs was based on a surgeon's experience and thus was significantly variable from center to center. Traditionally, an expert's opinion was the criterion for making the treatment decision, as well as the selection of the treating method, mainly due to the lack of high-quality evidence in the literature. During the last few years, various expert consensus on their management, practice recommendations, and guidelines issued by different organizations have increased the strength of evidence of the decision-making process. However, many aspects of the management of these patients still remain highly disputable, with frequently contradictory suggestions, and diametrically opposite approaches. Our current Delphi consensus attempted to address these controversial issues, and provide a common practice in the management of these challenging cases ([Fig. 2](#)).

4.2. Natural history of CMs

Thorough knowledge of the natural history of CCMs and their spinal counterparts is of paramount importance in the management decision-making process. A recently published meta-analysis reported that the five-year hemorrhagic risk of CCM patients was 15.8% (13.7–17.9%) ([Horne et al.](#)). The authors also found that the annual risk of re-bleeding significantly declines over time ([Horne et al.](#)). Unfortunately, the available data on the natural history of intramedullary spinal cord CMs are quite sparse ([Santos et al., 2021a](#); [Cohen-Gadol et al., 2006](#)). A meta-analysis including 40 previously published studies reported that intramedullary CMs show an annual hemorrhage rate of 2.1% ([Badhiwala et al., 2014](#)).

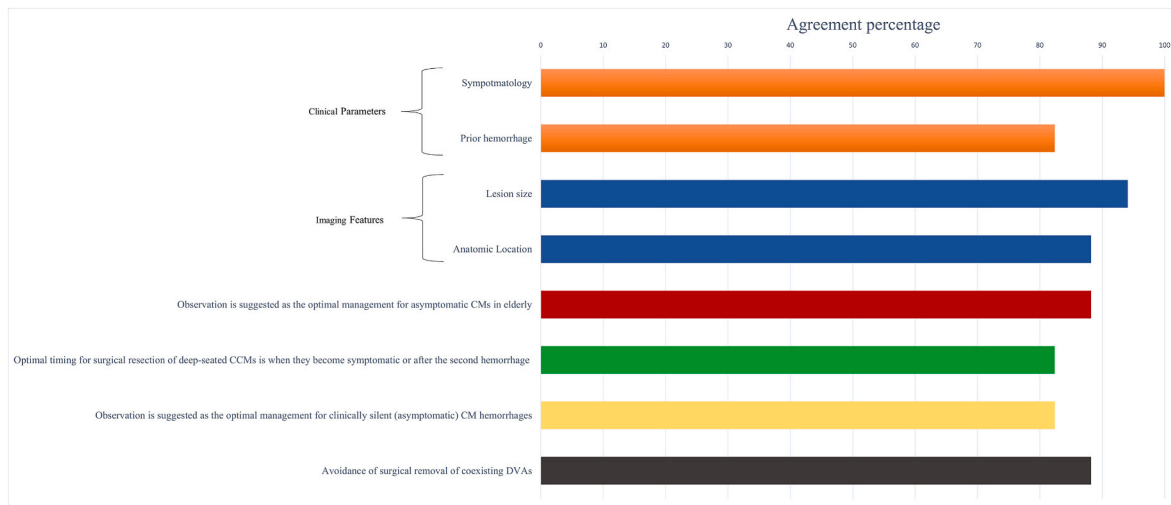


Fig. 1. Graph representation of the top six agreement points of our consensus. It is noteworthy that the agreement rate was >80%.

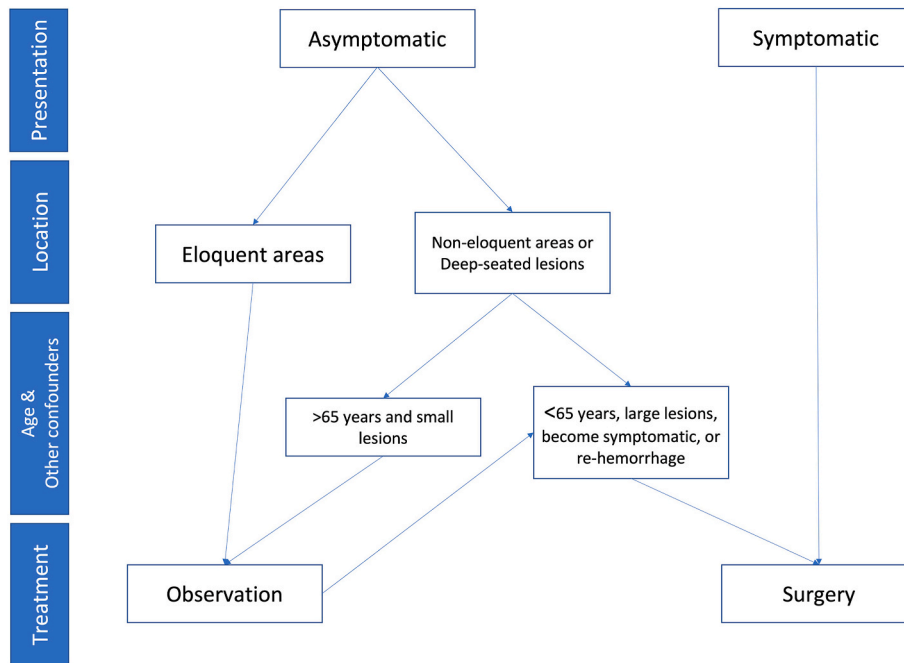


Fig. 2. A schematic representation of a suggested management algorithm based on our current CM consensus. This depicts a graphic representation of the clinical applicability of our consensus.

4.3. Clinical & genetic parameters affecting management

We were able to reach a consensus on the clinical factors affecting the decision-making process. The presence of symptoms was unanimously a factor for surgical resection of the underlying CM. This is in agreement with the previously published US Angioma Alliance guidelines recommending surgical resection for deep-seated CMs when symptomatic (class IIB, level B evidence) (Akers et al., 2017).

Moreover, 82.4% of our participants consider the second hemorrhage as an absolute indication for surgical resection of thalamus, basal ganglia, and brainstem CMs. Our currently proposed strategy is somewhat different than the US Angioma Alliance recommendations (Akers et al., 2017). Similarly to our consensus, they recommend surgical removal for brainstem CMs, after the second symptomatic bleeding (class IIB, level B evidence) (Akers et al., 2017). However, they recommend surgical resection for basal ganglia and thalamus CMs after the

first hemorrhage (class IIB, level B evidence) (Akers et al., 2017). It has to be mentioned that there is a growing body of evidence suggesting surgical resection even after the first episode of hemorrhage for brainstem CMs, since these lesions are characterized by the highest risk of recurrent bleeding (Santos et al., 2022b, 2023). Padney et al. (Pandey et al., 2013) stated that symptomatic deep CMs in the brainstem, basal ganglia, and thalamus demonstrate an aggressive behavior. Therefore, early surgery provides excellent clinical results and protects against future hemorrhages (Pandey et al., 2013). Similarly, a recently published international Delphi consensus provided level III evidence on the surgical management of brainstem CMs (Dammann et al., 2022). A panel of experts recommended conservative treatment for asymptomatic lesions, and surgical intervention after the first hemorrhage causing mass effect. A recurrent hemorrhage with progressive neurological deficit also constitutes an indication for surgical resection. They stated that the preferable timing for a resection is between 4 and 8 weeks after the last

hemorrhagic event. They considered that there was no difference, regarding their management, between sporadic and familial cases (Dammann et al., 2022). However, it is noteworthy that the proportion of uncertainty about expected postoperative outcome or indication for surgery in treated cases was 19.2% (range 5%–50%) (Dammann et al., 2022).

No consensus was reached by our panel of experts regarding the optimal management of spinal cord CMs. The US Angioma Alliance set of guidelines have identified that the indications for resection of spinal CMs after the first hemorrhage are weaker (class IIb, level C evidence) (Akers et al., 2017). Several studies in the literature report that a new onset of symptoms and/or imaging evidence of hemorrhage constitutes strong indications for surgical resection of spinal CMs (Rauschenbach et al., 2022b; Mitha et al., 2011; Flemming and Lanzino, 2020). Mitha et al. (2011) postulated that a symptomatic spinal CM, or imaging evidence of hemorrhage, or CM enlargement, represents indications for an urgent resection.

Surgical resection of a CCM is also considered in patients presenting with cavernoma-related epilepsy. The goal is to reduce the hemorrhagic risk and thus to abolish seizures. It has been demonstrated that CCM-related drug-resistant epilepsy patients have shown high percentages of seizure freedom, after resecting the underlying CCM (Dammann et al., 2017b; Rosenow et al., 2013; Baumann et al., 2007).

A consensus was also reached (agreement rate: 76.5%) regarding the importance of the patient's age as a determining factor intervention, with younger age favored for surgical intervention. In contrast, no consensus was reached regarding the actual role of familial CMs in the decision for surgical resection, since only 41.2% of our participants considered that as an indication for intervention. In surgically accessible brainstem CMs after the first hemorrhage, even in cases with mild clinical presentation, the patient's age seems to play a pivotal role in the treatment decision (Dammann et al., 2022). A previous consensus also stated that symptomatic lesions are managed according to similar criteria in sporadic and familial cases (Dammann et al., 2022). It has to be pointed out though that Al-Holou et al. (2012) have reported that the annual bleeding risk in children and younger adults with CCM is similar to the one reported for older adults, with the exception of familial cases. Likewise, Santos et al. (2021b) found that pediatric patients carried similar risk of (re)-hemorrhage compared to adults, in a five-year observational period.

4.4. Imaging parameters affecting management

The actual role of imaging characteristics of CMs in the decision for surgical intervention was examined in our consensus. There was a 94.1% agreement regarding the importance of the CM size, while an 88.2% consensus was reached on the impact of the CM anatomic location on the management planning. Contrariwise, no consensus was reached on the role of multiplicity of the lesions (agreement rate: 47.1%), and the existence or not of an associated DVA (agreement rate: 52.9%). According to the pertinent literature, various parameters have been identified as factors influencing the natural history, and consequently the treatment decision-making (Dammann et al., 2013, 2017a; Chen et al., 2020; Rauscher et al., 2023). However, there is contradictory data regarding the exact role of these factors including lesion size and multiplicity (Gross et al., 2011). In the brainstem, both CM location and size are key factors for selecting the proper management strategy (Santos et al., 2020; Dammann et al., 2022). Similarly, increased size is considered to be an indication for an urgent CM resection in spinal cases (Mitha et al., 2011). It is clearly proposed that CM location and clinical presentation are the most important factors in determining the proper management and treatment (Akers et al., 2017; Pandey et al., 2013; Dammann et al., 2022; Mouchtouris et al., 2015). Moreover, Winter et al. (2021) demonstrated that proximity of CCMs to eloquent areas constitutes a risk factor for poor postoperative outcome in patients suffering cavernoma-related epilepsy.

4.5. Additional imaging & electrophysiological preoperative testing

A consensus (agreement rate: 86.7%) was reached on the importance of obtaining additional preoperative advanced MRI studies, such as Fractional Anisotropy and Diffusion Tensor Imaging. These imaging MR modalities may provide valuable information regarding the topography of neuronal tracts adjacent to the CM, properly direct intraoperative cortical and subcortical electrical stimulation and mapping, and consequently increase the safety of the resection. However, no consensus was reached on the clinical utility of preoperative encephalography (agreement rate: 40%), or invasive encephalography (agreement rate: 26.7%). There is indeed a growing body of evidence which supports the idea that advanced imaging techniques increase the safety of surgical resection of CMs. Functional MRI, tractography, intraoperative electrophysiological monitoring, and frameless neuronavigation mitigate the chance of postoperative neurological deficits (Flemming and Lanzino, 2020; Abhinav et al., 2014). Moreover, intraoperative neurophysiologic monitoring techniques such as direct cortical mapping, somatosensory (SSEPs) and motor evoked potentials (MEPs), as well as D-wave monitoring for intramedullary CMs are employed with geometrically increasing frequency (Mitha et al., 2011; Rauschenbach et al., 2021; Sala et al., 2006; Ferrolì et al., 2006). On the other hand, it needs to be pointed out that the clinical benefit of the employment of intraoperative electrocorticography (ECoG) remains highly disputable (Ferrier et al., 2007; Van Gompim et al., 2009; Von der Brèlie and Schramm, 2011).

4.6. Intraoperative strategies

Resection of the hemosiderin ring, frequently surrounding a CM, has been a controversial topic. Our participants reached a consensus (agreement rate: 76.5%) regarding the resection of the hemosiderin ring only in patients presenting with epilepsy, and only when this can be safely done. The literature data is confusing regarding this issue. Unfortunately, this dilemma remains unresolved mostly due to the retrospective nature of the published studies (Rosenow et al., 2013). Flemming and Lanzino suggested lesionectomy with additional removal of the surrounding gliotic and hemosiderin-stained brain only in non-eloquent CM cases (Flemming and Lanzino, 2020). However, there are numerous studies in the literature reporting significantly better outcome after hemosiderin rim removal (Cohen et al., 1995; Casazza et al., 1997; Stefan and Hammen, 2004; Baumann et al., 2006; Hammen et al., 2007; Stavrou et al., 2008). On the contrary, several studies failed to statistically support this correlation (Casazza et al., 1996; Zevgaridis et al., 1996; Cappabianca et al., 1997). In a recent systematic review, the authors found no difference between pure lesionectomy without ring removal and resection with ring removal (Englot et al., 2011).

Similarly, the issue of removing the associated DVA has remained controversial. Our participants reached a consensus (agreement rate: 88.2%) that the DVA should not be removed. It has been demonstrated that approximately 30% of patients with sporadic CM will have an associated DVA on standard MRI sequences. DVAs have been implicated not only in the pathogenesis but also in the natural history of CM (Dammann et al., 2013; Chen et al., 2020; Gross et al., 2011; Schneble et al., 2012). Many studies advocate against the removal of the associated DVA, since this constitutes a normal venous drainage structure (Buhl et al., 2002). Numerous other clinical studies advocate avoiding DVA dissection for preventing serious complications such as edema, hemorrhage, and/or venous infarcts (Rosenow et al., 2013; Gross et al., 2013). Similarly, the panel of experts in the surgical management of brainstem CMs concluded that DVAs should be spared during surgery, while large DVAs can conflict the surgical approach and increase the surgical risks (Dammann et al., 2022).

4.7. Postoperative imaging

No consensus was reached among our participants on the

appropriate early, intermediate, or late postoperative imaging protocol. The different time approaches among our panel members are also reflected on the pertinent literature. Undoubtedly, MRI is the method of choice for the postoperative imaging. [Abla et al. \(2010\)](#) performed MRIs in all patients undergoing microsurgical resection for brainstem CMs within 24 hours postoperatively. Repeat imaging was performed each year for the first two to three years, and every two to four years thereafter. Patients who develop symptoms between follow-up MRIs require an immediate MRI ([Abla et al., 2010](#)). Likewise, [Akers et al. \(2017\)](#) suggested a repeat MRI with the onset of any new or worsening of any pre-existing symptoms (class I, level C evidence). As in our study, a previously published consensus did not reach an agreement regarding the follow-up imaging in surgically treated patients with brainstem CMs ([Dammann et al., 2022](#)). However, they agreed that in case of significant remnants identified on postoperative imaging, these should be resected, if accessible ([Dammann et al., 2022](#)). Generally, in the absence of hemorrhage or new symptoms, the utility of repeated MRIs remains still unclear.

In spinal cord CMs a long-term follow-up is recommended, since a significant percentage of these patients demonstrate prolonged postoperative improvement ([Mitha et al., 2011](#); [Rauschenbach et al., 2023](#); [Vishteh et al., 1997](#)). However, in a recently published meta-analysis for spinal CMs, [Fotakopoulos et al. \(2021\)](#) reported that the length of follow-up varied significantly among the included studies (3–12 months).

4.8. Employment of adjuvant pharmacotherapy

No consensus was reached among our participants on the administration of any adjuvant medications on CM patients. Various medications, including β -blockers, statins, acetic salicylic acid, or fasudil have been administered in CM patients for lowering the risk of hemorrhage. A recently published cohort study showed that antiplatelet medication alone, or in combination with statins was associated with a lower risk of CCM hemorrhage ([Marques et al., 2023](#)). This study also showed that the risk of hemorrhage after administering a combination of statin and antiplatelet medication was significantly lower to the one observed with antiplatelet medication alone. This finding may well indicate a possible synergistic effect ([Marques et al., 2023](#)). Furthermore, a protective effect for propranolol has been reported in numerous studies ([Apra et al., 2019](#); [Berti et al., 2014](#); [Goldberg et al., 2018](#); [Reinhard et al., 2016](#); [Zabramski et al., 2016](#)). Several clinical trials have assessed the potential protective role of statins and/or propranolol on the clinical course and the levels of CM biomarkers ([Polster et al., 2019](#); [Lanfrancini et al., 2020](#)). Recently published research data have shown that Rho-kinase activation constitutes a critical step in CCM genesis and evolution ([McDonald et al., 2012](#)). Therefore, fasudil, a potent Rho-kinase inhibitor, may slow the development of CMs ([Weiner and Ducruet, 2017](#)).

4.9. Systemic usage of anti-thrombotic prophylaxis in CM patients

Although our participants did not reach consensus regarding the initiation of anti-thrombotic/thrombolytic prophylaxis in CM patients, they reached a consensus (agreement rate: 82.3%) on initiating or maintaining them, when indicated for other systemic diseases. The Angioma Alliance Scientific Advisory Board Clinical Experts Panel recommended surgical resection of a solitary, asymptomatic CCM located in a non-eloquent cortical area, in those patients who may need to be on anticoagulation (class IIb, level C evidence) ([Akers et al., 2017](#)). They also noticed that there is limited amount of data available on the risk of anti-thrombotic medication usage in the general population, while the safety of thrombolytic therapies in patients with CCM and concomitant cerebral ischemia remains unclear (class III, level C evidence) ([Akers et al., 2017](#)). Contrariwise, in the literature there are several single-center, non-randomized cohort studies suggesting that the bleeding risk is lower in patients taking anti-thrombotics, by reducing

the risk of thrombosis of an associated DVA ([Schneble et al., 2012](#); [Al-Shahi Salman et al., 2012](#); [Bervini et al., 2018](#); [Flemming et al., 2013](#)). Likewise, a systematic review and meta-analysis by [Zuurbier et al. \(2019\)](#), postulated that antithrombotic therapy was associated with a lower risk of intracranial hemorrhage or focal neurological deficit caused by a CCM.

4.10. Management of asymptomatic CMs

Our participants reached a consensus that observation constitutes the best strategy for asymptomatic deep-seated and eloquent cortical CMs. This strategy was independent of the patient's age. Similarly, they reached a consensus that observation represents the best strategy for elderly patients with asymptomatic CCMs, even when these are in non-eloquent cortical areas. However, they reached no consensus regarding the best strategy for managing asymptomatic, non-eloquent cortical CCMs, in patients ≤ 65 years. Likewise, the Angioma Alliance published guidelines recommended no surgical resection for asymptomatic CCMs located in eloquent cortex, thalamus, basal ganglia, or brainstem (class III, level B evidence) ([Akers et al., 2017](#)). Similar factors and indications in determining the appropriate management and treatment have also been reported for pediatric populations ([Paddock et al., 2021](#)).

4.11. The role of SRS in the management of CCMs

No consensus was reached on the role of SRS in the management of deep-seated or eloquent cortical CCMs. There was a trend, among our participants (agreement rate: 50%) that SRS has no role in CCM management. It has to be mentioned though that approximately 50% of our panelists thought that SRS might have a role in the management of carefully selected, deep-seated and/or surgically inaccessible cases. SRS has been considered an alternative treatment modality for surgically inaccessible CCMs ([Nagy et al., 2018a, 2018b](#); [Lunsford et al., 2010](#); [Monaco et al., 2010](#)). The Angioma Alliance guidelines recommend that SRS may be considered for solitary CCMs, with previous symptomatic hemorrhage, if the CCM lies in eloquent cortical areas and their surgical resection carries an unacceptably high surgical risk (class IIb, level B evidence) ([Akers et al., 2017](#)). They have also emphasized that SRS is not recommended for asymptomatic CCMs, for those that are surgically accessible, or for familial cases because of the concern regarding the de novo CCM genesis (class III, level C evidence) ([Akers et al., 2017](#)). Indeed, there is a lot of discussion in the literature regarding radiation-induced CCMs. [Karlsson et al. \(2019\)](#), introduced the term pseudo-cavernoma to describe radiation-induced changes mimicking a CM. Significant histopathological and imaging features differentiate pseudo-cavernomas from true CCMs ([Cha et al., 2015](#)). Therefore, some radiation-induced CCMs may actually represent pre-existing non-hemorrhaged CCMs, which bled after SRS treatment. Some of the post-SRS observed CCMs may represent true radiation-induced lesions, while some others may be pseudo-cavernomas ([Karlsson et al., 2019](#)).

However, it remains to be defined whether the SRS treatment is advantageous to the CM natural history. Previous studies have shown that the risk of re-bleeding from repeatedly hemorrhaged CCMs declines after SRS treatment. The re-hemorrhage rate reduces from 50% per year, to 8–10% within the first 2 years, to 1–1.4% thereafter ([Lunsford et al., 2010](#); [Kondziolka et al., 1995](#); [Liu et al., 2005](#); [Pollock et al., 2000](#)). [Karlsson et al. \(1998\)](#) reported a trend for decreased hemorrhage rate four years after the SRS treatment. They also noted that higher radiation doses reduce the post-treatment risk of hemorrhage ([Karlsson et al., 1998](#)). It has to be taken into consideration that 8–17% of radio-surgically treated patients still required surgical resection at some point, because of the occurrence of multiple hemorrhagic events ([Lunsford et al., 2010](#); [Kondziolka et al., 1995](#); [Karlsson et al., 1998](#)). The exact role of SRS in the management of CCMs remains to be defined. An ongoing randomized controlled clinical trial is examining the efficacy of microsurgical or SRS intervention compared to the natural history of

patients with symptomatic CCMs (Harkness et al., 2022).

4.12. Study limitations

There are several potential limitations to our study. First of all, the present results are derived from expert personal opinions and not from robust clinical data. Thus, systematic or other kind of biases cannot be excluded. It has to be emphasized though that the absence of such solid clinical data necessitates an expert agreement. Second, there is no systematic way to identify experts. We invited a relatively small number of experts with a documented clinical and academic experience in CM management. Third, we invited experts only from Europe and the US, while the remaining world is under-represented. However, all participants took into consideration global literature data. Fourth, although we included experts with surgical and SRS experience, it is uncertain if the ratio between the two groups could introduce any biases in our study. Lastly, our survey addressed several scenarios considering the patient's age, clinical presentation, and CM location. For practical reasons, however, we could not include every possible scenario.

5. Conclusions

Our Delphi consensus identified that the presence of symptomatology, the occurrence of re-hemorrhage, the patient's age, as well as the CM size and anatomic location affect the decision-making process for surgical intervention. Our panel experts agree that the employment of advanced MR techniques is of value in the preoperative work-up and surgical planning of CM patients. There was agreement amongst our panel members on the strategy of not removing any associated DVAs, while hemosiderin rim removal is recommended only in CM-related epilepsy cases. Observation seems to be the most preferable strategy for asymptomatic eloquent cortical and deep-seated CMs. Likewise, observation is suggested in cases of clinically silent CMs with evidence of hemorrhage on the obtained imaging studies. A consensus was reached on the issue of surgical resection when deep-seated cerebral and/or eloquent cortical CMs become symptomatic or after the second episode of hemorrhage. Our consensus suggests that administration of anti-thrombotics/thrombolytics, when necessary for systemic medical conditions, may be initiated or continued. However, it is acknowledged that there remain several other controversial issues regarding the management of CM patients on which no consensus was reached.

Funding

This study did not receive any specific grant from funding agencies in the public, commercial, or not-for-profit sectors.

Declaration of competing interest

The authors declare that they have no known competing financial interests or personal relationships that could have appeared to influence the work reported in this paper.

Acknowledgements

The authors would like to thank Drs. Eftychios Archontakis, Edoardo Boccardi, and Ioannis Ioannidis, interventional neuroradiologists, for their valuable assistance and guidance in the preparation of our manuscript, regarding neuro-imaging issues.

Appendix A. Supplementary data

Supplementary data to this article can be found online at <https://doi.org/10.1016/j.bas.2023.102707>.

References

- Abhinav, K., Pathak, S., Richardson, R.M., Eng, J., Gardner, P., Yeh, F.C., Friedlander, R.M., Fernandez-Miranda, J.C., 2014. Application of high-definition fiber tractography in the management of supratentorial cavernous malformations: a combined qualitative and quantitative approach. *Neurosurgery* 74, 668–681. <https://doi.org/10.1227/NEU.0000000000000336>.
- Abla, A.A., Turner, J.D., Mitha, A.P., Lekovic, G., Spetzler, R.F., 2010. Surgical approaches to brainstem cavernous malformations. *Neurosurg. Focus* 29, E8. <https://doi.org/10.3171/2010.6.FOCUS10128>.
- Akers, A., Al-Shahi Salman, R., Awad, I., Dahlem, K., Flemming, K., Blaine Hart, B., Kim, H., Jusue-Torres, I., Kondziolka, D., Lee, C., Morrison, L., Rigamonti, D., Rebeiz, T., Tournier-Lasserre, E., Waggoner, D., Whitehead, K., 2017. Synopsis of guidelines for the clinical management of cerebral cavernous malformations: consensus recommendations based on systematic literature review by the Angioma Alliance Scientific Advisory Board Clinical Experts Panel. *Neurosurgery* 80, 665–680. <https://doi.org/10.1093/neuros/nyx091>.
- Al-Holou, W.N., O'Lynnner, T.M., Pandey, A.S., Gemmete, J.J., Thompson, B.G., Muraszko, K.M., Garton, H.J.L., O Maheret, C., 2012. Natural history and imaging prevalence of cavernous malformations in children and young adults. *J. Neurosurg. Pediatr.* 9, 198–205. <https://doi.org/10.3171/2011.11.PEDS11390>.
- Al-Shahi Salman, R., Hall, J.M., Horne, M.A., Moultrie, F., Josephson, C.B., Bhattacharya, J.J., Counsell, C.E., Murray, G.D., Papanastassiou, V., Ritchie, V., Roberts, R.C., Sellar, R.J., Warlow, C.P., Scottish Audit of Intracranial Vascular Malformations (SAIVMs) collaborators, 2012. Untreated clinical course of cerebral cavernous malformations: a prospective, population-based cohort study. *Lancet Neurol.* 11, 217–224. [https://doi.org/10.1016/S1474-4422\(12\)70004-2](https://doi.org/10.1016/S1474-4422(12)70004-2).
- Apra, C., Dumot, C., Bourdillon, P., Pelissou-Guyotat, I., 2019. Could propranolol be beneficial in adult cerebral cavernous malformations? *Neurosurg. Rev.* 42, 403–408. <https://doi.org/10.1007/s10143-018-01074-0>.
- Badhiwala, J.H., Farrokhkar, F., Alhazzani, W., Yarascavitch, B., Aref, M., Algird, A., Murty, N., Kachur, E., Cenic, A., Reddy, K., Almenawer, S.A., 2014. Surgical outcomes and natural history of intramedullary spinal cord cavernous malformations: a single center series and meta-analysis of individual patient data. *J. Neurosurg. Spine* 21, 662–676. <https://doi.org/10.3171/2014.6.SPINE13949>.
- Baumann, C.R., Schuknecht, B., Lo, R.G., Cossu, M., Citterio, A., Andermann, F., Siegel, A.M., 2006. Seizure outcome after resection of cavernous malformations is better when surrounding hemosiderin-stained brain also is removed. *Epilepsia* 47, 563–566. <https://doi.org/10.1111/j.1528-1167.2006.00468.x>.
- Baumann, C.R., Acciarri, N., Bertalanffy, H., Devinsky, O., Elger, C.E., Lo Russo, G., Cossu, M., Sure, U., Singh, A., Stefan, H., Hammen, T., Georgiadis, D., Baumgartner, R.W., Andermann, F., Siegel, A.M., 2007. Seizure outcome after resection of supratentorial cavernous malformations: a study of 168 patients. *Epilepsia* 48, 559–563. <https://doi.org/10.1111/j.1528-1167.2006.00941.x>.
- Berti, I., Marchetti, F., Skabar, A., Zennaro, F., Zanon, D., Ventura, A., 2014. Propranolol for cerebral cavernous angiomas: a magic bullet. *Clin. Pediatr. (Phila)* 53, 189–190. <https://doi.org/10.1177/0009922813492885>.
- Bervini, D., Jaeggi, C., Mordasini, P., Schucht, P., Raabe, A., 2018. Antithrombotic medication and bleeding risk in patients with cerebral cavernous malformations: a cohort study. *J. Neurosurg.* 1–9. <https://doi.org/10.3171/2018.1.JNS172547> (Online ahead of print).
- Buhl, R., Hempelmann, R.G., Stark, A.M., Mehdorn, H.M., 2002. Therapeutic considerations in patients with intracranial venous angiomas. *Eur. J. Neurol.* 9, 165–169. <https://doi.org/10.1046/j.1468-1331.2002.00372.x>.
- Cappabianca, P., Alfieri, A., Maiuri, F., Mariniello, G., Cirillo, S., de Divitiis, E., 1997. Supratentorial cavernous malformations and epilepsy: seizure outcome after lesionectomy on a series of 35 patients. *Clin. Neurol. Neurosurg.* 99, 179–183. [https://doi.org/10.1016/s0303-8467\(97\)00023-1](https://doi.org/10.1016/s0303-8467(97)00023-1).
- Casazza, M., Broggi, G., Franzini, A., Avanzini, G., Spreafico, R., Bracchi, M., Valentini, M.C., 1996. Supratentorial cavernous angiomas and epileptic seizures: preoperative course and postoperative outcome. *Neurosurgery* 39, 26–32. <https://doi.org/10.1097/00006123-199607000-00007>.
- Casazza, M., Avanzini, G., Ciceri, E., Spreafico, R., Broggi, G., 1997. Lesionectomy in epileptogenic temporal lobe lesions: preoperative seizure course and postoperative outcome. *Acta Neurochir. Suppl.* 68, 64–69. https://doi.org/10.1007/978-3-7091-6513-3_12.
- Cha, Y.J., Nahm, J.H., Ko, J.E., Shin, H.J., Chang, J.H., Cho, N.H., Kim, S.H., 2015. Pathological evaluation of radiation-induced vascular lesions of the brain: distinct from de novo cavernous hemangioma. *Yonsei Med. J.* 56, 1714–1720. <https://doi.org/10.3349/ymj.2015.56.6.1714>.
- Chen, B., Herten, A., Saban, D., Rauscher, S., Radbruch, A., Schmidt, B., Zhu, Y., Jabbarli, R., Wrede, K.H., Kleinschnitz, C., Sure, U., Dammann, P., 2020. Hemorrhage from cerebral cavernous malformations: the role of associated developmental venous anomalies. *Neurology* 95, e89–e96. <https://doi.org/10.1212/WNL.00000000000009730>.
- Cohen, D.S., Zubay, G.P., Goodman, R.R., 1995. Seizure outcome after lesionectomy for cavernous malformations. *J. Neurosurg.* 83, 237–242. <https://doi.org/10.3171/jns.1995.83.2.0237>.
- Cohen-Gadol, A.A., Jacob, J.T., Edwards, D.A., Krauss, W.E., 2006. Coexistence of intracranial and spinal cavernous malformations: a study of prevalence and natural history. *J. Neurosurg.* 104, 376–381. <https://doi.org/10.3171/jns.2006.104.3.376>.
- Dammann, P., Wrede, K.H., Maderwald, S., El Hindy, N., Mueller, O., Chen, B., Zhu, Y., Hütter, B.-O., Ladd, M.E., Schlamann, M., Sandalcioğlu, I.E., Sure, U., 2013. The venous angioarchitecture of sporadic cerebral cavernous malformations: a susceptibility weighted imaging study at 7 T MRI. *J. Neurol. Neurosurg. Psychiatry* 84, 194–200. <https://doi.org/10.1136/jnnp-2012-302599>.

- Dammann, P., Jabbarli, R., Witteck, P., Oppong, M.D., Kneist, A., Zhu, Y., Wrede, K.H., Müller, O., Forsting, M., Sure, U., 2016. Solitary sporadic cerebral cavernous malformations: risk factors of first or recurrent symptomatic hemorrhage and associated functional impairment. *World Neurosurg.* 91, 73–80. <https://doi.org/10.1016/j.wneu.2016.03.080>.
- Dammann, P., Wrede, K.H., Jabbarli, R., Müller, O., Mönninghoff, C., Forsting, M., Sure, U., 2017a. Of bubbles and layers: which cerebral cavernous malformations are most difficult to dissect from surrounding eloquent brain tissue? *Neurosurgery* 81, 498–503. <https://doi.org/10.1093/neuros/nyx025>.
- Dammann, P., Wrede, K.H., Jabbarli, R., Neuschulte, S., Menzler, K., Zhu, Y., Özkan, N., Müller, O., Forsting, M., Rosenow, F., Sure, U., 2017b. Outcome after conservative management or surgical treatment for new-onset epilepsy in cerebral cavernous malformation. *J. Neurosurg.* 126, 1303–1311. <https://doi.org/10.3171/2016.4.JNS1661>.
- Dammann, P., Herten, A., Santos, A.N., Rauschenbach, L., Chen, B., Oppong, M.D., Schmidt, B., Forsting, M., Kleinschnitz, C., Sure, U., 2021. Multimodal outcome assessment after surgery for brainstem cavernous malformations. *J. Neurosurg.* 135, 401–409. <https://doi.org/10.3171/2020.6.JNS201823>.
- Dammann, P., Abia, A.A., Al-Shahi Salman, R., Andrade-Barazarte, H., Benes, V., Cenozo, M., Connolly, E.S., Cornelius, J.F., Couldwell, W.T., Sola, R.G., Gomez-Paz, S., Hauck, E., Hernesniemi, J., Kivelev, J., Lanzino, G., Macdonald, R.L., Morcos, J.J., Ogilvy, C.S., Steiger, H.J., Steinberg, G.K., Santos, A.N., Rauschenbach, L., Oppong, M.D., Schmidt, B., Spetzler, R.F., Schaller, K., Lawton, M. T., Sure, U., 2022. Surgical treatment of brainstem cavernous malformations: an international Delphi consensus. *J. Neurosurg.* 136, 1220–1230. <https://doi.org/10.3171/2021.3.JNS2156>.
- Englot, D.J., Han, S.J., Lawton, M.T., Chang, E.F., 2011. Predictors of seizure freedom in the surgical treatment of supratentorial cavernous malformations clinical article. *J. Neurosurg.* 115, 1169–1174. <https://doi.org/10.3171/2011.7.JNS11536>.
- Ferrier, C.H., Aronica, E., Leijten, F.S., Spliet, W.G., Boer, K., van Rijen, P.C., van Huffelen, A.C., 2007. Electrooculography discharge patterns in patients with a cavernous hemangioma and pharmacoresistant epilepsy. *J. Neurosurg.* 107, 495–503. <https://doi.org/10.3171/JNS-07/09/0495>.
- Ferroli, P., Casazza, M., Marras, C., Mendola, C., Franzini, A., Broggi, G., 2006. Cerebral cavernomas and seizures: a retrospective study on 163 patients who underwent pure lesionectomy. *Neurol. Sci.* 26, 390–394. <https://doi.org/10.1007/s10072-006-0521-2>.
- Flemming, K.D., Lanzino, G., 2020. Cerebral cavernous malformation: what a practicing clinician should know. *Mayo Clin. Proc.* 95, 2005–2020. <https://doi.org/10.1016/j.mayocp.2019.11.005>.
- Flemming, K.D., Link, M.J., Christianson, T.J., Brown Jr., R.D., 2013. Use of antithrombotic agents in patients with intracerebral cavernous malformations. *J. Neurosurg.* 118, 43–46. <https://doi.org/10.3171/2012.8.JNS112050>.
- Flemming, K.D., Graff-Radford, J., Aakre, J., Kantarci, K., Lanzino, G., Brown Jr., R.D., Mielke, M.M., Roberts, R.O., Kremers, W., Knopman, D.S., Petersen, R.C., Jack Jr., C. R., 2017. Population-based prevalence of cerebral cavernous malformations in older adults: mayo Clinic Study of Aging. *JAMA Neurol.* 74, 801–805. <https://doi.org/10.1001/jamaneurol.2017.0439>.
- Fotakopoulos, G., Kivelev, J., Andrade-Barazarte, H., Tjahjadi, M., Goehre, F., Hernesniemi, J., 2021. Outcome in patients with spinal cavernomas presenting with symptoms due to mass effect and/or hemorrhage: conservative versus surgical management: meta-analysis of direct comparison of approach-related complications. *World Neurosurg.* 152, 6–18. <https://doi.org/10.1016/j.wneu.2021.05.094>.
- Goldberg, J., Jaeggi, C., Schoeni, D., Mordasini, P., Raabe, A., Bervini, D., 2018. Bleeding risk of cerebral cavernous malformations in patients on b-blocker medication: a cohort study. *J. Neurosurg.* 15, 1–6. <https://doi.org/10.3171/2017.12.JNS172404>.
- Gross, B.A., Lin, N., Du, R., Day, A.L., 2011. The natural history of intracranial cavernous malformations. *Neurosurg. Focus* 30, E24. <https://doi.org/10.3171/2011.3.FOCUS1165>.
- Gross, B.A., Batjer, H.H., Awad, I.A., Bendok, B.R., Du, R., 2013. Brainstem cavernous malformations: 1390 surgical cases from the literature. *World Neurosurg.* 80, 89–93. <https://doi.org/10.1016/j.wneu.2012.04.002>.
- Hammen, T., Romstock, J., Dorfner, A., Kerling, F., Buchfelder, M., Stefan, H., 2007. Prediction of postoperative outcome with special respect to removal of hemosiderin fringe: a study in patients with cavernous haemangiomas associated with symptomatic epilepsy. *Seizure* 16, 248–253. <https://doi.org/10.1016/j.seizure.2007.01.001>.
- Harkness, K., Kinsella, E., Wade, J., Kitchen, N., Al-Shahi Salman, R., CARE pilot trial collaboration. ABN Abstracts, 2022. Cavernomas: a randomised effectiveness (CARE) trial: treatment with versus without neurosurgery for symptomatic brain cavernoma. Parallel Session 3: acute/Vascular/Trauma|Wed 18 May, 1445 – 1600|J. Neurol. Neurosurg. Psychiatry 93 (9).
- Herten, A., Chen, B., Saban, D., Santos, A.N., Wrede, K.H., Jabbarli, R., Zhu, Y., Schmidt, B., Kleinschnitz, C., Forsting, M., Sure, U., Dammann, P., 2021. Health-related quality of life in patients with untreated cavernous malformations of the central nervous system. *Eur. J. Neurol.* 28, 491–499. <https://doi.org/10.1111/ene.14546>.
- Horne, M.A., Flemming, K.D., Su, I.-C., Stapf, C., Jeon, J.P., Li, D., Maxwell, S.S., White, P., Christianson, T.J., Agid, R., Cho, W.-S., Chang Wan Oh, C.W., Zhen Wu, Z., Zhang, J.-T., Kim, J.E., Brugge, K.T., Willinsky, R., Brown R.D.Jr., Murray, G.D., Al-Shahi Salman, R.; Cerebral Cavernous Malformations Individual Patient Data Meta-analysis Collaborators. Clinical course of untreated cerebral cavernous malformations: a meta-analysis of individual patient data. *Lancet Neurol.* 15, 166–173. [https://doi.org/10.1016/S1474-4422\(15\)00303-8](https://doi.org/10.1016/S1474-4422(15)00303-8).
- Kahn, E., Lane, M., Sagher, O., 2017. Eloquent: history of a word's adoption into the neurosurgical lexicon. *J. Neurosurg.* 127, 1461–1466. <https://doi.org/10.3171/2017.3.JNS17659>.
- Karlsson, B., Kihlström, L., Lindquist, C., Ericson, K., Steiner, L., 1998. Radiosurgery for cavernous malformations. *J. Neurosurg.* 88, 293–297. <https://doi.org/10.3171/jns.1998.88.2.0293>.
- Karlsson, B., Wu, B., Guo, W.Y., Yeo, T.T., 2019. Pseudocavernoma - a new diagnosis? *Acta Neurochir.* 161, 57–61. <https://doi.org/10.1007/s00701-018-3735-1>.
- Kondziolka, D., Lunsford, L.D., Flickinger, J.C., Kestle, J.R., 1995. Reduction of hemorrhage risk after stereotactic radiosurgery for cavernous malformations. *J. Neurosurg.* 83, 825–831. <https://doi.org/10.3171/jns.1995.83.5.0825>.
- Lanfranconi, S., Scola, E., Bertani, G.A., Zarino, B., Pallini, R., d'Alessandris, G., Mazzon, E., Marino, S., Carriero, M.R., Scelzo, E., Farago, G., Castori, M., Fusco, C., Petracca, A., d'Aguma, L., Tassi, L., d'Orto, P., Lampugnani, M.G., Nicolis, E.B., Vasami, A., Novelli, D., Torri, V., Meessen, J.M.T.A., Al-Shahi Salman, R., Dejana, E., Latini, R., Treat-CCM Investigators, 2020. Propranolol for familial cerebral cavernous malformation (Treat CCM): study protocol for a randomized controlled pilot trial. *Trials* 21, 401. <https://doi.org/10.1186/s13063-020-4202-x>.
- Liu, K.D., Chung, W.Y., Wu, H.M., Shiau, C.Y., Wang, L.W., Guo, W.Y., Pan, D.H.-C., 2005. Gamma knife surgery for cavernous hemangiomas: an analysis of 125 patients. *J. Neurosurg.* 102 (Suppl. 1), 81–86. https://doi.org/10.3171/jns.2005.102.s_supplement.0081.
- Lunsford, L.D., Khan, A.A., Niranjan, A., Kano, H., Flickinger, J.C., Kondziolka, D., 2010. Stereotactic radiosurgery for symptomatic solitary cerebral cavernous malformations considered high risk for resection. *J. Neurosurg.* 113, 23–29. <https://doi.org/10.3171/2010.1.JNS081626>.
- Marques, L.L., Jaeggi, C., Branca, M., Raabe, A., Bervini, D., Goldberg, J., 2023. Bleeding risk of cerebral cavernous malformations in patients on statin and antiplatelet medication: a cohort study. *Neurosurgery*. <https://doi.org/10.1227/NEU.0000000000002480> (Online ahead of print).
- McDonald, D.A., Shi, C., Shenkar, R., Stockton, R.A., Liu, F., Ginsberg, M.H., Marchuk, D. A., Awad, I.A., 2012. Fasudil decreases lesion burden in a murine model of cerebral cavernous malformation disease. *Stroke* 43, 571–574. <https://doi.org/10.1161/STROKEAHA.111.625467>.
- Mitha, A.P., Turner, J.D., Robert, F., Spetzler, R.F., 2011. Surgical approaches to intramedullary cavernous malformations of the spinal cord. *Neurosurgery* 68. <https://doi.org/10.1227/NEU.0b013e3182138d6c> [ONS Suppl 2], ons317–ons324.
- Monaco, E.A., Khan, A.A., Niranjan, A., Kano, H., Grandhi, R., Kondziolka, D., Flickinger, J.C., Lunsford, L.D., 2010. Stereotactic radiosurgery for the treatment of symptomatic brainstem cavernous malformations. *Neurosurg. Focus* 29, E11. <https://doi.org/10.3171/2010.7.FOCUS10151>.
- Mouchtouris, N., Chalouhi, N., Chitale, A., Starke, R.M., Tjoumakaris, S.I., Rosenwasser, R.H., Jabbour, P.M., 2015. Management of cerebral cavernous malformations: from diagnosis to treatment. *Sci. World J.*, 808314 <https://doi.org/10.1155/2015/808314>, 2015.
- Nagy, G., Burkitt, W., Stokes, S.S., Bhattacharyya, D., Yianni, J., Rowe, J.G., Kemeny, A. A., Radatz, M.W.R., 2018a. Contemporary radiosurgery of cerebral cavernous malformations, part 1: treatment outcome for critically located hemorrhagic lesions. *J. Neurosurg.* 1–9 <https://doi.org/10.3171/2017.5.JNS17776> (Online ahead of print).
- Nagy, G., Stokes, S.S., Eross, L.G., Bhattacharyya, D., Yianni, J., Rowe, J.G., Kemeny, A. A., Radatz, M.W.R., 2018b. Contemporary radiosurgery of cerebral cavernous malformations, part 2: treatment outcome for hemispheric lesions. *J. Neurosurg.* 1–9 <https://doi.org/10.3171/2018.2.JNS171267> (Online ahead of print).
- Paddock, M., Lanham, S., Gill, K., Sinha, S., Connolly, D.J.A., 2021. Pediatric cerebral cavernous malformations. *Pediatr. Neurol.* 116, 74–83. <https://doi.org/10.1016/j.pediatrneurol.2020.11.004>.
- Pandey, P., Westbroek, E.M., Gooderham, P.A., Steinberg, G.K., 2013. Cavernous malformation of brainstem, thalamus, and basal ganglia: a series of 176 patients. *Neurosurgery* 72, 573–589. <https://doi.org/10.1227/NEU.0b013e318283c9c2>.
- Pollock, B.E., Garces, Y.I., Stafford, S.L., Foote, R.L., Schomberg, P.J., Link, M.J., 2000. Stereotactic radiosurgery for cavernous malformations. *J. Neurosurg.* 93, 987–991. <https://doi.org/10.3171/jns.2000.93.6.0987>.
- Polster, S.P., Stadnik, A., Akers, A.L., Cao, Y., Christoforidis, G.A., Fam, M.D., Flemming, K.D., Girard, R., Hobson, N., Koenig, J.I., Koskimäki, J., Lane, K., Liao, J. K., Lee, C., Lyne, S.B., McBee, N., Morrison, L., Piedat, K., Shenkar, R., Sorrentino, M., Thompson, R.E., Whitehead, K.J., Zeineddine, H.A., Hanley, D.F., Issam A Awad, I.A., 2019. Atorvastatin treatment of cavernous angiomas with symptomatic hemorrhage: exploratory proof of concept (AT CASH EPOC) trial. *Neurosurgery* 85, 843–853. <https://doi.org/10.1093/neuros/nyy539>.
- Radiopaedia, Eloquent cortex, Radiology reference article. <https://radiopaedia.org/articles/eloquent-cortex/2020.DimuzioB, Rasuli B, Deng F, et al. Eloquent cortex, Reference article, Radiopaedia.org, https://doi.org/10.53347/rld-38674> (assessed 16 October 2023).
- Rauschenbach, L., Santos, A.N., Dinger, T.F., Herten, A., Oppong, M.D., Schmidt, B., Chihai, M., Haubold, J., Jabbarli, R., Wrede, K.H., Sure, U., Dammann, P., 2021. Predictive value of intraoperative neuromonitoring in brainstem cavernous malformation surgery. *World Neurosurg.* 156, e359–e373. <https://doi.org/10.1016/j.wneu.2021.09.064>.
- Rauschenbach, L., Bartsch, P., Santos, A.N., Lenkeit, A., Oppong, M.D., Wrede, K.H., Jabbarli, R., Chmielewski, W.X., Schmidt, B., Quesada, C.M., Forsting, M., Sure, U., Dammann, P., 2022a. Quality of life and mood assessment in conservatively treated cavernous malformation-related epilepsy. *Brain Behav.* 12, e2595 <https://doi.org/10.1002/brb3.2595>.
- Rauschenbach, L., Santos, A.N., Gull, H.H., Rieß, C., Deuschl, C., Schmidt, B., Oppong, M. D., Gembruch, O., Özkan, N., Jabbarli, R., Wrede, K.H., Sure, U., Dammann, P.,

- 2022b. Functional impact of multiple bleeding events in patients with conservatively treated spinal cavernous malformations. *J. Neurosurg. Spine* 38, 405–411. <https://doi.org/10.3171/2022.10.SPINE22940>.
- Rauschenbach, L., Santos, A.N., Engel, A., Olbrich, A., Benet, A., Li, Y., Schmidt, B., Gembruch, O., Özkan, N., Jabbarli, R., Wrede, K.H., Siegel, A., Lawton, M.T., Sure, U., Dammann, P., 2023. Functional neurological outcome of spinal cavernous malformation surgery. *Eur. Spine J.* <https://doi.org/10.1007/s00586-023-07640-5> (Online ahead of print).
- Rauscher, S., Santos, A.N., Gull, H.H., Rauschenbach, L., Chen, B., Schmidt, B., Meuschl, C., Benet, A., Jabbarli, R., Wrede, K.H., Siegel, A.M., Lawton, M.T., Sure, U., Dammann, P., 2023. Modifiable vascular risk factors in patients with cerebral and spinal cavernous malformations: a complete 10-year follow-up study. *Eur. J. Neurol.* 30, 1346–1351. <https://doi.org/10.1111/ene.15737>.
- Reinhard, M., Schuchardt, F., Meckel, S., Heinz, J., Felbor, U., Sure, U., Geisen, U., 2016. Propranolol stops progressive multiple cerebral cavernoma in an adult patient. *J. Neurol. Sci.* 367, 15–17. <https://doi.org/10.1016/j.jns.2016.04.053>.
- Rosenow, F., Alonso-Vanegas, M.A., Baumgartner, C., Blümcke, I., Carreño, M., Gizewski, E.R., Hamer, H.M., Knake, S., Kahane, P., Lüders, H.O., Mathern, G.W., Menzler, K., Miller, J., Otsuki, T., Ozkara, C., Pitkänen, A., Roper, S.N., Sakamoto, A. C., Sure, U., Walker, M.C., Steinhoff, B.J., Surgical Task Force, Commission on Therapeutic Strategies of the ILAE, 2013. Cavernoma-related epilepsy: review and recommendations for management: report of the surgical task force of the ILAE commission on therapeutic strategies. *Epilepsia* 54, 2025–2035. <https://doi.org/10.1111/epi.12402>.
- Sala, F., Palandri, G., Basso, E., Lanteri, P., Deletis, V., Faccioli, F., Bricolo, A., 2006. Motor evoked potential monitoring improves outcome after surgery for intramedullary spinal cord tumors: a historical control study. *Neurosurgery* 58, 1129–1141. <https://doi.org/10.1227/01.NEU.0000215948.97195.58>.
- Santos, A.N., Rauschenbach, L., Oppong, M.D., Chen, B., Hertent, A., Forsting, M., Sure, U., Dammann, P., 2020. Assessment and validation of proposed classification tools for brainstem cavernous malformations. *J. Neurosurg.* 1–7. <https://doi.org/10.3171/2020.6.JNS201585> (Online ahead of print).
- Santos, A.N., Rauschenbach, L., Oppong, M.D., Gembruch, O., Saban, D., Chen, B., Hertent, A., Schmidt, B., Li, Y., Özkan, N., Jabbarli, R., Wrede, K., Sure, U., Dammann, P., 2021a. Natural course of untreated spinal cord cavernous malformations: a follow-up study within the initial 5 years after diagnosis. *J. Neurosurg. Spine* 1–5. <https://doi.org/10.3171/2021.9.SPINE211052> (Online ahead of print).
- Santos, A.N., Rauschenbach, L., Saban, D., Chen, B., Hertent, A., Dinger, T.F., Li, Y., Tippelt, S., Marina, A.D., Dohna-Schwake, C., Schmidt, B., Jabbarli, R., Wrede, K.H., Sure, U., Dammann, P., 2021b. Natural course of cerebral cavernous malformations in children: a five-year follow-up study. *Stroke* 53, 817–824. <https://doi.org/10.1161/STROKEAHA.121.035338>.
- Santos, A.N., Rauschenbach, L., Saban, D., Chen, B., Oppong, M.D., Hertent, A., Gull, H. H., Rief, C., Deuschl, C., Schmidt, B., Jabbarli, R., Wrede, K.H., Zhu, Y., Frank, B., Sure, U., Dammann, P., 2022a. Multiple cerebral cavernous malformations: clinical course of confirmed, assumed and non-familial disease. *Eur. J. Neurol.* 29, 1427–1434. <https://doi.org/10.1111/ene.15253>.
- Santos, A.N., Rauschenbach, L., Gull, H.H., Olbrich, A., Lahl, K., Oppong, M.D., Dinger, T.F., Rief, C., Chen, B., Lenkeit, A., Schmidt, B., Li, Y., Jabbarli, R., Wrede, K. H., Sure, U., Dammann, P., 2022b. Central nervous system cavernous malformations: cross-sectional study assessing rebleeding risk after 2nd hemorrhage. *Eur. J. Neurol.* 30, 144–149. <https://doi.org/10.1111/ene.15574>.
- Santos, A.N., Rauschenbach, L., Gull, H.H., Dinger, T.F., Chih, M., Li, Y., Tippelt, S., Dohna-Schwake, C., Schmidt, B., Jabbarli, R., Wrede, K.H., Sure, U., Dammann, P., 2023. Functional outcome after initial and multiple intracerebral hemorrhage in children with cerebral cavernous malformations. *Eur. J. Neurol.* 30, 1364–1370. <https://doi.org/10.1111/ene.15749>.
- Schneble, H., Soumare, A., Herve, D., Bresson, D., Guichard, J.-P., Riant, F., Tournier-Lasserre, E., Tzourio, C., Chabriat, H., Stapf, C., 2012. Antithrombotic therapy and bleeding risk in a prospective cohort of patients with cerebral cavernous malformation. *Stroke* 43, 3196–3199. <https://doi.org/10.1161/STROKEAHA.112.668533>.
- Stavrou, I., Baumgartner, C., Frischer, J.M., Trattning, S., Knosp, E., 2008. Long term seizure control after resection of supratentorial cavernomas: a retrospective single-center study in 53 patients. *Neurosurgery* 63, 888–896. <https://doi.org/10.1227/01.NEU.0000327881.72964.6E>.
- Stefan, H., Hammen, T., 2004. Cavernous haemangiomas, epilepsy and treatment strategies. *Acta Neurol. Scand.* 110 <https://doi.org/10.1111/j.1600-0404.2004.00333.x>, 393–399.
- Taslimi, S., Modabbernia, A., Amin-Hanjani, S., Barker, F.G., Macdonald, R.L., 2016. Natural history of cavernous malformation: systematic review and meta-analysis of 25 studies. *Neurology* 86, 1984–1991. <https://doi.org/10.1212/WNL.00000000000002701>.
- Van Gompim, J.J., Rubio, J., Cascino, G.D., Worrell, G.A., Meyer, F.B., 2009. Electro-corticography-guided resection of temporal cavernoma: is electrocorticography warranted and does it alter the surgical approach? Clinical article. *J. Neurosurg.* 110, 1179–1185. <https://doi.org/10.3171/2008.10.JNS08722>.
- Vishteh, A.G., Sankhla, S., Anson, J.A., Zabramski, J.M., Spetzler, R.F., 1997. Surgical resection of intramedullary spinal cord cavernous malformations: delayed complications, long-term outcomes, and association with cryptic venous malformations. *Neurosurgery* 41, 1094–1100. <https://doi.org/10.1097/00006123-199711000-00013>.
- Von der Brölie, C., Schramm, J., 2011. Cerebral cavernous malformations and intractable epilepsy: the limited usefulness of current literature. *Acta Neurochir.* 153, 249–259. <https://doi.org/10.1007/s00701-010-0915-z>.
- Washington, C.W., McCoy, K.E., Zipfel, G.J., 2010. Update on the natural history of cavernous malformations and factors predicting aggressive clinical presentation. *Neurosurg. Focus* 29, E7. <https://doi.org/10.3171/2010.5.FOCUS10149>.
- Weiner, G.M., Ducruet, A.F., 2017. Fasudil slows development of cavernous malformations. *Neurosurgery* 80, N25–N27. <https://doi.org/10.1093/neuros/nyx100>.
- Winter, F., Blair, L., Buchfelder, M., Roessler, K., 2021. Risk factors for poor post-operative outcome and epileptic symptoms in patients diagnosed with cerebral cavernous malformations. *J. Neurol. Surg. Cent. Eur. Neurosurg.* 82, 59–63. <https://doi.org/10.1055/s-0040-1715496>.
- Zabramski, J.M., Kalani, M.Y., Filippidis, A.S., Spetzler, R.F., 2016. Propranolol treatment of cavernous malformations with symptomatic hemorrhage. *World Neurosurg.* 88, 631–639. <https://doi.org/10.1016/j.wneu.2015.11.003>.
- Zevgaridis, D., vanVelthoven, V., Ebeling, U., Reulen, H.J., 1996. Seizure control following surgery in supratentorial cavernous malformations: a retrospective study in 77 patients. *Acta Neurochir.* 138, 672–677. <https://doi.org/10.1007/BF01411470>.
- Zuurbier, S.M., Hickman, C.R., Tolia, C.S., Rinkel, L.A., Leyrer, R., Flemming, K.D., Bervini, D., Lanzino, G., Wityk, R.J., Schneble, H.-M., Sure, U., Al-Shahi Salman, R., Scottish Audit of Intracranial Vascular Malformations Steering Committee, 2019. Long-term antithrombotic therapy and risk of intracranial haemorrhage from cerebral cavernous malformations: a population-based cohort study, systematic review, and meta-analysis. *Lancet Neurol.* 18, 935–941. [https://doi.org/10.1016/S1474-4422\(19\)30231-5](https://doi.org/10.1016/S1474-4422(19)30231-5).

Anastasia Tasiou^{*}, Alexandros G. Brotis, Adamantios Kalogeras,
Christos Tzerefos
Department of Neurosurgery, University Hospital of Larissa, Faculty of
Medicine, University of Thessaly, Larissa, Greece

Cargill H. Alleyne Jr.
Cerebrovascular Service, Piedmont Augusta, Augusta, GA, USA

Alexandros Andreou
Department of Neurosurgery and Interventional Neuroradiology, Hygeia
Hospital, Athens, Greece

Andreas K. Demetriades
Department of Neurosurgery, Royal Infirmary Edinburgh, Scotland, UK

Nikolaos Foroglou
Department of Neurosurgery, AHEPA University Hospital, School of
Medicine, Aristotle University of Thessaloniki, Thessaloniki, Greece

Robert M. Friedlander
Department of Neurological Surgery, University of Pittsburgh Medical
Center, University of Pittsburgh School of Medicine, Pittsburgh, PA, USA

Bengt Karlsson
Department of Surgery, Division of Neurosurgery, National University
Hospital Singapore, Singapore

Neil Kitchen
Victor Horsley Department of Neurosurgery, National Hospital for
Neurology and Neurosurgery, Queen Square, London, UK

Torstein R. Meling
Department of Neurosurgery, The National Hospital, Copenhagen, Denmark
Department of Neurological Surgery, Istituto Nazionale Neurologico “C.
Besta”, Milan, Italy

Aristotelis Mitsos
Department of Neurosurgery, 401 General Military Hospital of Athens,
Athens, Greece

Vasilios Panagiotopoulos
Department of Neurosurgery, University Hospital of Patras, Patra, Greece

Themistoklis Papisilekas
Department of Neurosurgery, Athens University Medical School,
Evangelismos General Hospital, Athens, Greece

Giacomo Pavesi
Unit of Neurosurgery, Department of Biomedicine, Metabolic Sciences and
Neurosciences, University of Modena and Reggio Emilia, Modena, Italy

Lukas Rasulic
Faculty of Medicine, University of Belgrade, Clinic for Neurosurgery,
University Clinical Center of Serbia, Belgrade, Serbia

Alejandro N. Santos
Department of Neurosurgery and Spine Surgery, University Hospital Essen,
Essen, Germany
Center for Translational Neuro- and Behavioral Sciences (C-TNBS),
University Duisburg Essen, Essen, Germany

Robert F. Spetzler
Department of Neurosurgery, Barrow Neurological Institute, Phoenix, AZ,
USA

Ulrich Sure
Department of Neurosurgery and Spine Surgery, University Hospital Essen,
Essen, Germany

Stavropoula Tjoumakaris
Department of Neurosurgery, Thomas Jefferson University Hospital, Sidney
Kimmel Medical College, Philadelphia, PA, USA

Christos M. Toliadis
Department of Neurovascular Surgery, Kings College Hospital, London, UK

Peter Vajkoczy
Department of Neurosurgery, Charite University Hospital Berlin, Berlin,
Germany

Kostas N. Fountas
Department of Neurosurgery, University Hospital of Larissa, Faculty of
Medicine, University of Thessaly, Larissa, Greece

* Corresponding author. Department of Neurosurgery, Building A, 3rd
Floor, University Hospital of Larissa Biopolis, Larissa, 41110, Greece.
E-mail address: ttasiou@yahoo.com (A. Tasiou).