

Cherubism: Report of a case

VIKAS ELIAS KURUVILLA, VARGHESE MANI¹, BILAHARI N.², RANJITH KUMAR³

Abstract

Cherubism is an uncommon fibro-osseous disorder of the jaw that presents with varying degrees of involvement and tendency towards spontaneous remission. Children are normal at birth and the expanding jaw is noticed within the first year of life becoming progressively larger until the beginning of adolescence. Lesions are characterized by replacement of bone with fibrovascular tissue containing abundant multinucleated giant cells. Here, we describe a case of cherubism in a 4-year-old child with swelling on both sides of mandible with clinic radiographic features and suggestions for therapy.

Keywords: Cherubism, mandible, pathogenesis

Introduction

Cherubism is a rare, non-neoplastic, self-limiting fibro-osseous disease, which is characterized by painless expansion of the mandible or maxilla or both. Cherubism received its name because of the angel-like appearance of the patients (chubby and upward directed look) - Jones (1933). It is generally accepted that it is a benign, hereditary, disease of bone, beginning at the age of 2 or 3 years, progressive in childhood, with a peak at the age of five and showing spontaneous regression at the end of adolescence.^[1]

Cherubism is a familial disease in which the trait is transmitted in an autosomal dominant fashion with 100% penetrance in males and 50-70% penetrance in females.^[2] Mangion and Tiziani *et al.*, (1999) showed that the gene region responsible for cherubism is located on chromosome 4p16.3.^[3,4] Ueki *et al.*, (2001) found mutations in the gene for the SRC Homology 3 Domain Binding Protein 2.^[5]

The diagnosis of cherubism is based on clinical, radiographic

and histological findings. The clinical findings are: Familial occurrence, pronounced bilateral involvement of the jaws in early childhood, high arched palate, missing second and third molars, Indolent lymph node swellings, spontaneous arrest or regression after adolescence and absence of involvement of the temporomandibular joint.^[1]

Radiographically, the bones, which are involved, show a multilocular radiolucency with thin and expanded cortices, including the inferior border. The condyle and the condylar neck appear normal. Unerupted and displaced teeth are common. Cases show symmetric involvement both radiographically and clinically. Computerized tomography (CT) showed honeycomb-like lesions of the mandibular cortical bone. In the upper jaws, the tuberosity area is affected, with occlusion of the maxillary sinus and sometimes elevation of the orbital floor.^[2]

The microscopic appearance of the tissues from the involved jaws is sometimes characterized by the presence of great numbers of large multinucleated giant cells in a loose, delicate fibrillar connective tissue stroma containing large numbers of fibroblasts and many small blood vessels. In addition, a peculiar perivascular, eosinophilic cuffing of the small capillaries in the lesions is sometimes found.^[6,7]

Seward and Hankey (1957)^[8] suggested a grading system for cherubism.

- Grade I: Involvement of bilateral mandibular molar regions and ascending rami, mandible body, or mentis
- Grade II: Involvement of bilateral maxillary tuberosities (in addition to grade 1 lesions) and diffuse mandibular involvement
- Grade III: Massive involvement of the entire maxilla and mandible, except the condyles
- Grade IV: Involvement of both jaws, including the condyles.^[8]

Case Report

A 4-year-old boy presented with painless bilateral swelling of the mandible. When the boy was about 2 years old, the parents had noticed a change in facial symmetry of the face,

Departments of Oral and Maxillofacial Surgery and ²Oral Medicine and Radiology, PSM College of Dental Science, Akkikkavu, Thrissur; ¹Oral and Maxillofacial Surgery, Mar Baselius Dental College, Kothamangalam, Ernakulam, ³Prosthodontics, Royal Dental College, Chalissery, Kerala, India

Correspondence: Dr. Vikas Elias Kuruvilla, Department of Oral and Maxillofacial Surgery, PSM College of Dental Science, Akkikkavu, Thrissur, Kerala, India.
E-mail: kordent2004@yahoo.com

Access this article online	
Quick Response Code: 	Website: www.contempclindent.org
	DOI: 10.4103/0976-237X.118344

which later on became more marked [Figure 1]. Intraorally the alveolar ridges were swollen at the angle region and were firm on palpation. Patient had moderate bilateral submandibular lymph node enlargement. Physical and mental development was normal. Patient's parents are healthy had no siblings and none of their relatives had facial deformities.

Radiographically, the mandible showed a multilocular radiolucency with thin and expanded cortices, including the body and posterior rami bilaterally. The condyle and the condylar neck appeared normal. Maxilla was not involved. The second permanent molar bud was missing considering the age. Radiographically and clinically, symmetric involvement was evident [Figure 2]. CT scan revealed expansile remodeling with multiple osteolytic areas in the mandible [Figure 3]. Laboratory tests, which included serum calcium, phosphorous, alkaline phosphatase and parathyroid hormone were normal.

Biopsy from the central area of both right and the left rami were taken. Histopathological examination showed fibrovascular collagenous connective tissue with dispersed giant cells [Figure 4]. Patient was recalled after 4 years and patient was asymptomatic; however, the facial asymmetry was evident [Figure 5]. Follow-up orthopantomogram also showed multilocular radiolucencies within the posterior body and rami of mandibular region bilaterally [Figure 6]. As the condition tends to resolve around 15 years of age, patient is kept under periodic follow-up.

Discussion

The clinical features observed in our patient were similar to those stated in previous studies.^[2]

The painless enlargement of the submandibular lymph nodes frequently described in children with cherubism is probably a physiologic hyperplasia.^[9] Von Wowern *et al.*, (2000) suggested it could be due to the high osteoclastic activity.^[9]

Syndromes related with cherubism are Ramon syndrome (Cherubism, short stature, mental retardation and gingival fibromatosis), Noonan syndrome (dysmorphic features, developmental delay, short stature, mild mental retardation, cardiac anomaly, pulmonary stenosis, cryptorchidism in males and giant-cell lesions of bones and soft-tissues). This case lacked significant findings, which were suggestive of any known syndromes.

Several familial studies from different countries have postulated that cherubism is a hereditary condition, transmitted in an autosomal dominant pattern. A molecular pathogenesis of cherubism has been proposed: SH3BP2 gene mutations cause dysregulation of the Msx-1 gene, which is involved in regulating mesenchymal interaction in craniofacial

morphogenesis. In an affected individual, increased bone activity occurs between age 2.5 and 10-12 years, due to the up-regulation of Msx-1. Dysfunction of Msx-1 stops at the end of molar development, leading to remineralization of lesions.^[2]

Isolated single cases of cherubism have been reported in the literature, most of them based on history reported by the affected family members, who had not noticed any facial alteration in other relatives. In our non-familial case, beyond the history provided by the patient's parent, we observed close relatives for cherubic features; however, we could not find any.

Our case falls into grade - 1 category since only body of the mandible and rami were involved. Various studies indicate that the state of normalization is reached faster in patients of grade - 1 than of higher grades of cherubism.^[5] Condyle was not involved and this was in accordance with various literatures.

Raposo-Amaral CE *et al.*, (2007) speculate that cherubism is a disease of odontogenic origin as told by Jones but they also suggested a hypotheses that condyles and zygomatic arches are not affected because tooth buds do not develop in these skeletal segments. Unknown to Jones, the SH3BP2 mutation leading to parathyroid hormone chaperone protein disruption of normal tooth germ development lends additional support to this hypothesis.^[10]

In general, cherubism does not involve other parts of the skeleton or the bone metabolism, because the biochemical bone markers serum calcium, phosphorus and alkaline phosphatase have been found within the normal ranges with respect to age.

An eosinophilic perivascular cuffing of collagen is considered characteristic of cherubism; however, this feature is frequently absent as in our case. Clinical and radiographic correlation is necessary as the histologic features strongly resemble those seen in central giant cell tumors and the lesions of hyperparathyroidism.^[11]

Immunohistochemistry characterization of multinucleated giant cells reveals that these are osteoclasts since they are positive for tartrate resistant acid phosphatase.^[12] Immunohistochemistry was not done in our case.

Recommended therapy ranges from radical surgical removal to an attitude of wait and watch.

Excision of tissue is suggested in aggressive cases (grade-3) to reduce maxillofacial deformity after puberty and to ensure a successful outcome without the risk of progression requiring additional resection. According to Raposo-Amaral *et al.*, early 2-stage surgical curettage was found to be a reliable treatment

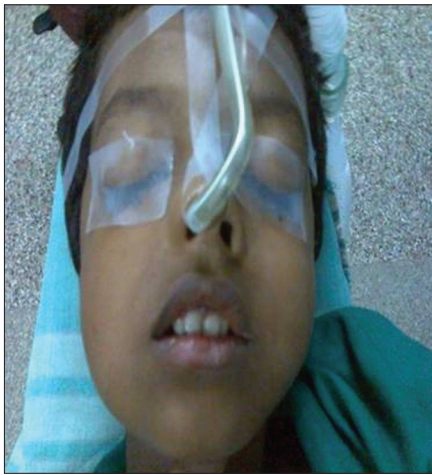

Figure 1: Preoperative clinical picture

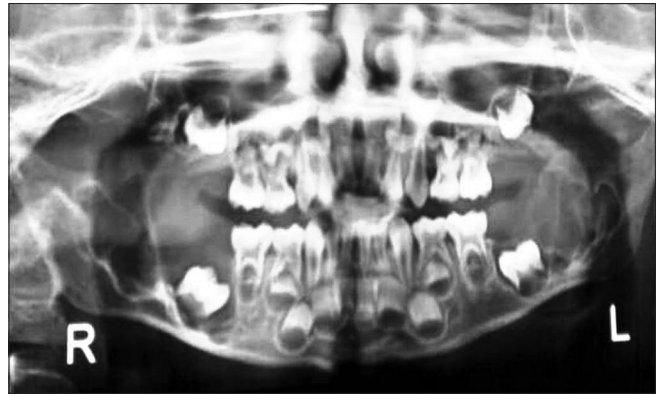


Figure 2: Pre-operative orthopantomogram

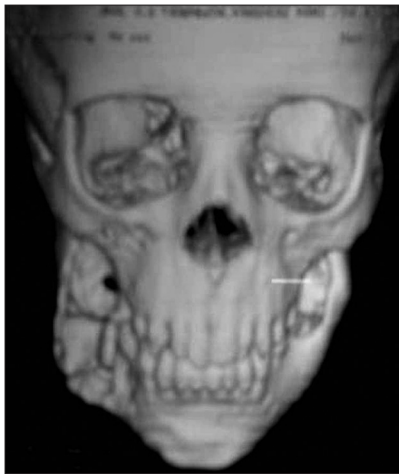

Figure 3: Pre-operative computerized tomography

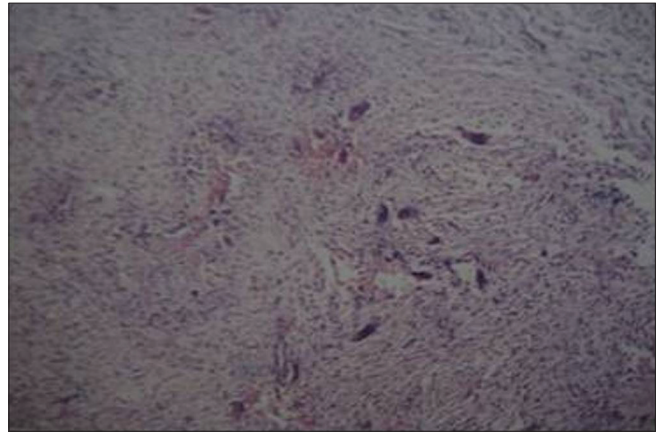


Figure 4: Histopathology

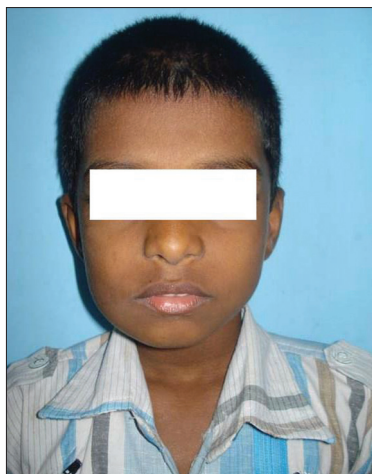

Figure 5: Follow-up picture

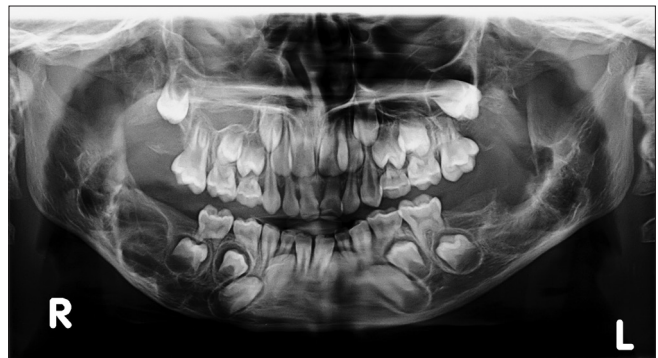

Figure 6: Follow-up orthopantomogram

that delivers immediate results and arrest the growth of any remaining cherubic tissue.^[10] Attempts to control this disease with radiotherapy have to be rejected completely. Osteosarcoma in the irradiated area is a possibility.^[13]

Calcitonin was tried as it inhibits the osteoclastic activity of the giant cells, but with varying results.^[14]

The general clinical approach is to avoid surgery altogether and allow natural involution to take place or defer surgeries until after puberty. If osseous contouring is required because of pain or psychological needs, it is done with the knowledge that the operated bone will re-expand at the same or may accelerate the rate of expansion, but the limited experience with surgery on these patients does not support this concern.

Based on the genetic mutations related to the disease, gene therapy is expected to play a role in future treatment.

References

1. Hyckel P, Berndt A, Schleier P, Clement JH, Beensen V, Peters H, *et al.* Cherubism-new hypotheses on pathogenesis and therapeutic consequences. *J Craniomaxillofac Surg* 2005;33:61-8.
2. Carvalho Silva E, Carvalho Silva GC, Vieira TC. Cherubism: Clinicoradiographic features, treatment, and long-term follow-up of 8 cases. *J Oral Maxillofac Surg* 2007;65:517-22.
3. Mangion J, Rahman N, Edkins S, Barfoot R, Nguyen T, Sigurdsson A, Townend JV, Fitzpatrick DR, Flanagan AM, Stratton MR: The gene for cherubism maps to chromosome 4p16.3. *Am J Hum Genet* 1999;65:151-7.
4. Tiziani V, Reichenberger E, Buzzo CL, Niazi S, Fukai N, Stiller M, Peters H, Salzano FM, Raposo do Amaral CM, Olsen BR: The gene for cherubism maps to chromosome 4p16. *Am J Hum Genet* 1999;65:158-66.
5. Ueki Y, Tiziani V, Santanna C, Fukai N, Maulik C, Garfinkle J, *et al.* Mutations in the gene encoding c-Abl-binding protein SH3BP2 cause cherubism. *Nat Genet* 2001;28:125-6.
6. Shafer WG, Hine MK, Levy BM. Diseases of bone and joints. *A Textbook of Oral Pathology*, 4th ed. Philadelphia: W.B. Saunders Company; 1997. p. 701-2.
7. Marx RE, Stern D. Fibro-osseous diseases and systemic diseases affecting bone. *Oral and Maxillofacial Pathology: A Rationale for Diagnosis and Treatment*, 1st ed. Illinois: Quintessence Publishers; 2003. p. 744-5.
8. Seward GR, Hankey GT. Cherubism. *Oral Surg Oral Med Oral Pathol.* 1957;10:952-74.
9. Von Wowern N. Cherubism: A 36-year long-term follow-up of 2 generations in different families and review of the literature. *Oral Surg Oral Med Oral Pathol Oral Radiol Endod* 2000;90:765-72.
10. Raposo-Amaral CE, de Campos Guidi M, Warren SM, Almeida AB, Amstalden EM, Tiziane V, *et al.* Two-stage surgical treatment of severe cherubism. *Ann Plast Surg* 2007;58:645-51.
11. Peñarrocha M, Bonet J, Mínguez JM, Bagán JV, Vera F, Mínguez I. Cherubism: A clinical, radiographic, and histopathologic comparison of 7 cases. *J Oral Maxillofac Surg* 2006;64:924-30.
12. Meng XM, Yu SF, Yu GY. Clinicopathologic study of 24 cases of cherubism. *Int J Oral Maxillofac Surg.* 2005;34:350-6.
13. Lima G de M, Almeida JD, Cabral LA. Cherubism: Clinicoradiographic Features and Treatment. *J Oral Maxillofac Res* 2010;1:e2
14. de Lange J, van den Akker HP, Scholtemeijer M. Cherubism treated with calcitonin: Report of a case. *J Oral Maxillofac Surg* 2007;65:1665-7.

How to cite this article: Kuruvilla VE, Mani V, Bilahari N, Kumar R. Cherubism: Report of a case. *Contemp Clin Dent* 2013;4:356-9.

Source of Support: Nil. **Conflict of Interest:** None declared.