

Received: 2012.07.12
Accepted: 2012.08.09

MRI patterns of hypoxic-ischemic brain injury in preterm and full term infants – classical and less common MR findings

Astra Cabaj, Monika Bekiesińska-Figatowska, Jarosław Mądzik

Department of Diagnostic Imaging, Institute of Mother and Child, Warsaw, Poland

Author's address: Monika Bekiesińska-Figatowska, Department of Diagnostic Imaging, Institute of Mother and Child, Kasprzaka 17a Str., 01-211 Warsaw, Poland, e-mail: zaklad.rtg@imid.med.pl

Summary

Hypoxic-ischemic brain injury occurring in antenatal, perinatal or early postnatal period constitutes an important diagnostic problem in both term and prematurely born neonates. Over the past several years magnetic resonance imaging (MRI) has become relatively easily accessible in Poland. On the basis of the central nervous system MRI, the experienced radiologists are able to determine the location of the hypoxic-ischemic lesions, their extent and evolution. Therefore he can help clinicians to answer the question whether the brain damage of the newborn is responsible for its clinical condition and he can contribute to determining the prognosis of the infant's future development. The aim of this study is to present the current knowledge of different types of hypoxic-ischemic brain lesions based on our personal experience and MR images from the archives of the Department of Diagnostic Imaging at the Institute of Mother and Child.

Key words: magnetic resonance imaging (MRI) • neonate • central nervous system (CNS) • hypoxic-ischemic encephalopathy (HIE)

PDF file: <http://www.polradiol.com/fulltxt.php?ICID=883379>

Background

25% of the world's newborn deaths are associated with perinatal brain injury resulting from hypoxic-ischemic lesions [1].

Diagnostic test of choice for the detection of these lesions is cranial ultrasound (transfontanel ultrasound). This test is non-invasive, readily available and reproducible, but it can only reveal the most severe hypoxic-ischemic lesions and it lacks prognostic significance [2].

This commonly used method is perfectly complemented by magnetic resonance imaging (MRI), an increasingly available and non-invasive examination (may be performed during the child's physiological sleep) which, unlike the computed tomography, does not involve the child's exposure to X-ray. MRI allows to reveal a number of lesions associated with HIE that are invisible on the ultrasound scans (i.e. cortico-subcortical lesions within the central region, bilateral parasagittal lesions and brain stem, thalamus, cerebellum and hippocampus lesions). Another MRI advantage

is the possibility to predict the clinical consequences of hypoxic-ischemic lesions [2].

MRI of Hypoxic-Ischemic Lesions

The subject literature describes three main MR patterns of hypoxic-ischemic lesions:

1. *periventricular leukomalacia – PVL*,
2. *basal ganglia and/or thalamus lesions – BGTL*,
3. and *multicystic encephalopathy – MCE* accompanied by injury to the basal ganglia, thalamus and/or cerebral cortex [3].

In preterm infants (mostly those born between 32 and 36 week of gestation – [4]) with a history of chronic hypoxia, CNS damage manifests itself as the first type of the above-mentioned injuries. Their differentiation from non-myelinated white matter of a normal newborn brain can be difficult and the assessment requires an experienced radiologist. MRI examination repeated in an older child, preferably above 2, reveals hyperintense in T2-weighted and FLAIR images periventricular gliosis rim, dilatation

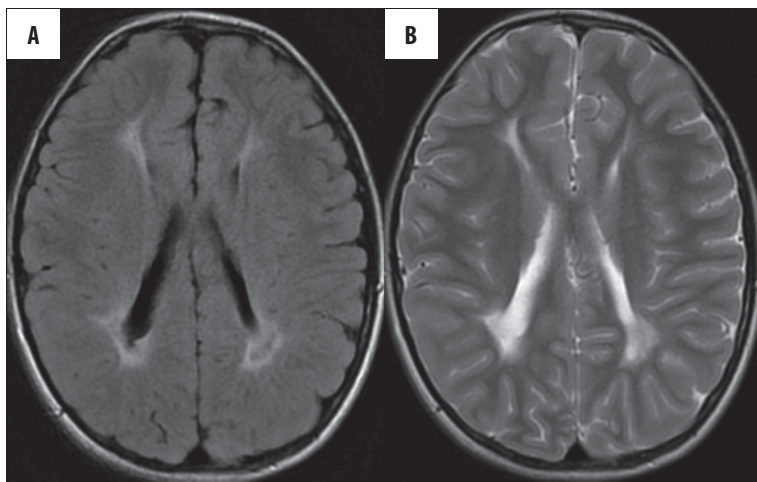


Figure 1. Bilateral, symmetrical paraventricular gliosis, uneven external outlines of the lateral ventricles, thinning of the white matter layer – classic pattern of hypoxic-ischemic lesions in a child born between 32 and 36 week of gestation. (A) FLAIR,ax; (B) FSE/T2,ax.

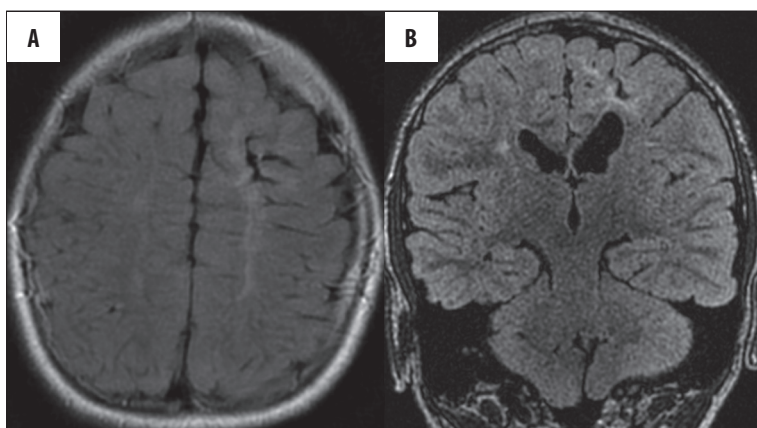


Figure 2. Involvement of the subcortical white matter in a child born after 36 week of gestation. Atypical asymmetric lesions. (A) FLAIR,ax; (B) CUBE/3D/FLAIR,cor.

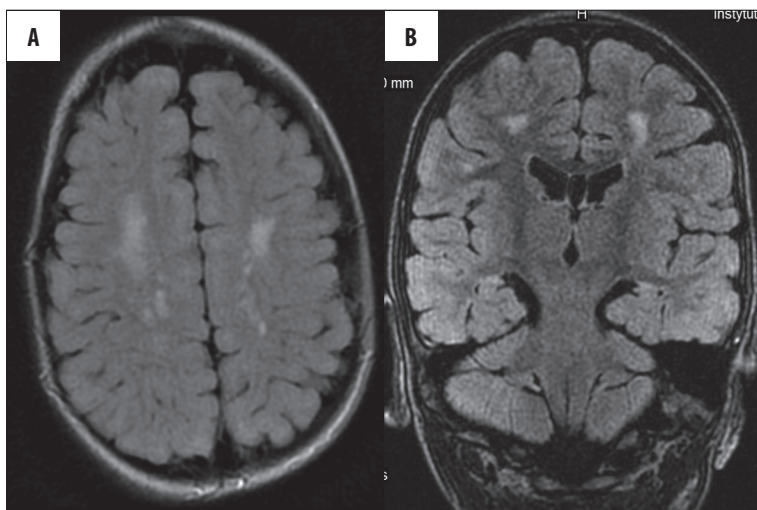


Figure 3. A rare case of isolated injury to subcortical white matter with no damage to periventricular white matter. (A) FLAIR,ax; (B) CUBE/3D/FLAIR,cor.

of lateral ventricles with uneven external outlines and considerable deepening of the convexity sulci that almost reach the side ends of the lateral ventricles. Typically the lesions are bilateral and symmetrical (Figure 1).

In late preterm newborns (born after 36 weeks of gestation) the injury involves the subcortical white matter as well. Their periventricular white matter is abnormal. Typically the lesions are symmetrical, though less often they can be asymmetric (Figure 2).

In our material we were also able to find very rare cases of isolated damage to the subcortical white matter without injury to the periventricular white matter (Figure 3).

Acute and severe hypoxia in term infants results in damage to the gray matter, especially the basal ganglia and thalamus (type 2 lesions) (Figure 4).

These lesions, also known as selective neuronal necrosis [2] are usually bilateral, and their range depends on the

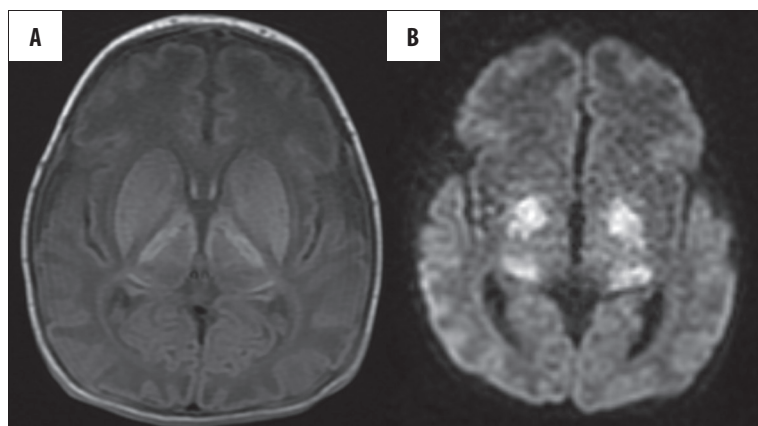


Figure 4. Injury of basal ganglia and thalamus in a term newborn – features of acute asphyxia. The lesions are hyperintense in all types of sequences (T1, T2, FLAIR) they show diffusion restriction. (A) SE/T1,ax; (B) DWI.

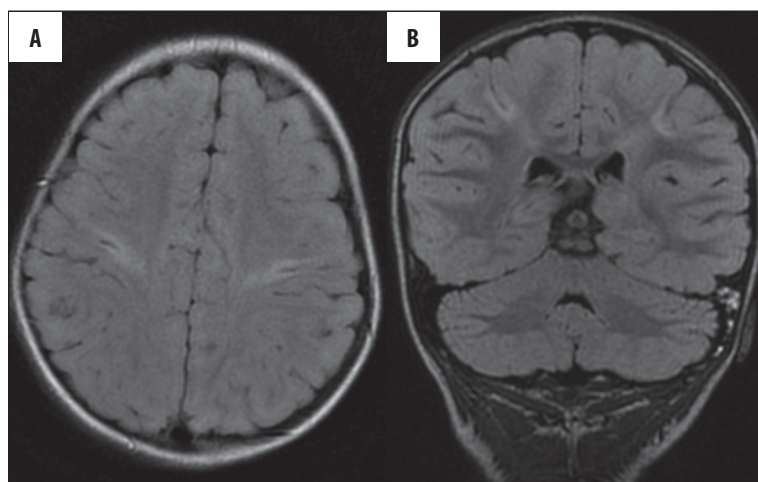


Figure 5. Cerebral cortex and white matter injury in a term newborn after acute asphyxia. (A) FLAIR,ax; (B) CUBE/3D/FLAIR,cor.

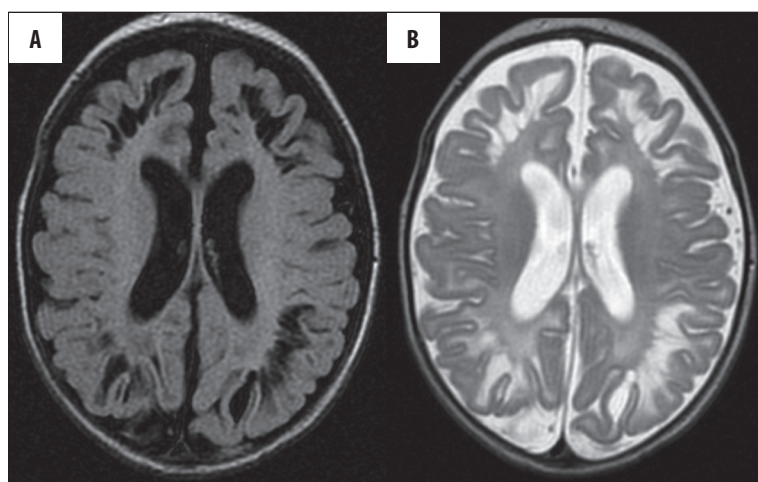


Figure 6. Multicystic encephalopathy in a 5-week-old child, visible despite therapeutic hypothermia. (A) FLAIR,ax; (B) FSE/T2,ax.

severity and duration of the hypoxic-ischemic event [5]. Rutherford described three stages of the selective neuronal necrosis – mild, moderate and severe.

Normal signal from the posterior limb of the internal capsule on T1 and T2-weighted images and focal character of the lesions visible in the basal ganglia are typical of mild selective neuronal necrosis. Moderate form of this condition is characterized by altered signal from the posterior limb of the internal capsule and the focal changes involve posterolateral part of the lenticular nucleus and lateral part of

the thalamus. A severe form of selective neuronal necrosis is always associated with altered signal from the posterior limb of the internal capsule, the changes in the basal ganglia are diffuse, include the head of the caudate nucleus and can extend to mesencephalon. Frequently the signal from the cerebral cortex and white matter is also altered (Figure 5).

Another author treats the severe form of selective neuronal necrosis as a separate type of injury – a cavity within the white matter with the involvement of basal ganglia, thalamus and/or cerebral cortex (type 3) [3].

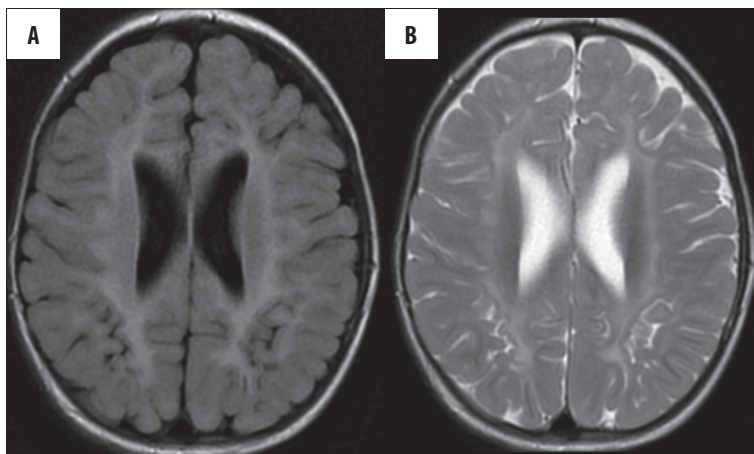


Figure 7. The same child as in Figure 6, aged 2 years and 4 months. Extremely rare case of cystic lesion regression. (A) FLAIR,ax; (B) FSE/T2,ax.

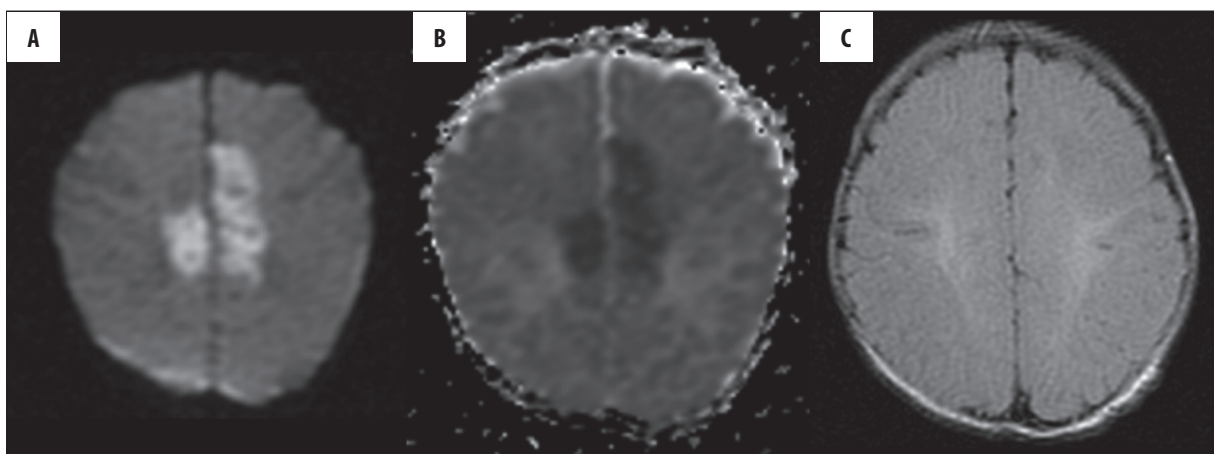


Figure 8. Acute, parasagittal brain injury, visible only in the DWI sequence. (A) DWI; (B) ADC; (C) FLAIR – undetectable lesions.

Extensive multicystic involvement of white matter (Figure 6), quite often accompanied by necrotic cavities within the basal ganglia and thalamus is typical for a prolonged and severe hypoxia.

This type of injury is more often found in term than preterm newborns and the prognosis is unfavourable. However, the child brain shows exceptional malleability and regenerative properties. Thanks to these features in rare cases the injuries can withdraw, even such heavy ones as the cavities in the white matter. The few cases of this phenomenon have been described in the literature [3] and we found one such case in our material (Figure 7).

Parasagittal brain injury is diagnosed less frequently than selective neuronal necrosis and is characteristic for mild or moderate, subacute hypoxia. It is located on the border of the vascular territories – parasagittally, bilaterally and includes the cerebral cortex and the adjacent white matter (Figure 8) [2,6].

More and more studies have shown that brain injury exponents are more closely related to the type of hypoxia-ischemia rather than to the maturity of the central nervous system at the time of the injury. Acute and severe hypoxia in preterm infants usually results in BGTL, characteristic for term infants, while term newborns after moderate and prolonged hypoxia develop PVL [3,7-9] This is explained by

the fact that acute and severe asphyxia limits the oxygen supply to the whole brain, resulting in damage to the regions of high metabolic activity and higher density of glutamate receptors, i.e. basal ganglia and thalamus. In the case of subacute, mild hypoxia there is enough time to direct the blood into these important areas, so they are not injured [10,11].

MRI Protocols

Literature suggested protocol of MRI scans for a newborn after the hypoxic-ischemic event should include:

- axial T1- and T2-weighted images, slice thickness 4 mm,
- sagittal T1-weighted images, slice thickness: 1.5–3 mm,
- coronal T2-weighted images, slice thickness: 4 mm,
- DWI,
- venous MRA,
- arterial MRA,
- MR spectroscopy (MRS),
- alternative scan after administration of a contrast medium if CNS infection is suspected (after examination of renal function) [12].

In everyday clinical practice at our center the scans are performed when the newborns are physiological asleep (only in very rare cases they require anesthesia) and we use a shortened protocol which, in majority of cases, allows us to obtain diagnostic images free from motion artifacts associated with the child awakening:

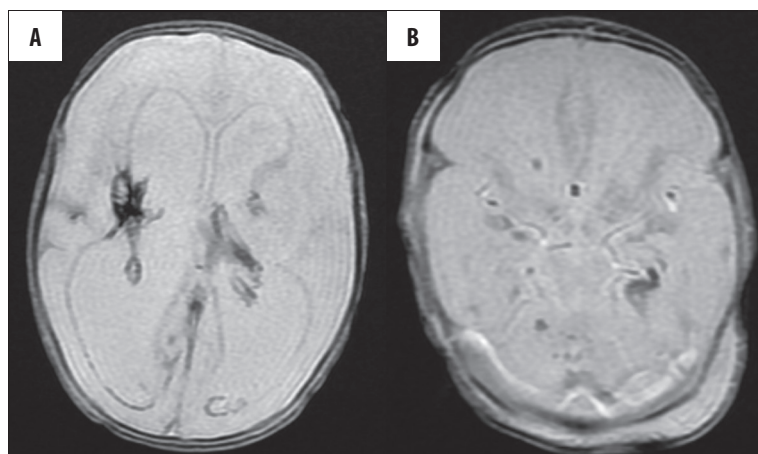


Figure 9. Intraventricular or intraparenchymal hemorrhage resulting from hypoxic-ischemic event in two different neonates born before 32 week of gestation. GRE/T2*,ax. (A) within supratentorial compartment; (B) infratentorial.

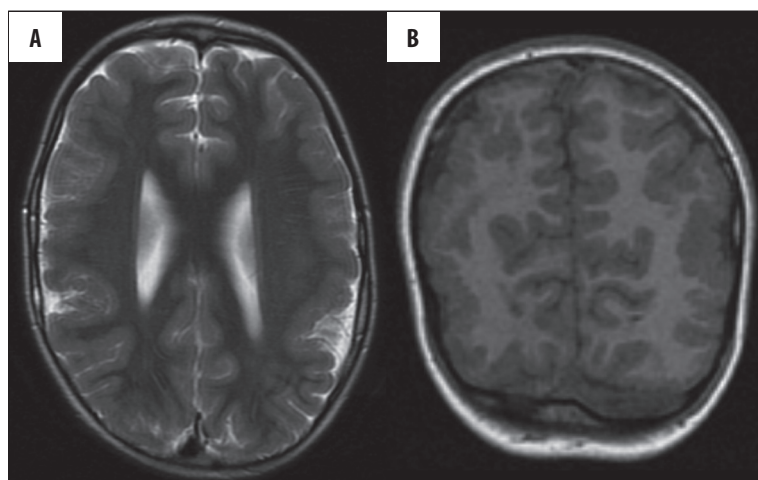


Figure 10. A 4-year-old boy with his first imaging examination. Clinical diagnosis: CP. The condition does not result from hypoxic-ischemic lesions but from a developmental malformation – polymicrogyria. (A) FSE/T2,ax; (B) FSPGR/3D/T1,cor.

- coronal T2-weighted images,
- axial T1-weighted images,
- axial SWI or GRE/T2*-weighted images,
- DWI,
- sagittal T2-weighted images,
- axial T2-weighted images,
- axial FLAIR images.

Very important addition to the above-cited literature-recommended protocol are the sequences sensitive to hemoglobin breakdown products (SWI, GRE/T2*-) used in our center. Neonates born before 32 week of gestation are particularly prone to develop germinal layer, intraventricular or intraparenchymal haemorrhages being the consequences of hypoxic-ischemic event (Figure 9) [4].

SWI sequence (*Susceptibility-Weighted Imaging*) seems to be better than GRE/ T2*-weighted images in detecting hemoglobin breakdown products, and it is useful in diagnosing venous stasis resulting from venous sinus thrombosis [13].

We do not perform routine venous MRA in each neonate in our center. This is due to this method's limitations if it is not performed after intravenous administration of gadolinium and generally avoiding administration of a contrast agent to the newborns.

Arterial MRA and MRS scans are not included in the study protocol.

The contrast agent approved for use in neonates is given very rarely when CNS infection is suspected.

DWI is a particularly important sequence. Hypoxic-ischemic lesions can be silent in a routine MRI, and this a few dozen second long sequence is the only way to detect them (Figure 8A,B). It generates considerably more noise that can possibly wake the newborn, however, due to its importance in the study protocol it is not placed at the end. The least important tool seems to be the FLAIR sequence, which in this period of the child's life provides much less information than at a later age (Figure 8C).

Clinical Picture

The pattern of hypoxic-ischemic lesions visible on MRI is associated with various types of neurological symptoms.

Children with the first form (PVL) are expected to develop spastic CP involving the lower limbs (diplegia), quadriplegia (tetraplegia – with more pronounced symptoms in the lower limbs) or hemiplegia (also involving predominantly the lower limb). Epilepsy is relatively common. The prognosis is worse when the subcortical white matter is affected as well: there usually occur spastic tetraplegia, severe

mental retardation (it is usually mild in the case of PVL), epilepsy, and often impaired vision.

In the second form (BGTL), when the lesions are moderately intense, we expect the child to develop extrapyramidal CP and normal intellectual development.

In the third form (MCE) the prognosis is most serious, usually a child develops a severe quadriplegic form of the cerebral palsy, with choreoathetotic symptoms, secondary microcephaly, mental retardation, and bulbar symptoms. They are commonly accompanied by epilepsy [2,14–17].

Children are more and more often referred for MRI scans and thus increasingly more children with a clinical diagnosis of CP are examined, in whom not hypoxic-ischemic lesions but different types of central nervous system congenital anomalies are found [18]. An example from our material is polymicrogyria diagnosed in a 4 year old boy after his first ever imaging test (Figure 10). It must be remembered that CP is a general term, comprising a wide

range of non-progressive motor disorders caused by injury or abnormal brain development at the early stages of its growth, and thus it may result from hypoxic-ischemic lesions or developmental brain malformations [19].

Conclusions

MRI, as the most effective method for detection of hypoxic-ischemic lesions, is increasingly often used for the CNS diagnostics in preterm neonates, neonates with very low birth weight, and term neonates with significant perinatal history. Correct radiological diagnosis can truly contribute to the efficient implementation of care over the sick child.

Three classic patterns of CNS lesions can be expected: PVL, BGTL, MCE. We can predict the infant development based on the MRI pattern of hypoxic-ischemic lesions [2,20,21], however, we can not forget about the amazing malleability/flexibility of the child brain that can surprise both radiologists and clinicians.

References:

- Lawn JE, Cousens S, Zupan J: 4 million neonatal deaths: when? Where? Why? *Lancet*, 2005, 365: 891e–900
- Triulzi F, Baldoli C, Righini A: Neonatal hypoxic-ischemic encephalopathy. In: *Pediatric Neuroradiology. Brain*. Tortori-Donati P, Rossi A, Biancheri R (eds.), Springer, Berlin-Heidelberg, 2005; 234–55
- Sie LTL, van der Knaap MS, Oosting J et al: MR patterns of hypoxic-ischemic brain damage after prenatal, perinatal or postnatal asphyxia. *Neuropediatrics*, 2000; 31: 128–36
- Valk J, Vermeulen RJ, van der Knaap MS: Post-hypoxic-ischemic encephalopathy of neonates. In: *Magnetic resonance of myelination and myelin disorders*. van der Knaap MS, Valk J. Springer-Verlag Berlin Heidelberg, 2005; 718–48
- Flodmark O, Barkovich AJ: Imaging of the infant brain. In: *The newborn brain*. Lagercranz H, Hanson M, Evrard P, Rodeck C (eds.), Cambridge University Press, 2002; 289–316
- Campistol J, Poo P, Fernandez Alvarez E et al: Parasagittal cerebral injury: magnetic resonance findings. *J Child Neurol*, 1999; 14: 683–85
- Barkovich AJ, Truwit CL: Brain damage from perinatal asphyxia: correlation of MR findings with gestational age. *Am J Neuroradiol*, 1990; 11: 1087–96
- Barkovich AJ, Sargent SK: Profound Asphyxia in the Premature Infant: Imaging Findings. *Am J Neuroradiol*, 1995; 16: 1837–46
- Martin E, Barkovich AJ: Magnetic resonance imaging in perinatal asphyxia *Archives of Disease in Childhood*, 1995; 72: F62–70
- Barkovich AJ: MR and CT evaluation of profound neonatal and infantile asphyxia. *Am J Neuroradiol*, 1992; 13: 959–72
- Pasternak JF, Gorey MT: The syndrome of acute near-total intrauterine asphyxia in the term infant. *PediatrNeurol*, 1998; 18: 391–98
- Rutherford M, Martinez Biarge M, Allsop J et al: MRI of perinatal brain injury. *Pediatr Radiol*, 2010; 40: 819–33
- Tong KA, Ashwal S, Obenaus A et al: Susceptibility-weighted MR imaging: a review of clinical applications in children. *Am J Neuroradiol*, 2008; 29: 9–17
- Barkovich AJ, Hajnal BL, Vigneron D et al: Prediction of neuromotor outcome in perinatal asphyxia: evaluation of MR scoring systems. *Am J Neuroradiol*, 1998; 9: 143–49
- Rutherford M: The asphyxiated term infant. In: *TMR of the neonatal brain*. Rutherford M (ed.), W.B. Saunders, London-Toronto, 2002; 99–128
- Barkovich AJ, Westmark K, Partridge C et al: Perinatal asphyxia: MR findings in the first 10 days. *Am J Neuroradiol*, 1995; 16: 427–38
- Maller AI, Hankins LL, Yeakley JW et al: Rolandic type cerebral palsy in children as a pattern of hypoxic-ischemic injury in the full-term neonate. *J Child Neurol*, 1998; 13: 313–21
- Okumura A, Kato T, Kuno K et al: MRI findings in patients with spastic cerebral palsy. II: Correlation with type of cerebral palsy. *Dev Med Child Neurol*, 1997; 39: 369–72
- Mutch L, Alberman E, Hagberg B et al: Cerebral palsy epidemiology: Where are we now and where are we going. *Dev Med Child Neurol*, 1992; 34: 547–51
- Bonifacio SL, Glass HC, Vanderpluym J et al: Perinatal events and early magnetic resonance imaging in therapeutic hypothermia. *J Pediatr*, 2011; 158: 360–65
- Zupan-Simunek V, Rutkowska M, Bekiesińska-Figatowska M: Wartość predykcyjna rezonansu magnetycznego (MR) w nabytych uszkodzeniach mózgu u noworodków. *Med Wieku Rozwojowego*, 2011; 15(3 Pt 2): 385–93 [in Polish]