



Skeletal Fluorosis Mimicking Spondyloarthritis: A Rare Presentation

Prasanta Padhan , Debashis Maikap

Department of Clinical Immunology and Rheumatology, Kalinga Institute of Medical Sciences, KIIT University, Bhubaneswar, Odisha, India, PIN: 751024

Mediterr J Rheumatol 2022;33(2):261-2

<https://doi.org/10.31138/mjr.33.2.261>

Article Submitted: 5 Feb 2021; Revised Form: 31 May 2021; Article Accepted: 20 Jun 2021; Available Online: 30 Jun 2022

Keywords: fluorosis, spondyloarthritis, osteosclerosis, calcification

CLINICAL IMAGE

A 46-year-old male presented to us with a 7-year history of pain in neck and lower back with recent onset pain in knees, elbows, and heels for the past one year. He was being treated for spondyloarthritis with intermittent analgesics for the past one year without benefit. On examination, there was brownish discoloration of teeth with rough and pitted enamel (**Figure 1A**). Musculoskeletal system examination showed tenderness on right elbow and bilateral achilles tendinitis. Spine examination revealed diffuse tenderness at the cervical spine, and the lumbo-sacral spine with mild restriction of forward and lateral movement. His modified Schober's test was 3cm and FABER test was negative. Laboratory investigation showed raised ESR (36 mm/1st hr; Normal <20 mm/1st hr and CRP (12mg/L; normal <5 mg/L). His complete blood counts, serum electrolytes including calcium, phosphorous, magnesium, alkaline phosphatase, Vitamin D3, and parathormone levels were normal. His rheumatoid factor, anti-CCP (anti-cyclic citrullinated peptide), and human leukocyte antigen B27 (HLA B27), test was negative. Plain radiograph of the pelvis showed osteosclerosis of the vertebral column, exuberant calcification

of pelvis and greater trochanter along with prominent hypertrophic spurring at the acetabular margins (**Figure 1D**). A plain radiograph of forearm bones was done, which demonstrated calcification of bilateral interosseous membranes of forearm bones. Skull and spine

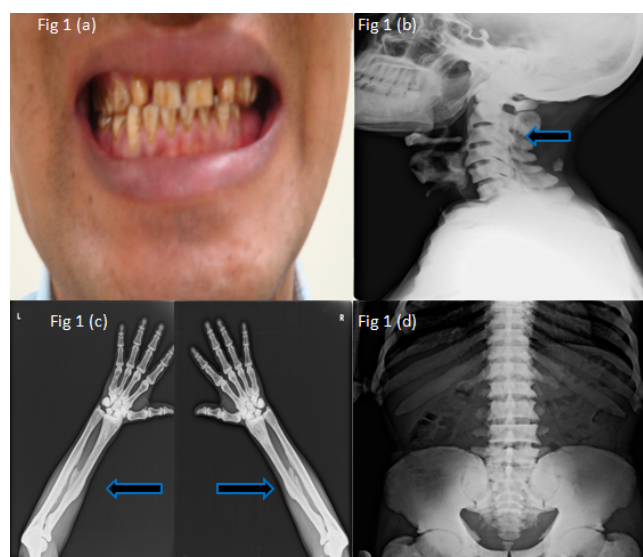


Figure 1. (a) Teeth showing dark brown streak and discoloration with pitted and rough enamel. (b) X-ray of skull and cervical spine showing osteosclerosis and the posterior longitudinal ligament ossification with calcification of thyroid and cricoid cartilage. (c) X-ray of both forearms showing interosseous membrane calcification. (d) X-ray of the pelvis showing osteosclerosis of the vertebral column, exuberant calcification of pelvis and greater trochanter along with prominent hypertrophic spurring at the acetabular margins.

radiograph showed osteosclerosis and posterior longitudinal ligament ossification with calcification of thyroid and cricoid cartilage of the neck (**Figure 1B,C**). His serum fluoride (F) level was 0.2 ppm (normal range <0.02 ppm) and his 24-hour urine fluoride level was 0.9 (normal

Corresponding Author:

Debashis Maikap
Senior Resident, Department of
Clinical Immunology and Rheumatology
Kalinga Institute of Medical Sciences
KIIT University
Bhubaneswar, Odisha, India
PIN: 751024
E-mail: debasishmaikap29@gmail.com
Tel.: +91-9040145062

<0.10 ppm) confirming diagnosis of dental and skeletal fluorosis. Our patient hailed from endemic area of fluorosis in Odisha, a state of India.

Other aetiologies for non-endemic fluorosis include chronic excessive consumption of black tea, recreational inhalation of fluoride containing vapours (huffing fluorocarbons), exposure to computer duster containing fluoride such as di- or tetrafluoroethane.^{1,2} Skeletal fluorosis can mimic various arthritis such as rheumatoid arthritis, osteoarthritis or spondyloarthropathy.³ The early stages of the disease may be asymptomatic or present as vague pain in the neck or back with rigidity, arthralgia and paraesthesia in the limbs,⁴ achilles tendinitis, and early morning stiffness.⁵ The present case had skeletal fluorosis resembling spondyloarthritis. Awareness of clinical, radiographic, and dental findings of fluorosis can help the physicians and rheumatologists from endemic areas to make early diagnosis and unnecessary workup.

CONFLICT OF INTEREST

The authors declare no conflicts of interest.

PATIENT CONSENT

A written informed consent was obtained from the patient before submitting this article.

REFERENCES

1. Kakumanu N, Rao SD. Skeletal fluorosis due to excessive tea drinking. *N Engl J Med* 2013 Mar 21;368(12):1140.
2. Cook FJ, Seagrove-Guffey M, Mumm S, Veis DJ, McAlister WH, Bijanki VN, et al. Non-endemic skeletal fluorosis: Causes and associated secondary hyperparathyroidism (case report and literature review). *Bone* 2021 Jan 6;115839.
3. Kumar S, Kakar A, Gogia A, Byotra SP. Skeletal fluorosis mimicking seronegative spondyloarthropathy: A deceptive presentation. *Trop Doct* 2011;41:247-8.
4. Czerwinski E, Nowack J, Dabrowska SD, Skolarczyk A, Kita B, Ksiezik M. Bone and joint pathology in fluoride-exposed workers. *Arch Environ Health* 1988;43:340-3.
5. Gupta R, Kumar AN, Bandhu S, Gupta S. Skeletal fluorosis mimicking seronegative arthritis. *Scand J Rheumatol* 2007;36:154-5.