

Infantile scimitar syndrome with unusual associations

Abullah Al-Shamrani, MD, Reem S. AlSadi, MD, Motea E. Elhoury, MD, Adel S. AlHarbi, MD.

ABSTRACT

متلازمة الرمح التركي هي متغير من الوريد الرئوي الشاذ، حيث أن أوردة الرئة اليمنى تصب بشكل غير طبيعي (جزئياً أو كلياً) في الوريد الأجوف السفلي. وغالباً ما تكون هذه الرئة متضررة والمجاري الهوائية المرتبطة بها غير مكتملة النمو. وبالإضافة إلى ذلك، يمكن أن تشارك الأوعية الجانبية الرئوية على الجانب المصاب، مما تسبب في احتباس جزء من الرئة في هذا الجانب؛ مثل هذه المتلازمة ترتبط عادة مع عيوب أخرى بالقلب. نستعرض هنا حالة متلازمة الرمح التركي التي تنطوي على علاقة نموذجية في الرئة اليمنى ولكن مع عيوب غير عادية كإستسقاء الرأس، وعدم إنتظام نبضات القلب. عرضنا هذه الحالة وماهية الطرق التشخيصية والعلاجية لمثل هذه الحالات.

Scimitar syndrome is a variant of partial anomalous pulmonary venous connection (PAPVC), in which all or part of the right lung is drained by right pulmonary veins that anomalously connect to the inferior vena cava (IVC). The affected lung and its associated airways are often hypoplastic. In addition, aortopulmonary collateral vessels may be involved on the affected side, causing sequestration of that side; such involvement is commonly associated with cardiac defects. We report a case of infantile scimitar syndrome that involved a typical association with the right lung, but with extremely unusual associations with congenital hydrocephalus and heart blockage. The presentation of this case and the role of different diagnostic approaches and management are discussed.

Saudi Med J 2017; Vol. 38 (7): 764-767

doi: 10.15537/smj.2017.7.18365

From the Department of Pediatric (Al-Shamrani, AlHarbi), Prince Sultan Medical Military City, and the Children Specialized Hospital (AlSadi), Prince Salman Heart Centre, (Elhoury), King Fahad Medical City, Riyadh, Kingdom of Saudi Arabia.

Received 10th January 2017. Accepted 7th June 2017.

Address correspondence and reprint request to: Dr. Abdullah S. Al-Shamrani, Consultant, Department of Pediatric, Prince Sultan Medical Military City, Riyadh, Kingdom of Saudi Arabia. E-mail: Shamrani99@yahoo.com
ORCID ID: orcid.org/0000-0001-7157-1706

Scimitar syndrome is a rare congenital anomaly that commonly results in hypoplasia or aplasia of one or more lobes of the right lung, leading to dextroposition of the heart. Other cardinal features of this syndrome are an anomalous pulmonary venous connection of the right lung to the IVC and anomalous systemic arterial supply of the right lower lobe, resulting in a sequestered lung.^{1,2} Scimitar syndrome is named for the appearance of the anomalous vein, which resembles a Turkish sword on a frontal chest radiograph.²

Case Report. Patient information. A newborn Saudi male antenatally diagnosed with congenital hydrocephalus developed mild respiratory distress soon after delivery.

Clinical finding. On examination, he had marked decreased breath sound on right sided chest. Head circumference was within normal range, loud heart sound in the pulmonary area. To treat this distress, nasal continuous positive airway pressure (NCPAP) was administered for respiratory support. The medical history and final resolution of the case (over a month period) was summarize in Figure 1.

Diagnostic assessment. A chest x-ray showed right lung collapse with a rim of pneumothorax on the left side. A chest CT scan performed after intravenous contrast (Figure 2) with CT angiography showed a hypoplastic right pulmonary artery and large feeding vessels supplying the lower lobe; these findings were consistent with sequestration of the right lower lobe. Hypoplasia of the right lung and airspace disease involving the right lower lobe are features of scimitar syndrome. An ECG revealed complete heart blockage,

Disclosure. Authors have no conflict of interests, and the work was not supported or funded by any drug company. Dr. Adel S. AlHarbi is a member of the Editorial Team, and was therefore excluded from any final editorial decisions regarding this paper.

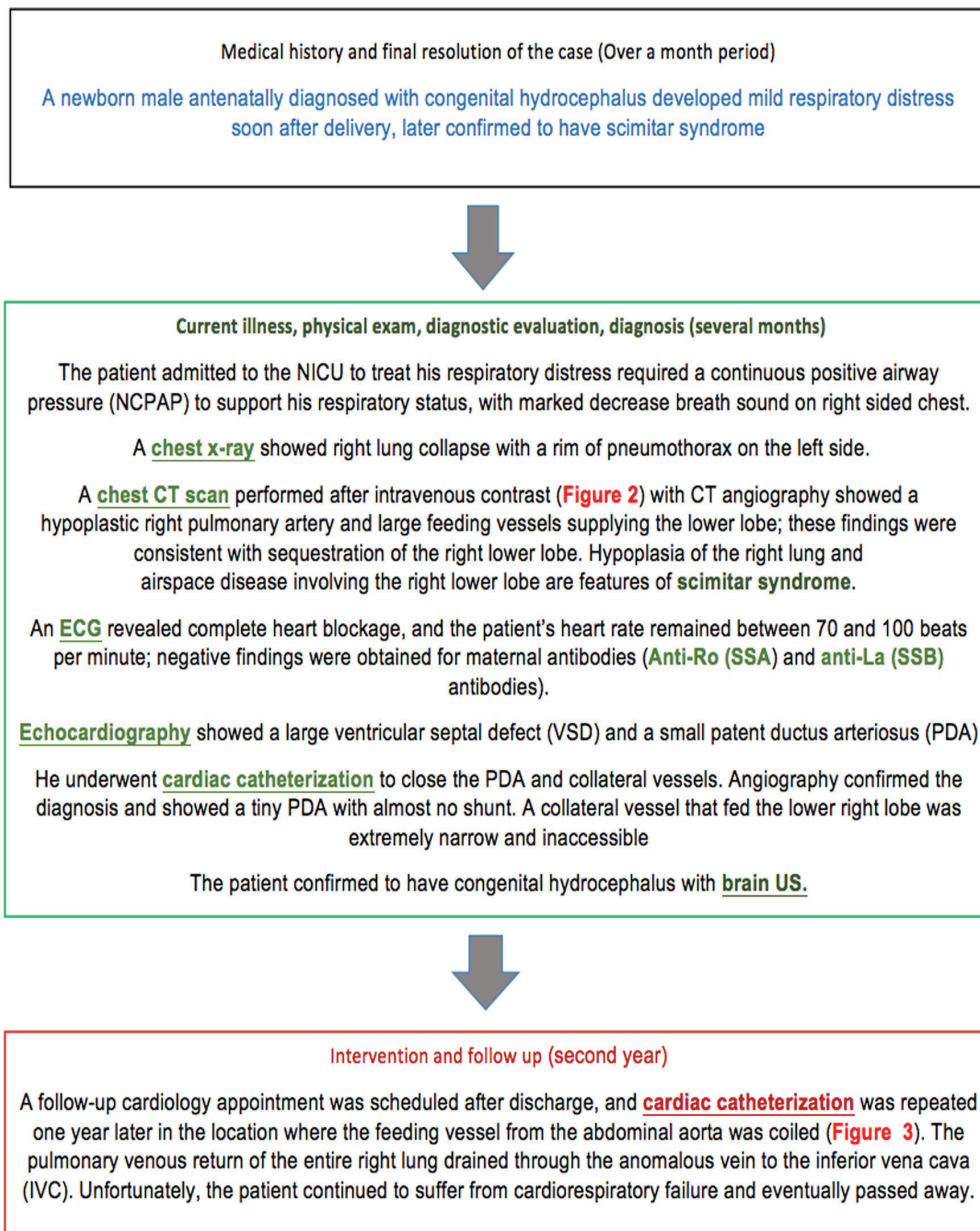


Figure 1 - Timeline summary of the case.

and his heart rate remained between 70 and 100 beats per minute; negative findings were obtained for maternal antibodies (anti-Ro [SSA] and anti-La [SSB] antibodies). Echocardiography showed a large ventricular septal defect (VSD) and a small patent ductus arteriosus (PDA). Both of these features shunted bidirectionally, indicating equal pulmonary and systemic arterial pressures.

Therapeutic intervention. His condition was managed conservatively. He underwent cardiac

catheterization to close the PDA and collateral vessels. Angiography confirmed the diagnosis and showed a tiny PDA with almost no shunt. A collateral vessel that fed the lower right lobe was extremely narrow and inaccessible. Repeated angiography showed stenosed vessels due to repeated access attempts.

A follow-up cardiology appointment was scheduled after discharge, and cardiac catheterization was repeated one year later in the location where the feeding vessel from the abdominal aorta was coiled (Figure 3). The

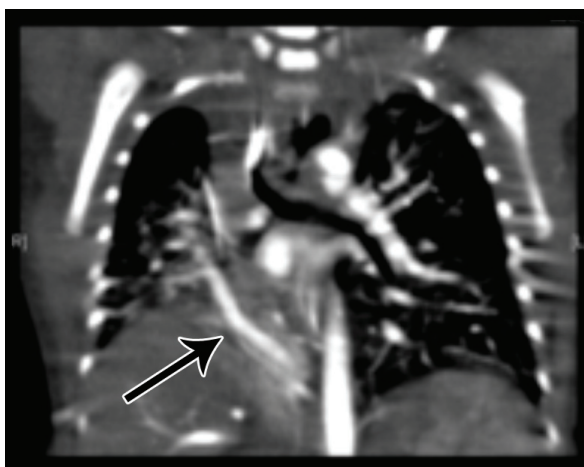


Figure 2 - A coronal view produced by chest CT, showing a sequestered right lower lobe with a large feeding vessel (arrow) from the abdominal aorta and a hypoplastic right lung.

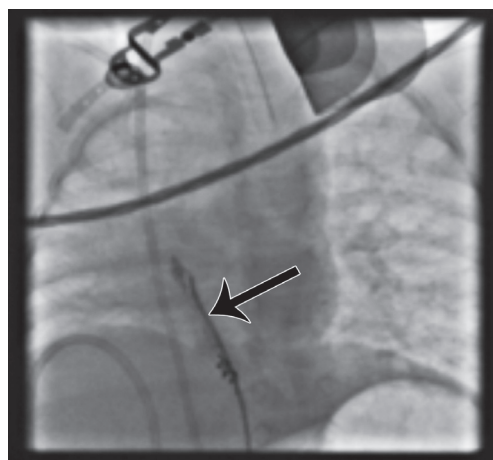


Figure 3 - AP projection showing the positioned coil occluding the arterial feeding vessel (arrow) and a venous catheter passing from the IVC to the lower right anomalous scimitar pulmonary vein.

pulmonary venous return of the entire right lung drained through the anomalous vein to the inferior vena cava (IVC). This finding was consistent with those obtained in typical scimitar syndrome cases; furthermore, the patient was confirmed to have congenital hydrocephalus. Unfortunately, he continued to suffer from cardiorespiratory failure and eventually passed away.

Discussion. Scimitar syndrome exhibits autosomal dominant inheritance with variable penetrance.³ The median age for presentation of this syndrome is 7 months, although the age at presentation varies.³ Many patients are asymptomatic throughout childhood and typically present with recurrent respiratory tract infections.³ The severity of scimitar syndrome varies considerably. Some patients with the relevant anomaly are completely unaware of their condition or present with mild respiratory symptoms that neither affect their lives nor require intervention. However, this defect can potentially cause significant health problems or endanger the heart;⁴ such issues were observed in our case, in which infantile scimitar syndrome was diagnosed. In this case, pulmonary pressure was equivalent to systemic pressure, with bidirectional shunts through the PDA. We have described the second reported case involving the association of scimitar syndrome with congenital hydrocephalus,⁵ which further adversely affected the outcome. This association appears to be coincidental because both anomalies could concurrently arise in early embryogenesis and because the neonate exhibited no apparent cause of hydrocephalus such as

infection or hemorrhage. The “scimitar sign” on chest x-rays was first described by Godwin et al,⁶ although this sign is an important diagnostic finding, it is not necessarily specific. Doppler examinations may show the union of the scimitar and systemic veins. The CT and MRI permit direct visualization of the anomalous vein, and angiographic techniques and multiplanar reconstructions allow radiologists to determine arterial and bronchial anatomy in detail.⁷ Conventional angiographic studies may still be ordered by surgeons to delineate the arterial and venous anatomy prior to surgical repair, and virtual bronchoscopy may show the fish-mouth appearance of the affected side and variable degrees of airway narrowing.⁷ Echocardiography could potentially be used to determine whether common cardiac defects such as atrial septal defect (ASD) and PDA are present and whether significant pulmonary hypertension and drainage of the pulmonary veins exist. Bronchoscopy can be utilized in cases of scimitar syndrome to assess the presence of airway hypoplasia.⁸ Because of the wide clinical spectrum for scimitar syndrome, the strategy for medical intervention depends on the severity of presentation and the amount of blood flowing to the IVC from completely or partially anomalous pulmonary veins. If there is a small amount of drainage, therapy may not be required. Management is often supportive and can include the prescription of cardiac medication if volume overload exists; the prescription of antibiotics for chest infections; the promotion of good nutrition; oxygen supplementation and the prescription of sildenafil for pulmonary

hypertension; and ventilatory support which all were utilized in our patient.⁴ The presence of respiratory symptoms is typically one of the main indications for surgical correction.^{3,9} Furthermore, surgical repair seldom results in normal blood flow to the right lung and abolishes the increased left-to-right shunt with pulmonary volume overload that often results in improving clinical conditions in most patients.^{9,10} Simple ligation or coil embolization of abnormal arterial vessels has been advocated as the best and simplest form of treatment, particularly in symptomatic infants as in our case.^{9,10} In contrast, Huddleston et al⁹ recommended repair of the anomalous venous return and the ligation of collaterals in symptomatic patients.⁹ Thrombosis and fibrosis of the redirected pulmonary veins are serious complications of the surgical re-implantation procedure, which often requires rethoracotomy with resection of the remaining lung. Pneumonectomy (either as a primary therapy or after repair failure) has produced similar results.^{3,10}

In conclusion, scimitar syndrome is a rare disease that has been well described in the literature, but has variable presentations and associations; thus, a great deal of caution is required with respect to diagnose infantile scimitar syndrome. This condition can be initially suspected from a chest x-ray, but is typically confirmed via CT angiography. For scimitar syndrome that presents in infants, large blood flow into the IVC from the anomalous pulmonary veins and the presence of hydrocephalus are negative prognostic factors.

References

1. Gao YA, Burrows PE, Benson LN, Rabinovitch M, Freedom RM. Scimitar syndrome in infancy. *J Am Coll Cardiol* 1993; 22: 873-882.
2. Neill CA, Ferenc C, Sabiston DC. The familial occurrence of hypoplastic right lung with systemic arterial supply and venous return, "scimitar syndrome". *Bull Johns Hopkins Hosp* 1960; 107: 1-21.
3. Najm HK, Williams WG, Coles JG, Rebeyka IM, Freedom RM. Scimitar syndrome: twenty years' experience and results of repair. *J Thorac Cardiovasc Surg* 1996; 112: 1161-1168.
4. Tamimi RJ, Al-Ghaihab M, AlAkhfash AA. Transcatheter closure of patent ductus arteriosus in infantile form of Scimitar syndrome with a type II amplatzer ductal occluder. *Journal of the Saudi Heart Association* 2010; 22: 65-67.
5. Örün UA, Özgür S, Ceylan O, Karademir S, Şenocak F, Yilmaz O, et al. Horseshoe Lung and Scimitar Syndrome Associated with Congenital Hydrocephalus in an Infant: Case Report. *Türkiye Klinikleri Cardiovascular Sciences* 2012; 24: 83-87.
6. Lucas E, Teldeschi A, Chamie F, Serra A, Ramos S, Silva ML, et al. [The importance of chest radiograph in the diagnosis of Scimitar syndrome]. *J Pediatr (Rio J)* 1998; 74: 479-482. Portuguese
7. Konen E, Raviv-Zilka L, Cohen RA, Epelman M, Boger-Megiddo I, Bar-Ziv J, et al. Congenital pulmonary venolobar syndrome: spectrum of helical CT findings with emphasis on computerized reformatting. *Radiographics* 2003; 23: 1175-1184.
8. Efrati O, Gonik U, Modan-Moses D, Bielorai B, Barak A, Vardi A, et al. The role of flexible fiberoptic bronchoscopy in evaluation of pulmonary diseases in children with congenital cardiac disease. *Cardiol Young* 2007; 17: 140-144.
9. Vida VL, Speggorin S, Padalino MA, Crupi G, Marcelletti C, Zannini L, et al. The Scimitar Syndrome: An Italian Multicenter Study. *Ann Thorac Surg* 2009; 88: 440-44.
10. Mahadi Kahrom, Hadi Kahrom; scimitar syndrome and evolution of management. *Pan Afr Med J* 2009; 3: 20.