



Convergence Analysis of Micro-Lesions (CAML): An approach to mapping of diffuse lesions from carotid revascularization

Allyson C. Rosen^{a,b,*,1}, Salil Soman^{a,c,1}, Jyoti Bhat^{a,d}, Angela R. Laird^e, Jeffrey Stephens^a, Simon B. Eickhoff^{f,g}, P. Mickle Fox^h, Becky Long^{i,j}, David Dinshak^k, Mario Ortega^l, Barton Lane^{a,m}, Max Wintermark^{a,m}, Elizabeth Hitchner^{a,n}, Wei Zhou^{a,n,o}

^a Palo Alto Veterans Affairs Health Care System, Palo Alto, CA 94304, United States

^b Department of Psychiatry, Stanford University, Stanford, CA 94305, United States

^c Harvard Medical School, Beth Israel Deaconess Medical Center, Department of Radiology, Boston, MA 00215, United States

^d Palo Alto Veterans Institute for Research, Palo Alto, CA 94304, United States

^e Department of Physics, School of Integrated Science and Humanity, Florida International University, Miami, FL 33199, United States

^f Institute of Systems Neuroscience, Medical Faculty, Heinrich Heine University Düsseldorf, Düsseldorf, Germany

^g Institute of Neuroscience and Medicine, Brain & Behaviour (INM-7), Research Centre Jülich, Jülich, Germany

^h Research Imaging Institute, The University of Texas Health Science Center at San Antonio, TX 78229, United States

ⁱ Department of Surgery, Stanford University, Stanford, CA 94305, United States

^j Department of Surgery, Texas Tech University Health Science Center El Paso, TX 79905, United States

^k Palo Alto University, Redwood City, CA 94063, United States

^l Department of Neurology, Washington University School of Medicine, St. Louis, MO 63110, United States

^m Department of Radiology, Stanford University, Stanford, CA 94305, United States

ⁿ Department of Vascular Surgery, Stanford University, Stanford, CA 94305, United States

^o Department of Surgery, Tucson, AZ 85724-5066, United States

ARTICLE INFO

Keywords:

Embolization

DWI

ALE

ABSTRACT

Carotid revascularization (endarterectomy, stenting) prevents stroke; however, procedure-related embolization is common and results in small brain lesions easily identified by diffusion weighted magnetic resonance imaging (DWI). A crucial barrier to understanding the clinical significance of these lesions has been the lack of a statistical approach to identify vulnerable brain areas. The problem is that the lesions are small, numerous, and non-overlapping. Here we address this problem with a new method, the Convergence Analysis of Micro-Lesions (CAML) technique, an extension of the Anatomic Likelihood Analysis (ALE). The method combines manual lesion tracing, constraints based on known lesion patterns, and convergence analysis to represent regions vulnerable to lesions as probabilistic brain atlases. Two studies were conducted over the course of 12 years in an active, vascular surgery clinic. An analysis in an initial group of 126 patients at 1.5 T MRI was cross-validated in a second group of 80 patients at 3T MRI. In CAML, lesions were manually defined and center points identified. Brains were aligned according to side of surgery since this factor powerfully determines lesion distribution. A convergence based analysis, was performed on each of these groups. Results indicated the most consistent region of vulnerability was in motor and premotor cortex regions. Smaller regions common to both groups included the dorsolateral prefrontal cortex and medial parietal regions. Vulnerability of motor cortex is consistent with previous work showing changes in hand dexterity associated with these procedures. The consistency of CAML also demonstrates the feasibility of this new approach to characterize small, diffuse, non-overlapping lesions in patients with multifocal pathologies.

1. Introduction

Carotid revascularization procedures (carotid artery stenting [CAS] and endarterectomy [CEA]) are treatments for carotid occlusive disease

that involve controlled manipulation of the carotid, and lead to multiple, tiny, brain lesions visible on diffusion weighted MR imaging (DWI). These lesions are clearly identifiable as procedure-related because they appear immediately after the procedure, are typically visible

* Corresponding author at: Palo Alto VAHCS, 3801 Miranda Ave (151Y), Palo Alto, CA 94304-1207, United States.

E-mail address: rosena@stanford.edu (A.C. Rosen).

¹ These authors contributed equally to the work.

for only a few days, and have been related to particles flowing to the brain and detected on carotid ultrasound (Bonati et al., 2010; Ederle et al., 2010; Poppert et al., 2006; Rapp et al., 2007; Skjelland et al., 2009; Tedesco et al., 2009). Clinically, endovascular procedures are effective means of preventing stroke, and whereas serious associated complications are rare (Brott, 2010), there have been inconsistent studies suggesting these lesions may be linked to subtle post-procedural cognitive decline and increased vulnerability to future cognitive declines (Aharon-Peretz et al., 2003; Fink et al., 2015; Ghogawala et al., 2008; Heyer et al., 1998; Tiemann et al., 2009; van Dijk and Kalkman, 2009; Wasser et al., 2011; Zhou et al., 2017; Zhou et al., 2012). For example, one large study showed changes in hand dexterity related to side of intervention (Heyer et al., 2015). To identify potentially subtle dysfunction, it is crucial to have highly specific knowledge of which brain systems are affected in order to develop sensitive and focused assessment. Since lesions from endovascular procedures are small (100–200 mm³), and diffuse, traditional analyses (e.g. Bates et al., 2003) are typically insensitive because they depend on lesions having spatial overlap.

In contrast, Anatomic Likelihood Estimation (ALE) analysis (Glahn et al., 2008) generates three dimensional maps of probabilities of lesion occurrence. ALE has primarily been used for meta-analyses, and represents the convergence of points across sets of three-dimensional peak coordinates in standard space obtained from published studies of functional imaging (Eickhoff et al., 2009; Laird et al., 2005; Turkeltaub et al., 2002) and voxel-based morphometry studies (Ellison-Wright et al., 2008; Glahn et al., 2008). The ALE statistical approach is also robust against false positives because it involves permutation testing and correcting for multiple comparisons using Family-wise-Error (FWE, Eickhoff et al., 2016).

Here we describe Convergence Analysis of Micro-Lesions (CAML), a new application of the ALE algorithms which is adapted for small lesions and surgical applications. Essentially lesions are defined manually, representative points are derived, and brains are compared based on what is known about the intervention. For example in this application, since procedure-related embolization tends to travel to the same side of the procedure, analyses were made more sensitive and informative by flipping brains so that hemispheres ipsilateral to the intervention are analyzed together. Results thus identify regions where lesions occur contralaterally, likely due to crossflow. In order to test the replicability and field robustness of these convergence maps, we collected data from two groups of patients from MRI's of different field strengths (1.5T, 3T) all scanned at a single institution over 12 years.

2. Material and methods

2.1. Participants

2.1.1. Selection

Indications for carotid revascularization procedures included severe asymptomatic stenosis (> 80%) of carotid arteries identified on carotid duplex ultrasound or moderate to severe stenosis (> 60%) with focal neurological symptoms. All patients who received CAS procedures were typically those deemed to be high-risk (Bates et al., 2007). All CAS and majority of CEAs were performed by a single operator (WZ) without changing in operative techniques. The study was approved by the Stanford Institutional Review Board and the R&D committee of the VA Palo Alto Health Care System (VAPAHCS). Procedures followed were in accordance with institutional guidelines. For some early data collected for Group 1, MRI data was obtained for clinical care and waivers of HIPAA authorization and consent were granted. For all later studies patients provided informed consent and HIPAA authorization.

2.1.2. Patient groups and procedures

The first group of patients was scanned on a 1.5 T MRI (Group 1) and the second group of patients was scanned on a 3 T MRI (Group 2), a

more sensitive acquisition protocol but one which was an opportunity to cross validate the initial results. The first group (Group 1) underwent successful carotid interventions between 2002 and 2009, a total of 126 patients (CAS = 55, CEA = 71). The second group (Group 2) underwent carotid interventions between 2009 and 2015, a total of 80 patients (CAS = 39, CEA = 41). A similar percentage of patients underwent stenting in Group 1 (44%) and Group 2 (49%).

2.2. Imaging acquisition

Both the groups (Group 1 and Group 2) included in this study, had pre and post-procedure MRI evaluations. Diffusion weighted images were collected before and within 48 h of the vascular intervention. Apparent Diffusion Coefficient (ADC) maps were calculated based on these DW-images using the product software. Group 1 data were collected on a 1.5 T MRI (Signa Excite HD 12.0, GE Medical Systems, Milwaukee, WI, USA). Axial DWI echoplanar/spin echo images (TR/TE = 12,000/80 milliseconds, b = 1000, 5 mm thick slices, 5 mm gap, matrix size 128 × 128, FOV = 300 mm, acquired inplane resolution 2.344 mm). Group 2 data were collected on 3 T MRI (Discovery MR 750 Software Rev. 23, GE Medical Systems, Milwaukee, WI, USA). The protocol included 30 directional whole brain Axial DWI echoplanar/spin echo images with Asset (TR = 6600, TE minimum, 5 B0 images with B0 = 1000s/mm², 2 NEX, 2.5 mm thick slices, 0 mm gap, matrix size 96 × 96, FOV = 240 mm).

2.3. Image analyses

Lesions were defined by signal intensity, increases on DWI and decreases on ADC. Procedure associated lesions were defined as the lesions seen only in the post-procedure DWI and ADC images and not in the pre-procedural DWI and ADC images. These post-procedure lesions were traced manually on individual MRI slices by a rater using MRICron (<http://people.cas.sc.edu/rorden/mricro/mricro.html>) in both groups. Board certified neuroradiologists (B.L., S.S.), checked these lesion definitions and one (S.S.) checked both groups for continuity of rating and also the pre-procedure images to assure that lesions are new lesions related to procedures. Routines from University of Oxford's Center for Functional MRI of the Brain (FMRIB) Software Library (Jenkinson et al., 2012; Smith et al., 2004) were used to prepare regions of interest (ROI's) for the ALE analysis. The B0 images of the DWI were skull stripped using BET 2.1 to remove the tissue outside the brain. These skull stripped images were then warped to the template brain used in ALE (Colin T1 MNI) using a 12 parameter, affine transformation with FLIRT 5.5. No lesion tissue masking was required as the lesions did not seem to be affecting the normalization of these B0 images. To enable group analyses, warping parameters derived from warping the whole brain B0 images, were applied to the ROI's. Since lesion laterality was typically ipsilateral to the side of surgery, ROI's were collapsed on to one hemisphere based on whether they were ipsilateral (right) versus contralateral (left, using FSL fslswapdim) and single points were extracted. A point based analysis was performed to avoid bias from large lesions, thus, the ALE analysis was conducted on the centers of mass of the ROI's rather than their entire volume. A parallel analysis of the entire ROI volumes resulted in similar results. To extract the peak coordinates for the ALE analysis, an FSL cluster routine was applied to the normalized ROI image files, one for each patient, to derive a center of gravity for each ROI, and these points were submitted for further analysis to GingerALE (version 2.3.6, <http://www.brainmap.org/ale/>) (Laird et al., 2009). In ALE, these three-dimensional coordinates were blurred with a Gaussian distribution to approximate the original cluster extent, and pooled to search for convergence. GingerALE (Eickhoff et al., 2009) was applied to data from the individual patients to generate a digital convergence map (full width half max values for each Gaussian distribution were determined automatically by the software with no additional full width half max values applied) and clusters

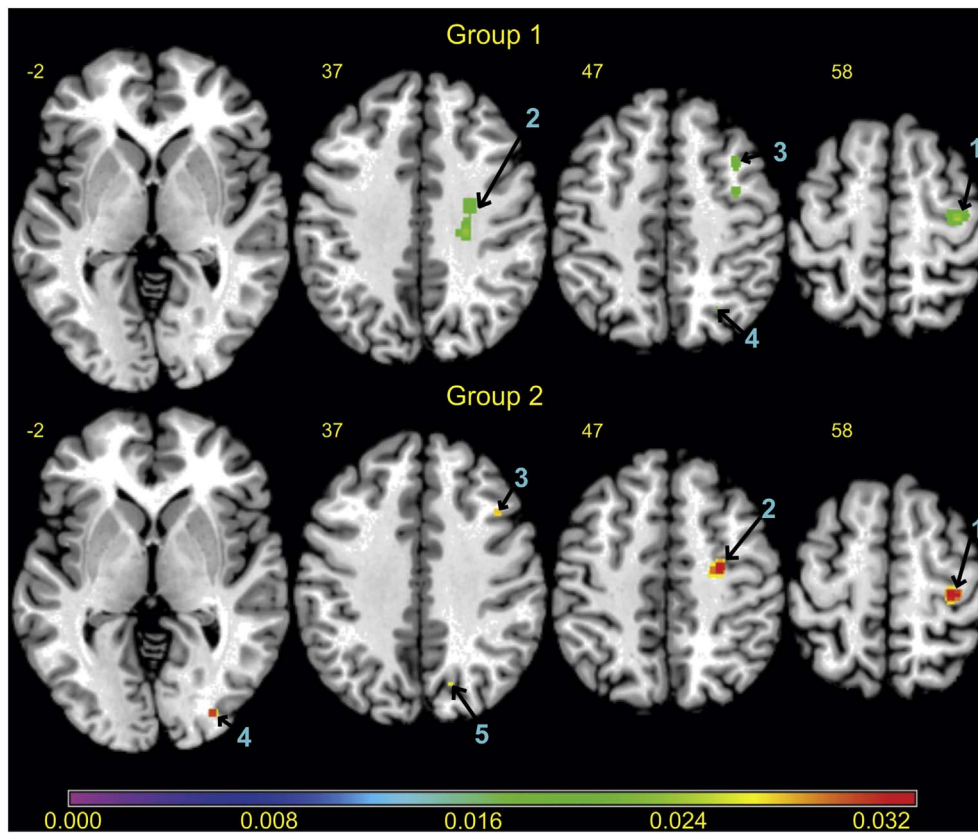


Fig. 1. ALE Statistics map for all clusters in Group 1 (top) and Group 2 (bottom) as seen in Table 1. Color scheme in the images represents the degree of convergence of lesions across patients in each group. (For interpretation of the references to color in this figure legend, the reader is referred to the web version of this article.)

(corrected for multiple comparisons with Voxel-level Family-wise Error, $p < 0.05$, number of permutations = 1000). The threshold was chosen to be adequately conservative to avoid false positive findings (Eklund et al., 2016).

3. Results

3.1. Overview

We present in Fig. 1 an image displaying the brain regions most vulnerable to the lesions in the two groups. Table 1 represents the separate ALE analyses of Group 1 (1.5T MRI) and Group 2 (3T MRI). Note that emboli ipsilateral to the side of the procedure were collapsed on to the right hemisphere, so the x coordinate only reflects the degree of

lateralization with respect to the procedure. Brodmann Areas reported were derived by ALE using the Talairach Daemon atlas (<http://www.talairach.org/daemon.html>) and the icbm2tal transform (Lancaster et al., 2007). Each label was checked by the investigators and when a Brodmann Area was not reported in ALE results (typically for a white matter region), other maps were used including, those provided by FSL (<http://fsl.fmrib.ox.ac.uk/fsl/fsl4.0/fslview/atlas-descriptions.html>) which include the Johns Hopkins WM/LONI 81 DTI Atlas and the Harvard-Oxford atlas.

3.2. Rates of lesions

General trends in overall lesion rates were consistent with the previously established findings. For example, more lesions were detected

Table 1
Separate group analyses for Group 1 and Group 2.

Cluster #	Descriptor center (peaks)	Brodmann area	Volume (mm ³)	ALE statistic	Peak ^a		
					x	y	z
Group 1							
1	Motor/premotor	4/6	1664	0.027	36	-18	56
2	Frontal WM		984	0.025	24	-24	38
3	Premotor/DLPFC	6/9	208	0.020	36	12	48
4	Parietal	7	8	0.018	26	-64	46
Group 2							
1	Motor/premotor	4	456	0.037	34	-26	60
2	Frontal WM	6	384	0.035	28	-12	46
3	DLPFC	9	128	0.031	42	18	38
4	Occipital	18	112	0.031	32	-86	-2
5	Parietal	7	8	0.026	16	-72	36

ALE = Anatomic likelihood estimate; WM = White Matter.
^a Montreal Neurological Institute (MNI) co-ordinates.

at higher MRI field strength. Lesions were detected in 34% of patients in Group 1 and 58% in Group 2; however, the raw number of patients with lesions was roughly equal. In Group 1, lesions were detected in 43 of the 126 (CAS = 31/55, CEA = 12/71) patients. In Group 2, lesions were detected in 46 (CAS = 35/39, CEA = 11/41) of the 80 patients on post-procedure DWI/ADC. In general the clusters in Group 2 tended to be slightly smaller and more numerous likely in part because of the slightly better resolution (i.e. 1.5T had 5 mm slices with a gap and 3T had 2.5 mm slices with no gap). Also consistent with expectations, CAS procedures led to more lesions than CEA in both of the groups. Among patients with embolic lesions, 72% (CAS = 31/43) of those in Group 1 and 76% (CAS = 35/46) of those in Group 2 are from CAS cohort. Of the 43 subjects with lesions in Group 1, 32 were symptomatic for carotid stenosis. Of the 46 subjects included in the analysis for Group 2, 24 were symptomatic.

3.3. Clinical features of patients with lesions

The vast majority of the plaques were located in the carotid bifurcation, with a few extending to common carotid arteries. Contralateral carotid stenosis or occlusion was present in Group 1 in 6.98% (3/43) and in Group 2 in 19.56% (9/46). Rate of preoperative symptoms for Group 1 was 74.4% (32/43) and Group 2 was 76% (35/46). Rate of new focal neurological symptoms for Group 1 was 16.2% (7/43, 2 CAS) and for Group 2 was 6.52% (3/46, 3 CAS). Screening for depression using the Geriatric Depression Scale was available for Group 2 and 33% (13/46) screened positive (i.e. > 9) preprocedure and 16.2% (6/46) screened positive postprocedure.

3.4. Locations of lesions

Table 1 shows the locations of lesions reaching significance. Fig. 1 displays these regions with cluster numbers corresponding to the table indicated in turquoise. Only lesions ipsilateral to the side of surgery reached significance. One of the most obvious differences across the groups was that results were more robust and consistent in Group 2 at the higher field strength than in Group 1, hence in Fig. 1 those clusters appear in warmer colors on Group 2. For both studies, the peak of the largest cluster (cluster 1) was in motor/premotor cortex (BA 4/6), Group 1 (36, -18, 56), and Group 2 (34, -26, 60). Cluster 2 was in the white matter, deep to the motor/premotor cortex. In Group 1, cluster 2 was deeper and larger than in Group 2. The next largest cluster (cluster 3) was in the dorsolateral prefrontal cortex (DLPFC) for both the groups. One other cluster common to both groups (cluster 4 in Group 1 and cluster 5 in Group 2) was in the dorsal/medial, parietal lobe region. Group 2 also included a cluster (cluster 4) in the occipital lobe.

4. Discussion

Across these two, patient groups, scanned on different MRI systems, CAML generated highly consistent, probabilistic maps that identified regions vulnerable to lesions from carotid revascularization. As expected, the higher field strength MRI increased sensitivity to detect these lesions. The motor/premotor cortex was the most likely to be affected. Other consistent regions included subcortical white matter deep to motor/premotor cortex, dorsolateral prefrontal cortex, and medial/superior parietal cortex. At the higher field strength an occipital cluster was also detected. In addition to being consistent across acquisitions, the analysis technique was thus quite sensitive in detecting patterns in approximately only 40 patients per group.

The finding that the region most vulnerable to these lesions was the motor/premotor area (BA 4/6) is consistent with other studies of carotid revascularization. Heyer et al. (2015) studied 374 patients undergoing CEA and found that post-procedure changes in hand dexterity were associated with the side of the surgery. Specifically, procedures contralateral to the nondominant hand (e.g. right hemisphere for right

handed patients) led to decreases in dexterity on the grooved pegboard. More sensitive and focused measures have also been used to monitor motor physiology during carotid surgeries, for example transcranial electrical motor evoked potential stimulation in approximately 600 CEA patients, or somatosensory evoked potentials (Malcharek et al., 2013; Uchino et al., 2012). Our findings support the validity of studies of motor cortex TMS excitability in patients at risk for vascular cognitive impairment (Katsoulas et al., 2005; Lanza et al., 2017) and/or vascular depression (Bella et al., 2011; Concerto et al., 2013; Pennisi et al., 2016). Whereas TMS motor cortex excitability alone cannot clearly distinguish vascular from other forms of degenerative burden such as Alzheimer's disease (Pennisi et al., 2015), a logical follow-up study would be of changes in motor cortex excitability following lesions in motor cortex occurring during endovascular procedures. More recent theories of cognitive aging and memory have also implicated the motor system in inhibitory processes in memory (Rae et al., 2015; Schilling et al., 2014).

The other clusters are within regions consistent with vascular cognitive impairment and vascular dementia. The dorsolateral prefrontal cortex (BA 9/46) and deep white matter in the frontal lobe have long been invoked as a neural substrate of executive dysfunction in vascular based mild cognitive impairment and in models of functional compensation in stroke and aging (Cabeza et al., 2002; Hachinski et al., 2006; Rosen et al., 2002; Smith et al., 2011; Ward, 2006). This region is also known to be involved with “prefrontal vascular syndrome” (Bella et al., 2010), a clinical phenomenon that involves both cognitive dysfunction and depressive symptoms. Of note even before the procedure a third of our cohort screened positive on the Geriatric Depression Scale, though there was a slight decrease after surgery, a finding that deserves further study. The superior parietal region (Group 1, cluster 4; Group 2, cluster 5) is part of the superior default mode network and damage to this system has been demonstrated to be particularly disruptive of cognition in stroke patients (Warren et al., 2014). The default mode network is also a brain system involved in memory that is affected by Alzheimer's disease through amyloid deposition (Buckner et al., 2005), hence lesions may be affecting an already vulnerable network. Apolipoprotein E-epsilon4 polymorphism, a genetic mutation associated with amyloid deposition, is associated with cognitive decline in Alzheimer's but also increased risk of CEA related cognitive decline (Heyer et al., 2014). The occipital cluster appears to be located at the border zone between the MCA and PCA territories and likely still represents an embolus location in the very distal MCA territory (Kansagra and Wong, 2008). This analysis thus identifies brain regions of interest for future a priori studies of brain changes related to carotid vascular procedures.

By identifying regional vulnerabilities in standard space, CAML thus represents a new, quantitative, approach to compare subtle, multifocal brain pathologies to findings from functional and structural MRI studies and across different clinical populations. There have been attempts to derive systematic patterns using the MRI scans of stroke patients from different vessel territories with reasonable success (Min et al., 2000; Phan et al., 2010; Phan et al., 2005; Phan et al., 2006). Probabilistic mapping of imaging data of different blood vessel territories has been based on patients with large strokes (Bilello et al., 2012; Hillis et al., 2004; Phan et al., 2009; Phan et al., 2006) and typically the statistics depend on simple proportions of patients. In our initial tests, maps based on the proportion of patients with lesions in a given voxel were extremely low for these tiny lesions and hence most statistical tests were insensitive and underpowered.

This study identifies consistent brain regions likely to be affected by carotid procedures and thus enables new lines of investigation of pathologies with diffuse non-overlapping lesions; however, there are also important limitations and need for further study. The consistency of the lesion locations across Groups 1 and 2 is compelling, but more study is needed on the mechanisms underlying this regional vulnerability. For example there may be regional differences in vessel tortuosity (Wang et al., 2016) or flow rate that may predict risk factors for

lesion deposition. A priori studies of the brain regions identified in this study should enable more sensitive analyses. A critical aspect of these results is that the interpretation of brain-behavior relationships underlying these probabilistic maps is not as straightforward as in a study of voxel based lesion symptom mapping (Bates et al., 2003) (VLSM) in which all patients share the same lesion. One can conclude that, for example, patients undergoing endovascular procedures have the highest likelihood of experiencing lesions that affect their motor system, but not that all patients experience this damage. Investigating more refined questions related to the functional effects of these brain lesions still needs VLSM analyses of subgroups of patients with similar lesions. In this study we adopted conservative thresholds and hence did not identify lesions contralateral to the procedure; however, larger cohorts will likely identify these clusters. Comparisons of data from two different MRI strengths suggest that increasingly sensitive MR imaging will reveal additional lesions. Large, multi-site cohort studies of carotid revascularization will be needed to identify these subgroups. These studies could also identify patient risk factors for large lesions, and additional comparisons between procedure types, (e.g. Gensicke et al., 2013). With approximately 40 patients per group and significant heterogeneity in lesion patterns we were conservative in the numbers of analyses we performed; however, with larger samples the correlation between clinical (plaque features, type of intervention, presence/absence of focal deficits) and neuroradiological data (lesion load, location, severity) would disclose additional interesting findings. Since these patients will likely have lesions in multiple locations and these lesions are tiny, studying disruptions of resting state fMRI networks of regions may be most informative (e.g. Warren et al., 2014). The fact that the two patient groups differed most in the frontal subcortical white matter lesions (cluster 2 in Group 1 and 2) suggests that this area may account for variability in patient outcomes either due to advancements in interventional techniques or differences in the patient groups. There also needs to be further study of the neural substrates of functional improvements and resilience. For example with respect to memory, there are some studies that find declines (Aharon-Peretz et al., 2003; Heyer et al., 1998; Zhou et al., 2012) but an increasing number of studies demonstrate improvements or resilience against the lesions (Aleksic et al., 2006; Bossema et al., 2005; Crawley et al., 2000; Ghogawala et al., 2013; Incalzi et al., 1997; Kim et al., 2015; Kougiyas et al., 2015; Kuliha et al., 2015; Migliara et al., 2013; Mononen et al., 1990; Ortega et al., 2014; Pearson et al., 2003; Piccetto et al., 2013; Takahashi et al., 2013; Wang et al., 2015; Xia et al., 2015; Xu et al., 2007; Zhou et al., 2017).

CAML thus provides many new opportunities for the study of multifocal pathology. Our consistent findings across two different MRI's and patient cohorts from a real-world setting at a Veteran's hospital, where complex patients with cardiovascular risk factors and comorbidities are highly prevalent (Johnson et al., 2004; Medicine, 2014), over a decade of vascular surgeries, highlights the robustness of CAML.

5. Conclusions

The CAML approach used convergence analysis to identify replicable patterns of tiny lesions following carotid endovascular procedures. The motor/premotor cortex is highly vulnerable to these lesions. Other regions that also have a high likelihood of lesions include the dorso-lateral prefrontal cortex and medial superior parietal lobe. There is variability in extension to the white matter deep to motor cortex and occipital lobe hence this may be a target of study of heterogeneous patient outcomes. Applying this technique to other multifocal pathologies may yield different, as yet undiscovered, patterns of regional vulnerability and new lines of research.

Acknowledgments and funding page

ACR was supported by a K award NIH NIA (K01AG025157) and the

Mental Illness Research Education and Clinical Center (MIRECC). JTS was supported by the MIRECC. ARL, SBE, PMF were supported by the NIMH (R01-MH074457). Other grant support includes the American Heart Association (CRP2610312) and NIH NINDS (R01NS070308). JB was supported by NIH NINDS (R21NS081416) and Palo Alto Veterans Institute for Research (PAVIR).

Conflicts of interest/disclosures

None.

References

- Aharon-Peretz, J., Tomer, R., Gabrieli, I., Aharonov, D., Nitecki, S., Hoffman, A., 2003. Cognitive performance following endarterectomy in asymptomatic severe carotid stenosis. *Eur. J. Neurol.* 10, 525–528.
- Aleksic, M., Huff, W., Hoppmann, B., Heckenkamp, J., Pukrop, R., Brunkwall, J., 2006. Cognitive function remains unchanged after endarterectomy of unilateral internal carotid artery stenosis under local anaesthesia. *Eur. J. Vasc. Endovasc. Surg.* 31, 616–621.
- Bates, E., Wilson, S.M., Saygin, A.P., Dick, F., Sereno, M.I., Knight, R.T., Dronkers, N.F., 2003. Voxel-based lesion-symptom mapping. *Nat. Neurosci.* 6, 448–450.
- Bates, E.R., Babb, J.D., Casey, D.E., 2007. ACCF/SCAI/SVMB/SIR/ASITN 2007 - clinical expert consensus document on carotid stenting: a report of the American College of Cardiology Foundation Task Force on clinical expert consensus documents (ACCF/SCAI/SVMB/SIR/ASITN Clinical Expert Consensus Document Committee on Carotid Stenting). *J. Am. Coll. Cardiol.* 49 (1), 126–170.
- Bella, R., Pennisi, G., Cantone, M., Palermo, F., Pennisi, M., Lanza, G., Zappia, M., Paolucci, S., 2010. Clinical presentation and outcome of geriatric depression in subcortical ischemic vascular disease. *Gerontology* 56, 298–302.
- Bella, R., Ferri, R., Cantone, M., Pennisi, M., Lanza, G., Malaguarnera, G., Spampinato, C., Giordano, D., Raggi, A., Pennisi, G., 2011. Motor cortex excitability in vascular depression. *Int. J. Psychophysiol.* 82, 248–253.
- Bilello, M., Lao, Z., Krejza, J., Hillis, A., Herskovits, E., 2012. Atlas-based classification of hyperintense regions from MR diffusion-weighted images of the brain: preliminary results. *Neuroradiol. J.* 25, 112–120.
- Bonati, L.H., Jongen, L.M., Haller, S., 2010. New ischaemic brain lesions on MRI after stenting or endarterectomy for symptomatic carotid stenosis: a substudy of the International Carotid Stenting Study (ICSS). *Lancet Neurol.* 9 (4), 353–362.
- Bossema, E.R., Brand, N., Moll, F.L., Ackerstaff, R.G.A., van Doornen, L.J.P., 2005. Does carotid endarterectomy improve cognitive functioning? *J. Vasc. Surg.* 41, 775–781.
- Brott, T.G., 2010. Stenting versus endarterectomy for treatment of carotid-artery stenosis. *N. Engl. J. Med.* 363 (1), 11–23.
- Buckner, R.L., Snyder, A.Z., Shannon, B.J., LaRossa, G., Sachs, R., Fotenos, A.F., Sheline, Y.I., Klunk, W.E., Mathis, C.A., Morris, J.C., Mintun, M.A., 2005. Molecular, structural, and functional characterization of Alzheimer's disease: evidence for a relationship between default activity, amyloid, and memory. *J. Neurosci.* 25, 7709–7717.
- Cabeza, R., Anderson, N.D., Locantore, J.K., McIntosh, A.R., 2002. Aging gracefully: compensatory brain activity in high-performing older adults. *NeuroImage* 17, 1394–1402.
- Concerto, C., Lanza, G., Cantone, M., Pennisi, M., Giordano, D., Spampinato, C., Ricceri, R., Pennisi, G., Aguglia, E., Bella, R., 2013. Different patterns of cortical excitability in major depression and vascular depression: a transcranial magnetic stimulation study. *BMC Psychiatry* 13.
- Crawley, F., Stygall, J., Lunn, S., Harrison, M., Brown, M.M., Newman, S., 2000. Comparison of microembolism detected by transcranial Doppler and neuropsychological sequelae of carotid surgery and percutaneous transluminal angioplasty. *Stroke* 31, 1329–1334.
- van Dijk, D., Kalkman, C., 2009. Why are cerebral microemboli not associated with cognitive decline? *Anesth. Analg.* 109, 1006–1008.
- Ederle, J., Dobson, J., Featherstone, R.L., Bonati, L.H., van der Worp, H.B., de Borst, G.J., Lo, T.H., Gaines, P., Dorman, P.J., Macdonald, S., Lyrer, P.A., Hendriks, J.M., McCollum, C., Nederkoorn, P.J., Brown, M.M., Algra, A., Bamford, J., Beard, J., Bland, M., Bradbury, A.W., Brown, M.M., Clifton, A., Gaines, P., Hacke, W., Halliday, A., Malik, I., Mas, J.L., McGuire, A.J., Sidhu, P., Venables, G., Bradbury, A., Brown, M.M., Clifton, A., Gaines, P., Collins, R., Molyneux, A., Naylor, R., Warlow, C., Ferro, J.M., Thomas, D., Bonati, L.H., Coward, L., Dobson, J., Ederle, J., Featherstone, R.F., Tindall, H., McCabe, D.J.H., Wallis, A., Brooks, M., Chambers, B., Chan, A., Chu, P., Clark, D., Dewey, H., Donnan, G., Fell, G., Hoare, M., Molan, M., Roberts, A., Roberts, N., Beiles, B., Bladin, C., Clifford, C., Fell, G., Grigg, M., New, G., Bell, R., Bower, S., Chong, W., Holt, M., Saunderson, A., Than, P.G., Gett, S., Leggett, D., McGahan, T., Quinn, J., Ray, M., Wong, A., Woodruff, P., Foreman, R., Schultz, D., Scoop, R., Stanley, B., Allard, B., Atkinson, N., Cambell, W., Davies, S., Field, P., Milne, P., Mitchell, P., Tress, B., Yan, B., Beasley, A., Dunbabin, D., Stary, D., Walker, S., Cras, P., d'Archambeau, O., Hendriks, J.M.H., Van Schil, P., Bosiers, M., Deloosse, K., van Buggenhout, E., De Letter, J., Devos, V., Ghekiere, J., Vanhooren, G., Astarci, P., Hammer, F., Lacroix, V., Peeters, A., Verhelst, R., DeJaegher, L., Peeters, A., Verbist, J., Blair, J.F., Caron, J.L., Daneault, N., Giroux, M.F., Guilbert, F., Lanthier, S., Lebrun, L.H., Oliva, V., Raymond, J., Roy, D., Soulez, G., Weill, A., Hill, M., Hu, W., Hudion, M., Morrish, W., Sutherland, G., Wong, J., Alback, A., Harno, H., Ijas, P., Kaste, M., Lepantalo, M., Mustanoja, S., Paananen, T., Porras, M., Putaala, J., Railo,

- M., Sairanen, T., Soine, L., Vehmas, A., Vikatmaa, P., Goertler, M., Halloul, Z., Skalej, M., Brennan, P., Kelly, C., Leahy, A., Moroney, J., Thornton, J., Koelemay, M.J.W., Nederkoorn, P.J., Reekers, J.A.A., Roos, Y.B.W.E.M., Hendriks, J.M., Koudstaal, P.J., Pattynama, P.M.T., van der Lugt, A., van Dijk, L.C., van Sambeek, M.R.H.M., van Urk, H., Verhagen, H.J.M., Bruininckx, C.M.A., de Bruijn, S.F., Keunen, R., Knippenberg, B., Mosch, A., Treurniet, F., van Dijk, L., van Overhagen, H., Wever, J., de Beer, F.C., van den Berg, J.S.P., van Hasselt, B.A.A.M., Zeilstra, D.J., Boiten, J., van Otterloo, J.C.A.D., de Vries, A.C., Nieholt, G.J.L.A., van der Kallen, B.F.W., Blankensteijn, J.D., De Leeuw, F.E., Kool, L.J.S., van der Vliet, J.A., de Borst, G.J., de Kort, G.A.P., Kapelle, L.J., Lo, T.H., Mali, W.P.T.M., Moll, F., van der Worp, H.B., Verhagen, H., Barber, P.A., Bouchier, R., Hill, A., Holden, A., Stewart, J., Bakke, S.J., Krohg-Sorensen, K., Skjelland, M., Tennoe, B., Bialek, P., Biejat, Z., Czepiel, W., Czlonkowska, A., Dowzenko, A., Jedrzejska, J., Kobayashi, A., Lelek, M., Polanski, J., Kirbis, J., Milosevic, Z., Zvan, B., Blasco, J., Chamorro, A., Macho, J., Obach, V., Riambau, V., San Roman, L., Branera, J., Canovas, D., Estela, J., Gaibar, A.G., Perendreu, J., Bjorses, K., Gottsater, A., Ivancev, K., Maetzsch, T., Sonesson, B., Berg, B., Delle, M., Formgren, J., Gillgren, P., Kall, T.B., Konrad, P., Nyman, N., Takolander, R., Andersson, T., Malmstedt, J., Soderman, M., Wahlgren, C., Wahlgren, N., Binaghi, S., Hirt, L., Michel, P., Ruchat, P., Bonati, L.H., Engelter, S.T., Fluri, F., Guerke, L., Jacob, A.L., Kirsch, E., Lyrrer, P.A., Radue, E.W., Stierli, P., Wasner, M., Wetzel, S., Bonvin, C., Kalangos, A., Lovblad, K., Murith, N., Ruefenacht, D., Sztajzel, R., Higgins, N., Kirkpatrick, P.J., Martin, P., Adam, D., Bell, J., Bradbury, A.W., Crowe, P., Gannon, M., Henderson, M.J., Sandler, D., Shinton, R.A., Scriven, J.M., Wilmink, T., D'Souza, S., Egun, A., Guta, R., Puneekar, S., Seriki, D.M., Thomson, G., Brennan, A., Enevoldson, T.P., Gilling-Smith, G., Gould, D.A., Harris, P.L., McWilliams, R.G., Nasser, H.C., White, R., Prakash, K.G., Serracino-Inglott, F., Subramanian, G., Symth, J.V., Walker, M.G., Clarke, M., Davis, M., Dixit, S.A., Dolman, P., Dyker, A., Ford, G., Golkar, A., Jackson, R., Jayakrishnan, V., Lambert, D., Lees, T., Louw, S., Macdonald, S., Mendelow, A.D., Rodgers, H., Rose, J., Stansby, G., Wyatt, M., Baker, T., Baldwin, N., Jones, L., Mitchell, D., Munro, E., Thornton, M., Baker, D., Davis, N., Hamilton, G., McCabe, D., Platts, A., Tibballs, J., Beard, J., Cleveland, T., Dodd, D., Gaines, P., Lonsdale, R., Nair, R., Nassef, A., Nawaz, S., Venables, G., Belli, A., Clifton, A., Cloud, G., Halliday, A., Markus, H., McFarland, R., Morgan, R., Pereira, A., Thompson, A., Chataway, J., Cheshire, N., Gibbs, R., Hammady, M., Jenkins, M., Malik, I., Wolfe, J., Adiseshiah, M., Bishop, C., Brew, S., Brookes, J., Brown, M.M., Jager, R., Kitchen, N., Ashleigh, R., Butterfield, S., Gamble, G.E., McCollum, C., Nasim, A., O'Neill, P., Wong, J., Edwards, R.D., Lees, K.R., MacKay, A.J., Moss, J., Rogers, P., Study, I.C.S., 2010. Carotid artery stenting compared with endarterectomy in patients with symptomatic carotid stenosis (International Carotid Stenting Study): an interim analysis of a randomised controlled trial. *Lancet* 375, 985–997.
- Eickhoff, S.B., Laird, A.R., Grefkes, C., Wang, L.E., Zilles, K., Fox, P.T., 2009. Coordinate-based activation likelihood estimation meta-analysis of neuroimaging data: a random-effects approach based on empirical estimates of spatial uncertainty. *Hum. Brain Mapp.* 30, 2907–2926.
- Eickhoff, S.B., Nichols, T.E., Laird, A.R., Hoffstaedter, F., Amunts, K., Fox, P.T., Bzdok, D., Eickhoff, C.R., 2016. Behavior, sensitivity, and power of activation likelihood estimation characterized by massive empirical simulation. *NeuroImage* 137, 70–85.
- Eklund, A., Nichols, T.E., Knutsson, H., 2016. Cluster failure: why fMRI inferences for spatial extent have inflated false-positive rates. *Proc. Natl. Acad. Sci. U. S. A.* 113, 7900–7905.
- Ellison-Wright, I., Glahn, D.C., Laird, A.R., Thelen, S.M., Bullmore, E.T., 2008. The anatomy of first-episode and chronic schizophrenia: an anatomical likelihood estimation meta-analysis. *Am. J. Psychiatr.* 165, 1015–1023.
- Fink, H.A., Hemmy, L.S., MacDonald, R., Carlyle, M.H., Olson, C.M., Dysken, M.W., McCarten, J.R., Kane, R.L., Garcia, S.A., Rutks, I.R., Ouellette, J., Wilt, T.J., 2015. Intermediate- and long-term cognitive outcomes after cardiovascular procedures in older adults: a systematic review. *Ann. Intern. Med.* 163 107–+.
- Gensicke, H., Zumburn, T., Jongen, L.M., Nederkoorn, P.J., Macdonald, S., Gaines, P.A., Lyrrer, P.A., Wetzel, S.G., van der Lugt, A., Mali, W.P.T.M., Brown, M.M., van der Worp, H.B., Engelter, S.T., Bonati, L.H., Investigators, I.-M.S., 2013. Characteristics of ischemic brain lesions after stenting or endarterectomy for symptomatic carotid artery stenosis results from the international carotid stenting study-magnetic resonance imaging substudy. *Stroke* 44, 80–U153.
- Ghogawala, Z., Westerveld, M., Amin-Hanjani, S., 2008. Cognitive outcomes after carotid revascularization: the role of cerebral emboli and hypoperfusion. *Neurosurgery* 62, 385–395.
- Ghogawala, Z., Amin-Hanjani, S., Curran, J., Ciarleglio, M., Berenstein, A., Stabile, L., Westerveld, M., 2013. The effect of carotid endarterectomy on cerebral blood flow and cognitive function. *J. Stroke Cerebrovasc. Dis.* 22, 1029–1037.
- Glahn, D.C., Laird, A.R., Ellison-Wright, I., Thelen, S.M., Robinson, J.L., Lancaster, J.L., Bullmore, E.T., Fox, P.T., 2008. Meta-analysis of gray matter anomalies in schizophrenia: application of anatomical likelihood estimation and network analysis. *Biol. Psychiatry* 64, 774–781.
- Hachinski, V., Iadecola, C., Petersen, R.C., Breteler, M.M., Nyenhuis, D.L., Black, S.E., Powers, W.J., DeCarli, C., Merino, J.G., Kalaria, R.N., Vinters, H.V., Holtzman, D.M., Rosenberg, G.A., Wallin, A., Dichgans, M., Marler, J.R., Leblanc, G.G., 2006. National Institute of Neurological Disorders and Stroke-Canadian Stroke Network vascular cognitive impairment harmonization standards. *Stroke* 37, 2220–2241.
- Heyer, E.J., Adams, D.C., Solomon, R.A., Todd, G.J., Quest, D.O., McMahon, D.J., Steneck, S.D., Choudhri, T.F., Connolly, E.S., 1998. Neuropsychometric changes in patients after carotid endarterectomy. *Stroke* 29, 1110–1115.
- Heyer, E.J., Mergeche, J.L., Stern, Y., Malone, H.R., Bruce, S.S., Ward, J.T., Connolly, E.S., 2014. Apolipoprotein E-epsilon 4 polymorphism and cognitive dysfunction after carotid endarterectomy. *J. Clin. Neurosci.* 21, 236–240.
- Heyer, E.J., Mallon, K.A., Mergeche, J.L., Stern, Y., Connolly, E.S., 2015. Deficits of hand coordination and laterality of carotid endarterectomy. *J. Neurosurg.* 122, 101–106.
- Hillis, A.E., Work, M., Barker, P.B., Jacobs, M.A., Breese, E.L., Maurer, K., 2004. Re-examining the brain regions crucial for orchestrating speech articulation. *Brain* 127, 1479–1487.
- Incalzi, R.A., Gemma, A., Landi, F., Pagano, F., Capparella, O., Snider, F., Manni, R., Carbonin, P., 1997. Neuropsychologic effects of carotid endarterectomy. *J. Clin. Exp. Neuropsychol.* 19, 785–794.
- Jenkinson, M., Beckmann, C.F., Behrens, T.E., Woolrich, M.W., Smith, S.M., 2012. FSL. *NeuroImage* 62, 782–790.
- Johnson, M.L., Pietz, K., Battleman, D.S., Beyth, R.J., 2004. Prevalence of comorbid hypertension and dyslipidemia and associated cardiovascular disease. *Am. J. Manag. Care* 10, 926–932.
- Kansagra, A.P., Wong, E.C., 2008. Quantitative assessment of mixed cerebral vascular territory supply with vessel encoded arterial spin labeling MRI. *Stroke* 39, 2980–2985.
- Katsoulas, G., Tsolakis, I., Argyriou, A.A., Polychronopoulos, P., Argentiou, M., Chroni, E., 2005. Effects of carotid endarterectomy on motor evoked potentials elicited by transcranial magnetic stimulation. *J. Neurol.* 252, 1050–1054.
- Kim, J.J., Schwartz, S., Wen, J., Devirgilio, C., Lobue, A., Walot, I., Koopmann, M., Donayre, C., White, R.A., 2015. Comparison of neurocognitive outcomes after carotid endarterectomy and carotid artery stenting. *Am. Surg.* 81, 1010–1014.
- Kougias, P., Collins, R., Pastorek, N., Sarath, S., Barshes, N.R., McCulloch, K., Pisimisis, G., Berger, D.H., 2015. Comparison of domain-specific cognitive function after carotid endarterectomy and stenting. *J. Vasc. Surg.* 62, 355–361.
- Kuliha, M., Roubec, M., Prochazka, V., Jonszta, T., Hrbac, T., Havelka, J., Goldirova, A., Langova, K., Herzig, R., Skoloudik, D., 2015. Randomized clinical trial comparing neurological outcomes after carotid endarterectomy or stenting. *Br. J. Surg.* 102, 194–201.
- Laird, A.R., McMillan, K.M., Lancaster, J.L., Kochunov, P., Turkeltaub, P.E., Pardo, J.V., Fox, P.T., 2005. A comparison of label-based review and ALE meta-analysis in the stroop task. *Hum. Brain Mapp.* 25, 6–21.
- Laird, A.R., Eickhoff, S., Kurth, F., Fox, P., Uecker, A., Turner, J., Robinson, J., Lancaster, J., Fox, P., 2009. ALE meta-analysis workflows via the brainmap database: progress towards a probabilistic functional brain atlas. *Front. Neuroinform.* 3, 1–11.
- Lancaster, J.L., Tordesillas-Gutierrez, D., Martinez, M., Salinas, F., Evans, A., Zilles, K., Mazziotta, J.C., Fox, P.T., 2007. Bias between MNI and Talairach coordinates analyzed using the ICBM-152 brain template. *Hum. Brain Mapp.* 28 (11), 1194–1205.
- Lanza, G., Bramanti, P., Cantone, M., Pennisi, M., Pennisi, G., Bella, R., 2017. Vascular cognitive impairment through the looking glass of transcranial magnetic stimulation. *Behav. Neurol.* 2017, 1421326.
- Malcharek, M., Ulkatan, S., Marinò, V., Geyer, M., Lladó-Carbó, E., Perez-Fajardo, G., Arranz-Arriaga, B., Climent, J., Aloj, F., Franco, E., Chiacchiarri, L., Kulpok, A., Sablotzki, A., Hennig, G., Deletis, V., 2013. Intraoperative monitoring of carotid endarterectomy by transcranial motor evoked potential: a multicenter study of 600 patients. *Clin. Neurophysiol.* 124, 1025–1030.
- Medicine, I.O., 2014. Veterans and Agent Orange: Update 2012. Washington D.C.
- Migliara, B., Trentin, M., Idone, D., Mirandola, M., Griso, A., Lino, M., 2013. Neurocognitive changes after eversion carotid endarterectomy under local anesthesia. *Ann. Vasc. Surg.* 27, 727–735.
- Min, W.K., Park, K.K., Kim, Y.S., Park, H.C., Kim, J.Y., Park, S.P., Suh, C.K., 2000. Atherothrombotic middle cerebral artery territory infarction - topographic diversity with common occurrence of concomitant small cortical and subcortical infarcts. *Stroke* 31, 2055–2061.
- Mononen, H., Lepojarvi, M., Kallanranta, T., 1990. Early neuropsychological outcome after carotid endarterectomy. *Eur. Neurol.* 30, 328–333.
- Ortega, G., Alvarez, B., Quintana, M., Yugueros, X., Alvarez-Sabin, J., Matas, M., 2014. Asymptomatic carotid stenosis and cognitive improvement using transcervical stenting with protective flow reversal technique. *Eur. J. Vasc. Endovasc. Surg.* 47, 585–592.
- Pearson, S., Maddern, G., Fitridge, R., 2003. Cognitive performance in patients after carotid endarterectomy. *J. Vasc. Surg.* 38, 1248–1252.
- Pennisi, G., Bella, R., Lanza, G., 2015. Motor cortex plasticity in subcortical ischemic vascular dementia: what can TMS say? *Clin. Neurophysiol.* 126, 851–852.
- Pennisi, M., Lanza, G., Cantone, M., Ricceri, R., Spampinato, C., Pennisi, G., Di Lazzaro, V., Bella, R., 2016. Correlation between motor cortex excitability changes and cognitive impairment in vascular depression: pathophysiological insights from a longitudinal TMS study. *Neural Plast.* 2016, 10. <http://dx.doi.org/10.1155/2016/8154969>.
- Phan, T.G., Donnan, G.A., Wright, P.M., Reutens, D.C., 2005. A digital map of middle cerebral artery infarcts associated with middle cerebral artery trunk and branch occlusion. *Stroke* 36, 986–991.
- Phan, T.G., Srikanth, V., Reutens, D.C., 2006. Borderzone infarction: stroke topography does not easily equate with stroke mechanism. *Stroke* 37, 2658.
- Phan, T.G., Fong, A.C., Donnan, G.A., Srikanth, V., Reutens, D.C., 2009. Digital probabilistic atlas of the border region between the middle and posterior cerebral arteries. *Cerebrovasc. Dis.* 27, 529–536.
- Phan, T.G., Chen, J., Donnan, G., Srikanth, V., Wood, A., Reutens, D.C., 2010. Development of a new tool to correlate stroke outcome with infarct topography: a proof-of-concept study. *NeuroImage* 49, 127–133.
- Picetto, L., Spalletta, G., Casolla, B., Cacciarri, C., Cavallari, M., Fantozzi, C., Ciuffoli, A., Rasura, M., Imperiale, F., Sette, G., Caltagirone, C., Taurino, M., Orzi, F., 2013. Cognitive performance following carotid endarterectomy or stenting in asymptomatic patients with severe ICA stenosis. *Cardiovasc. Psych. Neuro.* 2013, 6.
- Poppert, H., Wolf, O., Theiss, W., Heider, P., Hollweck, R., Roettinger, M., Sander, D., 2006. MRI lesions after invasive therapy of carotid artery stenosis: a risk-modeling analysis. *Neurol. Res.* 28, 563–567.

- Rae, C.L., Hughes, L.E., Anderson, M.C., Rowe, J.B., 2015. The prefrontal cortex achieves inhibitory control by facilitating subcortical motor pathway connectivity. *J. Neurosci.* 35, 786–794.
- Rapp, J.H., Wakil, L., Sawhney, R., Pan, X.M., Yenari, M.A., Glastonbury, C., Coogan, S., Wintermark, M., 2007. Subclinical embolization after carotid artery stenting: new lesions on diffusion-weighted magnetic resonance imaging occur postprocedure. *J. Vasc. Surg.* 45, 867–872.
- Rosen, A.C., Prull, M.W., O'Hara, R., Race, E.A., Desmond, J.E., Glover, G.H., Yesavage, J.A., Gabrieli, J.D.E., 2002. Variable effects of aging on frontal lobe contributions to memory. *Neuroreport* 13, 2425–2428.
- Schilling, C.J., Storm, B.C., Anderson, M.C., 2014. Examining the costs and benefits of inhibition in memory retrieval. *Cognition* 133, 358–370.
- Skjelland, M., Krohg-Sørensen, K., Tennøe, B., Bakke, S.J., Brucher, R., Russell, D., 2009. Cerebral microemboli and brain injury during carotid artery endarterectomy and stenting. *Stroke* 40, 230–234.
- Smith, S.M., Jenkinson, M., Woolrich, M.W., Beckmann, C.F., Behrens, T.E., Johansen-Berg, H., Bannister, P.R., De, L.M., Drobnjak, I., Flitney, D.E., Niazy, R.K., Saunders, J., Vickers, J., Zhang, Y., De, S.N., Brady, J.M., Matthews, P.M., 2004. Advances in functional and structural MR image analysis and implementation as FSL. *NeuroImage* 23 (Suppl. 1), S208–S219.
- Smith, E.E., Salat, D.H., Jeng, J., McCreary, C.R., Fischl, B., Schmahmann, J.D., Dickerson, B.C., Viswanathan, A., Albert, M.S., Blacker, D., Greenberg, S.M., 2011. Correlations between MRI white matter lesion location and executive function and episodic memory. *Neurology* 76, 1492–1499.
- Takahashi, Y., Ogasawara, K., Matsumoto, Y., Kosayama, M., Yoshida, K., Kub, Y., Beppu, T., Murakami, T., Nanba, T., Ogawa, A., 2013. Changes in cognitive function after carotid endarterectomy in older patients: comparison with younger patients. *Neurol. Med. Chir.* 53, 353–359.
- Tedesco, M.M., Dalman, R.L., Zhou, W., Coogan, S.M., Lane, B., Lee, J.T., 2009. Reduction of postprocedure microemboli following retrospective quality assessment and practice improvement measures for carotid angioplasty and stenting. *J. Vasc. Surg.* 49, 607–612.
- Tiemann, L., Reidt, J.H., Esposito, L., Sander, D., Theiss, W., Poppert, H., 2009. Neuropsychological sequelae of carotid angioplasty with stent placement: correlation with ischemic lesions in diffusion weighted imaging. *PLoS One* 4, e7001.
- Turkeltaub, P.E., Eden, G.F., Jones, K.M., Zeffiro, T.A., 2002. Meta-analysis of the functional neuroanatomy of single-word reading: method and validation. *NeuroImage* 16, 765–780.
- Uchino, H., Nakamura, T., Kuroda, S., Houkin, K., Murata, J.-i., Saito, H., 2012. Intraoperative dual monitoring during carotid endarterectomy using motor evoked potentials and near-infrared spectroscopy. *World Neurosurg.* 78, 651–657.
- Wang, Q., Zhou, M., Zhou, Y., Ji, J., Raithel, D., Qiao, T., 2015. Effects of carotid endarterectomy on cerebral reperfusion and cognitive function in patients with high grade carotid stenosis: a perfusion weighted magnetic resonance imaging study. *Eur. J. Vasc. Endovasc. Surg.* 50, 5–12.
- Wang, L., Zhao, F., Wang, D., Hu, S., Liu, J., Zhou, Z., Lu, J., Qi, P., Song, S., 2016. Pressure drop in tortuosity/kinking of the internal carotid artery: simulation and clinical investigation. *Biomed. Res. Int.* 2016, 2428970.
- Ward, N.S., 2006. Compensatory mechanisms in the aging motor system. *Ageing Res. Rev.* 5, 239–254.
- Warren, D.E., Power, J.D., Bruss, J., Denburg, N.L., Waldron, E.J., Sun, H., Petersen, S.E., Tranel, D., 2014. In: Network measures predict neuropsychological outcome after brain injury. *Proceedings of the National Academy of Sciences of the United States of America*. 111. pp. 14247–14252.
- Wasser, K., Pilgram-Pastor, S.M., Schnaudigel, S., Stojanovic, T., Schmidt, H., Knauf, J., Groschel, K., Knauth, M., Hildebrandt, H., Kastrup, A., 2011. New brain lesions after carotid revascularization are not associated with cognitive performance. *J. Vasc. Surg.* 53, 61–70.
- Xia, Z.Y., Sun, Q.J., Yang, H., Zhang, M.X., Ban, R., Xu, G.L., Wu, Y.P., Wang, L.X., Du, Y.F., 2015. Effect of carotid artery stenting on cognitive function in patients with internal carotid artery stenosis and cerebral lacunar infarction: a 3-year follow-up study in China. *PLoS One* 10.
- Xu, G.L., Liu, X.F., Meyer, J.S., Yin, Q., Zhang, R.L., 2007. Cognitive performance after carotid angioplasty and stenting with brain protection devices. *Neurol. Res.* 29, 251–255.
- Zhou, W., Hitchner, E., Gillis, K., Sun, L.X., Floyd, R., Lane, B., Rosen, A., 2012. Prospective neurocognitive evaluation of patients undergoing carotid interventions. *J. Vasc. Surg.* 56, 1571–1578.
- Zhou, W., Baughman, B.D., Soman, S., Wintermark, M., Lazzeroni, L.C., Hitchner, E., Bhat, J., Rosen, A., 2017. Volume of subclinical embolic infarct correlates to long-term cognitive changes after carotid revascularization. *J. Vasc. Surg.* 65, 686–694.