

# Condyloma acuminatum of the male urethra: A case report

SAGE Open Medical Case Reports  
Volume 8: 1–3  
© The Author(s) 2020  
Article reuse guidelines:  
sagepub.com/journals-permissions  
DOI: 10.1177/2050313X20904584  
journals.sagepub.com/home/sco



Abdelrazak Meliti<sup>1,3</sup> , Abdulrahman Hawari<sup>1</sup>,  
Haneen Al-Maghrabi<sup>1</sup>  and Ghadeer Mokhtar<sup>1,2</sup>

## Abstract

Condyloma acuminatum is an anogenital lesion caused by the human papillomavirus infection. It is a common, sexually transmitted disease. It usually affects the external genitalia, while urethral and bladder involvement is uncommon. Human papillomavirus types are classified into three categories depending on their oncogenic potential: low risk (type 6, 11, 42, 43, 44, 59, 66, 68, and 70), intermediate-risk (type 30, 31, 33, 34, 35, 39, 40, 49, 51, 52, 53, 57, 58, 63, and 64) and high risk (type 16, 18, 45, and 56). High-risk and intermediate-risk human papillomavirus DNA types, together with other co-factors still to be defined, account for over 90% of anogenital pre-malignant and malignant tumours. Herein, we report a unique case of condyloma acuminatum positive for human papillomavirus -6 involving the penile urethra, presents as the primary and only site of the disease in a diabetic type-2 patient.

## Keywords

Human papillomavirus, low-risk HPV-6, condyloma acuminatum

Date received: 9 February 2019; accepted: 31 December 2019

## Introduction

Human papillomavirus (HPV) is a non-enveloped, small, double-stranded DNA virus which belongs to the *papillomavirus* family. There are many known genotypes of HPV, around 30–40 are known to infect human being.<sup>1</sup> HPVs are classified based on their oncogenic potential into high-risk (HR), intermediate-risk and low-risk (LR) types.<sup>2</sup> All types of HPV can infect epithelial cells of mucosal or cutaneous surfaces. Most condylomata are positive for HPV types 6 and 11, although co-infection with HR HPV is possible. HPVs 16 and 18 are the most common HR-HPV and are the leading cause of approximately 70% of cervical cancers in women, while in males they are the leading cause of anal and penile squamous carcinomas. Apart from the anogenital region, HR-HPV accounts for oropharyngeal carcinoma in both genders.<sup>3</sup> LR-HPV, primarily types 6 and 11, are the most common causes of benign lesions, that is, genital warts (condyloma acuminatum and flat condyloma) and laryngeal papilloma.<sup>3</sup> Condyloma acuminatum is one of the most common sexually transmitted diseases which affects millions of people worldwide every year. LR-type 6 HPV is responsible for about 89% of genital warts, whereas type 11 HPV cause 11% of genital warts.<sup>4</sup> Genital warts and condyloma acuminatum are highly infectious, with an approximate transmission rate of more

than 60%.<sup>5</sup> Condyloma bearing either HPV type 6 or 11 have similar clinical manifestations and histology.<sup>6</sup> They present clinically as solitary lesions but more often as clusters with a predilection to the anogenital area. They also involve mucocutaneous surfaces such as urethral opening, cervix, vagina, and anus.<sup>7</sup> However, proximal urethral involvement in males is very uncommon.

## Case report

We present a 47-year-old male patient, known case of diabetes and hypertension, well-controlled on medications. He is known to have bilateral renal stones for which he underwent

<sup>1</sup>Department of Anatomic Pathology & Laboratory Medicine, King Faisal Specialist Hospital & Research Centre, Jeddah, Saudi Arabia

<sup>2</sup>Department of Anatomic Pathology, Faculty of Medicine, King Abdulaziz University, Jeddah, Saudi Arabia

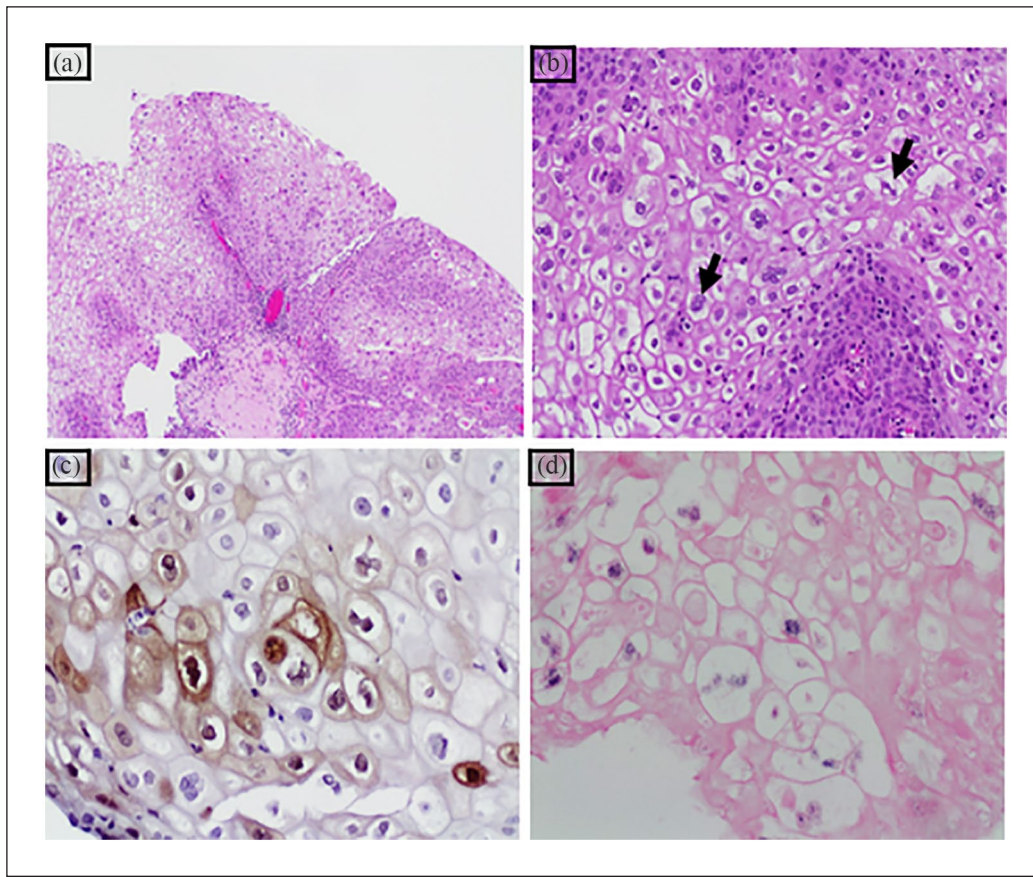
<sup>3</sup>Department of Laboratory Medicine & Pathology, University of Alberta, Edmonton, AB, Canada

### Corresponding Author:

Abdelrazak Meliti, Department of Anatomic Pathology & Laboratory Medicine, King Faisal Specialist Hospital & Research Centre, Jeddah Branch, P.O. Box 40047, Jeddah 21499, Saudi Arabia.

Emails: ameliti2014@gmail.com; mabeldelrazak@kfshrc.edu.sa





**Figure 1.** Histopathology examination of hematoxylin and eosin stain slides (H&E), immunohistochemistry, and in situ hybridization studies (ISH). (a) Papillary lesion composed of hyperplastic non-keratinizing stratified squamous epithelial proliferation (H&E, 10x); (b) dysplastic changes with increased N/C ratio, nuclear hyperchromasia, and mild atypia. koilocytotic changes and binucleation (black arrow) (H&E, 40x); (c) immunohistochemistry for p16 is positive in binucleated cells (100x) and (d) in-situ hybridization (ISH) is positive for HPV-6 (100x).

percutaneous nephrolithotomy (PCNL) and bilateral ureteroscopy (URS) with laser lithotripsy. The patient presented to our hospital with gross hematuria, he underwent cystoscopic examination which revealed a papillary-like lesion suspicious for malignancy within mid penile urethra extending distally. Nevertheless, the urethral meatus, prostatic urethra, and bladder neck were normal endoscopically. Apart from bilateral renal stones, the patient had no previous history of genitourinary pathology. Clinical examination of external genitalia was unremarkable for gross abnormality. The urethral lesion was removed through cystoscopic biopsy and submitted for histopathologic examination. Gross examination revealed a minute papillary-like tan tissue fragment. Microscopic examination showed a fragment of papillary proliferation composed of hyperplastic non-keratinizing stratified squamous epithelium. In areas HPV-related changes were evident, including koilocytotic atypia (nuclear wrinkling with perinuclear halos), and binucleation (Figure 1(a) and (b)). However, no convincing histopathological evidence of papillary urothelial carcinoma. P16 immunohistochemistry staining was positive (Figure 1(c)). In-situ hybridization

(ISH) was positive for HPV-6 (Figure 1(d)) and negative for HPV-16. Altogether, the histologic features and molecular studies were diagnostic of condyloma acuminata of the penile urethra. The postoperative stay was uneventful with a short hospital stay. The patient is followed-up regularly at the outpatient urology clinic. He is healthy with excellent functional performance status at 5 months.

## Discussion

Condyloma acuminatum uncommonly affects the male genital system, particularly the urethra. Male urethral involvement usually occurs in an association with external genitalia condylomata. A literature review revealed few reported cases of isolated male urethra condyloma acuminata. Olsen and colleagues presented one example of condyloma acuminatum of the prostatic urethra without associated lesions on the external genitalia, but these condylomas were extensively involving the urethral meatus.<sup>8</sup> Fralick and colleagues studied 114 biopsy-proven HPV infection of the external genitalia, of which 14 are

intraurethral lesions. Only 8 patients present with a single urethral lesion, and the remaining 6 with multiple lesions; all confined to anterior urethra.<sup>9</sup> The current case represents an isolated penile urethral papillary growth without previous or concurrent evidence of external genitalia involvement. The initial clinical impression raises the suspicion of a malignant urothelial neoplasm, particularly papillary urothelial carcinoma.

Nevertheless, the histopathologic examination revealed classic features of condyloma acuminatum. Confirmatory ancillary studies were positive P16 and HPV-ISH, which further support the histological impression. Few studies have suggested that chronic diseases with long-standing immunosuppression such as diabetes mellitus can be the initiative causative factor for urinary bladder malignancy. Pathophysiology of long-standing insulin resistance, along with the metabolism of body fat, is more likely to generate an environment of cellular destruction. Ultimately leading to random genetic mutations and cell proliferation that can contribute to metaplasia and dysplasia-carcinoma sequence.<sup>10</sup> The morphological differential diagnosis of the current case includes papillary urothelial carcinoma, squamous cell carcinoma (SCC), and verrucous carcinoma. High-grade papillary urothelial carcinoma predominantly exhibits significant disordered proliferation with loss of polarity, high N/C ratio, prominent nuclei, and atypical mitosis. SCC shows unequivocal malignant features either of keratinizing or non-keratinizing subtype with anaplastic cytonuclear changes.

On the other hand; verrucous carcinoma could arise on the external genitalia, exhibits an exophytic, non-infiltrative growth pattern with bushing borders. The role of HPV testing might not be necessary for condyloma acuminatum diagnosis as the cytomorphic features are usually sufficient for determination. However, it is essential not to misdiagnose condyloma acuminatum as a malignant lesion to avoid overtreatment.

## Conclusion

We report a unique case of isolated penile urethral condyloma acuminatum. Condyloma acuminatum involves not only the external genitalia but also on rare occasions could involve the prostatic urethra, urinary bladder, and ureter. Urologists and practicing pathologists should be aware of this uncommon event as a diagnostic pitfall and should always consider condyloma acuminatum in the differential diagnosis for malignant urothelial neoplasms to further enhance the clinical management plans safely.

## Declaration of conflicting interests

The author(s) declared no potential conflicts of interest with respect to the research, authorship, and/or publication of this article.

## Ethical approval

Ethical approval to report this case was obtained from King Faisal Specialist Hospital and Research Centre, Jeddah, Saudi Arabia (IRB 2018-CR-19).

## Funding


The author(s) received no financial support for the research, authorship, and/or publication of this article.

## Informed consent

Verbal and written informed consents were obtained from the patient for their anonymized information to be published in this article.

## ORCID iDs

Haneen Al-Maghrabi  <https://orcid.org/0000-0003-3088-7717>

Abdelrazak Meliti  <https://orcid.org/0000-0003-0845-6187>

## References

1. Alhamlan FS, Al-Qahtani AA and Al-Ahdal MN. Current studies on human papillomavirus in Saudi Arabia. *J Infect Dev Ctries* 2015; 9(6): 571–576.
2. Chrisofos M, Skolarikos A, Lazaris A, et al. HPV 16/18-associated condyloma acuminatum of the urinary bladder: first international report and review of literature. *Int J STD AIDS* 2004; 15(12): 836–838.
3. Grace M and Mravak-Stipetić M. Human papillomavirus-associated diseases. *Clin Dermatol* 2014; 32(2): 253–258.
4. Grce M, Husnjak K, Skerlev M, et al. Detection and typing of human papillomaviruses by means of polymerase chain reaction and fragment length polymorphism in male genital lesions. *Anticancer Res* 2000; 20(3B): 2097–2102.
5. Scarbrough Lefebvre CD, Van Krieking G, Goncalves MA, et al. Appraisal of the burden of genital warts from a health-care and individual patient perspective. *Public Health* 2011; 125(7): 464–475.
6. Lacey CJ, Lowndes CM and Shah KV. Burden and management of non-cancerous HPV-related conditions: HPV-6/11 disease. *Vaccine* 2006; 24(Suppl. 3): S35–S41.
7. Scheinfeld N. Condylomata acuminata (anogenital warts) in adults: epidemiology, pathogenesis, clinical features, and diagnosis, [https://www.uptodate.com/contents/condylomata-acuminata-anogenital-warts-in-adults-epidemiology-pathogenesis-clinical-features-and-diagnosis?search=condylomata-acuminata-anogenital-warts-in-adults-epidemiology-pathogenesis-clinical-features-and-diagnosis&source=search\\_result&selectedTitle=1~80&usage\\_type=default&display\\_rank=1](https://www.uptodate.com/contents/condylomata-acuminata-anogenital-warts-in-adults-epidemiology-pathogenesis-clinical-features-and-diagnosis?search=condylomata-acuminata-anogenital-warts-in-adults-epidemiology-pathogenesis-clinical-features-and-diagnosis&source=search_result&selectedTitle=1~80&usage_type=default&display_rank=1)
8. Olsen S, Marcussen N, Jensen KM, et al. Urethral condylomata, due to human papillomavirus (HPV) type 6/11, associated with transitional cell tumors in the bladder and ureter: a case report. *Scand J Urol Nephrol Suppl* 1995; 172: 51–55.
9. Fralick RA, Malek RS, Goellner JR, et al. Urethroscopy and urethral cytology in men with external genital condyloma. *Urology* 1994; 43(3): 361–364.
10. Habib SL and Rojna M. Diabetes and risk of cancer. *ISRN Oncol* 2013; 2013: 583786.