

SHORT REPORT

Rare Condition, Unusual Anatomy, Elegant Solution — an Uncommon Manifestation of Kawasaki Disease

Nuno H. Coelho ^{a,b,*}, Paulo Barreto ^a, Victor Martins ^a, Clara Nogueira ^{a,b}, Jacinta Campos ^{a,b}, Andreia Coelho ^{a,b}, Rita Augusto ^{a,b}, Carolina Semião ^a, Evelise Pinto ^a, João Ribeiro ^a, Alexandra Canedo ^{a,b}

^a Department of Angiology and Vascular Surgery, Centro Hospitalar, Vila Nova de Gaia/Espinho, Portugal

^b Faculty of Medicine, University of Porto, Porto, Portugal

Introduction: Peripheral artery aneurysms are a rare manifestation of Kawasaki disease (KD), with an estimated incidence of approximately 2% of all KD patients. The case of a 14-year-old girl with past clinical history suggestive of KD is reported; she presented with an aneurysm located in the brachial part of a superficial brachioulnoradial artery, still with the genuine brachial artery in place (an anatomical variation with a reported incidence of 0.14–1.3% in general population). Relevant medical data were collected from the hospital database.

Report: This is a report of a case of a symptomatic superficial brachioulnoradial artery aneurysm, secondary to KD, treated with aneurysm exclusion and superficial brachioulnoradial to the genuine brachial artery transposition. Uneventful intra- and postoperative course with symptom resolution is reported.

Discussion: The coexistence of a rare manifestation of KD (peripheral aneurysm) with an even rarer brachial artery variation allowed a simple but elegant solution, making this a unique case.

© 2018 The Authors. Published by Elsevier Ltd on behalf of European Society for Vascular Surgery. This is an open access article under the CC BY-NC-ND license (<http://creativecommons.org/licenses/by-nc-nd/4.0/>).

Article history: Received 2 July 2018, Revised 1 November 2018, Accepted 7 November 2018,

Keywords: Kawasaki disease, Brachial artery aneurysm, Superficial brachioulnoradial artery, Brachial–antebrachial arterial pattern variations

INTRODUCTION

Kawasaki disease (KD) is of unknown cause and is an acute, self-limited, small and medium-sized vessels vasculitis; the diagnosis is based on clinical criteria.¹ Apart from the hypothesis of an infectious trigger, a possible genetic contribution is suggested by epidemiological studies that show a 10-fold increased risk of KD in siblings of an index case.^{2,3} It affects children younger than 4–5 years and is the leading cause of acquired heart disease in this group age.^{4,5} In addition to life-threatening coronary artery involvement, aneurysms may develop in almost any medium-sized vessels; however, peripheral artery aneurysms (PAAs) are rarely described (incidence less than 2% in KD patients).^{5,6} The improved results obtained with aspirin and immunoglobulin in the acute setting dramatically reduced mortality, and late-onset PAA could have a higher incidence than previously reported because PAA can remain asymptomatic in KD's acute phase. Later, compressive symptoms or limb-threatening events such as thromboembolization may prompt aneurysm diagnosis and treatment. Nevertheless,

the relation between a previous KD and a later manifestation may be difficult to establish.

CASE REPORT

A 14-year-old girl presented in the outpatient clinic with a painful pulsatile left arm mass and occasional hand paresthesia. Clinical history revealed a familiar history of KD (older sister) and a previous admission at 9 years-old, due to fever and unspecified exanthematic disease, managed only with symptomatic medications. Since then, she noted a pulsatile mass in the left arm medial aspect associated with vague and sporadic complaints of pain that were never serious enough to be brought to medical attention. Five years later, she started to report more frequent pain over the mass, associated with hand paresthesia. A duplex ultrasound (DUS) was performed revealing a left brachial aneurysm and she was referred to our center. A careful DUS evaluation, complemented with computed tomography angiography (angio-CT) (Fig. 1), revealed a bilateral superficial brachioulnoradial (SBUR) artery with an axillary origin (crossing superficial to the median nerve, but under the brachial fascia, branching into radial and ulnar arteries at the elbow level) coexisting with a “normal” brachial artery (deep track in relation to median nerve, extending to the forearm as common interosseous trunk). On the left side, a 15-mm fusiform aneurysm with a craniocaudal length of 42 mm with abundant mural thrombus was identified,

* Corresponding author. Rua Conceição Fernandes s/n, 4434-502 Vila Nova de Gaia, Portugal.

E-mail address: nunoc.90@gmail.com (Nuno H. Coelho).

2405-6553/© 2018 The Authors. Published by Elsevier Ltd on behalf of European Society for Vascular Surgery. This is an open access article under the CC BY-NC-ND license (<http://creativecommons.org/licenses/by-nc-nd/4.0/>).

<https://doi.org/10.1016/j.ejvssr.2018.11.002>

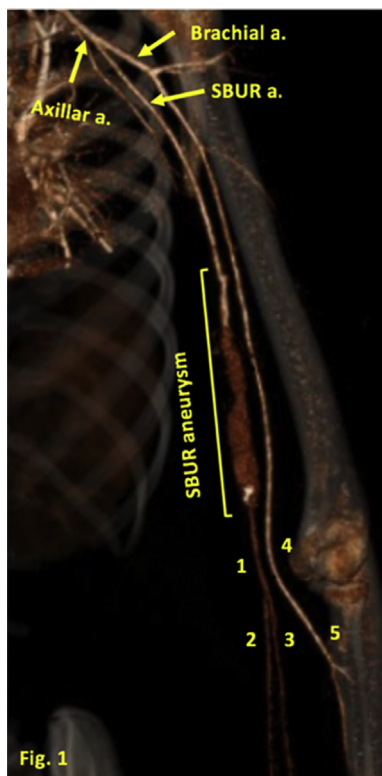

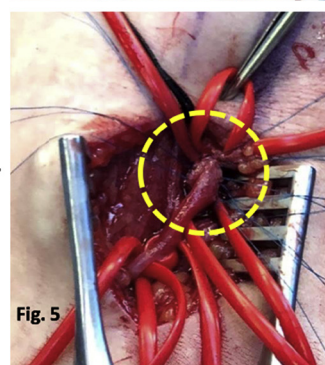
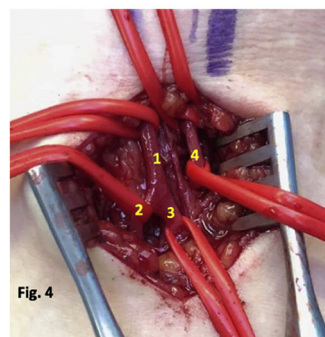
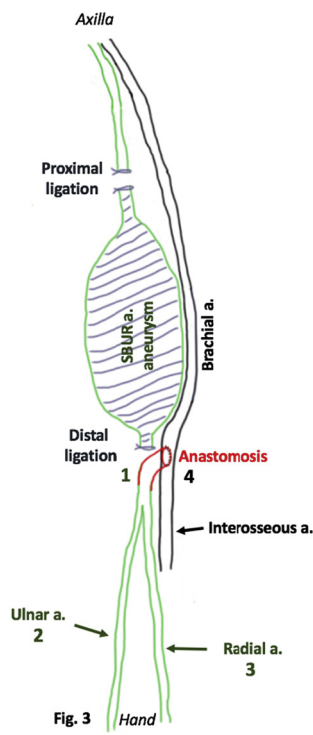
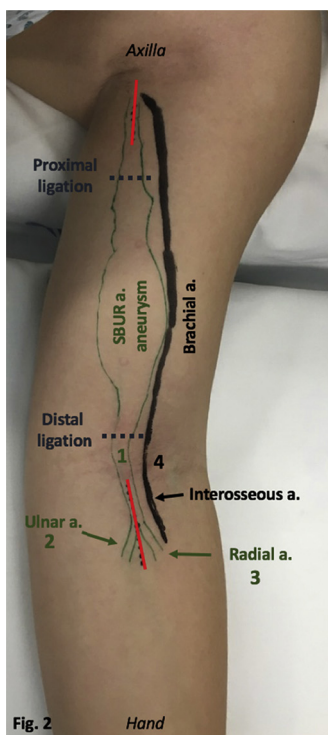
Figure 1. Left arm computed tomography angiography. (1) SBUR; (2) ulnar artery; (3) radial artery; (4) brachial artery; (5) interosseous artery. SBUR = superficial brachioulnoradial artery.

addressing the brachial part of the SBUR artery, with the genuine brachial artery still in place. Radial and cubital arteries presented triphasic antegrade flow, collapsing when performing selective SBUR artery manual compression. The genuine brachial artery presented normal triphasic antegrade flow. Coronary and other peripheral aneurysms were excluded using angio-CT.

Owing to thrombus burden and compressive complaints, a surgical approach was performed: aneurysm exclusion and distal SBUR to distal genuine brachial artery transposition with a latero-terminal anastomosis, through separate stitches (Figs. 2–5). The postoperative course was uneventful and the patient was discharged 2 days after surgery, with radial and cubital pulses present. Aneurysmatic artery specimen histopathology was consistent with KD vasculitis. On follow-up evaluation, 2 months after surgery, the patient reported no symptoms. DUS evaluation demonstrated triphasic antegrade flow at the radial and cubital arteries and complete aneurysm thrombosis and shrinkage (15 mm–7.8 mm).

DISCUSSION

In this case, the presence of a PAA at such an early age associated with a positive familiar history of KD (patient’s sister, who was diagnosed and treated for KD at the age of 5 years) raised the suspicion of KD-related PAA. When they were asked, both parents and patient described a previous admission at 9 years with clinical signs and symptoms



Figures 2–5. Perioperative DUS planning (Fig. 2): the procedure was undertaken through two small incisions: one near the axilla and one at the cubital fossa (red lines). Intervention planning is represented in Fig. 3. Initially, distal SBUR artery (1), SBUR bifurcation into cubital (2) and radial (3) arteries and distal brachial artery (4) were isolated at cubital fossa (Fig. 4). After that, the proximal SBUR artery was isolated through an upper arm incision. Then SBUR artery aneurysm ligation was performed in the proximal and distal part (black lines, Fig. 1). Finally, distal SBUR to distal brachial artery transposition, with latero-terminal anastomosis and separated stitches, was performed with interosseous artery preservation (Fig. 5). SBUR a. = superficial brachioulnoradial artery; a. = artery.

compatible with an incomplete manifestation of KD that did not undergo proper diagnosis or treatment. It is known that, in the acute phase, KD treatment with intravenous immunoglobulins and aspirin is effective and can even lead to aneurysm regression.⁶ However, and despite being noted since then, the pulsatile left arm mass was only investigated 5 years later, at a time when it was already symptomatic and requiring intervention. Surgery in KD-related PAA is rarely reported in the literature and it is often complex, not only due to anatomic factors but also due to the patient's age. Endovascular treatment, although possible and less aggressive, may be not advisable at such an early age.⁶ In the reported case, an unusual bilateral brachial artery variation, with a reported incidence of only 0.14–1.3% in some case series,⁷ allowed this simple, but inventive, solution: using only autologous conduits and performed using two small skin incisions (Fig. 2). Considering the absence of feeding collaterals and the risk of iatrogenic nerve damage, the aneurysm was excluded (proximal and distal ligation) without excision, minimizing the number of incisions and their length. As previously mentioned, surveillance DUS proved complete aneurysm thrombosis and shrinkage. A lifelong annual surveillance program was implemented, to exclude the appearance of metachronous PAA. The patient's sister was also investigated for PAA and both continue to be followed by the Pediatric Department.

CONCLUSION

Coronary KD involvement is of paramount importance. Peripheral artery aneurysm degeneration should never be neglected, owing to its inherent morbidity (highlighting thromboembolic complications). The coexistence of this rare brachial artery aneurysm with an even rarer brachial artery variation allowed a simple but elegant solution, making this a unique case.

ACKNOWLEDGMENTS

We thank to the Department of Human Anatomy, Faculty of Medicine University of Porto, for the anatomical variation analysis.

CONFLICTS OF INTEREST

None.

FUNDING

None.

REFERENCES

- 1 Eleftheriou D, Levin M, Shingadia D, Tulloh R, Klein NJ, Brogan PA. Management of Kawasaki disease. *Arch Dis Child* 2014;**99**:74–83.
- 2 Hirata S, Nakamura Y, Yanagawa H. Incidence rate of recurrent Kawasaki disease and related risk factors: from the results of nationwide surveys of Kawasaki disease in Japan. *Acta Paediatr* 2001;**90**:40–4.
- 3 Uehara R, Yashiro M, Nakamura Y, Yanagawa H. Kawasaki disease in parents and children. *Acta Paediatr* 2003;**92**:694–7.
- 4 Mason A. *NIH Public Access* 2009;**19**:389–99.
- 5 Satou GM, Giamelli J, Gewitz MH. Kawasaki disease: diagnosis, management, and long-term implications. *Cardiol Rev* 2007;**15**: 163–9.
- 6 Hoshino S, Tsuda E, Yamada O. Characteristics and fate of systemic artery aneurysm after Kawasaki disease. *J Pediatr* 2015;**167**:108–112.e2.
- 7 Rodríguez-Niedenführ M, Vázquez T, Nearn L, Ferreira B, Parkin I, Sañudo Jr. Variations of the arterial pattern in the upper limb revisited: a morphological and statistical study, with a review of the literature. *J Anat* 2001;**199**:547–66.