



## Original Research Article

# Volumetric and dosimetric comparison of two delineation guidelines for the radiation treatment of laryngeal squamous cell carcinoma

C. Bondue<sup>a,\*</sup>, S. Racadot<sup>b</sup>, A. Coutte<sup>a</sup>, P. Dupuis<sup>b</sup>, M.C. Biston<sup>b</sup>, V. Grégoire<sup>b</sup><sup>a</sup> Department of Radiation Oncology, University Hospital, Amiens, France<sup>b</sup> Department of Radiation Oncology, Centre Léon Bérard, Lyon, France

## ARTICLE INFO

## Article history:

Received 28 March 2019

Revised 31 May 2019

Accepted 9 June 2019

Available online 20 June 2019

## Keywords:

Delineation guidelines

Primary tumor clinical target volume

Larynx

Dosimetry

## ABSTRACT

**Purpose:** Three methods have been recently proposed for the delineation of the primary tumor clinical target volume (CTV-P) in Head and Neck Cancers: the anatomic method popularized in the French literature by Lapeyre et al. the geometric methods proposed by the DAHANCA group, and more recently the international guidelines promoted by Grégoire et al. integrating the latter two. The aim of this study was to perform a volumetric and dosimetric comparison of the French and the International consensus methods in laryngeal SCC.

**Patients and methods:** Two radiation oncologists independently delineated the high dose and low dose primary tumor CTV in four patients with T2 or T3 N0-M0 laryngeal SCC following either the so-called French guidelines or the International guidelines. For the 4 cases, the GTV was delineated by a single radiation oncologist. Nodal CTVs were delineated by one radiation oncologist for the 4 cases using International guidelines. Dose optimization was then performed with VMAT (MONACO version 5.11) using 6 MeV photons. Differences in target volumes and dose distributions in OARs and PTVs were then evaluated with various metrics such as the DICE Similarity Coefficient and the homogeneity index.

**Results:** Major differences were observed in the CTV delineation between the 2 delineation methods for the low dose volumes and to a lower extent for the high dose volumes. These differences translated into variations in dose distribution favoring the International guidelines for decreasing dose to various OARs. Such differences toned down when dose distribution on the primary tumors PTVs and nodal PTVs were combined.

**Conclusion:** This study demonstrated large differences in CTV delineation between the 2 delineation guidelines. Such differences translated into differences in dose distribution.

Published by Elsevier B.V. on behalf of European Society for Radiotherapy and Oncology. This is an open access article under the CC BY-NC-ND license (<http://creativecommons.org/licenses/by-nc-nd/4.0/>).

## 1. Introduction

The delineation of target volumes (TV) for Head and Neck (H&N) IMRT (Intensity-Modulated Radiation Therapy) is a complex process requiring a deep knowledge of H&N anatomy and pathways of tumor spread. Several retrospective studies have shown a large inter-observer variability (IOV) in radiotherapy target volume delineation [1]. These differences are well-recognized for their potential impacts on dose distribution and clinical outcomes [2].

In H&N cancer, to reduce the IOV in the delineation, international consensus guidelines have been published for the Organ at

Risk (OARs) delineation [3], and for the nodal Clinical Target Volume (CTV-N) in the node-negative and then in the node positive neck [4,5]. For the primary tumor clinical target volume delineation (CTV-P), a new international consensus was published by Grégoire et al. in 2018 [6]. These international guidelines have been developed as a guide to help radiation oncologists to delineate their target volumes, and likely help in reducing inter-clinician variability. Such guidelines are of interest when elaborating Quality Assurance recommendations for Head and Neck squamous cell carcinoma (SCC). In a nutshell, there have been traditionally two non-exclusive approaches for the delineation of the primary tumor clinical target volume. The anatomical school was proposed in 2002 by Eisbruch et al. and by Grégoire in 2003, and was based on the knowledge of local tumors spread using compartmentalization of head and neck anatomy [7,8]. This anatomic margin approach was further developed and diffused in

\* Corresponding author at: Department of Radiotherapy, University Hospital of Amiens-Picardie, 1 rond-point du Professeur Christian Cabrol, 80054 Amiens Cedex 1, France.

E-mail address: [c.bondue88@gmail.com](mailto:c.bondue88@gmail.com) (C. Bondue).

the French literature by Lapeyre et al. [9–11]. He systematically reviewed the H&N anatomy emphasizing on the various routes for tumor dissemination based on the identification of weak and resistant anatomic structures. According to these guidelines, the high dose CTV includes the gross tumor volume (GTV) plus a 3 to 10 mm margin depending on the tumor location and the presence of anatomic barriers. The lower dose CTV includes the entire anatomical compartment(s) at risk of tumor cells dissemination. When no barrier is clearly identified, the proposal is to use a typical margin of 2–3 cm from the border of the GTV. This approach was proposed irrespective of the tumor T-stage.

The second approach is the geometric delineation promoted recently by DAHANCA and is based on the geometric expansion of the Gross Tumor Volume (GTV-P). The main argument supporting this approach is that tumor cell density decreases with distance from the edge of the GTV. Those data are derived from pathological examinations, and on the basis on these observations, DAHANCA proposed to define a high-risk CTV including the primary tumor GTV plus a 5 mm margin, and a lower risk CTV with an additional 5 mm margin. These CTV are only adjusted for natural anatomic boundaries such as bone and air cavities. In support of this proposal was a recent retrospective study from 3 Danish centers reporting that the majority of primary tumor recurrences were found within 10 mm from the boundary of the GTV, and that various delineation practices had limited impact on disease local recurrence [12]. Hansen et al. have demonstrated that the use of these guidelines translated into more homogeneous target volume delineation among Danish centers [13].

In this framework, the new international consensus guidelines proposed by Gregoire and al., aimed at reconciling the anatomic and geometric concepts for primary tumor CTV delineation by including a deeper anatomic component into the geometric concept [6]. In short, these guidelines propose an expansion of the primary tumor GTV by 5 and 10 mm but adapted to the H&N anatomy to generate the high and low dose CTV, respectively. This proposal is a probabilistic approach, and target volume delineation will be considered optimal when reaching a compromise between a too tight volume that could be associated to an unacceptable rate of local recurrence, and a too large volume, which could be associated to an unacceptable rate of treatment morbidity.

Currently, no comparison between the International guidelines and the anatomic approach has been performed. The aim of this study was to compare the delineation of the primary tumor Clinical Target Volumes in 4 laryngeal tumors (T2 or T3) in terms of volume and dose distribution after VMAT planning.

## 2. Materials and methods

### 2.1. Patient characteristics

Four patients with laryngeal SCC were included into this study. The first patient was an active smoker male of 64 years, without comorbidities, who complained about progressive dysphonia. A fiberoptic examination completed by an endoscopy under general anesthesia with biopsy, and a diagnostic CT scan revealed a glottic SCC infiltrating the whole right vocal cord, the anterior commissure, the 2/3 of the left vocal cord, the right ventricle and the ventricular band up to the arytenoid. The larynx was fixed. No cervical node was identified. This tumor was staged T3-N0-M0 of the glottic larynx (UICC/AJCC 8th TNM edition).

The second patient was a 60 years old man, with gastroesophageal reflux, who has been diagnosed with a glottic SCC. This lesion was originating at the vocal process and the right vocal cord

with an extension into the ventricular band, without invasion of the anterior commissure. The mobile cord was mobile. The lesion was staged T2-N0-M0 (UICC/AJCC 8th TNM edition) of the glottic larynx.

The third patient was a 66 years old active smoker man, with cardiovascular comorbidities who complained of progressive dysphonia. Fiberoptic examination, endoscopy under general anesthesia with biopsies and a diagnostic CT scan demonstrated a SCC of 16 × 20 mm of the foot of epiglottis. The pre-epiglottic space was invaded as well as the anterior commissure. The larynx was mobile. No cervical node was identified. The lesion was staged T3-N0-M0 (UICC/AJCC 8th TNM edition) of the supra-glottic larynx.

The fourth patient was a 70 years old man. The tumor invaded the totality of the right vocal cord, the anterior commissure, the right arytenoid and the ventricular band. At the clinical investigation, the larynx was fixed. There was no infiltration of the pre-epiglottic space, and no lymph node was identified. This lesion was classified T3-N0-M0 (UICC/AJCC 8th TNM edition) of the glottic larynx.

### 2.2. Contouring of the organs at risk and target volumes

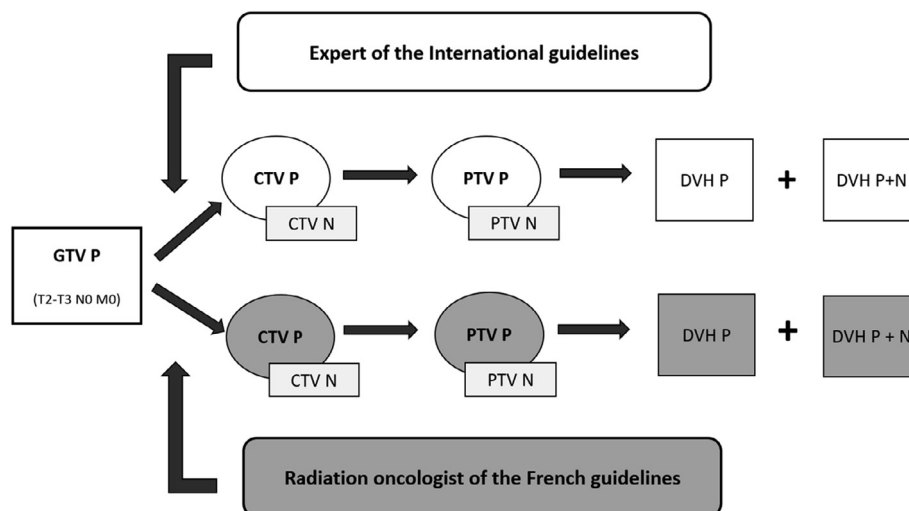
The primary tumor GTV were delineated by V. Grégoire (VG) using information provided by the fiberoptic examination, the description of the lesion visualized during the endoscopy under general anesthesia and the diagnostic and planning CT. The primary target volume CTVs were delineated by (VG) according to the International consensus guidelines, and by S. Racadot (SR) according to the French anatomic guidelines. Both observers delineated a low dose CTV (so-called CTV-P2) and a high dose CTV (so-called CTV-P1). For the French anatomic delineation, the CTV-P1 included the GTV-P and potentially involved anatomic regions, and the CTV-P2 included the CTV-P1 according to the description proposed by Lapeyre et al. [11] For the International guidelines, the delineation followed the guidelines proposed by Gregoire et al., namely applying a 5 + 5 mm expansion of the GTV with adaptations for air cavities, complex head and neck anatomy, and anatomic barriers.

The nodal-CTV delineation and the Organs at Risk (OAR) were delimited using international guidelines [3,4].

### 2.3. CT planning, treatment planning and evaluation

For the planning CT, patients were in supine position and immobilized using a five fixations thermoplastic mask fixed to the base plate. Two or 3 mm tick contrast-enhanced CT scans were acquired from the base of skull to the sterno-clavicular joints.

Contouring and Volumetric Modulated Arc Radiotherapy (VMAT) plans were performed using MONACO version 5.11. PTV of the various CTVs were generated using a 4 mm expansion trimmed by 2 mm from the skin surface. Treatments plans were realized using VMAT with two arcs in 6 MeV photons from Elekta VERSA HD linear accelerator. For each case, and for the two different methods of contouring, the same physicist performed two treatment plans, one only using the PTV-P1 and PTV-P2, then a second plan considering the combined PTV-P1, PTV-P2 and the PTV-N. Dose calculation were performed using a MONTE CARLO algorithm. The prescribed dose was 70 Gy in 35 fractions of 2 Gy for the high-risk tumor volume, and 54.25 Gy in 35 fractions of 1.55 Gy/fr for the low-risk tumor volume and for the prophylactic nodal volume. The planning goal was to achieve homogeneous dose distributions in the various PTVs, complying with the ICRU-83 recommendation, i.e. at least 90% of the dose to 99% of the PTV, at least 95% of the



**Fig. 1.** Design of the study from delineation to the planning treatment. GTV-P: Primary Gross Tumor Volume; CTV-P: Primary Clinical Target Volume; CTV-N: Nodal Clinical Target Volume; PTV-P: Primary Clinical Target Volume; PTV-N: Nodal Planning Target Volume; DVH: Dose Volume Histogram.

dose to 95% of the PTV and no more than 5% of the PTV receiving more than 107% of the dose. For OARs, the following typical constraints were used: near maximal dose ( $D_{2\%}$ ) to the PRV spinal cord <35 Gy,  $D_2$  to the PRV brainstem <25 Gy, mean dose ( $D_{\text{mean}}$ ) to the parotid gland <25 Gy,  $D_{\text{mean}}$  to the submandibular gland <40 Gy,  $D_{\text{mean}}$  to the pharyngeal constrictor muscles (PCM) <35 Gy,  $D_{\text{mean}}$  to the oral cavity <25 Gy,  $D_{\text{mean}}$  to the trachea <50 Gy, and  $D_{\text{mean}}$  to the esophagus <30 Gy.

To compare dose distribution between the two delineation guidelines, the following metrics were used: Homogeneity Index ( $HI = (D_{2\%} - D_{98\%})/D_{50\%}$ ),  $D_{\text{mean}}$ ,  $D_{95\%}$ ,  $D_{90\%}$ ,  $D_{50\%}$ ,  $D_{107\%}$  of the prescribed doses and the volume of isodoses receiving 95% and 50% of the two prescription dose levels, i.e.  $V_{66.5 \text{ Gy}}$ ,  $V_{51.5 \text{ Gy}}$ ,  $V_{35 \text{ Gy}}$ ,  $V_{27.1 \text{ Gy}}$ . For the OAR, differences in dose distribution were evaluated by the  $D_{\text{mean}}$  at PCM, both parotids, both submandibular glands, the oral cavity, the esophagus, as well as by the  $D_{2\%}$  of the PRV spinal cord, PRV brainstem, mandibula and esophagus. The consistency in contouring was evaluated by the DICE Similarity Coefficient (DSC) calculated by P2E (Aquilab SAS) Software. This measure of overlap was defined by this formula  $2|V_1 \cap V_2|/|V_1| + |V_2|$  where  $V_1$  represents the contours from the French guidelines,  $V_2$  the contours from the International guidelines and “ $\cap$ ” the intersection.

The design of the study from the delineation to the dose distribution is displayed in Fig. 1.

### 3. Results

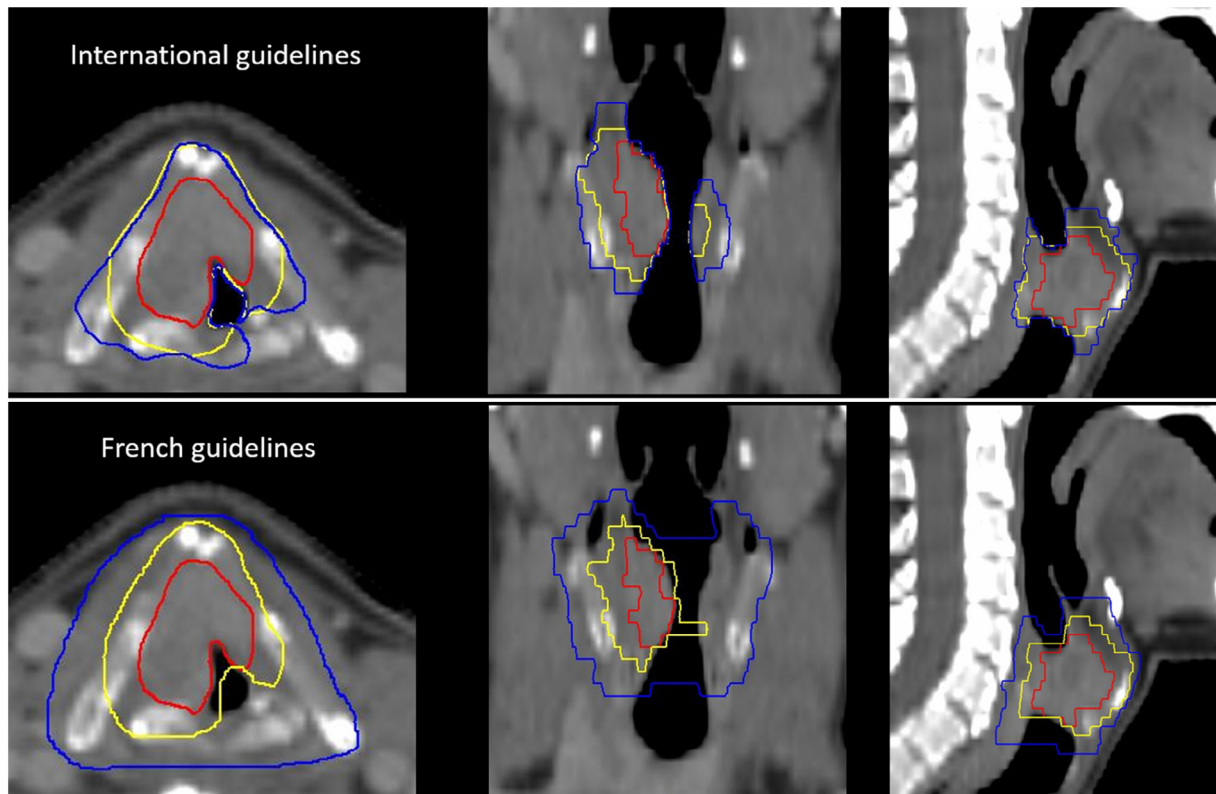
#### 3.1. Comparison of the primary tumor CTV delineation

For the first patient, the delineation of the high dose CTV (CTV-P1) was quite similar between the 2 delineation methods (Fig. 2, Table 1 and Appendix A). Both radiation oncologists included the left and right para-glottic space, the left and right aulla of the thyroid cartilages, the right arytenoid, the mucosal extension, and they both excluded the strap muscles, the contralateral arytenoid, and the hyoid bone. Part of the cricoid cartilage and the pre-epiglottic space were included in the 5 mm expansion. For the low dose CTV (CTV-P2), according to the French guidelines, the air cavities, the strap muscles, a part of the hyoid bone, the cricoid cartilage, the contralateral arytenoid, the 2 piriform sinuses, the

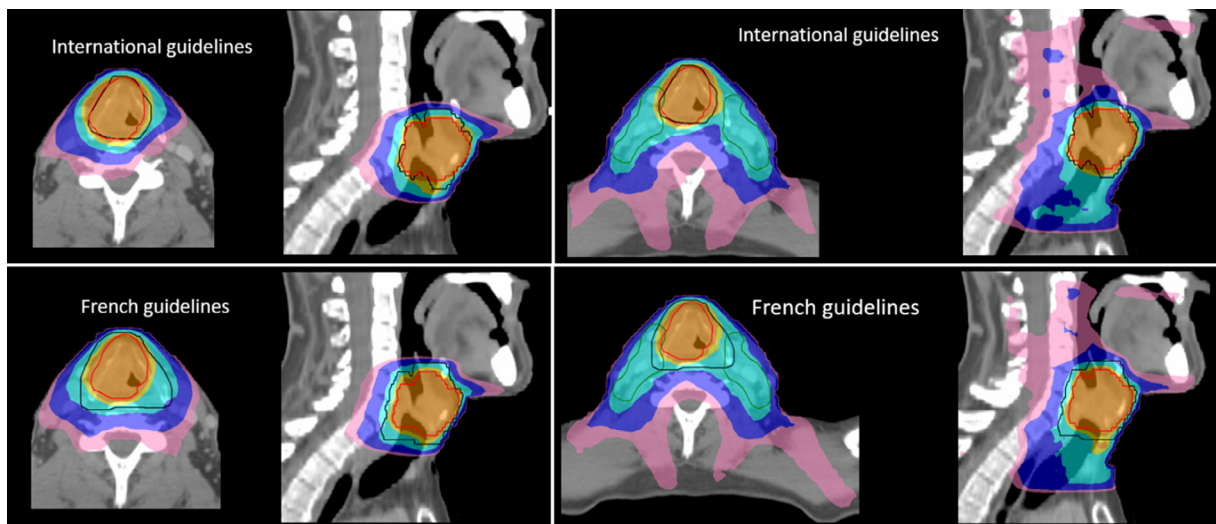
retrocricoid areas, and a part of the 2 valleculae were included. According to the International guidelines, the CTV-P2 was a 10 mm expansion of the GTV-P with corrections for the air cavities, the vertebral body, the strap muscles, the piriform sinus, the retrocricoid region and the contralateral arytenoid. Consequently, the hence delineated volume was more than half the volume delineated according to the French guidelines.

For the second patient, delineations of the CTV-P1 were also similar. Both radiation oncologists included in their expansion the totality of the right vocal cord, the homolateral glottic space, the homolateral arytenoid cartilage and the mucosa. The right aulla of the thyroid cartilage and the cricoid cartilage were also included in the French guidelines but excluded in the International guidelines. The delineation of the low dose CTV for the French guidelines included the air cavities, the two vocal cords as well as the anterior commissure, the contralateral glottic space, the pre-epiglottic space, the cricoid cartilage, the contralateral arytenoid cartilage, the hypopharyngeal and retrocricoid regions, and a part of the 2 valleculae except the strap muscles. The International guidelines included in the low dose CTV the right vocal cord up to the anterior commissure, the mucosa, the cricoid cartilage, the right aulla of the thyroid cartilage and the glottic space, the right arytenoid and excluded the air cavities, the strap muscles and the retrocricoid region. Thus, the volume of the low-risk CTV was nearly 5 times larger for the French guidelines (Table 1, Appendices B and C).

For the third patient, only subtle differences were observed between the 2 delineation guidelines for the delineation of the high-risk CTV. The 2 guidelines included the paraglottic spaces, the thyroid cartilage, the epiglottis, the homolateral arytenoid, the pre-glottic space. In the French guidelines, the radiation oncologist included in his expansion, a part of the strap muscle, the piriform sinus, the cricoid cartilage. For the CTV-P2 delineation, the two radiation oncologists included the two glottic spaces, the thyroid cartilages, the pre-glottic space, the epiglottis, the homolateral arytenoid. But in the French guidelines, the radiation oncologist also included the strap muscles, the hyoid bone, a part of the tonsil, the cricoid cartilage, the arytenoid cartilages, the retrocricoid and hypopharyngeal regions, the 2 valleculae and the air cavities. Major difference was thus seen in low dose delineation with a volume almost 4 times larger for the French guidelines (Table 1, Appendix D).



**Fig. 2.** Planning CT on axial (left), coronal (middle) and sagittal (right) reconstructions for the 1st patient. The GTV is delimited in red, the CTV-P1 in yellow and the CTV-P2 in blue. Delineations were done according to the International guidelines (upper row) or the French guidelines (lower row). (For interpretation of the references to colour in this figure legend, the reader is referred to the web version of this article.)



**Fig. 3.** Comparison of dose distributions for the 1st patient. CTV were delineated according the International guidelines (upper row) or the French guidelines (lower row). Dose planning was done using only the primary tumor target volumes (left panels) or both the primary tumor and the nodal volumes (right panels). The PTV-P1, PTV-P2 and PTV-N are delineated in red, black and green, respectively; the 95% isodose, 90% isodose, 50% isodose of the high-dose (70 Gy) are represented in orange, yellow and blue, respectively. The 95%, and the 50% isodose of the low prescribed dose (54.25 Gy) are represented in turquoise and pink, respectively. (For interpretation of the references to colour in this figure legend, the reader is referred to the web version of this article.)

For the fourth case, the delineations were similar between the 2 guidelines for the high dose CTV and largely different for the low-risk CTV. The 2 radiation oncologists included in their high dose CTV the paraglottic spaces, the thyroid cartilage, the pre-glottic space, the laryngeal mucosa, a part of thyroid cartilage and the homolateral arytenoid. In the CTV-P2, the

International guidelines didn't include the two valleculae, the piriform sinus, the retrocricoid region, the hyoid bone, the strap muscles, and the contralateral arytenoid. Consequently, the volume of the low-risk CTV of the French guidelines was 3 times larger than in the international guidelines (Table 1, Appendix E).

**Table 1**

Comparison between CTV-P1 and CTV-P2 for the 4 patients. The ratio is the CTV delineated according to the French guidelines divided by the CTV delineated according to the International guidelines; in CTV-P2, a major difference between the two radiation oncologists with a mean ratio of  $3.23 \pm 1.06$  was observed. DICE Similarity Coefficient is the measurement of overlap volumes.

	CTV-P1 (cm <sup>3</sup> )				CTV-P2 (cm <sup>3</sup> )			
	International Guidelines	French Guidelines	Ratio	DICE Coefficient	International Guidelines	French Guidelines	Ratio	DICE Coefficient
Case 1	19.61	19.38	0.99	0.91	28.97	66.79	2.31	0.60
Case 2	3.94	5.05	1.28	0.81	11.34	53.98	4.76	0.35
Case 3	17.76	20.22	1.14	0.91	22.93	88.44	3.86	0.41
Case 4	14.00	14.60	1.04	0.94	22.11	66.73	3.02	0.50
Mean			1.07				3.23	
SD			0.13				1.06	

Regarding the conformity of the delineation, for the delineation of the high dose CTV, DICE Similarity Coefficient (DSC) were concordant. But, for the delineation of the low dose CTV, we found a moderate agreement for 2 cases and a weak agreement for the case #2 and case #3 (Table 1).

### 3.2. Comparison of the dose distributions

The dose distribution for the first patient is presented in Fig. 3. The dose distribution for the 3 other patients are presented in the appendices (Appendices F, G, H).

For all patients, the PTV coverage for the 95% and the 90% isodoses fulfilled the constraints, and no difference was observed between the plans generated based on International guidelines or the French guidelines (Appendix I). For the low dose PTV, the dose metrics were higher in the International guidelines likely translating the lower difference in volume between the PTV-P1 and the PTV-P2 in comparison to the French guidelines. The Homogeneity Index (HI) were quite similar between the International and the French guidelines for both the PTV-T-only and the PTV-T + N plans.

Regarding the isodose volume comparison, for the low dose plans, the volumes were systematically larger with the French guidelines at least when looking at the dose distribution restricted to the primary tumor volume. This effect was somehow diluted when both the primary tumor and the node target volumes were used for dose distribution. For the high dose plans, only subtle differences were observed between the International and French guidelines.

The doses to the OARs are reported in Appendix J. The ratio is the ratio of the dose according to the French guidelines on the dose according to the International guidelines. For each plan, dose distribution was performed using the primary tumor volume only and both the primary tumor volume and the nodal CTV. For all OARs, the international guidelines allowed a better sparing of normal tissue, especially for the only planning of the primary tumor volumes. The absolute figures are rather low except for the  $D_{\max}$  of the esophagus which partly overlapped with the primary tumor PTV.

## 4. Discussion

In summary, the comparison between these 2 guidelines indicated 1) major differences for the delineation of the CTV-P2 with air cavities and more surrounding normal tissue included according to the French guidelines, and 2), a rather good consistency for the delineation of the CTV-P1; such differences translated in large differences in dose distribution even when dose planning to

the primary tumor and the lymph nodes were combined. Such results were not attributable to differences in the quality of the VMAT-plans, since the HI were globally similar between the 2 delineation guidelines in all clinical-cases of this study.

Typically, for the low risk CTV (CTV-P2) of laryngeal SCC, the French guidelines recommended the systematic delineation of the suprahoid epiglottis and the hyoid bone, cranially, the cricoid cartilage, the contralateral thyroid aulla and strap muscles (except for the T2 tumor), laterally, and the 2 arytenoids, the piriform sinuses and the retrocricoid regions, posteriorly. It is highly debatable if these structures are at risk for microscopic infiltration in T2 and T3 laryngeal SCC.

Analyzing whole laryngectomy specimens, Kirchner and al. demonstrated that in 52 specimens of glottic cancers (11 with T1 tumors, 15 with T2 tumors, 25 with T3 tumors and one with T4 tumors), only 5 tumors invaded the thyroid aulla. Four of these tumors were associated with subglottic extension of 1 cm or more, and the other tumor showed upward extension into the ventricle, displacing the intact ventricular band and eroding the thyroid cartilage in its mid-portion. The inner perichondrium of the thyroid cartilage presents an effective barrier to cancer spread into the cartilage, and the fascia of the strap muscles further prevent extension into these muscles. In supraglottic cancer, no invasion of the thyroid aulla was observed even for T3 and T4 lesions, and even for those with extensive involvement of the pre-epiglottic space. The hyoid bone was never involved, even in cases of the most extreme invasion of the pre-epiglottic space. In subglottic cancer, the cricoid cartilage was sometimes invaded by tumors with large subglottic components with infiltration through the crico-thyroid membrane. In transglottic cancer, a tumor size higher than 2 cm was associated with infiltration of the laryngeal framework [14]. The hyo-epiglottic ligament (HL) serves as the roof of both the para-glottic and pre-epiglottic spaces and separates the supraglottic larynx from the valleculae. In 70 laryngectomies performed in case of supraglottic cancer, Zeitel and Kirchner demonstrated that HL is a resilient connective tissue barrier to prevent cranial infiltration to the valleculae and the tongue base, and no infiltration was observed without synchronous erosion of the suprahoid epiglottis or the pharyngo-epiglottic fold [15]. These histopathological data clearly suggest that the French guidelines for the delineation of the low risk CTV of laryngeal tumors unduly include too much normal tissue harboring very low risk or no risk at all for tumor dissemination, at least for the T2 and T3 tumors. In addition to the anatomic and histo-pathological data mentioned above, evidences have also been reported that tumor cells invade surrounding normal tissues with a probability that decreases with the distance from the edge of the GTV [16–18]. In this framework and in absence of a unique model quantifying the probability of

tumor cell infiltration with the distance from the GTV edge, the use of 2 adjacent rims of 5 mm of normal tissue around the GTV with 2 different dose prescription appears quite logical, as proposed by the International guidelines.

In support of this proposal, the recent study of Zukauskaite using GTV to different CTV margins in 3 Danish centers, showed that recurrences mainly appeared within the GTV, and no relationship between the rate of local relapse and the extend of margin used could be demonstrated. The few recurrences occurring outside of the CTV were within the 95% isodose attesting that radioresistance was likely a better explanation for those failures than sub-optimal target volume delineation or dose distribution [12,19,20].

It should be emphasized that a proper delineation of the GTV is a paramount requirement for proper delineation of the CTV. This require information from endoscopy under general anesthesia, fiberoptic examination to be performed by the treating radiation oncologist, and various diagnostic imaging modalities. It also requires that the treating radiation oncologist matures the complex head and neck anatomy, and consequently it thus illustrates that proper management of head and neck tumors be performed in reference centers to maximize adequate tumor outcome [21].

When one looked at dose distribution after VMAT planning, the difference between the two delineation guidelines decreased when both the primary tumor PTV and the nodal PTV were combined. This observation does not rule out the importance of proper target volume delineation, as in the future the likely use of different radiation beam quality such as protons, may further increase dose conformality and make target volume delineation an even more crucial step in patient management [22].

Finally, we should also mention that inter-observer variability between observers for target volume delineation have been reported to be substantially decreased by the use of a well-defined set of geometric guidelines [13]. Considering the potential consequences for outcome of variability in target volume delineation, this further emphasizes on the importance of using soundly defined guidelines for target volume delineation [1,2]. Such inter-observer variability study has never been reported for the French guidelines.

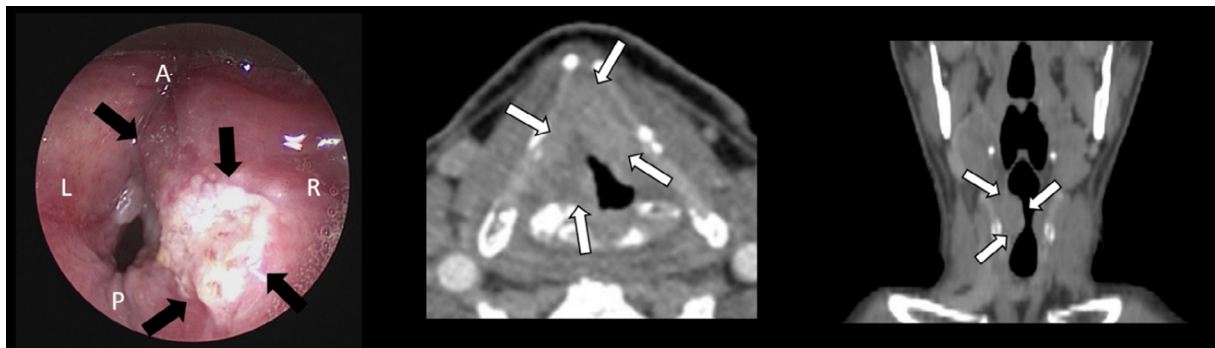
## 5. Conclusion

The delineation of target volume in H&N tumors is a complex process requiring a comprehensive knowledge in anatomy and in the pathways involved in tumor spread. The challenge of this process is to avoid a too tight volume delineation that could be associated to an unacceptable rate of local recurrence, and a too large volume, which could be associated to an unacceptable rate of treatment morbidity. In this framework, the data reported in the present study, although only concerning 4 typical cases, do suggest that an optimal compromise could be obtained by the use of the International guidelines for primary tumor delineation.

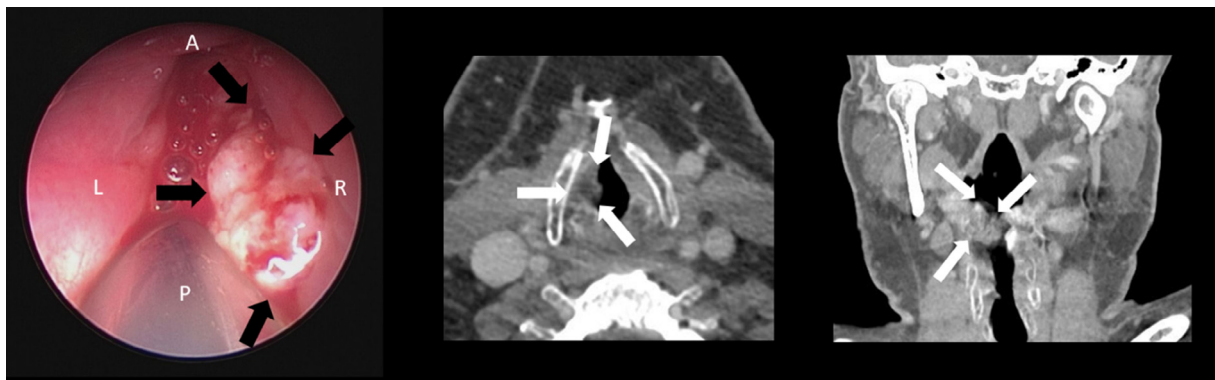## Declaration of Competing Interest

None.

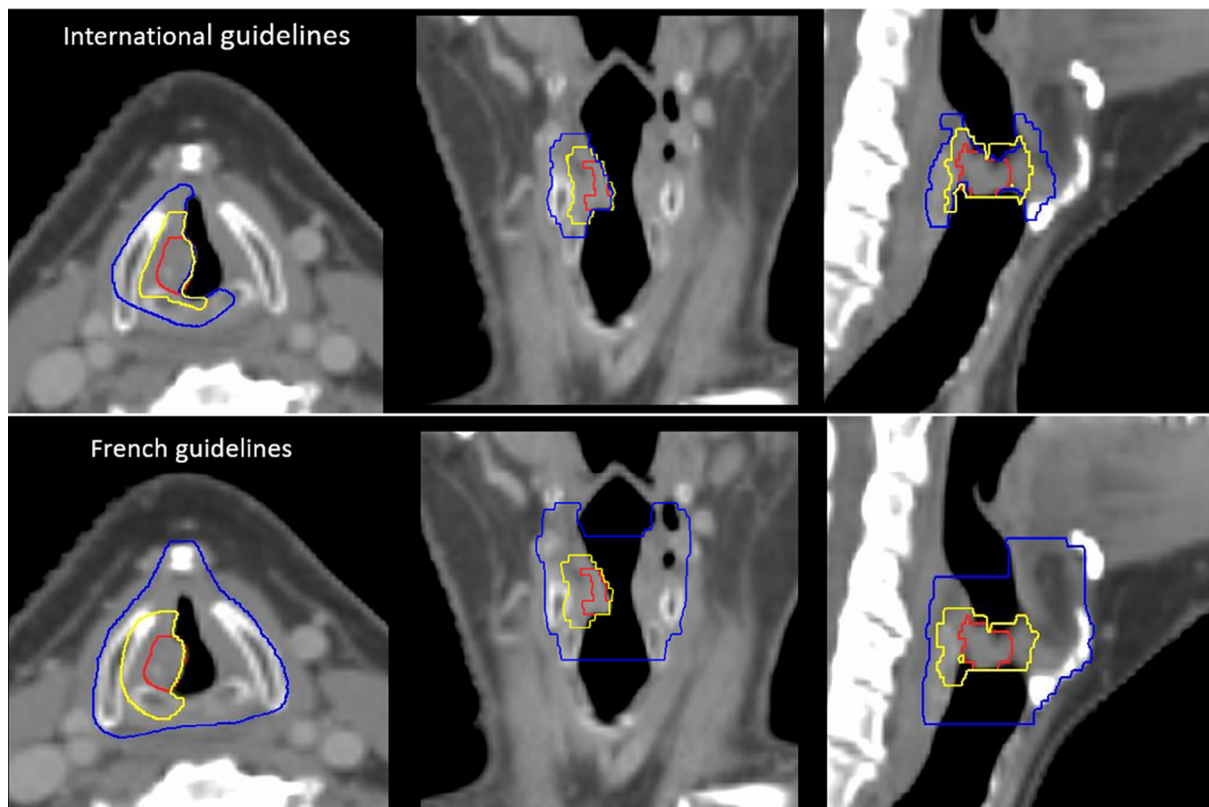
## Figures of Appendix



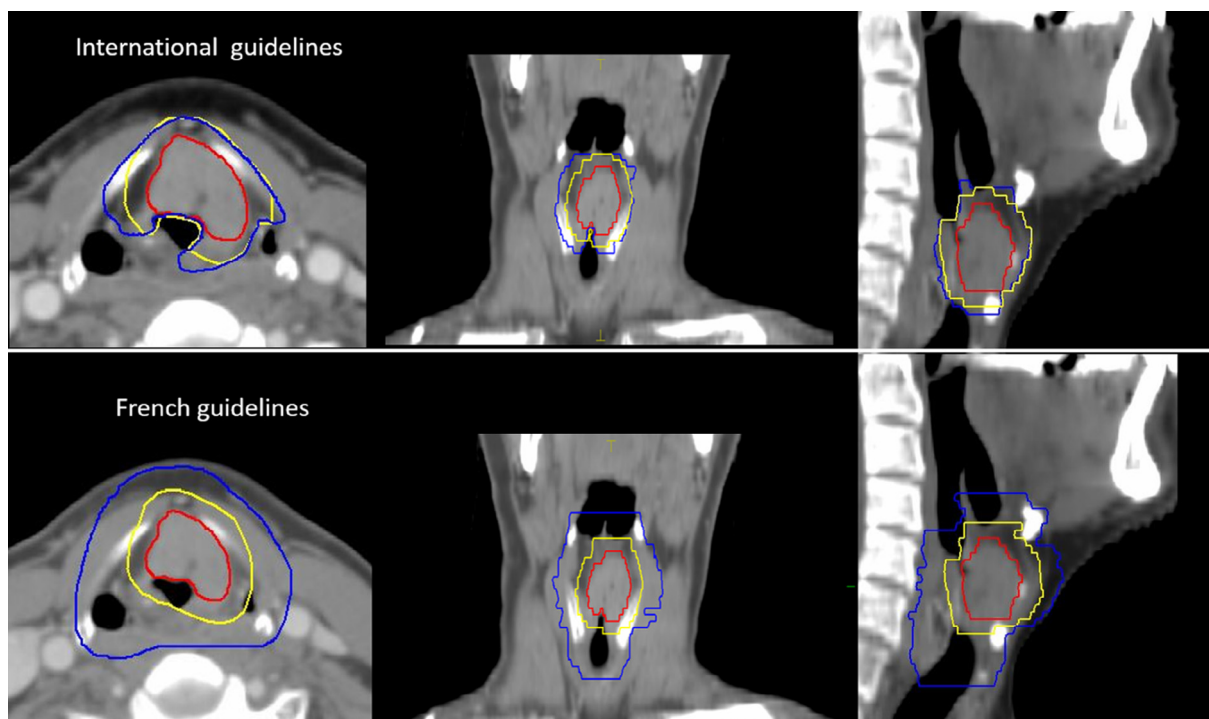
**Appendix A.** Endoscopic view (left), and diagnostic CT on axial and coronal (middle, right) reconstructions of the 1st patient. The arrows represent the tumor's infiltration. The letters A mean anterior, P posterior, R right and L left directions, respectively.



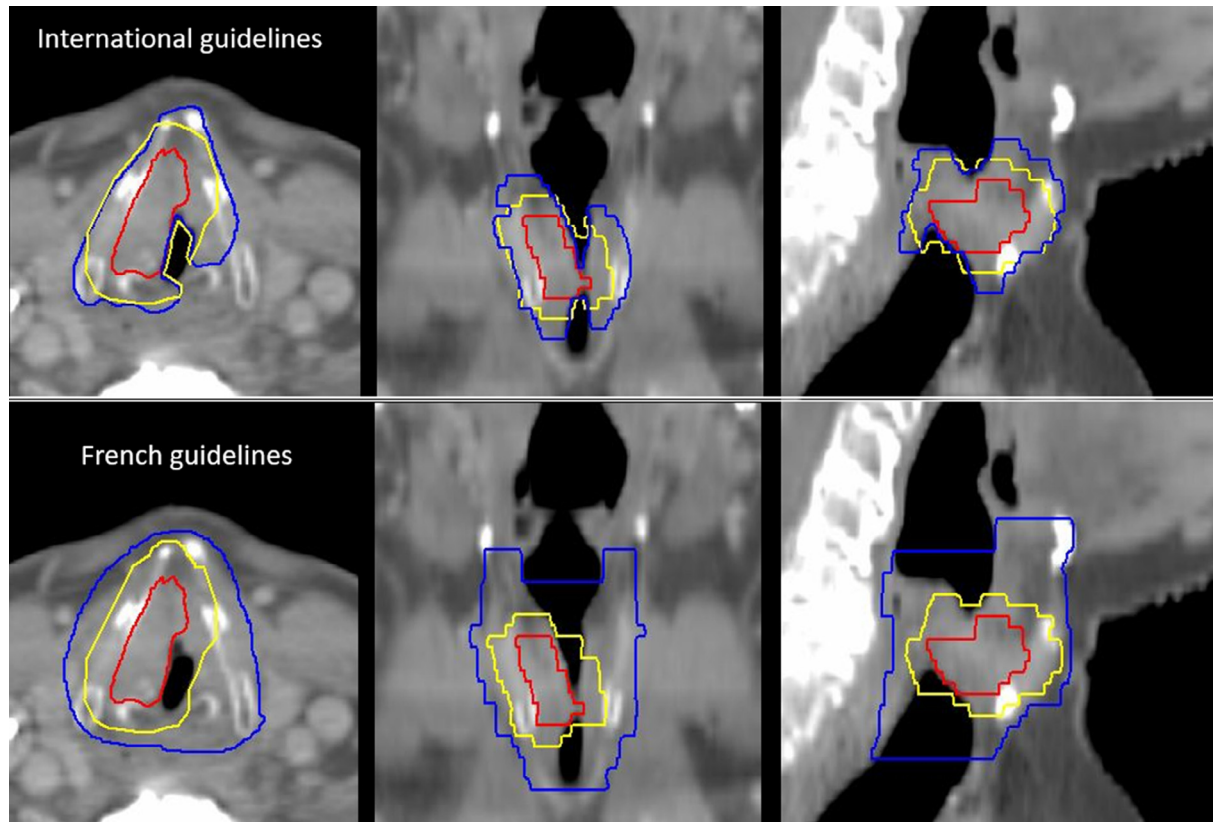
**Appendix B.** Endoscopic view (left) and axial, coronal diagnostic CT (middle, right) of the 2nd patient. The arrows represent the infiltration of the tumor. The letters A mean anterior, P posterior, R right and L left directions, respectively.



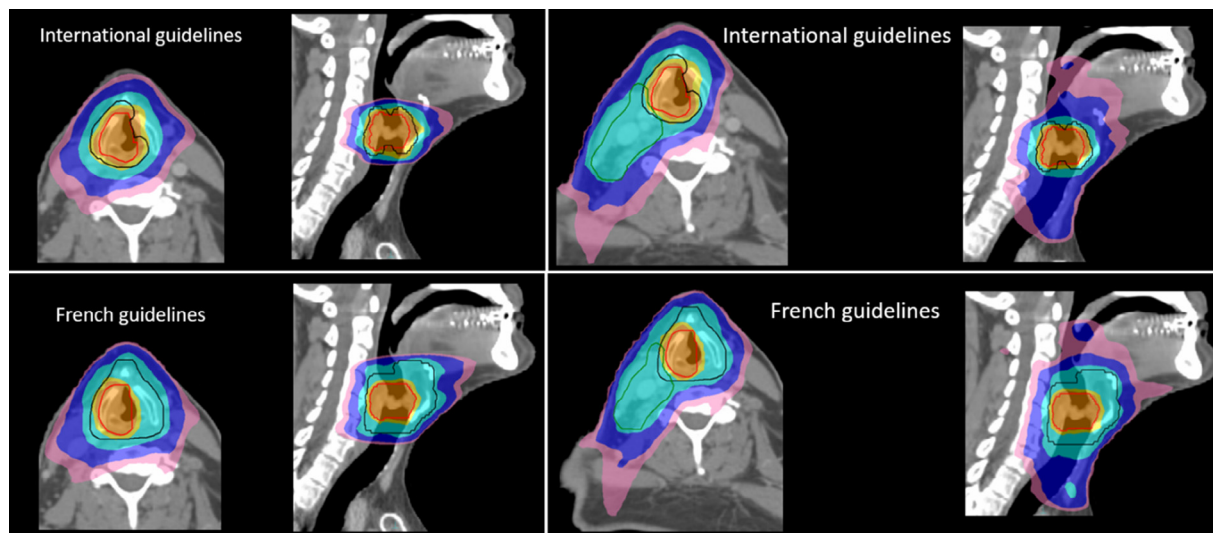
**Appendix C.** Planning CT on axial (left), coronal (middle) and sagittal (right) reconstructions for the 2nd patient. The GTV is delimited in red, the CTV-P1 in yellow and the CTV-P2 in blue. Delineations were done according to the International guidelines (upper row) or the French guidelines (lower row). (For interpretation of the references to colour in this figure legend, the reader is referred to the web version of this article.)



**Appendix D.** Planning CT on axial (left), coronal (middle) and sagittal (right) reconstructions for the 3rd patient. The GTV is delimited in red, the CTV-P1 in yellow and the CTV-P2 in blue. Delineations were done according to the International guidelines (upper row) or the French guidelines (lower row). (For interpretation of the references to colour in this figure legend, the reader is referred to the web version of this article.)

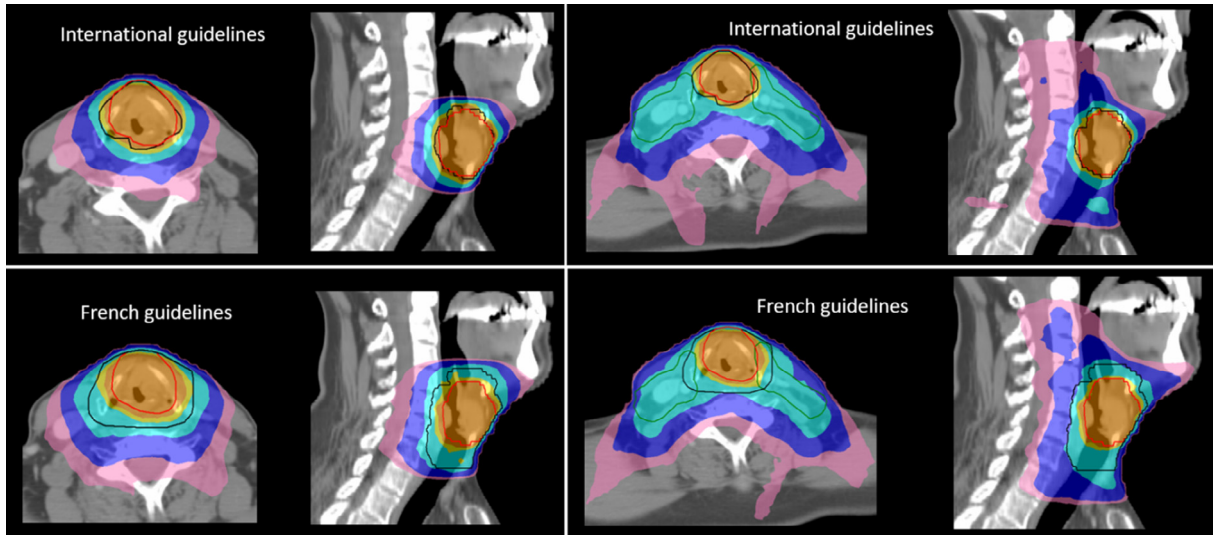


**Appendix E.** Planning CT on axial (left), coronal (middle) and sagittal (right) reconstructions for the 4th patient. The GTV is delimited in red, the CTV-P1 in yellow and the CTV-P2 in blue. Delineations were done according to the International guidelines (upper row) or the French guidelines (lower row). (For interpretation of the references to colour in this figure legend, the reader is referred to the web version of this article.)

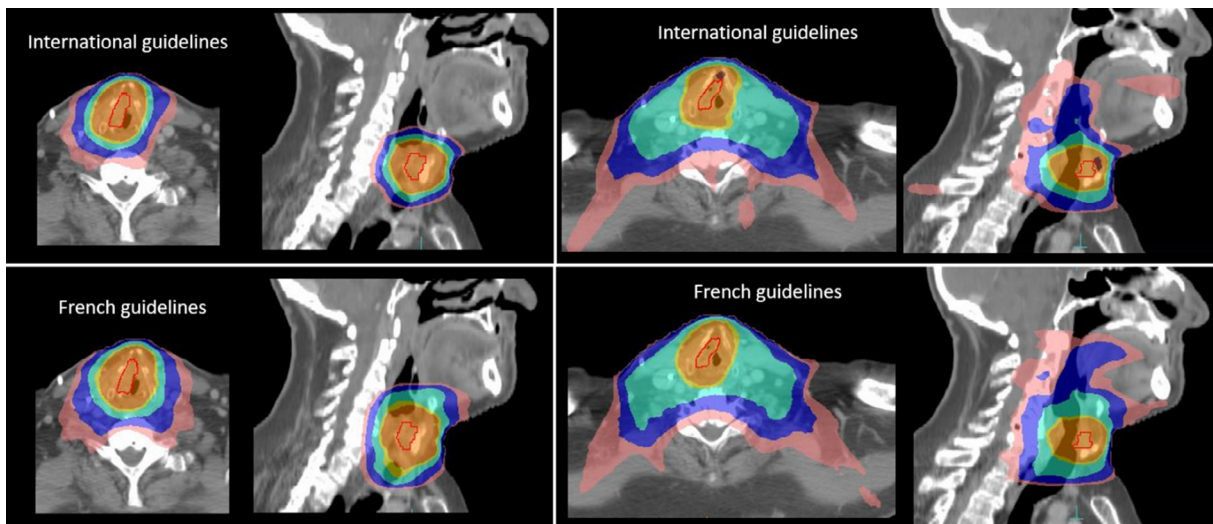


**Appendix F.** Comparison of dose distributions for the 2nd patient. CTV were delineated according the International guidelines (upper row) or the French guidelines (lower row). Dose planning was done using only the primary tumor target volumes (left panels) or both the primary tumor and the nodal volumes (right panels). The PTV-P1, PTV-P2 and PTV-N are delineated in red, black and green, respectively; the 95% isodose, 90% isodose, 50% isodose of the high-dose (70 Gy) are represented in orange, yellow and blue, respectively. The 95%, and the 50% isodose of the low prescribed dose (54.25 Gy) are represented in turquoise and pink, respectively. (For interpretation of the references to colour in this figure legend, the reader is referred to the web version of this article.)





**Appendix G.** Comparison of dose distributions for the 3rd patient. CTV were delineated according the International guidelines (upper row) or the French guidelines (lower row). Dose planning was done using only the primary tumor target volumes (left panels) or both the primary tumor and the nodal volumes (right panels). The PTV-P1, PTV-P2 and PTV-N are delineated in red, black and green, respectively; the 95% isodose, 90% isodose, 50% isodose of the high-dose (70 Gy) are represented in orange, yellow and blue, respectively. The 95% and the 50% isodose of the low prescribed dose (54.25 Gy) are represented in turquoise and pink, respectively. (For interpretation of the references to colour in this figure legend, the reader is referred to the web version of this article.)



**Appendix H.** Comparison of dose distributions for the 4th patient. CTV were delineated according the International guidelines (upper row) or the French guidelines (lower row). Dose planning was done using only the primary tumor target volumes (left panels) or both the primary tumor and the nodal volumes (right panels). The PTV-P1, PTV-P2 and PTV-N are delineated in red, black and green, respectively; the 95% isodose, 90% isodose, 50% isodose of the high-dose (70 Gy) are represented in orange, yellow and blue, respectively. The 95% and the 50% isodose of the low prescribed dose (54.25 Gy) are represented in turquoise and pink, respectively. (For interpretation of the references to colour in this figure legend, the reader is referred to the web version of this article.)

## Appendix Tables

## Appendix I

Comparison between PTV dose coverage, volumes of the 95% and 50% isodose of the high and low dose prescriptions, and Homogeneity index (HI).

	Case 1				Case 2				Case 3				Case 4			
	T Dosimetry		T + N Dosimetry		T Dosimetry		T + N Dosimetry		T Dosimetry		T + N Dosimetry		T Dosimetry		T + N Dosimetry	
	Int. Guidelines	Fr. Guidelines	Int. Guidelines	Fr. Guidelines	Int. Guidelines	Fr. Guidelines	Int. Guidelines	Fr. Guidelines	Int. Guidelines	Fr. Guidelines	Int. Guidelines	Fr. Guidelines	Int. Guidelines	Fr. Guidelines	Int. Guidelines	Fr. Guidelines
PTV: parameters																
<i>High dose</i>																
Dmean (Gy)	70.5	70.6	70.3	70.0	70.0	70.0	70.6	70.6	70.1	70.3	69.9	70.5	70.4	70.1	70.3	70.0
D95% (Gy)	68.3	68.2	68.3	68.0	68.5	67.5	67.8	67.8	68.3	68.1	67.8	67.6	68.1	68.3	67.7	68.0
D90% (Gy)	69.0	69.0	68.9	68.6	68.8	68.1	68.5	68.4	68.9	68.8	68.5	68.5	68.9	68.7	68.4	68.6
D107% (Gy)	0	0	0	0	0	0	0.34	0	0	0	0	0	0	0	0.3	0
D50% (Gy)	70.6	70.9	70.4	70.1	70	70.2	70.5	70.7	70.2	70.4	70.1	70.8	70.5	70.1	70.4	70.1
<i>Low dose</i>																
D95% (Gy)	59.8	53.7	52.6	52.6	61.3	53.8	53.5	53.6	64.7	55.9	52.6	52.7	59.9	54.0	55.4	53.8
D90% (Gy)	62.9	55.0	53.6	53.6	63.3	54.5	54.3	54.0	66.4	57.2	53.3	53.5	62.4	55.4	56.7	54.7
D50% (Gy)	70.1	65.5	55.8	56.2	68.7	58.0	56.6	55.9	70.0	64.2	56.9	56.3	70.5	65.5	62.0	62.1
Volume of isodose																
<i>High dose</i>																
V66.5 Gy (cm <sup>3</sup> )	54	53	56	54	26	20	21	20	53	56	47	50	41	52	40	43
V51.5 Gy (cm <sup>3</sup> )	116	154	632	644	76	138	370	454	112	229	601	653	84	155	556	576
<i>Low dose</i>																
V35 Gy (cm <sup>3</sup> )	194	283	1308	1299	149	270	704	826	197	398	1335	1368	151	299	1094	1116
V27.1 Gy (cm <sup>3</sup> )	271	384	1943	1951	208	372	1023	1168	285	572	1921	1892	215	438	1622	1673
Homogeneity index																
<i>High dose</i>																
	0.07	0.07	0.07	0.07	0.09	0.07	0.10	0.09	0.06	0.07	0.07	0.09	0.08	0.06	0.09	0.07
<i>Low dose</i>																
	0.24	0.30	0.35	0.35	0.28	0.32	0.34	0.33	0.30	0.26	0.34	0.36	0.22	0.29	0.21	0.25

## Appendix J

Dose distribution in the OARs for each patient according to the International and the French guidelines.

	T Dosimetry			T+N Dosimetry			T Dosimetry			T + N Dosimetry					
	Int. Guidelines	Fr. Guidelines	Ratio	Int. Guidelines	Fr. Guidelines	Ratio	Int. Guidelines	Fr. Guidelines	Ratio	Int. Guidelines	Fr. Guidelines	Ratio			
	Guidelines	Guidelines		Guidelines	Guidelines		Guidelines	Guidelines		Guidelines	Guidelines				
<i>D<sub>mean</sub> R parotid (Gy)</i>															
Case 1	0.5	0.6	1.2	25.1	26.3	1.05	<i>D<sub>mean</sub> PCM (Gy)</i>			15.3	19.4	1.27	42.3	47.1	1.11
Case 2	0.3	0.6	2.0	13.5	14.6	1.08	Case 2			14.3	22.7	1.59	29.3	35.3	1.20
Case 3	0.3	0.6	2.0	13.4	18.7	0.96	Case 3			22.1	27.7	1.25	43.8	45.8	1.05
Case 4	0.3	0.6	2.0	24.1	26.1	1.08	Case 4			15.4	24.2	1.57	48.3	49.3	1.02
mean.			<b>1.71</b>			<b>1.04</b>	mean.					<b>1.40</b>			<b>1.08</b>
SD			0.40			0.06	SD					0.18			0.08
<i>D<sub>mean</sub> L parotid (Gy)</i>															
Case1	0.5	0.5	1.0	24.6	25.0	1.02	<i>D<sub>mean</sub> esophagus (Gy)</i>			3.8	4.3	1.13	17.2	16.6	0.97
Case 2	0.3	0.6	2.0	3.4	5.0	1.47	Case 2			1.5	5.3	3.53	8.3	12.7	1.53
Case 3	0.3	0.6	2.0	17.6	17.8	1.01	Case 3			3.3	12.8	3.88	19.1	22.0	1.15
Case 4	0.3	0.7	2.33	23.2	25.2	1.09	Case 4			7.3	18.2	2.49	17.6	26.5	1.51
mean.			<b>1.71</b>			<b>1.06</b>	mean.					<b>2.55</b>			<b>1.25</b>
SD			0.58			0.22	SD					1.23			0.28
<i>D<sub>mean</sub> R submandibular (Gy)</i>															
Case1	13.8	17.5	1.27	53.8	52.8	0.98	<i>D<sub>2%</sub> esophagus (Gy)</i>			40.0	48	1.20	51.9	52.2	1.01
Case 2	6.8	17.1	2.51	46.2	53.2	1.15	Case 2			15.5	14.9	0.96	21.2	54.6	2.58
Case 3	20.9	37.5	1.79	49.1	49.9	1.02	Case 3			29.6	56	1.89	45.6	54.7	1.20
Case 4	4.3	16.1	3.74	38.8	38.2	0.98	Case 4			26.9	53.5	1.99	47.6	54.9	1.15
mean.			<b>1.93</b>			<b>1.03</b>	mean.					<b>1.54</b>			<b>1.30</b>
SD			1.07			0.08	SD					0.51			0.73
<i>D<sub>mean</sub> L submandibular (Gy)</i>															
Case1	11.3	19.3	1.71	52.5	53.7	1.02	<i>D<sub>2%</sub> mandibula (Gy)</i>			20.6	24.5	1.19	48.7	46.4	0.95
Case 2	3.5	10.6	3.03	14.7	25.9	1.76	Case 2			2.7	20.8	7.70	41	41.7	1.02
Case 3	7.8	15.4	1.97	50.3	51.0	1.01	Case 3			13.1	28.30	2.19	48.2	49.1	1.02
Case 4	2.2	6.0	2.73	44.9	39.5	0.88	Case 4			15.4	15.4	1.00	35.6	39.8	1.12
mean.			<b>2.07</b>			<b>1.05</b>	mean.					<b>1.72</b>			<b>1.02</b>
SD			0.62			0.40	SD					3.17			0.07
<i>D<sub>mean</sub> oral cavity (Gy)</i>															
Case1	3.3	4.6	1.39	24.7	26.7	1.08	<i>D<sub>2%</sub> PRV Spinal Cord (Gy)</i>			29.6	29.6	1.00	34.7	33,60	0.97
Case 2	0.6	2.8	4.67	17.9	18.3	1.02	Case 2			22.1	23.3	1.05	25.0	25.7	1.03

## Appendix J (continued)

	T Dosimetry			T+N Dosimetry			Case 3	T Dosimetry			T + N Dosimetry		
	Int. Guidelines	Fr. Guidelines	Ratio	Int. Guidelines	Fr. Guidelines	Ratio		Int. Guidelines	Fr. Guidelines	Ratio	Int. Guidelines	Fr. Guidelines	Ratio
Case 3	2.3	7.8	3.39	21.7	24.8	1.14	Case 3	28.4	35.0	1.23	34.6	36.0	1.04
Case 4	0.6	0.2	0.33	28.3	30.7	1.08	Case 4	17.2	17.7	1.03	31.4	32.00	1.02
mean.			<b>2.26</b>			<b>1.09</b>	mean.			<b>1.09</b>			<b>1.01</b>
SD			1.95			0.05	SD			0.10			0.03

## Appendix A. Supplementary data

Supplementary data to this article can be found online at <https://doi.org/10.1016/j.ctro.2019.06.003>.

## References

- [1] Hong TS, Tome WA, Chappell RJ, Harari PM. Variations in target delineation for head and neck IMRT: an international multi-institutional study. *Int J Radiat Oncol* 2004;60(1):S157–8.
- [2] Vinod SK, Jameson MG, Min M, Holloway LC. Uncertainties in volume delineation in radiation oncology: a systematic review and recommendations for future studies. *Radiother Oncol* 2016;121(2):169–79.
- [3] Brouwer CL et al. CT-based delineation of organs at risk in the head and neck region: DAHANCA, EORTC, GORTEC, HKNPCSG, NCIC CTG, NCRI, NRG Oncology and TROG consensus guidelines. *Radiother Oncol* 2015;117(1):83–90.
- [4] Grégoire V et al. CT-based delineation of lymph node levels and related CTVs in the node-negative neck: DAHANCA, EORTC, GORTEC, NCIC, RTOG consensus guidelines. *Radiother Oncol J Eur Soc Ther Radiol Oncol* 2003;69(3):227–36.
- [5] Grégoire V et al. Delineation of the neck node levels for head and neck tumors: a 2013 update. DAHANCA, EORTC, HKNPCSG, NCIC CTG, NCRI, RTOG, TROG consensus guidelines. *Radiother Oncol* 2014;110(1):172–81.
- [6] Grégoire V et al. Delineation of the primary tumour Clinical Target Volumes (CTV-P) in laryngeal, hypopharyngeal, oropharyngeal and oral cavity squamous cell carcinoma: AIRO, CACA, DAHANCA, EORTC, GEORCC, GORTEC, HKNPCSG, HNCIG, IAG-KHT, LPRHHT, NCIC CTG, NCRI, NRG Oncology, PHNS, SBRT, SOMERA, SRO, SSHNO, TROG consensus guidelines. *Radiother Oncol* 2018;126(1):3–24.
- [7] Eisbruch A, Foote RL, O'Sullivan B, Beitler JJ, Vikram B. Intensity-modulated radiation therapy for head and neck cancer: emphasis on the selection and delineation of the targets. *Semin Radiat Oncol* 2002;12(3):238–49.
- [8] Grégoire V, Daisne J-F, Geets X, Levendag P. Selection and delineation of target volumes in head and neck tumors: beyond ICRU definition. *Rays* 2003;28(3):217–24.
- [9] Lapeyre M et al. Propositions for the selection and the delineation of peritumoral microscopic disease volumes in oral cavity and oropharyngeal cancers (lymph nodes excluded). *Cancer Radiother J Soc Francaise Radiother Oncol* 2005;9(4):261–70.
- [10] Lapeyre M, Loos G, Biau J. Delineation for oral cavity and oropharyngeal cancers. *Cancer Radiother J Soc Francaise Radiother Oncol* 2013;17(5–6):493–7.
- [11] Lapeyre M, Bailly C, Toledano I, Montalban A, Russier M. Cancer de l'hypopharynx et du larynx : proposition de sélection et délimitation des volumes cibles microscopiques péri-tumoraux (aires ganglionnaires exclues). *Cancer/Radiothérapie* 2010;14:S43–51.
- [12] Zukauskaitė R et al. Local recurrences after curative IMRT for HNSCC: effect of different GTV to high-dose CTV margins. *Radiother Oncol* 2018;126(1):48–55.
- [13] Hansen CR et al. Consequences of introducing geometric GTV to CTV margin expansion in DAHANCA contouring guidelines for head and neck radiotherapy. *Radiother Oncol* 2018;126(1):43–7.
- [14] Kirchner JA. Two hundred laryngeal cancers: patterns of growth and spread as seen in serial section. *Laryngoscope* 1977;86(4):474–82.
- [15] Zeitels SM, Kirchner JA. Hyoepiglottic ligament in supraglottic cancer. *Ann Otol Rhinol Laryngol* 1995;104(10):770–5.
- [16] Campbell S et al. Evaluation of microscopic disease in oral tongue cancer using whole-mount histopathologic techniques: implications for the management of head-and-neck cancers. *Int J Radiat Oncol* 2012;82(2):574–81.
- [17] Yuen PW, Lam KY, Chan AC, Wei WI, Lam LK. Clinicopathological analysis of local spread of carcinoma of the tongue. *Am J Surg* 1998;175(3):242–4.
- [18] Fleury B et al. Approche anatomopathologique de l'extension microscopique des carcinomes épidermoïdes ORL: implications pour la définition du volume cible anatomoclinique. *Cancer/Radiothérapie* Nov. 2014;18(7):666–71.
- [19] Raktoe SAS, Dehnad H, Raaijmakers CPJ, Braunius W, Terhaard CHJ. Origin of tumor recurrence after intensity modulated radiation therapy for oropharyngeal squamous cell carcinoma. *Int J Radiat Oncol* 2013;85(1):136–41.
- [20] De Felice F, Thomas C, Barrington S, Pathmanathan A, Lei M, Urbano TG. Analysis of loco-regional failures in head and neck cancer after radical radiation therapy. *Oral Oncol* 2015;51(11):1051–5.
- [21] Sharma A, Schwartz SM, Méndez E. Hospital volume is associated with survival but not multimodality therapy in Medicare patients with advanced head and neck cancer: Hospital Volume in Head and Neck Cancer. *Cancer* 2013;119(10):1845–52.
- [22] Blanchard P, Frank SJ. Place de la protonthérapie en cancérologie ORL. *Cancer/Radiothérapie* 2017;21(6–7):515–20.