

# Lateral malleolus hook plate for comminuted Weber A and B fractures: A retrospective study

Fang Zhenhua, Hazibullah Waizy<sup>1</sup>, Xie Ming, Kan Wusheng

## ABSTRACT

**Background:** The goal of managing the comminuted fracture of lateral malleolus is to restore length, rotation and alignment which might be more challenging with extensive comminution around the area of the distal tip. The common osteosynthesis techniques such as the one-third tubular plate, tension band wiring, K-wires, screws, or intramedullary nail may be insufficient in cases with a comminuted lateral malleolus. The anatomical hook plate is an alternative implant in such cases. We present our results of the comminuted lateral malleolar fractures (Weber A, B), managed by open reduction and internal fixation (ORIF) with an anatomical hook plate of lateral malleolus (Königsee Implant Company, Germany).

**Materials and Methods:** We retrospectively reviewed 20 patients of comminuted fracture of distal lateral malleolus between 2008 and 2010. There were 12 males and 8 females, right side was involved in 18 patients and left in 2. The mean age was 51.9 years (range 18-75 years). The fractures were categorized by Denis-Weber classification type A (n=1), B1 (n=1), B2 (n=13) and B3 (n=5). Nineteen cases were of closed injury and one of open injury (Gustilo Anderson type II). These patients underwent ORIF with a lateral malleolus anatomical hook plate. Followup including radiographs and clinical examinations were performed. The American Orthopedic Foot and Ankle Society (AOFAS) ankle hindfoot scores were documented at followups.

**Results:** The mean followup was 21.4 months (range 16-27 months). The average AOFAS score was 94.3 (range 78-100) points. A stable anatomic reduction and bony union were obtained in all the cases. The average time was 3.1 months (range 2.5-4 months). Four cases had complications like posttraumatic osteoarthritis, hardware impingement and superficial wound infection.

**Conclusion:** A reasonably good stability can be obtained in distal most comminuted fractures of lateral malleolus with a lateral malleolus anatomical hook plate. We believe this method to be a reasonable treatment option for a distal lateral comminuted malleolar fracture when other common fixations are insufficient to fix the fragments.

**Key words:** Lateral malleolus, distal comminuted lateral malleolus fracture, lateral malleolus hook plate

## INTRODUCTION

The goal of managing the comminuted fracture of lateral malleolus is to restore length, rotation and alignment which might be more challenging with extensive comminution around the area of the distal tip.<sup>1-3</sup>

Different techniques are commonly used to address this comminuted fracture, such as K-wires, tension band wires, one-third tubular plate, screws and intramedullary nails.<sup>1,4-10</sup>

There are no operative indications for the majority of Weber A and partial Weber B fracture due to good stability.<sup>1,11</sup> However, when there is distal fibular fracture with shortening, comminution and rotation, involving the talus instability; open reduction and internal fixation (ORIF) is recommended.<sup>1</sup> The lateral malleolar fracture, which exhibits an oblique or spiral pattern is generally stabilized with an infraglenoid screw and is supplemented by a neutralizing tubular plate.<sup>12</sup> Many studies show that a good reduction and bone union could be achieved for displaced unstable fractures by ORIF.<sup>6,7,10,12-14</sup> However, in cases with small distal fragments, the fixations of the distal fragments by screws or other conventional fixations are challenging.<sup>9,15</sup> A one-third tubular plate is also associated with many complications such as fragment nonunion and dislocation for such cases.<sup>7</sup> It is well-accepted that poor fragment stabilization may result in postoperative displacement with a high risk of nonunion or malunion leading to osteoarthritis.<sup>7,11,12</sup>

Department of Foot and Ankle Surgery, WuHan Orthopedic Hospital, WuHan PuAi Hospital Affiliated TongJi Medical College, HuaZhong University of Science and Technology - 430 033 WuHan, China, <sup>1</sup>Department of Orthopedic, Hannover Medical School, Anna-von-Borries-Str. 1-7, 30625 Hannover, Germany

**Address for correspondence:** Dr. Fang Zhenhua, 473, Han Zhengjie, PuAi Hospital Affiliated TongJi Medical College, HuaZhong University of Science and Technology. 430033 WuHan, China.  
E-mail: bone\_ghost@hotmail.com

### Access this article online

#### Quick Response Code:



**Website:**  
www.ijoonline.com

**DOI:**  
10.4103/0019-5413.114918

Generally, complex distal lateral malleolar fractures are difficult to fix by conventional internal fixations, especially for comminuted fractures. As an alternative fixation, a lateral malleolus hook plate has been used in managing the lateral malleolar fractures.<sup>8</sup>

In this retrospective study, we present the clinical and radiological results in managing comminuted fractures of the lateral malleolus (Weber A, B) with a lateral malleolus hook plate (Königsee Implant Company, Thuringen, Germany) [Figure 1].

## MATERIALS AND METHODS

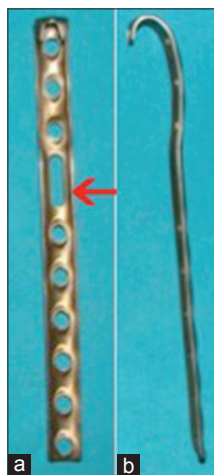
The informed consent was obtained from all the patients to participate in the study at the latest followup. The present study has been approved by ethical committee in our hospital. Inclusion criteria: (i) Unstable fracture (Denis-Weber A, B) which met the indications of ORIF: displacement (or shortening) of the fibula more than 2 mm; (ii) Comminuted fractures (Denis-Weber A, B). The exclusion criteria were: (i) Type C Weber fractures; (ii) simple lateral malleolar fracture including linear and transverse/oblique fracture.

There were 12 male and 8 females, right side was involved in 18 patients and left in 2. The mean age was 51.9 years (range 18-75 years). All the fractures were categorized by Denis-Weber classification type A (n=1), B1 (n=1), B2 (n=13) and B3 (n=5). Nineteen cases were close injury and one was open injury (Gustilo Anderson type II) combined with ankle dislocation and medial deltoid ligament rupture. The patient who suffered open injury was managed by a staged protocol. The first stage comprised of the thorough debridement and bone distraction to restore the alignment

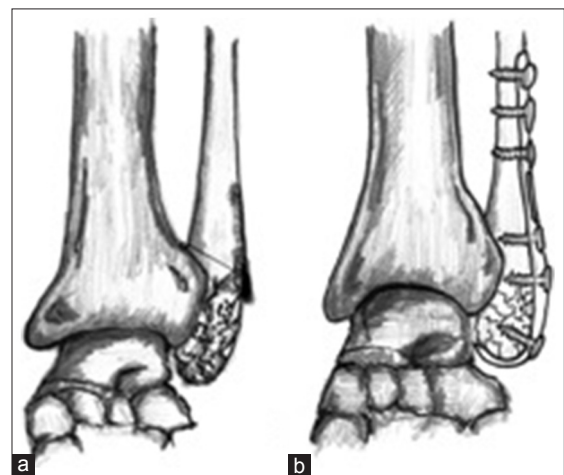
of the ankle joint. In the second stage (15 days after initial injury), the ORIF was finished after excluding an infection. The causes of injury consisted of vehicular trauma (n=14) and high energy falls (n=6). There were nine cases which had osteoporosis [Singh's Index grade I (n=1), grade II (n=3) grade III (n=5)], one case combined the osteochondral lesion of talar, five cases with syndesmosis injury. Five cases had syndesmotomic injury. One case had associated osteochondral lesion.

Initial computerized tomography (CT) was performed for all the comminuted cases. The period from injury to ORIF ranged from 5 h to 16 days. The operation time was determined by surgeons according to the local state of the skin (swelling, blister). All patients were operated by same surgeon (FZ).

We used a longitudinal lateral approach to manage the lateral malleolar fracture under spinal anesthesia. In 18 cases, a separate medial incision was used for ORIF wherein a medial malleolar fracture was involved. All procedures including the management of the medial malleolar and posterior malleolar fractures were done according to AO rules.<sup>1</sup> The distal cancellous bone screws need to be short of the medial side of the fibula to avoid damage to the lateral talar articular surface [Figure 2]. The fixation of the plate may be done with 3.5-mm cortical screws, but with a 2.7-mm drill for better screw hold. We fixed the plate in the anterior two-third area of distal fibula to avoid impingement between the plate and peroneal tendons [Figure 3]. For the syndesmotomic diastasis cases, we used one or two 3.5 mm cortical screws placed between 2 and 5 cm above the ankle joint space in the neutral position. The screws were removed prior to full weight-bearing. There is no obvious anatomical marker



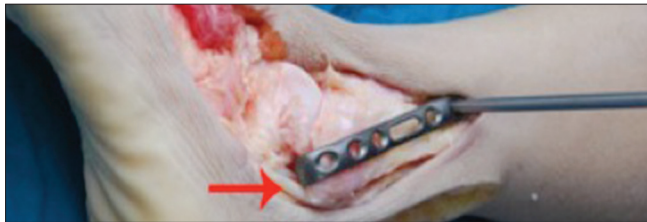
**Figure 1:** Clinical photograph (a) The anteroposterior and (b) lateral appearances of a lateral malleolus anatomical hook plate (Königsee Implant Company, Thuringen, Germany) showing the distal hooks, one sliding hole (the red arrow) and a valgus angle of plate



**Figure 2:** The line diagram showing (a) preoperative distal comminuted fibular fragments which are tiny to fix by common fixations and (b) postoperative successful fixation achieved by means of special hook design

to contribute to fracture reduction in managing the distal comminuted lateral malleolus fracture; we restore the fibular length by means of adjusting the sliding screw position in the sliding hole. Fluoroscopy was used to verify the reduction of comminuted fractures. Good reduction was defined as fibula shortening  $\leq 2$  mm and a posterior displacement of less than 2 mm. The fair reduction represented a fibular shortening, a posterior displacement of 2-4 mm and 1-3 mm increase in the medial space. A poor reduction was defined as posterior displacement of above 4 mm and a fibula shortening in excess of 2 mm.<sup>1</sup>

A short leg cast was applied postoperatively until wound healing. Active and passive rehabilitation was recommended strongly after operation. Gradual weight-bearing was started at 4 weeks and advanced as tolerated. Full weight-bearing was permitted when bony union was evident radiographically.



**Figure 3:** The arrow shows the relative relation between the peroneal longus tendon and plate in a fresh cadaveric specimen who illustrates the ideal position of the plate and should not close the tendon to avoid the impingement between the plate and tendons

All patients were evaluated through clinicroadiologically. The radiographs of ankles were taken in both anteroposterior (AP) and lateral views [Figure 4]. Radiographic healing was characterized as evidence of bridging callus across the fracture sites or the obliteration of the fracture lines on both AP and lateral radiographs.

## RESULTS

The average union time was 3.1 months (range 2.5-4 months). The average AOFAS ankle-hindfoot score was 94.3 (range 78-100 points) points at the latest followup [Table 1]. The radiographic examination [Table 2] showed minor signs of osteoarthritis in one case with a trimalleolar fracture. The patient was pain free at clinical examination without formation of ectopic bone in the joint within our 24 months' followup. Meanwhile, the function and alignment of the ankle were normal. Three patients (15%) complained of symptomatic hardware which was removed. Another patient presented with impingement between the hook ankle plate and the peroneus longus tendon [Table 3]. The patient complained of mild pain in the ankle when he moved his ankle, which was resolved spontaneously by rest. In this patient, X-rays taken at followup showed the plate with minor signs of too inferior and posterior. We removed the plate 6 months after operation and the pain disappeared when he moved his ankle at the postoperative second day, with 95 points (AOFAS) at the latest followup. There was no nonunion, malunion, or fracture dislocation. Wound necrosis did not occur in all patients. One

**Table 1: The essential clinical parameters and postoperative AOFAS scores**

Patient number	Age (years)/gender	Followup (months)	Weber type	Open or closed injury	Syndesmotic injury	Combined special injury	The interval from injury to operation	AOFAS score (postoperative)
1	31/M	27	B3	Close	Yes	No	5 days	97
2	67/M	18	B2	Close	No	No	<6 h	94
3	48/M	22	B2	Close	No	No	<6 h	99
4	63/F	21	B3	Close	Yes	Osteochondral lesion of talus	<6 h	78
5	57/M	21	B2	Close	No	No	7 days	89
6	55/F	24	A	Close	No	No	<6 h	98
7	75/F	24	B2	Close	No	No	8 days	95
8	39/M	18	B2	Close	Yes	No	<6 h	99
9	18/F	22	B2	Close	No	No	<6 h	99
10	36/M	16	B2	Close	No	No	<6 h	98
11	46/M	21	B3	Close	No	No	<6 h	97
12	34/F	26	B2	Open	No	Dislocation of ankle	15 days	80
13	72/M	24	B2	Close	Yes	No	<6 h	95
14	68/F	22	B3	Close	Yes	No	7 days	97
15	52/M	18	B1	Close	No	No	<6 h	100
16	53/F	19	B2	Close	No	No	<6 h	99
17	42/M	24	B2	Close	Yes	No	<6 h	98
18	69/M	21	B3	Close	No	No	5 days	86
19	37/M	24	B2	Close	No	No	<6 h	98
20	75/F	18	B2	Close	No	No	<6 h	96

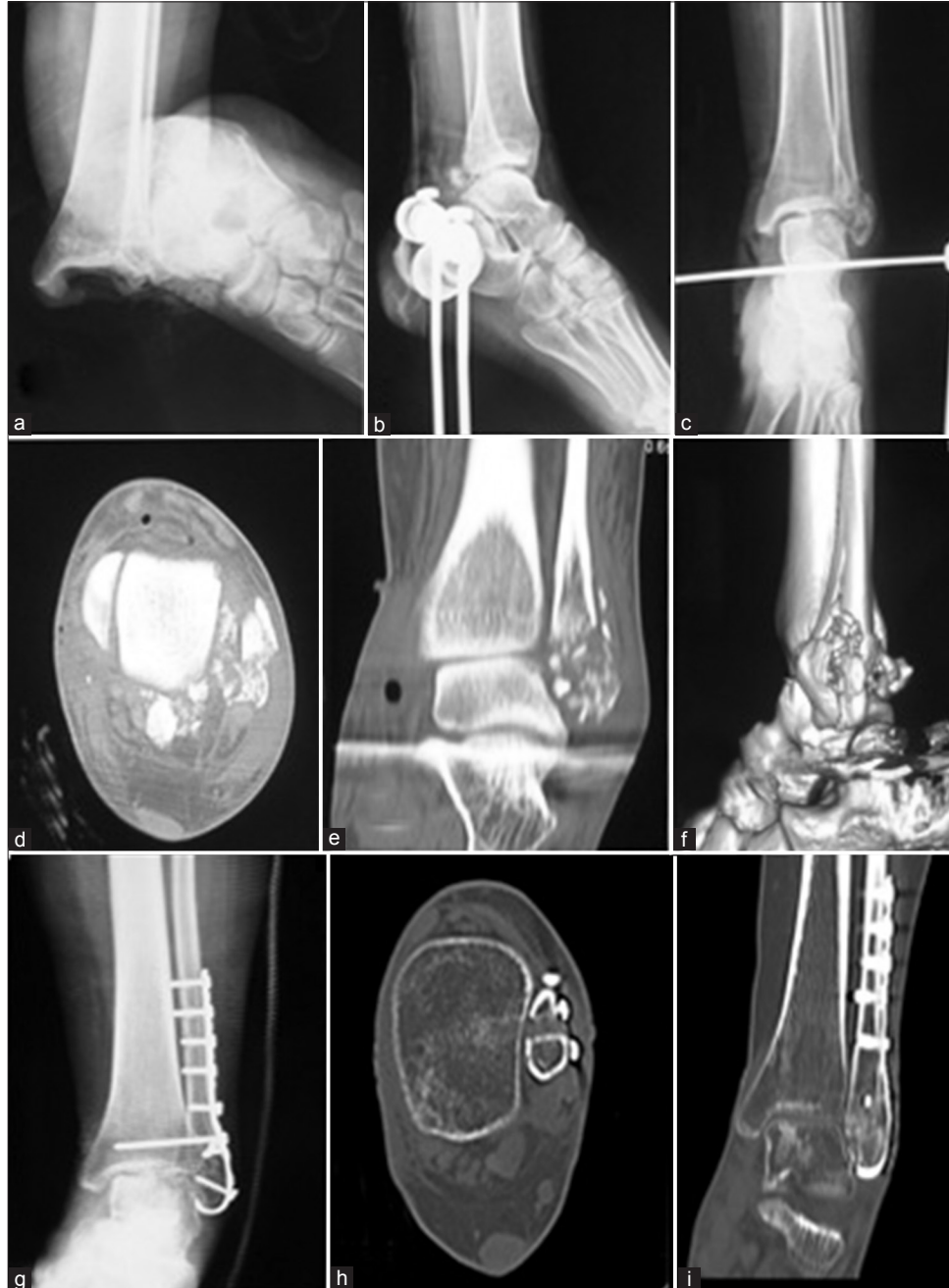AOFAS=American orthopedic foot and ankle society

patient had a superficial infection, after 5 days of treatment with oral antibiotics, the wound healed uneventfully. In one patient, the trans syndesmotomic screw broke 2 months after full weight-bearing owing to patient's poor compliance.

## DISCUSSION

The previous study showed the initial 1 mm lateral

displacement of the talus or 3° external rotation of the distal fibula resulted in 42% reduction in the tibiotalar contact area and increased stress would lead to ankle arthritis.<sup>16</sup> The exact restoration of anatomic structure with adequate length and rotation of the distal fibula are prerequisites for a good functional result in managing ankle fracture.<sup>1,3</sup> An efficient fixation is essential for fusion and early rehabilitation. In cases with tiny fragments the



**Figure 4:** A 34-year-old patient (No. 12) suffered comminuted fracture of left lateral malleolus associated with deltoid ligament rupture and open dislocation. (a) Preoperative X-ray ankle joint anteroposterior view showing the dislocation of ankle (b) lateral and (c) anteroposterior views after reduction showing comminuted distal lateral malleolar fracture (d) Preoperative CT including transection, (e) coronal section, (f) three dimensional reconstruction showing fragments of the distal lateral malleolar fractures (g) Postoperative X-ray of anteroposterior view showing good reduction and rigid fixation had been achieved through the hook plate. (h) Postoperative CT including transection, (i) coronal section showing bone union at 16 weeks, accompanying anatomical reconstruction of the articular surface



**Table 2: Radiological parameters**

Postoperative radiological parameters	Result (normal/abnormal)	Number of patients
Joint space	Normal	19
	Abnormal	1
Fibular shortening	Normal	20
	Abnormal	0
Valgus angle of joint space	Normal	20
	Abnormal	0
Talar tilt	Normal	19
	Abnormal	1
Syndesmosis	Normal	19
	Abnormal	1

**Table 3: Complications**

Complications	Number of patients
Wound infection (superficial or deep)	1 (superficial)
Soft tissue damage (skin graft or the flap required)	0
Fracture dislocation	0
Loosening of the internal fixation	1
Impingement between the plate and tendon	1
Delayed union of bone	0
Malunion	0
Nonunion of bone	0
Traumatic arthritis	1
Nerve injury	0
Thrombosis	0

fixation is challenging. The common fixations (K-wires, tension band wires, one-third tubular plate, screws and intramedullary nails) are insufficient to fix fragments in those patients. When the distance from fracture level to distal tip of fibula is less than 2 cm then a plate cannot be fixed effectively.<sup>8</sup> Our results showed that good anatomical reduction and effective fixation could be achieved by means of the lateral malleolus hook plate in cases with tiny distal fragments. The advantages of the lateral malleolar hook plate are given in literatures. There is a special hook design that can successfully fix comminuted fragments of distal fibular fracture.<sup>8</sup> For the distal comminuted fibula fracture, the one-third tubular plate has many risks with higher postoperative loosening rate especially for the distal screw, leading to the comminuted fragment dislocation postoperatively.<sup>15</sup> The hook plate achieved multi-plane fixations attributing to the distal special hook design.<sup>8</sup> A study shows that two sharp hooks are helpful for improving anti-torsion properties, preventing distal screw loosening and maintaining the reduction effect during the period of healing which reduce the possibility of displacement which is effective to increase the fixing force of distal fracture fragment.<sup>8</sup> Hook plates meet the demand of distal lateral fibular anatomical reconstruction owing to the plate's valgus angle (10-15°), which can prevent narrowing of the ankle joint space resulting in

limiting the activities of the talus.<sup>8</sup> There is a sliding hole in the plate, which contributed to restoration of the length of the fibula in cases with comminuted fracture. In cases with a shortening of the distal fibula Gerber *et al.*,<sup>17</sup> recommended to fix the plate to the distal fibula firstly to adjust the length before fixing the plate to the proximal fibula. This can be achieved by using distraction against a proximal shaft screw (push-pull screw). There is no obvious anatomical marker to contribute to fracture reduction in managing the distal comminuted lateral malleolar fracture, we can restore the fibular length effectively by means of adjusting the sliding screw position in the sliding hole.

Due to the design of hook plate, impingement between the plate and peroneal tendon may occur resulting in the peroneal tendonitis. In our series we had one case with impingement between plate and peroneal tendons. Typically, the patient complained of pain in the lateral ankle and aggravation when the ankle was moving. We removed the internal fixation at postoperative 6 months. The symptoms disappeared immediately after the second operation. The plate may irritate peroneal tendons which was reported in previewed literature in terms of the application of an "anti-glide" plate to the fibula in a dorsal approach.<sup>14</sup> The position of the plate is crucial. There is possible damage to peroneal tendons if the plate is placed too close to the peroneal tendons. Although the hook plate has biomechanical advantages in lateral malleolar fracture, we emphasize that it is recommended only for the distal lateral comminuted malleolar fracture due to its possible irritation with peroneal tendons.

Soft tissue problems are common in these procedures and are reported in up to 22% of cases.<sup>15,18</sup> In present study, one case (5%) had superficial infection which recovered uneventfully after administering oral antibiotics. Ideally ORIF should be accomplished as quickly as possible (<6 h). After this period, the swelling becomes too tense and the operation has to be planned after the swelling has subsided.<sup>1</sup> Meanwhile, less soft tissue dissection may reduce wound complication in the procedure of operation.<sup>18</sup> Diabetes, dementia, peripheral vascular disease and smoking were also found to be statistically significant risk factors associated with wound complication.<sup>15</sup> Our patients underwent operation at less than 6 h after injury or above 5 days, after clinical reduction of the swelling. We concluded that the operation time was critical according to the evaluation of local skin condition, which attributed to minimizing the wound complication risks.

Injuries of the superficial peroneal nerve may result directly from the procedure of ORIF. Neubauer *et al.*,<sup>19</sup> reported that

there was a great risk in managing distal fibular fracture with plate longer than six holes, associated with a longitudinal incision, midway between the anterior and posterior margins of the distal fibular. In present study, there was no nerve injury. We believe that a shorter plate could contribute to reducing the incidence of this damage.

Lee *et al.*,<sup>7</sup> documented the symptomatic hardware problems that existed in 45.5% patients in the plate group for treating lateral malleolar fractures, meanwhile, 95.5% patients asked to remove the hardware. Brown *et al.*,<sup>20</sup> reported 31% patients had lateral pain overlying their fracture hardware and nearly 50% continued to have pain even after hardware removal. In our study, only three patients (15%) required removal due to palpable hardware. The reason may be related to our small sample size.

This study has several limitations. Firstly, it is a retrospective study with a short-term followup. Secondly, the present study lacked a comparative group, such as patients managed with different implants. We only compared our results with relevant literatures. Thirdly, owing to the limited number of cases, we could not demonstrate the absolute clinical advantage of the lateral malleolus anatomical hook plate.

To conclude, the lateral malleolus anatomical hook plate is a reasonable alternative fixation option in managing comminuted fractures of lateral malleolus.

## REFERENCES

1. Sutter PM, Peltzer J. Principles of operative treatment of malleolar fractures today. *Eur J Trauma Emerg Surg* 2010;36:505-14.
2. Gougoulas N, Khanna A, Sakellariou A, Maffulli N. Supination-external rotation ankle fractures: Stability a key issue. *Clin Orthop Relat Res* 2009;468:243-51.
3. Lloyd J, Elsayed S, Hariharan K, Tanaka H. Revisiting the concept of talar shift in ankle fractures. *Foot Ankle Int* 2006;27:793-6.
4. Tambe A, Swami K, Murali S, Browne A. A new technique for fixing unstable Weber B fractures of the ankle: Evaluation of outcome, in the elderly and those with poor skin envelope. *Foot Ankle Surg* 2004;10:169-76.
5. Bajwa AS, Gantz DE. Cerclage wire and lag screw fixation of the lateral malleolus in supination and external rotation fractures of the ankle. *J Foot Ankle Surg* 2005;44:271-5.
6. McKenna PB, O'Shea K, Burke T. Less is more: Lag screw only fixation of lateral malleolar fractures. *Int Orthop* 2007;31:497-502.
7. Lee YS, Chen SW. Lateral fixation of open AO type-B2 ankle fractures: The Knowles pin versus plate. *Int Orthop* 2009;33:1135-9.
8. Sun T, Wang D, Zhou Z, Yu R. Biomechanical analysis of lateral malleolus's anatomical hook-plate for fixation of Weber A-type ankle fracture. *Zhongguo Xiu Fu Chong Jian Wai Ke Za Zhi* 2008;22:824-7.
9. Tornetta P3<sup>rd</sup>, Creevy W. Lag screw only fixation of the lateral malleolus. *J Orthop Trauma* 2001;15:119-21.
10. Fernandez GN. Internal fixation of the oblique, osteoporotic fracture of the lateral malleolus. *Injury* 1988;19:257-8.
11. Joy G, Patzakis MJ, Harvey JP Jr. Precise evaluation of the reduction of severe ankle fractures. *J Bone Joint Surg Am* 1974;56:979-93.
12. Yablon IG, Heller FG, Shouse L. The key role of the lateral malleolus in displaced fractures of the ankle. *J Bone Joint Surg Am* 1977;59:169-73.
13. Lee YS, Chen SH, Lin JC, Chen YO, Huang CR, Cheng CY. Surgical treatment of distal tibia fractures: A comparison of medial and lateral plating. *Orthopedics* 2009;32:163.
14. Lamontagne J, Blachut PA, Broekhuysen HM, O'Brien PJ, Meek RN. Surgical treatment of a displaced lateral malleolus fracture: The antiglide technique versus lateral plate fixation. *J Orthop Trauma* 2002;16:498-502.
15. SooHoo NF, Krenek L, Eagan MJ, Gurbani B, Ko CY, Zingmond DS. Complication rates following open reduction and internal fixation of ankle fractures. *J Bone Joint Surg Am* 2009;91:1042-9.
16. Ramsey PL, Hamilton W. Changes in tibiotalar area of contact caused by lateral talar shift. *J Bone Joint Surg Am* 1976;58:356-7.
17. Gerber C, Mast JW, Ganz R. Biological internal fixation of fractures. *Arch Orthop Trauma Surg* 1990;109:295-303.
18. Lynde MJ, Sautter T, Hamilton GA, Schuberth JM. Complications after open reduction and internal fixation of ankle fractures in the elderly. *Foot Ankle Surg* 2012;18:103-7.
19. Neubauer T, Heidari N, Weinberg AM, Grechenig W, Tesch NP, Pichler W, *et al.* The risk of nerve injury with minimally invasive plate osteosynthesis of distal fibula fractures: An anatomic study. *Arch Orthop Trauma Surg* 2011;131:1409-12.
20. Brown OL, Dirschl DR, Obrebsky WT. Incidence of hardware-related pain and its effect on functional outcomes after open reduction and internal fixation of ankle fractures. *J Orthop Trauma* 2001;15:271-4.

**How to cite this article:** Zhenhua F, Waizy H, Ming X, Wusheng K. Lateral malleolus hook plate for comminuted Weber A and B fractures: A retrospective study. *Indian J Orthop* 2013;47:364-9.

**Source of Support:** Nil, **Conflict of Interest:** Each author certifies that he or she has no commercial associations (e.g., consultancies, stock ownership, equity interest, patent/licensing arrangements, et al) that might pose a conflict of interest in connection with the submitted article.