



Importance of Diameter of Long Process of Incus in Stapedotomy-New Findings From In Vivo Study

Veluswamy Anand¹ Aiswarya Anand¹  Sridurga Janarthanan¹ Sebina Francis¹

¹Department of ENT, MCV ENT CLINIC, Tamil Nadu, India

Address for correspondence Aiswarya Anand, MBBS., DLO., M.S, MCV ENT Centre, Coimbatore, Tamil Nadu, 642001, India (e-mail: anand@entanand.com).

Int Arch Otorhinolaryngol 2023;27(3):e385–e392.

Abstract

Introduction Stapes surgery for otosclerosis is a precise surgical procedure. To achieve excellent hearing results, a firm and stable attachment of the prosthesis to the long process of incus (LPI) is necessary. The present study provides details on the attachment site in two dimensions to choose an appropriate prosthesis and to ensure firm attachment for better surgical outcomes.

Objective To study the diameter of the LPI and its relevance in determining the piston, used in stapes surgery by an in vivo method.

Methods This study was conducted in 41 patients who underwent stapedotomy, where both Anteroposterior (AP) and Mediolateral (ML) diameters of the LPI were measured at the site of attachment of the piston using specially designed instruments, intraoperatively.

Radiological data were obtained to measure the LPI diameter from the normal ears of 46 patients. It was measured from both the right and left side, hence 92 LPI diameters were obtained.

Results The most commonly used site for prosthesis attachment is between 1–1.5 mm away from the tip of the LPI. We found great variability in the diameters of LPI in the attachment site, with the AP diameter ranging between 0.6 -1.5mm and the ML diameter ranging between 0.5mm-1.2 mm.

Conclusion Pistons by design have characteristics of gripping incus that will vary between types. Based on LPI dimensions, ideal piston types with appropriate inner loop diameters are suggested in this study. HRCT before surgery should include measurements of the LPI as a guide to the choice of the prosthesis during surgery.

Keywords

- ▶ Incus
- ▶ Stapedotomy
- ▶ Piston
- ▶ Otosclerosis
- ▶ Prosthesis

Introduction

Stapes surgery for otosclerosis is a precise surgical procedure. To achieve excellent hearing results a firm and stable attachment of the prosthesis to the long process of incus (LPI) is necessary. A loose connection will lead to the absorption of sound energy and consecutively to incomplete resolution of the conductive hearing loss. It could also lead to necrosis of the long process of the incus.¹

To have a firm attachment of the prosthesis on the incus, a surgeon needs to have a detailed information on the three-dimensional anatomy of the incus. Although there are many publications on the macroscopic and histological morphology of the incus, clinical anatomy is poorly mentioned in the literature.²⁻⁴ There are in vitro studies where the incus diameters were measured from cadaver temporal bones. This study to our knowledge is the first in vivo effort. Factors that influence treatment outcome are also discussed.

received
September 7, 2020
accepted after revision
May 17, 2021

DOI <https://doi.org/10.1055/s-0043-1770995>.
ISSN 1809-9777.

© 2023. Fundação Otorrinolaringologia. All rights reserved.
This is an open access article published by Thieme under the terms of the Creative Commons Attribution-NonDerivative-NonCommercial-License, permitting copying and reproduction so long as the original work is given appropriate credit. Contents may not be used for commercial purposes, or adapted, remixed, transformed or built upon. (<https://creativecommons.org/licenses/by-nc-nd/4.0/>)
Thieme Revinter Publicações Ltda., Rua do Matoso 170, Rio de Janeiro, RJ, CEP 20270-135, Brazil

In the present study we got more details on the attachment site parameters in two dimensions to enable us in choosing an appropriate prosthesis and to ensure firm attachment. Pistons by design have characteristics of gripping the incus that will vary between types. It varies between Teflon (Indian audio center, Chandigarh, India and Grace medicals, Memphis, TN, USA), soft clip (KURZ GmbH Medizintechnik, Dusslingen, Germany) and superelastic nitinol (Audio technologies, Piacenza, Italy). The standard Teflon piston has an inner loop diameter of 0.6mm and after expansion many a time will have a loose attachment to a thin incus for e.g.: 0.6 mm diameter.

Incus problems can be seen with almost every type of prosthesis. Incus necrosis is less likely the result of reduction of vascular supply or mucosal disruption due to very tight prosthesis as believed once, but is more likely because of vibratory movements at the prosthesis-incus contact site due to flaccid prosthesis or re-stenosis of the oval window constricting the prosthesis.⁵ Accordingly, optimizing the circumferential fit of the prosthesis may decrease the risk of future incus necrosis. Poor fit could also lead to dys-synchronous movement of the incus and give rise to increase of friction and out of phase movement that can worsen hearing outcomes. This is known as “Loose-wire syndrome.” The characteristic sign is the short-term improvement of the patient’s hearing following the Valsalva maneuver.

Objective

To measure and study the diameter of the long process of incus (LPI) and its relevance in determining the piston, used in stapes surgery by an in vivo method.

Methodology

This was a two-part observational study, done in a tertiary care center. The first part was an in vivo study taking direct measurements of the diameter of the long process of the incus in 41 patients undergoing stapes surgery. The second part was a radiographic study taking measurements of the diameter of the long process of the incus on CT scans of 46 normal patients. The study was conducted after receiving an institutional ethics committee approval.

Informed and written consent were obtained from all patients, who were willing to participate in the study. The study period was from November 2017 to September 2019.

In the first part of the study, both Anteroposterior (AP) (►Fig. 1) and Mediolateral (ML) diameters (►Fig. 2) of the long process of incus were measured. Custom instruments were used to take measurements, intraoperatively. These custom instruments had measuring calipers of 0.6mm, 0.8mm and 1mm. A straight version was used to measure AP diameter and a curved version for the ML diameter (designed by the author specifically for the study). These instruments were designed based on the range of diameters of the incus observed in previous cadaver incudal studies (►Fig. 3a and ►3b). Measurements were taken at the anticipated site of attachment of the piston which is ~1mm away

from the tip of long process of the incus and data were recorded (►Table 1). All surgeries and intraoperative measurements were performed by the same ENT surgeon.

In the second part of the study, high-resolution computed tomography scans (HRCT) of the temporal bones [obtained by Toshiba Alexion multi-slice helical CT] were assessed at three imaging centers. Using the OsirixDicom viewer the LPI diameter was measured in normal ears of 46 patients resulting in 92 measurements (►Fig. 4a and ►Fig. 4b). These patients underwent HRCT scans for non-otological reasons. And patients with chronic otitis media, and ossicular chain abnormalities were excluded from the study. Revision stapes surgery patients were not included in the study.

Results

The total numbers of male patients were 17 and the total numbers of female patients were 24 at surgery. In the group that underwent HRCT, 29 patients were males and 17 were females. Age group of the patients ranged between 18 to 64 years. Mean age of male patient is 42 years and mean age of female patient is 45 years.

Radiological measurements were done in 3 centers and the data are given below.

Radiologically measured incus diameters: CENTER 1

The incus diameters were measured in 18 patients on both right and left sides. 10 were males and 8 were females. The AP diameter of incus ranged from 0.8mm to 1mm, with a mean diameter of 0.89mm. The ML diameter of incus ranged from 0.8 to 1.1mm, with a mean diameter of 0.96mm. (►Table 2).

Radiologically measured incus diameters: CENTER 2

Incus diameters were measured in 15 patients on both the right and left side.

10 were male and 5 were female patients. The AP diameter of incus ranged from 0.8mm to 1.5mm, with a mean diameter of 1.1mm. The ML diameter of incus ranged from 0.7 to 1.1mm, with a mean diameter of 0.9mm (►Table 3).

Radiologically measured incus diameters: CENTER 3

There were a total of 13 patients and the right and left incus diameters were calculated as AP and ML diameters. There were 9 males and 4 females. The AP diameter of incus ranged from 0.6mm to 1mm, with a mean diameter of 0.8mm. The ML diameter of incus ranged from 0.5 to 1.15mm, with a mean diameter of 0.76mm (►Table 4).

In 18 patients who underwent stapedotomy, the intraoperative data (AP and ML diameter) were correlated with those obtained by aHRCT temporal bone (►Table 5). This was done only for the correlation of patient’s surgical and radiological measurements and was not taken as additional number for the study.

Taking into consideration our measurements done both radiologically and surgically together, the AP diameter varies from 0.6mm to 1.5mm and the ML diameter varies from 0.5 mm to 1.2 mm. Depending on quantitative analysis, the mean AP diameter was 0.93 mm and the mean ML diameter was 0.88mm at the site of attachment of prosthesis. The AP diameter shows a greater range and sample variance when

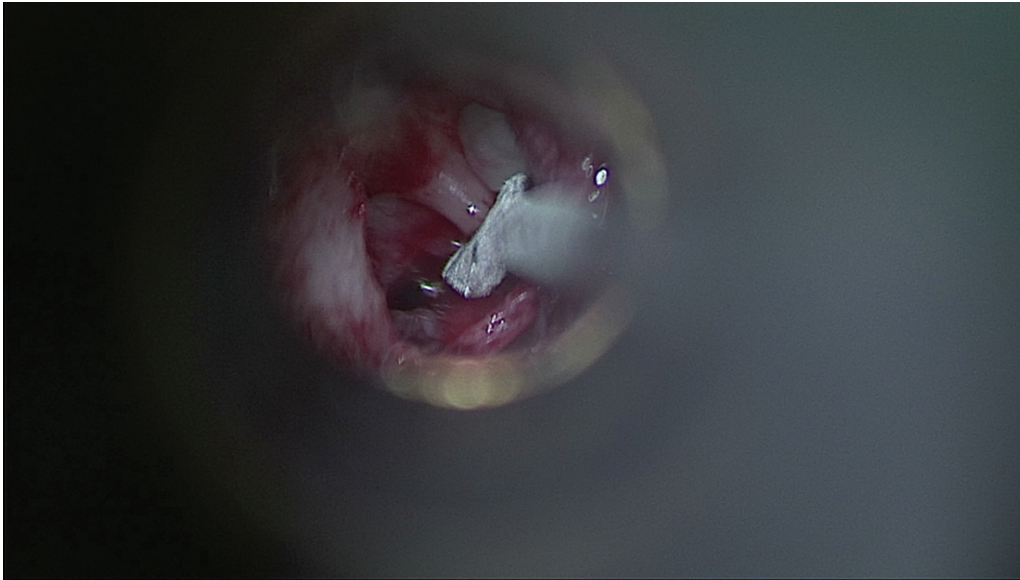


Fig. 1 Antero-posterior diameter measured using the straight instrument during a right stapedotomy surgery

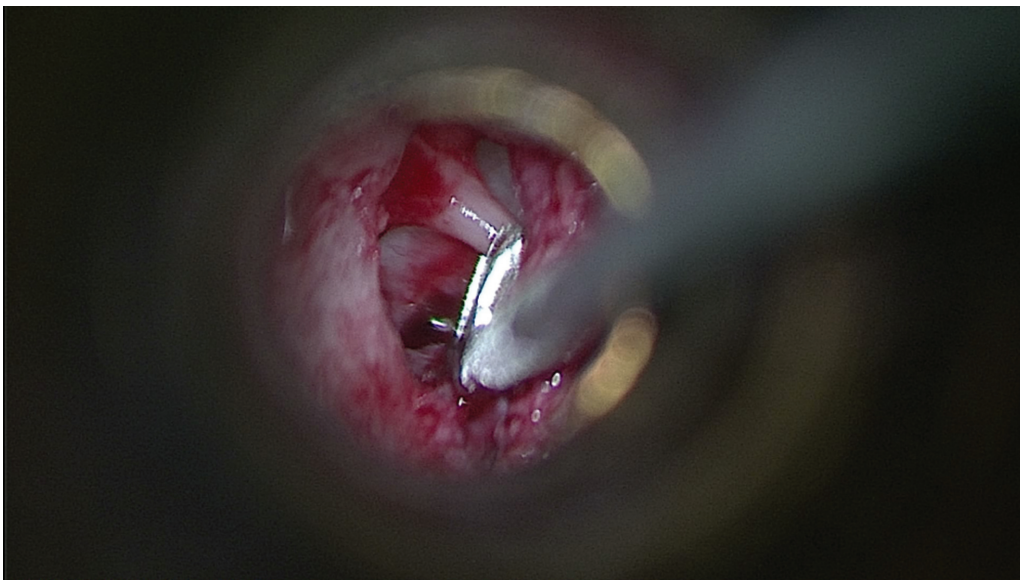


Fig. 2 Medio-lateral diameter measured using a curved instrument during a right stapedotomy surgery

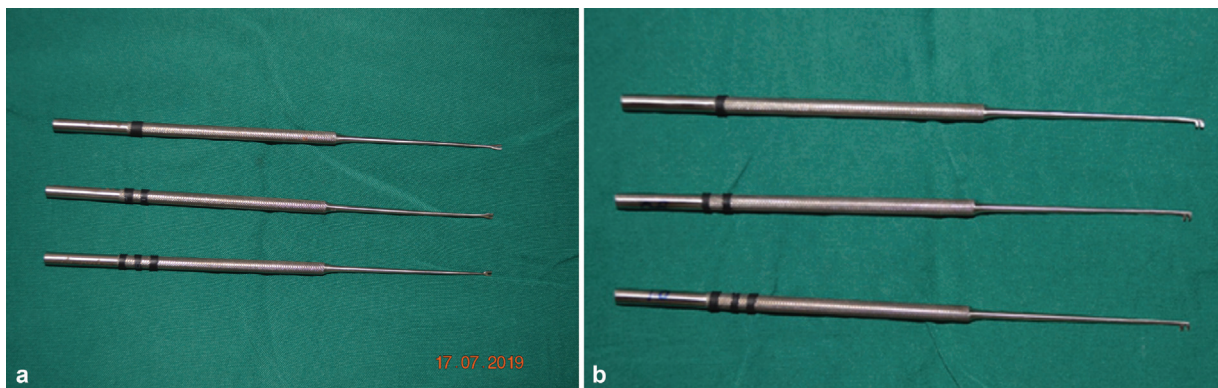


Fig. 3 (a) Straight instruments used for measuring the anteroposterior diameter -1,2,3 rings correspond to 0.6mm,0.8mm and 1 mm respectively. (b) Curved instrument used for measuring the Medio-lateral diameter.1,2 and 3 rings correspond to 0.6mm,0.8mm and 1mm respectively

Table 1 Diameters of LPI measured during surgery with appropriate piston usage

Ap diameter of LPI	Medio lateral diameter of LPI	Piston used	Length of piston shaft/diameter of piston
0.8 mm	1.0mm	Soft clip	4.25mm/0.4mm
0.8 mm	0.8 mm	Teflon	4.25 mm/0.4mm
0.8 mm	0.8 mm	Nitinol	4.25 mm/0.4mm
0.8 mm	0.8mm	Teflon	4.25 mm/0.4mm
0.8mm	0.8 mm	Teflon	4.25mm/0.4mm
0.8 mm	0.8 mm	Teflon	4.25mm/0.4mm
1.0mm	1.0mm	Teflon	4.5 mm/0.4mm
0.8 mm	0.8 mm	Nitinol	4.25 mm/0.4mm
0.8mm	0.8 mm	Nitinol	4.5 mm/0.4mm
0.8mm	0.8 mm	Teflon	4.5mm/0.4mm
1.0mm	1.0mm	Teflon	5 mm/0.4mm
0.6mm	0.8mm	Soft clip	4.5mm/0.4mm
0.8mm	0.8 mm	Soft clip	4.25mm/0.4mm
0.8mm	0.8 mm	Nitinol	5mm/0.4mm
0.8mm	1.0mm	Teflon	4.5mm/0.4mm
0.6mm	0.8 mm	Nitinol	4.25mm/0.4mm
0.8mm	1.0mm	Teflon	4.25mm/0.4mm
0.8mm	0.8mm	Nitinol	4.5mm/0.4mm
0.6mm	0.8mm	Soft clip	4.25mm/0.4mm
1.0mm	0.8mm	Teflon	5mm/0.4mm
0.8mm	0.8mm	Nitinol	4.75 mm/0.4mm
0.8mm	0.8mm	Soft clip	4.25mm/0.4mm
0.6mm	0.8	Soft clip	4.5 mm/0.4mm
1.0mm	1.0mm	Teflon	4.5 mm/0.4mm
1.0mm	1.0mm	Teflon	4.5mm/0.4mm
1.0mm	0.8mm	Teflon	4.25mm/0.4mm
0.8mm	1.0mm	Teflon	4.5mm/0.4mm
1.0mm	0.8mm	Teflon	4.5 mm/0.4mm
1.0mm	1.0mm	Teflon	4.25mm/0.4mm
0.8mm	0.8mm	Soft clip	4.25mm/0.4mm
0.8mm	0.8mm	Nitinol	4.5mm/0.4mm
0.8mm	0.8mm	Nitinol	5mm/0.4mm
1.0mm	1.0mm	Teflon	4.5mm/0.4mm
1.0mm	0.8mm	Teflon	4.5mm/0.4mm
1.0mm	1.0mm	Teflon	4.25mm/0.4mm
1.0mm	1.0mm	Teflon	4.5mm/0.4mm
1.0mm	1.0mm	Teflon	5mm/0.4mm
1.0mm	0.8mm	Nitinol	4.25mm/0.4mm
0.8mm	1.0mm	Nitinol	5.5.mm/0.4mm
1.0mm	1.0mm	Teflon	4.5mm/0.4mm
1.0mm	1.0mm	Teflon	4.5mm/0.4mm

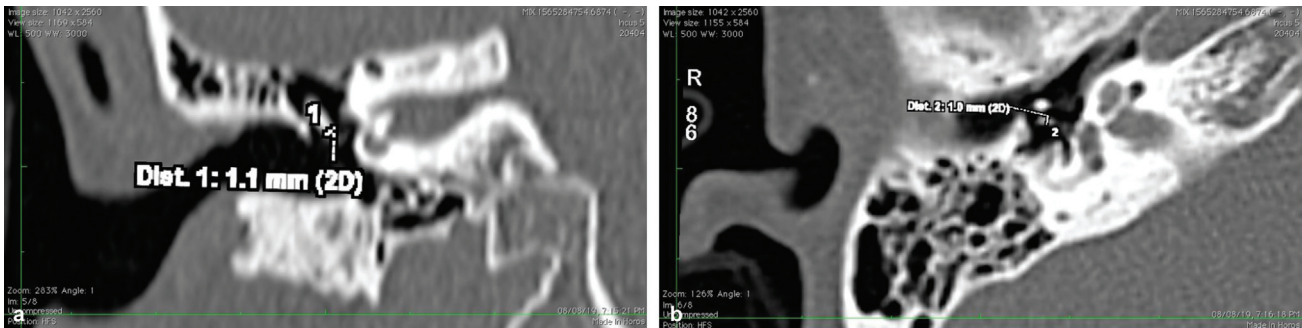


Fig. 4 (a) Radiological measurement of the mediolateral diameter of LPI in the coronal section of HRCT. (b) Radiological measurement of Anteroposterior diameter of LPI in an axial section of HRCT

Table 2 Incus diameter measurements done at Center 1

Side of measurement	AP diameter of LPI in mm	Medio-lateral diameter of LPI in mm	Side of Measurement	AP diameter of LPI in mm	Medio-lateral diameter of LPI in mm
Right	1.0	1.0	Left	0.8	0.9
right	0.9	0.8	Left	0.9	0.8
right	0.8	1.0	Left	0.9	0.9
right	0.9	1	Left	0.9	0.9
right	0.9	1.1	Left	1.0	0.9
right	1	1.1	Left	0.9	1.1
right	1	0.9	Left	0.9	0.9
right	0.9	1	Left	1.0	0.9
right	0.8	1	Left	1	0.9
right	1	0.8	Left	0.9	0.9
right	0.9	0.9	Left	1	1
right	1	1	Left	0.9	1.1
right	0.9	1.1	Left	0.8	1
right	1	0.7	Left	0.8	0.8
right	0.9	0.7	Left	1	0.8
right	1	1	Left	0.9	1
right	1	0.8	Left	1	0.8
right	0.9	1.1	Left	0.9	1.1

compared with the ML diameter. Also, there is no significant difference between the diameters measured at surgery and in CT for the 18 patients in which data obtained from both were compared (→Table 6).

Discussion

The most critical points of stapedotomy are the perforation of the footplate and the attachment of the stapes prosthesis on the incus. There are no appropriate instruments, which could ensure a stable attachment of the stapes prosthesis loop on the LPI.

We found a great variability in the diameters of LPI with AP diameter ranging between 0.6 -1.5mm and the ML

diameter ranging between 0.5mm to 1.2 mm. The most commonly used site for prosthesis attachment is between 1–1.5 mm from the tip of the LPI. According to Kwok et al, the average level of prosthesis attachment is 1.4 mm +/- 0.28 mm from the tip of the long process. The diameter at this level has a wide range. Measuring the incus diameter in the incus bone of 11 cadavers, Kwok et al found a minimum diameter of 0.66 +/- 0.05mm and a maximum diameter of 0.81 mm +/- 0.1mm. In that study the mean circumference was 2.46 +/- 0.23 mm. They concluded that the loop of stapes prosthesis should have the following dimensions: diameter 0.9 mm, loop length of 2.2mm, and opening of loop 0.7 mm. However, the material, memory of the prosthesis and its malleability are also important factors.⁶

Table 3 Incus diameter measurements obtained from center 2

Side of measurement	Ap diameter of LPI in mm	Medio-lateral diameter of LPI in mm	Side of measurement	AP diameter of LPI in mm	Medio-lateral diameter of LPI in mm
right	1.1	0.9	Left	1.1	0.6
right	1.5	0.9	Left	1.1	0.8
right	1.1	0.7	Left	1.1	0.7
right	1.5	0.9	Left	1.4	0.9
right	1.3	0.8	Left	1.2	0.8
right	1.1	0.8	Left	1.4	0.9
right	1.2	1.1	Left	1.2	0.8
right	1.1	0.8	Left	1.1	0.7
right	1.3	1.1	Left	1.4	0.7
right	1.1	0.8	Left	1.2	0.9
right	1.2	0.7	Left	1.3	1
right	0.9	0.8	Left	0.8	1
right	0.9	0.8	Left	1.2	0.8
Right	1.1	1.0	Left	0.9	0.7
right	1.0	0.9	Left	1.2	0.7

Table 4 Radiologically measured diameters from center 3

Side of measurement	AP diameter of LPI in mm	Medio-lateral diameter of LPI in mm	Side of measurement	AP diameter of LPI in mm	Medio-lateral diameter of LPI in mm
Right	0.9	0.6	Left	0.7	0.5
Right	0.9	0.9	Left	0.8	0.9
Right	0.8	0.7	Left	0.8	0.6
Right	1.0	0.8	Left	1.0	0.8
Right	0.9	0.9	Left	0.9	0.7
Right	0.9	0.7	Left	0.8	0.8
Right	0.7	1.2	Left	0.9	1.0
Right	0.7	0.9	Left	0.7	0.8
Right	0.6	0.8	Left	0.8	1.0
Right	0.8	1.1	Left	0.7	0.8
Right	0.6	1.0	Left	0.7	1.15
Right	0.9	1.13	Left	0.8	1.12
Right	0.7	0.9	Left	0.8	0.9

Toth et al studied 50 cadaver incus in which he demonstrated greater variability with a range in diameter from 0.52 mm to 1.15 mm. Our study shows similar results in variability like the study by Toth et al. Toth et al also demonstrated three different cross-sectional shapes (Round, oval or irregular) proceeding along the LPI from 0.5 mm, 1 mm, 1.5 mm, 2 mm and 2.5 mm from the tip. He has also demonstrated difference in shape of planes passing through the diameter at cross section by measuring the angle between lateral wall of incus and the cross section. It could be

truncated shape or an inverted truncated shape.⁷ Stapes prostheses that have a thin band shaped loop (eg-Platinum ribbon) cannot be attached to the whole bony surface despite a spiral shape if the LPI has the shape of a truncated cone. These facts further stress the importance of adapting an ideal piston loop to the patient's incus. Since 2009, a titanium stapes prosthesis, the soft clip (KURZ GmbH Medizintechnik, Germany) is available. This is a self-retaining prosthesis that requires no crimping. The short-term hearing results are very good, but it cannot be used in a very thin or a very thick incus

Table 5 Comparison between surgically obtained diameters and radiologically obtained diameters made for 18 patients

AP diameter at surgery	Medio-lateral diameter at surgery	AP diameter measured in CT	Medio-lateral measurement measured in CT
0.8mm	1mm	0.7mm	1mm
0.8mm	0.8mm	0.7mm	0.8mm
0.8mm	0.8mm	0.8mm	0.7mm
0.8mm	0.8mm	0.7mm	0.7mm
0.8mm	0.8mm	0.8mm	0.9mm
0.8mm	0.8mm	0.8mm	0.8mm
1mm	1mm	1mm	1.12mm
0.8mm	0.8mm	0.7mm	0.8mm
0.8mm	0.8mm	0.9mm	0.9mm
1mm	1mm	1.15mm	1mm
0.6mm	0.8mm	0.6mm	0.7mm
0.8mm	0.8mm	0.8mm	0.8mm
0.8mm	0.8mm	0.7mm	0.8mm
0.8mm	1mm	0.8mm	1mm
0.6mm	0.8mm	0.5mm	0.8mm
0.8mm	1mm	0.8mm	1.12mm
0.8mm	0.8mm	0.8mm	0.8mm
0.6mm	0.8mm	0.6mm	0.7mm

Table 6 Statistics

Parameters	AP diameter	Lateral diameter
Mean	0.935	0.881
Standard error	0.015	0.011
Median	0.9	0.9
Mode	0.8	0.8
Standard deviation	0.181	0.129
Sample variance	0.032	0.0167
Kurtosis	0.979	-0.219
Skewness	0.759	-0.02
Range	0.9	0.7
Maximum	0.6	0.5
Minimum	1.5	1.2
Sum	123.5	116.3
Count	132	132

long process.⁸ The remaining diameter of a closed clip prosthesis is ~0.5mm with an optimum expansion of 0.9mm. In cases of a minimum diameter 0.5 mm of LPI fitting to the bone surface may be too loose because of reduced expansion of the loop. With an extreme diameter of 1.15 mm, the expansion of the loop exceeds its given

diameter more than 2 times. This could lead to inability of prosthesis to attach or to a lack of gripping force to the incus because of over expansion. Furthermore, large size of the LPI, leads to greater forces needed to attach the prosthesis and can result in incus subluxation or dislocation necessitating a revision surgery.

Superelastic Nitinol piston (Audio Technologies, Italy) has short term and long term follow up studies with good hearing results. Very good post op results are obtained while the rates of complications are low.⁹

Optimum fitting depends on the diameter and form of the long process of the incus. Again, in case of extreme diameters like mentioned previously, fitting to the bone could be restricted by the given properties of the prosthesis optimized for a certain diameter. Also, prosthesis tends to slip and elastic recoil at times uncontrollably throws it out of the microscope's field of vision. Revision stapes surgery accounts for 10% of otology surgeries.¹⁰ The reappearance of conductive deafness is the main reason for revision. Fisch et al¹⁰ have reported that in almost 80–85% of cases, revision surgery is related with either prosthesis (too tight or fixed, too loose, too long, too short, bent, etc.) or oval window problems (fibrosis, narrowing, granulation tissue, new bone formation, fistula). In addition to problems like inadequate crimping of prosthesis to incus or prosthesis detachment or overlooked incus mobility problems, one of the most common causes of revision surgery is incudo malleolar ankylosis or malleus-epitympanic fixation especially for patients who have limited hearing gain during primary surgery.

The Teflon piston has an inner loop diameter that measures 0.6mm (Grace Medicals, Memphis, TN, USA) to 0.8 mm (Indian audio center, Chandigarh, India) that needs expansion before crimping. In this situation, even after crimping the piston remain loose. For a 0.6 mm LPI ideally the piston should have a smaller loop to ensure a good fit. Before measurement of the LPI was available interposed autologous fat, fascia or vein was used to improve the fit.

The author feels that customizing size of the prosthesis after determining the diameters of incus at the probable attachment site (either radiologically/or directly during surgery) will reduce the need for reliance on crimping and memory of prosthesis. We also expect less hearing deterioration as a result of better contact between prosthesis and incus with reduced likelihood of incus necrosis. The Kurz soft clip and nitinol piston were more suitable for smaller LPI diameters between 0.6 mm-0.8 mm and the Teflon piston was more suitable for incus diameters >0.8mm. In our study we have found diameters of 0.5 mm also so more attention to the inner loop diameter needs to be given.

While additional crimping of these pistons designed to be used without crimping is possible for a loose fit, it is ineffective and can be dangerous.

Piston manufacturers report piston specifications such as functional length and diameter. The inner loop diameters are not reported by all manufacturers. Until pistons with variable inner loop diameters are available knowing these measurements can optimize piston selection.

Conclusion

The purpose of this study is to provide anatomic data on the diameter of the long process of the incus at the area of attachment for stapes prosthesis. Knowing the dimensions of the attachment site optimizes the size of the prosthesis loop at surgery. Measurements of the LPI diameter on HRCT before

the Otosclerosis surgery can guide prosthesis selection during surgery.

Funding

The author(s) received no financial support for the research.

Conflict of Interest

None declared.

References

- 1 McGee TM. The loose wire syndrome. *Laryngoscope* 1981;91(9Pt 1): 1478–1483
- 2 Schwalbe GA. *Lehrbuch der Anatomie der Sinnesorgane*. E. Besold, 1887:487–92
- 3 Skinner M, Honrado C, Prasad M, Kent HN, Selesnick SH. The incudostapedial joint angle: implications for stapes surgery prosthesis selection and crimping. *Laryngoscope* 2003;113(04): 647–653
- 4 Gully AJ, Schuknecht HF. *Anatomy of the Temporal Bone with surgical Implications*. New York, NY: parthenon publishing Group; 1995:63–68
- 5 Lesinski SG. Causes of conductive hearing loss after stapedectomy or stapedotomy: a prospective study of 279 consecutive surgical revisions. *Otol Neurotol* 2002;23(03):281–288
- 6 Kwok P, Fisch U, Gleich O, Achhammer K, Strutz J. Stapes surgery: the diameter of the long process of the incus. *Otol Neurotol* 2006; 27(04):469–477
- 7 Tóth M, Moser G, Rösch S, Grabmair G, Rasp G. Anatomic parameters of the long process of incus for stapes surgery. *Otol Neurotol* 2013;34(09):1564–1570
- 8 Bast F, Schrom T. [First experiences with the new soft-clip piston as an alloplastic prosthesis during stapedotomy]. [in German] *Laryngorhinootologie* 2009;88(05):304–308
- 9 Bast F, Weikert S, Schrom T. Treatment of otosclerosis with a superelastic nitinol piston: first results. *Indian J Otolaryngol Head Neck Surg* 2011;63(02):126–131
- 10 Fisch U, Acar GO, Huber AM. Malleostapedotomy in revision surgery for otosclerosis. *Otol Neurotol* 2001;22(06):776–785