


NON-INVASIVE ANGIOGRAPHY**Original Studies**

Novel method for radial sheath removal using manual pressure over hemostatic pad combined with ulnar compression

Carmelo Panetta, MD^{1,2}  | Sunil Rao, MD³

¹Division of Cardiology, Department of Medicine, University of Minnesota, Minneapolis, Minnesota

²HealthEast Heart Care, St. Joseph Hospital, St. Paul, Minnesota

³Duke Clinical Research Institute, Durham, North Carolina

Correspondence

Carmelo Panetta, MD, HealthEast Heart Care, 45 West 10th Street, St. Paul, MN 55102.

Email: panet002@umn.edu

Funding information

HealthEast Heart Care, St. Paul, MN, Chitogen In., Minneapolis, MN

Abstract

Objectives: Study a novel method using manual pressure on a hemostatic pad and hemoband for ulnar compression as a potential alternative for radial sheath removal.

Background: The standard for transradial access site (TRA) sheath removal requires an inflatable pressure band over the radial artery and recently a band over the ulnar artery to reduce complications. We present a novel technique using a SoftSeal®-STF hemostatic pad over the radial artery combined with a hemoband over the ulnar artery after sheath removal.

Methods: All patients had activated clotting time (ACT); sheath removal was performed immediately upon transfer to the recovery room. A hemoband compressed the ulnar artery, radial artery flow was measured using plethysmography and pulse oximetry while direct pressure applied using SoftSeal-STF hemostatic pad for 15 min after radial sheath removed. Radial artery patency was measured using reverse Barbeau test. If radial artery occlusion (RAO) present, patient was asked to return in one month to repeat test.

Results: Fifty-nine patients were enrolled in the study, one-third with diabetes mellitus, one-third with prior coronary artery bypass surgery, and one-third with history of percutaneous coronary intervention. Mean ACT 261 ± 50 sec, all patients had 4 Fr sheaths and no PCI were performed. Three (6%) patients had minor bleeding requiring use of a pressure band and one (2%) had RAO, which re-canalized at one month.

Conclusions: Manual pressure of SoftSeal-STF hemostatic pad combined with ulnar compression is a potential alternative to current practice with an inflatable pressure band.

KEYWORDS

radial artery occlusion, transradial access, transradial approach, transradial catheterization

1 | INTRODUCTION

Transradial access (TRA) has been advanced due to reduction in access site complications compared to femoral access [1]. The combination of adequate anticoagulation, with patent hemostasis, has kept radial artery occlusion (RAO) rates low [2,3]. The use of a pressure band [3] for several hours after removal of the sheath is the mainstay post procedure, with the recent advance of using ulnar compression to reduce

RAO less than 1% [4]. Direct manual pressure has the potential to reduce costs and time in the recovery unit and improve access in the preparation/recovery area of the cardiac catheterization laboratory. The SoftSeal®-STF hemostatic pad has properties proposed to induce thrombosis and reduce bleeding over wound or vascular access sites [5]. We present results of a clinical study on a novel technique using manual pressure on a SoftSeal-STF hemostatic pad over the radial artery access site combined with the use of pressure over the ulnar artery after sheath removal for TRA.

Work was completed at HealthEast/St. Joseph Hospital, St. Paul, MN

This is an open access article under the terms of the Creative Commons Attribution-NonCommercial-NoDerivs License, which permits use and distribution in any medium, provided the original work is properly cited, the use is non-commercial and no modifications or adaptations are made.

© 2018 The Authors Catheterization and Cardiovascular Interventions Published by Wiley Periodicals, Inc.

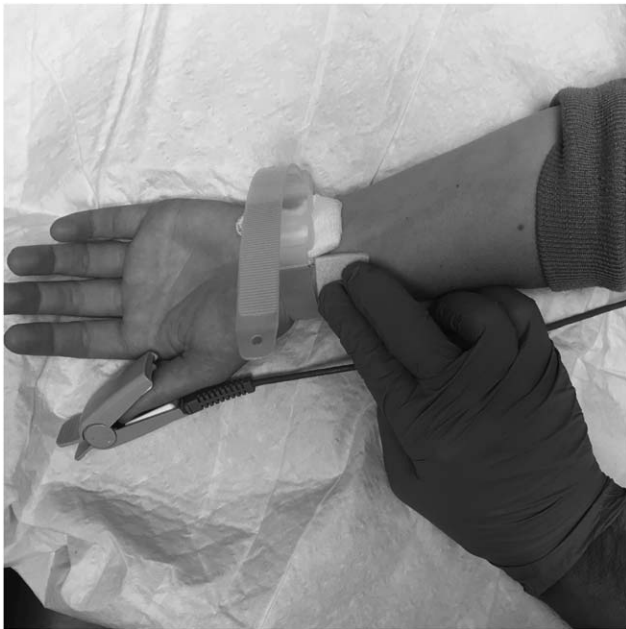

FIGURE 1 Radial artery access site after sheath removal using hemoband over ulnar artery and SoftSeal-STF pad over radial artery with manual compression with photoplethysmogram to confirm patent hemostasis

2 | MATERIALS AND METHODS

All patients had radial artery access using 4 Fr sheaths (Terumo for cardiac catheterization and coronary angiography). Nitroglycerine (100 mcg) and nicardipine (100 mcg) were given intra-radial after sheath placed, followed by 1,000 units of heparin intra-radial and additional heparin given via intravenous route 50 units/kg and monitored by activated clotting time (ACT) (Hemochron Response, Edison, NJ). If patient was on heparin on arrival, an ACT was obtained and additional heparin given to achieve ACT greater than 200 sec. After coronary angiography, the patient was transferred to the recovery room and the sheath immediately removed. The protocol involves placement of a disposable pressure pad band (HemoBand Corp, Portland, OR) over the ulnar artery and photoplethysmogram to have constant measurement to rule out complete occlusion of the radial artery during the entire period of manual pressure and afterwards for monitoring. SoftSeal-STF Hemostatic pad (Chitogen Inc, Minneapolis, MN) is placed over the radial artery access site, sheath is removed and pressure is applied for 15 min (Figure 1). Initial testing for study design evaluated 8–15 min manual pressure, with higher bleeding rates below 14 min prompting use of 15 min for direct pressure and use of simultaneous ulnar compression to allow more firm pressure over the radial access site. Radial artery patency was evaluated by measuring flow to the hand with plethysmography and pulse oximetry (Reverse Barbeau) [6] and bleeding was monitored. If bleeding were to occur, a TR Band Inflator (Terumo, Elkton, MD) was placed. Patients with RAO were asked to return for repeat testing of flow to the hand after one month.

TABLE 1 Clinical Characteristics of Study Patients

Variables	All (n = 59)
Age (years)	67 ± 11
Women no. (%)	23 (39%)
Diabetes mellitus no. (%)	19 (32%)
Current smoker no. (%)	5 (9%)
Prior CABG ^a no.(%)	18 (31%)
Prior PCI ^a no. (%)	25 (42%)
Anti-platelet medication ^a no. (%)	13 (22%)
Warfarin or NOAC ^a no. (%)	7 (12%)
Systolic blood pressure (mm Hg)	151 ± 9
Diastolic blood pressure (mm Hg)	79 ± 6
Platelet count (thou/uL)	213 ± 74
INR ^a	1.36 ± 0.5
Creatinine (mg/dL)	1.01 ± 0.4

^aCABG = coronary artery bypass surgery; PCI = percutaneous coronary intervention; Anti platelet medication includes clopidogrel, prasugrel or ticagrelor; NOAC = new oral anticoagulant; INR = International normalized ratio for only those on warfarin.

3 | RESULTS

Fifty-nine patients were enrolled in the study with slightly less than half female, one-third with diabetes mellitus; three quarters had prior coronary artery bypass surgery or percutaneous coronary intervention (PCI) (Table 1). One-third was on warfarin, new oral anticoagulant or one of the antiplatelet medications clopidogrel, prasugrel, or ticagrelor. Intravenous heparin was given in all 59 patients except for one patient who was on intravenous heparin on arrival and with an ACT above 200 sec. The mean dose of intravenous heparin was 3,983 ± 1,185 units and all patients received 1,000 units heparin intra-radial artery along with the intra-radial vasodilators. ACT was performed in all 59 patients with mean 261 ± 50 sec. All patients had only diagnostic angiography with 4 Fr sheath, and no PCI were performed. All patients were transferred from the cardiac catheterization laboratory to recovery rooms and the sheath was immediately removed as outlined in Methods section.

Three patients (6%) had minor bleeding requiring use of a pressure band over the radial artery with compression for 2 hr per protocol. One (2%) patient, who did not have bleeding complications, had RAO that re-canalized at one month.

4 | DISCUSSION

TRA has several advantages including lower bleeding, patient satisfaction, and rapid ambulation and discharge [7]. TRA has known complication of RAO [2–4,7], but with the use of anticoagulation, patent hemostasis, and the use of trans-ulnar pressure, the risk is significantly lower compared to earlier studies [4]. Patent hemostasis has employed

the use of an inflatable pressure band, which is the standard of care with rare exceptions [7]. We report a novel technique combining ulnar compression with a HemoBand with manual pressure over a SoftSeal-STF hemostatic pad for 15 min. Limitations of the results include the use of only 4 Fr sheaths and the study was not randomized with a pressure band, therefore any comparison to alternative methods for sheath removal are only hypothetical. Longer compression times may be required for larger sheaths. Further randomized trials would be warranted to compare time to discharge, use of pressure band with hemostatic pad compared to direct manual pressure compared to standard pressure band evaluating the rates of RAO and bleeding, staffing to accommodate removal of both 5 Fr and 6 Fr sheath sizes and time to discharge.

5 | CONCLUSION

Manual compression of SoftSeal-STF hemostatic pad and ulnar compression with a hemoband for radial sheath removal is a novel method that appears relatively safe. Future studies should be considered with larger sheath size and to evaluate the length of stay in recovery and possible improved catheterization laboratory patient throughput compared to a pressure band.

ACKNOWLEDGMENTS

Clinical research team at HealthEast including Andrew Snyder, Beth Jorgenson and Mark Laliberte. Funding for the study was supported by HealthEast Heart Care, St. Paul, MN and Chitogen Inc., Minneapolis, MN.

CONFLICT OF INTEREST

Carmelo Panetta Co-owner LP Medical, LLC. The other author do not have any conflict of interest.

ORCID

Carmelo Panetta MD  <http://orcid.org/0000-0002-4707-8265>

REFERENCES

- [1] Feldman DN, Swaminathan RV, Kaltenbach LA, et al. Adoption of radial access and comparison of outcomes to femoral access in percutaneous coronary intervention: An updated report from the National Cardiovascular Data Registry (2007–2012). *Circulation* 2013;127:2295–2306.
- [2] Spaulding C, Lefèvre T, Funck F, Thébault B, Chauveau M, Hamda KB, Chalet Y, Monségu J, Tsocanakis O, Py A, Guillard N, Weber S. Left radial approach for coronary angiography: Results of a prospective study. *Catheter Cardiovasc Diagn* 1996;39:365–370.
- [3] Pancholy S, Coppola J, Patel T, Roke-Thomas M. Prevention of radial artery occlusion-patent hemostasis evaluation trial (PROPHET study): A randomized comparison of traditional versus patency documented hemostasis after transradial catheterization. *Catheter Cardiovasc Interv* 2008;72:335–340.
- [4] Pancholy S, Bernat I, Bertrand O, Patel T. Prevention of radial artery occlusion after transradial catheterization. The PROPHET-II randomized trial. *J Am Coll Cardiol* 2016;9:1992–1999.
- [5] Achneck HE, Sileshi B, Jamiolkowski RM, Albala DM, Shapiro ML, Lawson JH. A comprehensive review of topical hemostatic agents efficacy and recommendations for use. *Ann Surg* 2010;251:217–228.
- [6] Barbeau GR, Arsenault F, Dugas L, Simard S, Larivière MM. Evaluation of the ulnopalmar arterial arches with pulse oximetry and plethysmography: Comparison with the Allen's test in 1010 patients. *Am Heart J* 2004;147:489–493.
- [7] Caputo RP, Tremmel JA, Rao S, Gilchrist IC, Pyne C, Pancholy S, Frasier D, Gulati R, Skelding K, Bertrand O, Patel T. Transradial arterial access for coronary and peripheral procedures: Executive summary by the transradial committee of the SCAI. *Catheter Cardiovasc Interv* 2011;78:823–839.

How to cite this article: Panetta C, Rao S. Novel method for radial sheath removal using manual pressure over hemostatic pad combined with ulnar compression. *Catheter Cardiovasc Interv*. 2018;92:322–324. <https://doi.org/10.1002/ccd.27579>