

Cementation in total hip arthroplasty: history, principles, and technique

James R Satalich¹, Daniel J Lombardo¹, Simon Newman², Gregory J Golladay¹ and Nirav K Patel¹

¹VCU Health Department of Orthopaedic Surgery, Richmond, Virginia, USA

²Nuffield Orthopaedic Center, University of Oxford, Oxford, UK

Correspondence should be addressed to James R Satalich

Email

james.satalich@vcuhealth.org

- Total hip arthroplasty (THA) is a remarkably successful operation that has grown rapidly its utilization.
- Early modern THA constructs as developed by Sir John Charnley featured cemented femoral stems and acetabular components. The technique of cementing components for THA has evolved over time.
- Modern acetabular preparation requires exposure of the subchondral bone with appropriate cement penetration into the trabecular bone, whereas femoral preparation requires cleaning of the canal, cement restrictor placement, retrograde filling, and pressurization of the cement.
- When used appropriately, these techniques result in excellent long-term survivorship of implants and are also widely considered to be the ideal method of fixation for hip fractures.
- The purpose of this article to review the history, properties, techniques, and outcomes of bone cement utilization in THA.

Keywords

- ▶ total hip replacement
- ▶ arthroplasty
- ▶ bone cement
- ▶ surgical technique

EFORT Open Reviews
(2022) 7, 747–757

Background

Sir John Charnley's low friction total hip arthroplasty (THA) revolutionized the management of hip osteoarthritis. His design featured a low frictional torque head, a high-density polyethylene-bearing surface, and fixation of components to bone with acrylic cement. This, as well as future designs of THA, has shown excellent long-term outcomes, with THA being coined as 'the orthopedic operation of the century' (1). As the utilization of THA developed, press-fit components have become more popular, and the utilization of cement has decreased (2). While still commonly used in Europe and Australia (35), cemented THA in the United States has steadily declined to the point that cement use in arthroplasty is considered to be a 'lost art' among orthopedic surgeons and trainees. Despite this, there remain scenarios in which cemented THA components have superior outcomes such as for hip fracture, where cementation is arguably the standard of care. This paper aims to review the history, properties, techniques, and outcomes of bone cement utilization in THA.

History of bone cement

Themistocles Gluck is credited as being among the first to experiment with the use of cement for the fixation

of artificial joints in the 1880s (3). This practice did not gain popularity until Charnley introduced the use of polymethylmethacrylate (PMMA) bone cement for THAs in the late 1950s (4).

While the current composition of bone cement has not changed much, the technique of cement insertion has evolved significantly since its inception. 'First-generation' technique included simple hand mixing, finger packing, and hand insertion of cement. Early basic and clinical studies showed significant improvements in the fixation strength of cement when the cancellous bone of the canal was cleaned and cleared of debris (5, 6, 7). These findings led to 'second-generation' cement technique which includes utilizing a cement restrictor (8), thorough irrigation and drying of the canal, and retrograde filling with the cement, yielding improved outcomes compared to previous techniques (9).

'Third-generation' or modern cementing technique includes the elements of the second-generation technique, with the addition of vacuum mixing and pressurization of the cement, in addition to centralizers around the stem to ensure a uniform cement mantle. Vacuum mixing is used to decrease the porosity of cement in order to improve its mechanical properties (12). Pressurization of cement was later found to result in improved penetration into the macrostructure of cancellous bone, resulting in

stronger fixation (10, 11). Centralizers are primarily aimed to decrease the incidence of C2 defects on the Barrack classification where the implant is in direct contact with the bone due to complete voids in the cement mantle (9).

Despite these advances and strong clinical outcomes, in the mid- to late 1990s, there was a movement away from the use of cement in THA. One driving factor was that the long-term outcomes of cemented acetabular components were often viewed as suboptimal with increased rates of loosening and failure compared to cemented stems (33). These poor results may relate to the technically demanding nature of cemented acetabular component insertion, bony morphology around the acetabulum, and increased shear stresses at the bone–implant interface (13). This coupled with the success of press-fit acetabular components drove the utilization of a ‘hybrid’ technique, with cemented femoral and uncemented acetabular components (14). Another concern at this time was what was initially called ‘cement disease’. This was based on the observation that a pathologic bone response occurred at the bone–cement interface due to a foreign material (15). This process was later discovered to be related to osteolysis due to polyethylene debris and not a distinct reaction to the cement. Concerns about long-term fixation, as well as the difficulties encountered with cement removal during revision, influenced the trend toward fully uncemented THA which constituted 93% of all THA in the USA by 2012 (16).

Formation of PMMA

PMMA bone cement is formed by mixing a liquid methylmethacrylate (MMA) monomer and a powdered MMA–styrene co-polymer. To expedite the reaction, the powdered MMA component also is packaged with an initiator such as benzoyl peroxide, while the liquid includes an activator such as *N,N*-dimethyl-*p*-toluidine (DmpT). To be used for cementation purposes, the MMA must be polymerized. When mixed, the DmpT causes the decomposition of the di-benzoyl peroxide (BPO) in a reduction/oxidation process. This forms free radicals which initiate the polymerization process through attachment to the C=C double bond of the MMA. The continued process of breaking the double bond and recombination of the two radical chains lead to the formation of a large polymer and depletion of free radicals. This radical polymerization of MMA to PMMA is an exothermic process, ultimately releasing 57 kJ of heat per mole of MMA and results in the formation of bone cement used today.

There have been concerns of thermal necrosis due to the elevated temperature formed during the exothermic process of cement curing which could contribute to aseptic loosening of cemented implants. This drove attempts to develop a low-temperature cement called

Boneloc (Biomet, Warsaw, IN, USA) in the early 1990s (37). This bone–cement was designed through alterations in the chemical properties and reaction in order to be a cold curing cement. Despite the conceptual benefits of cold curing cement, studies on its use have shown inferior mechanical properties compared to conventional PMMA bone–cement (37, 38).

Properties of bone cement

Several different additives are used to improve the properties of PMMA for use in the fixation of implants. Hydroquinone is added as a stabilizer to the monomer to prevent spontaneous polymerization from light or heat exposure in the packaging. As discussed in the prior section, an initiator, BPO, and an accelerator, DmpT, are also added to the liquid as catalysts to decrease the energy of activation of the polymerization reaction. Contrast agents, such as zirconium dioxide (ZrO₂) or barium sulfate (BaSO₄), are also added to make the cement radiopaque. Commercial bone cement is typically packaged such that the powder contains the PMMA polymers, an initiator, and a radio-opacifier, while the liquid component contains the MMA monomer, an accelerator, and a stabilizer.

Adjuvants can also be added to the cement, such as antibiotics, for treating or preventing infection. The antibiotic must be heat stable so as not to be denatured during curing of the cement. Various amounts of antibiotic can either be added by the surgeon or be pre-mixed in commercially available preparations. The dose used must be high enough to allow appropriate elution but low enough to avoid systemic effects or compromising the mechanical strength of the cement. Methylene blue dye can be added or chlorophyll is pre-mixed to the bone cement, allowing for a readily apparent color contrast to that of the bone. While methylene blue has no effect on the mechanical properties of cement, it does decrease the setting time (17).

The process of cement curing is divided into four stages: mixing, sticky or waiting, working, and hardening. The mixing phase ends when the dough becomes homogenous and is stirred easily.

The working phase begins when the cement is no longer ‘sticky’ or ‘hairy’ and is complete when the cement folds when kneading and does not join itself. The working phase of cement is the ideal time for application due to these characteristics and the lower risk for embolization. Increasing ambient temperature and humidity can affect the cement handling characteristics, resulting in a faster and slower setting time, respectively. It is therefore recommended that bone cement be stored and used in consistently controlled environments.

Bone cement preparations are also available in various viscosities based on the relative amounts of monomer and

polymer in the mix. For use in orthopedics, the cement must be thin enough to allow it to be delivered into the bone but also viscous enough to resist the inclusion of blood into the cement causing lamination. High-viscosity cement typically has a longer working and shorter waiting phase, with greater heat generation. On the contrary, low-viscosity cement typically has a shorter working and a longer waiting phase (18). The benefit of high-viscosity cement is easier handling and application, whereas low-viscosity cement has demonstrated greater penetration into the bone and theoretically better fixation (19). There are also medium-viscosity cement preparations that attempt to bridge the gap between these two. As such, the ideal cement viscosity for use in THA is still unknown and should be selected according to the intended use and surgeons' experience.

Cement fracturing

Mechanical failure of the PMMA bone cement can lead to loosening and ultimately implant failure. Fatigue failure whereby cracks are formed and ultimately propagated under cyclical loading is a common mode of failure of cemented implants (40, 41, 42). The basic understanding of the mechanism in which cracks occur is an important piece of fundamental knowledge a surgeon should know when using bone cement.

There can be areas of discontinuity or gapping within the bone cement mantle (39). These areas of discontinuity can be caused or created due to many different reasons. One reason is due to the microconstituents within the cement, such as barium sulfate (BaSO_4) or other radiopacifiers which effectively create a void in the cement. They also may occur due to pore formation during cement curing and are unavoidable (39). Under cyclical loading, these discontinuities can expand and coalesce into macrocracks in turn leading to disintegration of the cement mantle and loosening of implants.

Cementing techniques

While there are many different techniques for cemented THA, several key points can help improve the workflow and outcomes. Bone cement can be prepared in a variety of commercially available, vacuum pressure mixing systems to reduce its porosity. The cement should be mixed according to the manufacturer's recommended duration and then be transferred to a commercially available delivery device or a cement 'gun' that can allow for precise fill and pressurization. The mixing chamber of most modern cement systems is typically also the same chamber for the cement delivery system, to avoid handling between these steps. If a pressurizer

is to be used for the femur, then this is applied to the long attachment or nozzle. It is also important to start a timer when beginning to mix the cement so that it can be inserted in the appropriate phase and help determination of curing.

Acetabular preparation and cementation

After appropriate exposure of the acetabulum (Fig. 1), it should be reamed so that bleeding cancellous bone is exposed from the ilium, ischium, and pubis (Fig. 2). Four to six holes should be drilled to a depth of 5–10 mm to allow for better cement interdigitation (Fig. 3). This can be achieved using instruments such as the lug hole drill used for the femoral component in knee arthroplasty or the 4 mm drill bit used for acetabular cup screws (Fig. 4). These holes should be particularly placed superiorly in the anterior–superior and posterior–superior zones, from 10 to 2 o'clock on a clock face. The bone surface should be cleaned with pulsatile lavage saline and then thoroughly dried, for example, with epinephrine-soaked sponges. We recommend the polyethylene cup be placed into the acetabulum beforehand to ensure it can be seated without obstruction, taking note of its relation to nearby anatomical landmarks such as the posterior or anterior walls.

Once in the doughy phase, the cement is rolled into a ball and placed into the acetabulum and pressurized over the entire bone surface (Fig. 5). Eighty grams of cement are usually adequate for this if there are no significant bone defects. Pressurization can be with a specific device

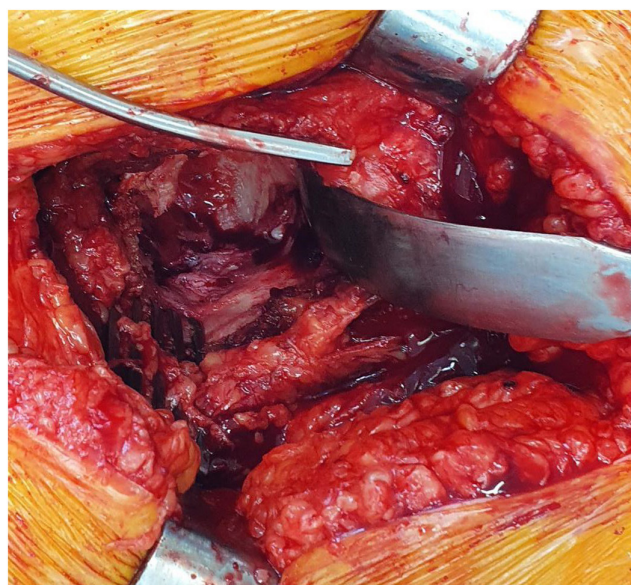

Figure 1
Initial exposure of the acetabulum during a total hip replacement via a posterior approach.

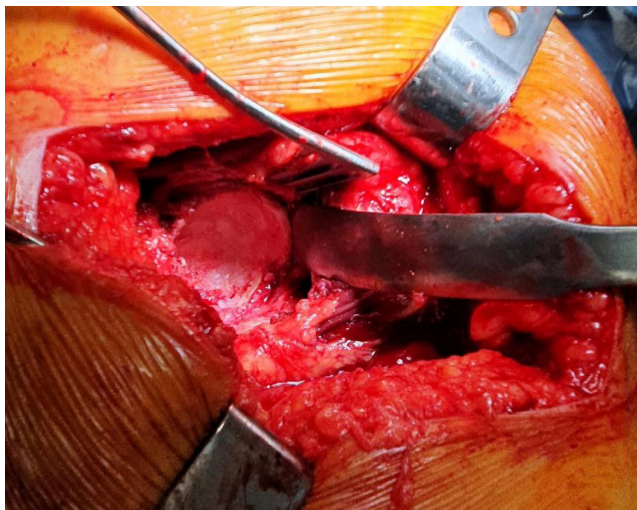


Figure 2
Appearance of the acetabulum following reaming.

according to the implant used such as the acetabular liner impactor on a handle or a sponge placed into a surgical glove and tied with a knot. Either device should be wet with saline to avoid cement adherence (Fig. 6). One must plan for an even, 2 to 3 mm cement mantle around the component.

The all-polyethylene cemented acetabular component (Fig. 7) should then be inserted in the ideal orientation using an introducer (Fig. 8). It is important to completely bury the cup within the boundary of the bony acetabulum. After the initial push, the introducer can be removed and excess cement cleared around the cup and acetabulum, particularly by the notch. Note is also made of how much more the cup needs to be seated and positioning according to the surrounding anatomical landmarks. The introducer is then re-inserted with constant and firm pressure,

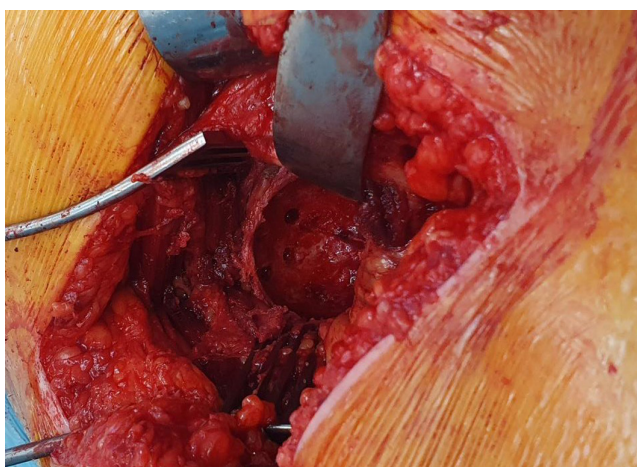


Figure 3
Appearance of the acetabulum following drill hole placement.



Figure 4
Example of the drill utilized for acetabulum cement hole creation.

sometimes with counterpressure on the buttock to allow the cup to be seated (Fig. 9). If it does not sit appropriately, always be prepared to remove the cup and cement quickly to restart the process. The leg and implants must be held still during the curing phase as any motion can lead to changes in the implant position, potentially creating voids in the cement mantle. Constant and steady pressure should be applied as the cement expands, to prevent changes in the implant position. During this time, curettes and Freer elevators can be used to score the edges of the cement and remove any excess with care not to remove cement between the implant and bone. Excess cement should also not touch the soft tissue and the drapes due to the heat generated by curing which may cause burns. Cement around the component can be checked for setting using a Freer elevator for firmness in addition to a more matte finish appearance. Finally, component positioning and fixation is checked with any excess cement removed

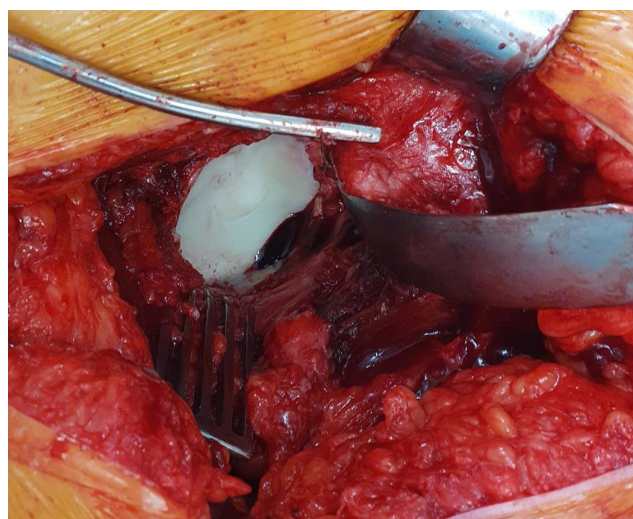


Figure 5
Bone cement placed into acetabulum after preparation.

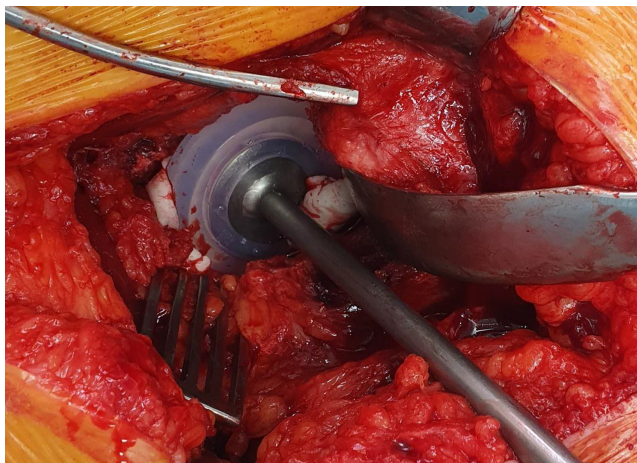


Figure 6
Pressurization of cement in the acetabulum with surrounding extruded cement.

with care using osteotomes, paying specific attention to the acetabular notch (Fig. 10).

Femoral preparation and cementation

The femur should be exposed with a clear view down the canal according to the selected approach, after preparation according to the selected implant type. Most instruments needed for further preparing the canal for cementation canal can be obtained from commercially available kits (Fig. 11). The bone surfaces should be cleaned using a combination of pulsatile lavage saline and a manual intramedullary brush (There is a risk of leaving plastic debris in the femoral canal after using the plastic brush.) (Fig. 12). A cement restrictor should be placed to seal the distal portion of the canal. Although different sizes are available, radial cuts can be made along the restrictor with scissors to allow insertion into a narrower canal. The restrictor should be placed approximately 1.5–2 cm distal to the stem to allow for an adequate distal cement mantle. The




Figure 7
Example of an all-polyethylene acetabular component.

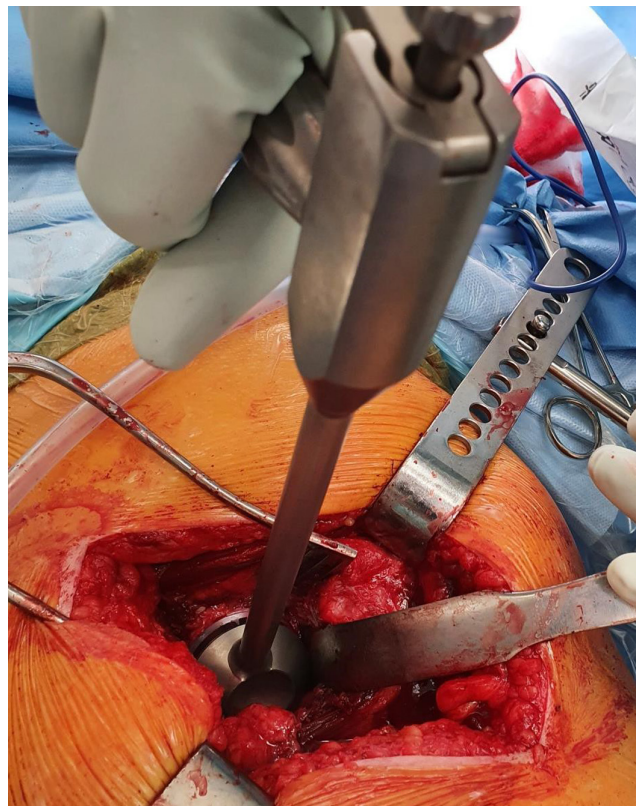

Figure 8
Acetabular component insertion using a holder.

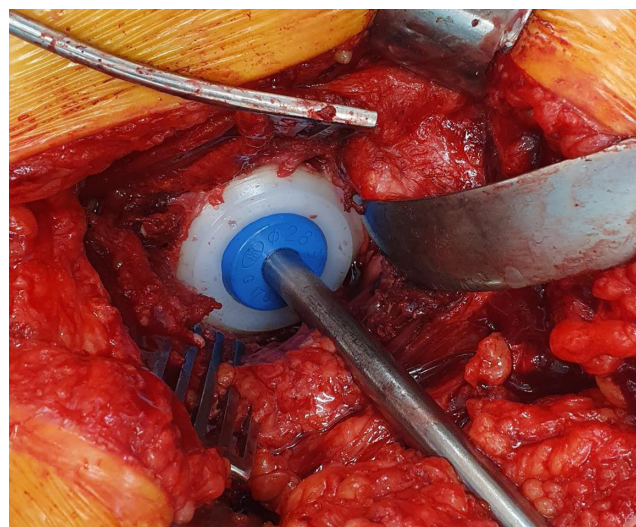


Figure 9
Pressurization of acetabular component with appropriate version and inclination according to the surrounding anatomical landmarks after excess cement has been cleared.

depth should be marked on the inserter for the restrictor (Fig. 13), and it is introduced in a controlled manner by gently tapping with a mallet. The inserter is removed with

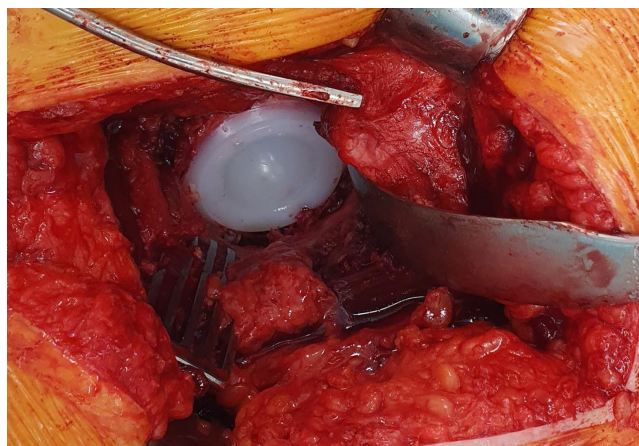


Figure 10
Final position of the cemented acetabular component with removal of excess cement.

counterclockwise rotation, and the restrictor position can be checked by re-inserting the broach if needed. The bone surface can be dried using epinephrine-soaked sponges or femoral sponge with suction attachment (Fig. 14). Prior to cementing, a sponge can be placed into the acetabulum to catch any loose cement.

It is important to prepare all instruments needed for stem insertion prior to mixing the cement due to the time-sensitive nature of the process (Fig. 15). This includes opening the femoral stem, attaching it to the introducer and trialing the disengagement mechanism. In the case of taper slip stems, the centralizer, which can be of varying sizes, should be attached. When the cement reaches the doughy stage (Fig. 16), it can be inserted into the canal in a retrograde fashion using the cement gun with the long nozzle. A small-bore nasogastric tube (10 or 12 French gauge) attached to suction tubing can also be placed

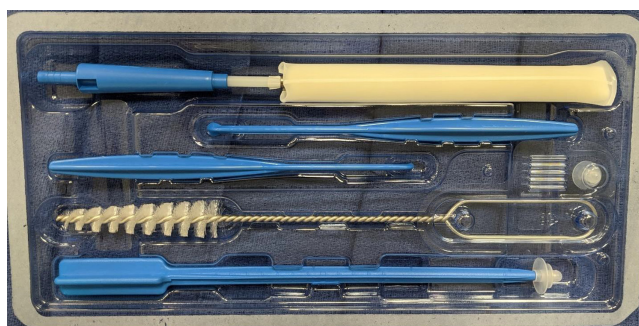

Figure 11
Example of a commercially available cement preparation kit. The components include (from top to bottom): femoral sponge with suction attachment, disposable cement sculps, femoral canal brush, universal and small canal restrictors, and a disposable restrictor inserter (BioPrep™ Bone Preparation Kit, Stryker Instruments).

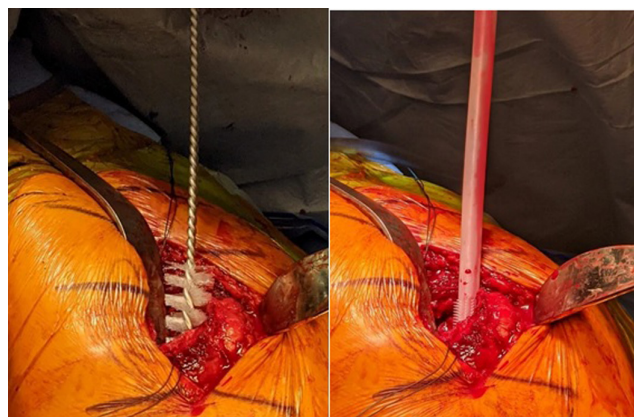


Figure 12
Mechanical cleaning of the femoral canal using either (A) manual brush or (B) a brush-tipped pulsed lavage (Interpulse Femoral Canal Brush, Styker Instruments).

into the canal and removed as the cement is inserted to reduce blood lamination and voids. Pressurization is achieved after retrograde insertion of the cement by snapping off the long nozzle of the cement gun, and (the previously attached) cement pressurizer is applied firmly to the proximal femur with counterpressure on the knee if needed while injecting the cement (Fig. 17). The distal cement restrictor creates a closed space, and leaking of the intramedullary canal fluid suggests that cement is being forced into the bone interstices with adequate pressurization. In more hemodynamically frail patients, thumb pressurization alone may be recommended to minimize the risk of embolic disease.

The femoral component is then inserted by hand using the introducer. The surgeon's thumb holds pressure over the medial calcar, helping to push the stem away from inadvertent varus positioning and allowing further pressurization of the cement (Fig. 18). After advancing the stem two-thirds of its length into the canal, excess cement is then cleared around the component. At this stage, alignment and anteversion are checked which allows for small corrections before seating the stem in



Figure 13
A cement restrictor attached to the inserter. The desired depth of the canal restrictor is marked out against a set point of the femoral stem (e.g. collar or shoulder) to allow for a 1.5–2 cm distal cement mantle.

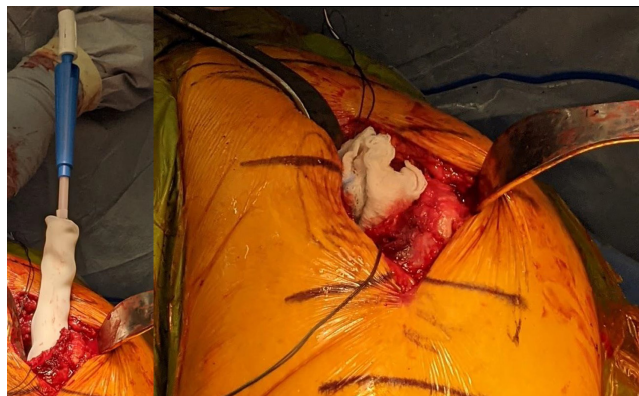

Figure 14

Drying the femoral canal. The femoral canal can be dried with (A) a femoral sponge with suction attachment or (B) by packing with epinephrine-soaked gauze.

its final position. Excess cement is then cleared using a Freer elevator, and the stem is held with gentle steady pressure while the leg is kept still to prevent change in position which alters the cement mantle, leaving voids and increasing the risk of failure. After curing, excess is removed using an osteotome with attention to the space in between the femur and acetabulum. Finally, the sponge in the acetabulum should be removed, with manual sweeping and irrigation for debris that can cause third body wear.

If there is difficulty seating the stem (or there is significant malposition), it should be removed with the intramedullary cement as quickly as possible, to avoid overlengthening and difficulty with reduction. A new mix

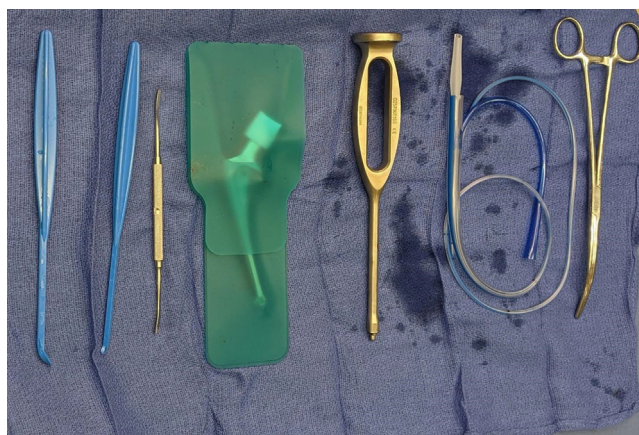


Figure 15

Instruments required for cementing the femoral stem. These should be placed in order of use on the Mayo stand and include (from left to right): curettes and elevator to scrape excess cement, a stem and insertion handle, a nasogastric tube to remove blood from canal during insertion, and a large clamp to remove packed sponges from canal.




Figure 16

Testing of the phase of cement curing prior to use. (A) Cement that is not ready for insertion will have a runny or sticky consistency. (B) Cement that is for insertion will have a doughy consistency with wrinkling on the surface and not stick to the surgical glove.

of cement should be prepared and the aforementioned steps repeated. If the stem needs to be replaced and the cement has cured, an option would be to remove the stem using an extractor, retain the cement mantle, and utilize a cement-in-cement technique with a smaller stem. Mallet impaction of the stem should be avoided at all times during insertion due to the risk of periprosthetic fracture.

Cement implantation syndrome

Bone cement implantation syndrome (BCIS) is an immediate complication of cementing components during THA. This occurs when intramedullary pressure from cementation forces medullary fat into the blood vessels. This typically occurs at high pressures (>300 mmHg) (20) and is most often seen in patients with pathological proximal femoral, including hip fractures (34). Rutter *et al.* report 62 cases in which death or severe harm was secondary to the use of cement during a hemiarthroplasty for a femoral neck fracture (37). Comorbidities, which increase the risk of BCIS, include cardiopulmonary disease and bony metastases which create a highly permeable and vascular bone surface (20). Sequelae of fat emboli include systemic hypotension, hypoxemia, pulmonary hypertension, cardiac arrhythmias, and cardiac arrest. There is up to a 16-fold increase in 30-day mortality (36). Fortunately, intraoperative mortality secondary to BCIS is rare, with one study reporting 23 cases among 38 488 THAs at a single institution over a 33-year period (21).

There is some evidence that low-viscosity cement decreases intramedullary pressure during femoral component cementation without compromising the pullout strength of the bone–cement–implant interface




Figure 17

Pressurization of the femoral cement. After retrograde insertion of femoral cement using a cement ‘gun’, the long-attachment nozzle is broken off a tight seal created using the gray pressurizer (Universal pressurizer, DePuy Orthopaedics, Warsaw, IN, USA) before further injecting cement.

compared to higher viscosity cement, theoretically reducing the risk of BCIS (20). Supportive management of BCIS can be effective in reducing morbidity and mortality. This involves the use of 100% inspired oxygen, aggressive fluid resuscitation including pre-loading the patient prior to cementation, and vasopressors to maintain

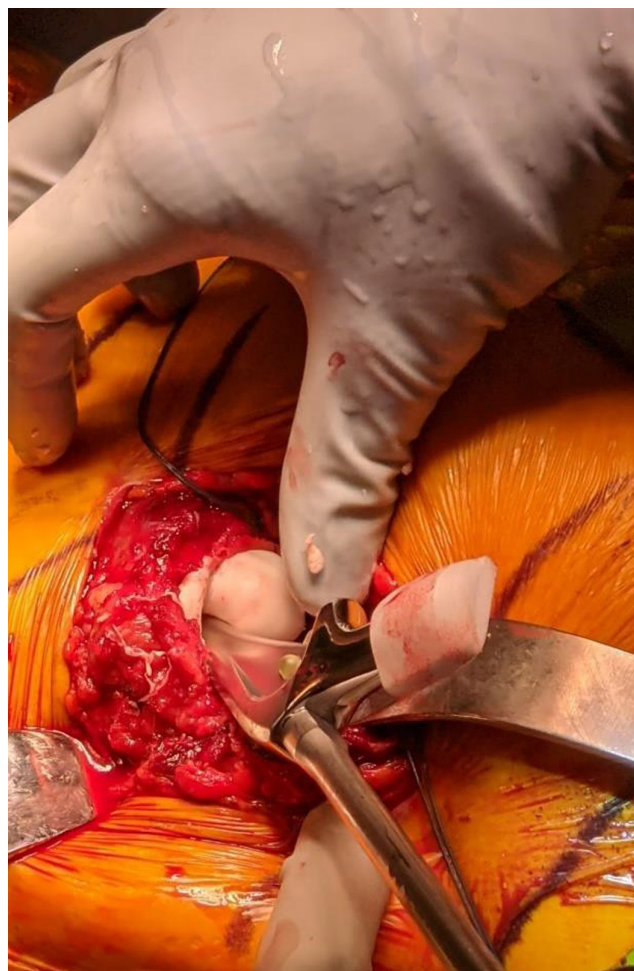

Figure 18

Insertion of the femoral stem using an insertion handle. The surgeon’s thumb is held over the medial calcar to prevent cement extrusion and help pressurization.

hemodynamic stability in high-risk patients (22). It is therefore important to communicate plans for cementing to anesthesiologists prior to the procedure and cementing to facilitate appropriate intervention and monitoring.

Outcomes of cemented THA

The trend of moving away from cemented THA continues despite excellent long-term outcomes with cemented implants. A large review of the Norwegian Arthroplasty Register showed that all THAs had a 96.7% survival rate, of which uncemented THAs had a 40% higher risk of all-cause revision compared to cemented THAs, predominantly for periprosthetic fracture and dislocation (23). Furthermore, the revision risk due to periprosthetic fracture was particularly increased in women over 55 years of age with an uncemented stem regardless of acetabular fixation (23). The success of cemented stems has been exemplified by

a single institution review of the Exeter Universal Stem (Stryker, Kalamazoo, MI, USA) in 382 hips with 99% survivorship from aseptic loosening at 20–25 years (24). These excellent long-term outcomes with decreased periprosthetic fracture rates make a compelling argument for using cemented femoral stems in THA.

From the National Joint Registry 18th Annual Report published in 2021, hip arthroplasty data were collected from all participating hospitals in England, Wales, Northern Ireland, the Isle of Man, and the States of Guernsey. This report documented primary hip operations performed between April 1, 2003, and December 31, 2020. There were 1 251 164 elective primary total hips during this time period. In their conclusion, between 2003 and 2007, cemented fixation was the most common, followed by uncemented fixation. Between 2008 and 2019, uncemented fixation was the most common, with hybrid fixation being the most common method in 2020. The breakdown included 31.3% all-cemented, 37.2% uncemented, 22.7% all-hybrid, 2.6% reverse hybrid, and 3.2% resurfacing groups, and 2.9 were unclassified. A total of 37 444 primary revisions, 3.0%, were performed during this time period. At 17 years since the primary procedure, the cumulative revision rates were 6.12% in all-cemented, 8.81% in all-uncemented, 5.87% in hybrid, 6.68% reverse hybrid, and 14.79% with resurfacing groups. Aseptic loosening was the most common reasons for revision in all parties. In evaluating the number of revisions per 1000 prosthesis-years with regard to aseptic loosening, the rate is 1.5 for all-cemented, 1.31 for uncemented, 0.51 for hybrid, 1.27 for reverse hybrid, and 2.19 for the resurfacing groups. With regard to periprosthetic fracture, the rate is 0.53 for all-cemented, 0.68 for uncemented, 0.89 for hybrid, 0.65 for reverse hybrid, and 1.10 for the resurfacing groups. With regard to implant wear, the rate is 0.18 for all-cemented, 0.34 for uncemented, 0.20 for hybrid, 0.23 for reverse hybrid, and 1.10 for the resurfacing groups.

From the American Joint Replacement Registry 8th Annual Report published in 2021, hip arthroplasty data were collected from over 1150 institutions in the United States. This report documented primary hip operations performed between 2012 and 2020. There were 752 440 total hip arthroplasties and 61 214 revisions performed during this period. Only 4.2% of all elective primary total hip arthroplasties used cemented femoral component fixation. In 2012, surgeons only cemented the femoral stem 2.8% of the time when compared to 5.8% in 2020. Cemented femoral components had higher cumulative percent revisions in males but lower in females (age/gender-adjusted hazard ratio of cemented vs cementless is 1.414 in males and 0.728 in females). Adjusting for age and gender, cemented femoral fixation showed a significant reduction in early revision due to periprosthetic

fracture compared to cementless fixation (age/gender-adjusted hazard ratio of cemented vs cementless is 0.208).

Overall, when evaluating most large registries with regard to cemented femoral stems and the differences based on locations, the reported percentage is 5.8% in the American Joint Replacement Registry (AJRR; USA), 32.3% in the National Joint Registry (NJR; Europe), 39.2% in Australian Orthopaedic Association National Joint Replacement Registry, and 58% in the Swedish Hip Arthroplasty Registry.

The outcomes of cemented acetabular components are less clear. One study of 203 THAs using the Exeter Contemporary (Stryker) cemented acetabular component demonstrated excellent outcomes with no aseptic loosening or component migration at 12 years (25). A large meta-analysis of 26 576 THAs showed a decreased revision rate for cemented cups compared to uncemented cups (odds ratio (OR): 0.54); however, this difference did not persist after adjusting for age and other demographic variables (26). On the contrary, a single institution review comparing 12- to 18-year follow-up of 2156 THAs with various fixation techniques showed all-cemented components to have a higher revision rate (0.80/observed component years (OCY)) compared to hybrid components (0.51/OCY).(27). While the data are not as compelling as for cementing stems due to possible limited long-term survivorship, studies generally support the use of cemented acetabular components.

There is particular interest in using cemented stems in THA and hemiarthroplasty for femoral neck fracture due to the presence of poor bone quality, capacious canals, and increased risks of these patients for periprosthetic fracture. The American Academy of Orthopaedic Surgeons Clinical Practice guidelines cite moderate evidence supporting the use of cemented femoral stems among these patients due to this increased risk of periprosthetic fracture (28). Guidelines from the United Kingdom also recommend the use of cemented implants for arthroplasty after hip fracture (29). A large database review of 12 491 hemiarthroplasties performed for hip fracture demonstrated a lower risk of aseptic revision at 1 year between cemented (1.3%) and press-fit stems (3.0%), with no differences in 90-day mortality or other complications (30). A randomized control trial comparing 112 cemented to 108 press-fit hemiarthroplasties also showed a lower prevalence of periprosthetic fracture with cemented (0.9%) compared to uncemented stems (7.4%) at 5 years (31). Similar results were again seen in a meta-analysis of 950 hemiarthroplasties with uncemented stems having greater complications compared to cemented stems (OR: 1.61) at 1 to 5 years (32). This difference was largely driven by implant-related complications such as fracture, loosening, and dislocation (OR: 3.15) (32). While there

are good outcomes for both cemented and press-fit stems in hip fractures, the former show superior outcomes with lower complications and thus are preferred according to national and international guidelines.

Conclusions

THA is a remarkably successful operation for managing patients with end-stage hip arthritis. PMMA bone cement, which has been used since the early iterations of modern THA, has been falling out of favor in recent years compared to uncemented components. Despite this trend, these cemented components still demonstrate excellent results, particularly for femoral stems and for hip fracture surgery. It is therefore important for orthopedic surgeons to understand the properties and techniques associated with cementing implants in THA.

ICMJE Conflict of Interest Statement

The authors declare that there is no conflict of interest that could be perceived as prejudicing the impartiality of the research reported.

Funding

This research did not receive any specific grant from any funding agency in the public, commercial, or not-for-profit sector.

Author contribution statement

All the authors of this manuscript contributed significantly in all attributes.

References

1. Coventry MB. *Foreward. Hip Arthroplasty*. New York: Churchill Livingstone 1991.
2. Troelsen A, Malchau E, Sillesen N & Malchau H. A review of current fixation use and registry outcomes in total hip arthroplasty: the uncemented paradox. *Clinical Orthopaedics and Related Research* 2013 **471** 2052–2059. (<https://doi.org/10.1007/s11999-013-2941-7>)
3. Brand RA, Mont MA & Manring MM. Biographical sketch: Themistocles Gluck (1853–1942). *Clinical Orthopaedics and Related Research* 2011 **469** 1525–1527. (<https://doi.org/10.1007/s11999-011-1836-8>)
4. Charnley J. Anchorage of the femoral head prosthesis to the shaft of the femur. *Journal of Bone and Joint Surgery. British Volume* 1960 **42-B** 28–30. (<https://doi.org/10.1302/0301-620x.42b1.28>)
5. Halawa M, Lee AJ, Ling RS & Vangala SS. The shear strength of trabecular bone from the femur, and some factors affecting the shear strength of the cement-bone interface. *Archives of Orthopaedic and Traumatic Surgery. Archiv Fur Orthopadische und Unfall-Chirurgie* 1978 **92** 19–30. (<https://doi.org/10.1007/BF00381636>)
6. Lange DR. The mechanical bonding of methylmethacrylate to cancellous bone. Effect of a hemostatic agent. *Journal of Bone and Joint Surgery. American Volume* 1979 **61** 254–256. (<https://doi.org/10.2106/00004623-197961020-00016>)
7. Cooke FWC, GB, Lunceford EM & Sauer BW. The influence of surgical technique on the strength of cement fixation. 24th Annual Meeting of the Orthopaedic Research Society. Dallas, Texas, 1978.
8. Hungerford DS & Krackow KA. A convenient distal plug for the femoral cavity in total hip arthroplasty. *Clinical Orthopaedics and Related Research* 1981 **154** 329–330. (<https://doi.org/10.1097/00003086-198101000-00063>)
9. Barrack RL, Mulroy RD, Jr & Harris WH. Improved cementing techniques and femoral component loosening in young patients with hip arthroplasty. A 12-year radiographic review. *Journal of Bone and Joint Surgery. British Volume* 1992 **74** 385–389. (<https://doi.org/10.1302/0301-620X.74B3.1587883>)
10. Krause WR, Krug W & Miller J. Strength of the cement-bone interface. *Clinical Orthopaedics and Related Research* 1982 **163** 290–299. (<https://doi.org/10.1097/00003086-198203000-00043>)
11. Majkowski RS, Miles AW, Bannister GC, Perkins J & Taylor GJ. Bone surface preparation in cemented joint replacement. *Journal of Bone and Joint Surgery. British Volume* 1993 **75** 459–463. (<https://doi.org/10.1302/0301-620X.75B3.8496223>)
12. Wixson RL, Lautenschlager EP & Novak MA. Vacuum mixing of acrylic bone cement. *Journal of Arthroplasty* 1987 **2** 141–149. ([https://doi.org/10.1016/s0883-5403\(87\)80021-9](https://doi.org/10.1016/s0883-5403(87)80021-9))
13. Ritter MA & Thong AE. The role of cemented sockets in 2004: is there one? *Journal of Arthroplasty* 2004 **19**(4)(Supplement 1) 92–94. (<https://doi.org/10.1016/j.arth.2004.02.006>)
14. Harris WH & Maloney WJ. Hybrid total hip arthroplasty. *Clinical Orthopaedics and Related Research* 1989 **249** 21–29. (<https://doi.org/10.1097/00003086-198912000-00004>)
15. Jones LC & Hungerford DS. Cement disease. *Clinical Orthopaedics and Related Research* 1987 **225** 192–206. (<https://doi.org/10.1097/00003086-198712000-00016>)
16. Lehil MS & Bozic KJ. Trends in total hip arthroplasty implant utilization in the United States. *Journal of Arthroplasty* 2014 **29** 1915–1918. (<https://doi.org/10.1016/j.arth.2014.05.017>)
17. Bargar WL, Heiple KG, Weber S, Brown SA, Brown RH & Kotzar G. Contrast bone cement. *Journal of Orthopaedic Research: Official Publication of the Orthopaedic Research Society* 1983 **1** 92–100. (<https://doi.org/10.1002/jor.1100010112>)
18. Kuehn KD, Ege W & Gopp U. Acrylic bone cements: composition and properties. *Orthopedic Clinics of North America* 2005 **36** 17–28. (<https://doi.org/10.1016/j.ocl.2004.06.010>)
19. Sayeed Z, Padela MT, El-Othmani MM & Saleh KJ. *Acrylic Bone Cements for Joint Replacement*, 2nd ed. **9**, pp. 199–214: Amsterdam: Elsevier Ltd 2017.
20. Rothberg DL, Kubiak EN, Peters CL, Randall RL & Aoki SK. Reducing the risk of bone cement implantation syndrome during femoral arthroplasty. *Orthopedics* 2013 **36** e463–e467. (<https://doi.org/10.3928/01477447-20130327-23>)
21. Parvizi J, Holiday AD, Ereth MH & Lewallen DG. The Frank Stinchfield award. Sudden death during primary hip arthroplasty. *Clinical Orthopaedics and Related Research* 1999 **369** 39–48. (<https://doi.org/10.1097/00003086-199912000-00005>)
22. Donaldson AJ, Thomson HE, Harper NJ & Kenny NW. Bone cement implantation syndrome. *British Journal of Anaesthesia* 2009 **102** 12–22. (<https://doi.org/10.1093/bja/aen328>)

- 23. Dale H, Børsheim S, Kristensen TB, Fenstad AM, Gjertsen JE, Hallan G, Lie SA & Furnes O.** Fixation, sex, and age: highest risk of revision for uncemented stems in elderly women – data from 66,995 primary total hip arthroplasties in the Norwegian Arthroplasty Register. *Acta Orthopaedica* 2020 **91** 33–41. (<https://doi.org/10.1080/17453674.2019.1682851>)
- 24. Petheram TG, Whitehouse SL, Kazi HA, Hubble MJ, Timperley AJ, Wilson MJ & Howell JR.** The Exeter Universal cemented femoral stem at 20 to 25 years: a report of 382 hips. *Bone and Joint Journal* 2016 **98–B** 1441–1449. (<https://doi.org/10.1302/0301-620X.98B11.37668>)
- 25. Maggs JL, Smeatham A, Whitehouse SL, Charity J, Timperley AJ & Gie GA.** The Exeter Contemporary flanged cemented acetabular component in primary total hip arthroplasty. *Bone and Joint Journal* 2016 **98–B** 307–312. (<https://doi.org/10.1302/0301-620X.98B3.35901>)
- 26. Toossi N, Adeli B, Timperley AJ, Haddad FS, Maltenfort M & Parvizi J.** Acetabular components in total hip arthroplasty: is there evidence that cementless fixation is better? *Journal of Bone and Joint Surgery. American Volume* 2013 **95** 168–174. (<https://doi.org/10.2106/JBJS.K.01652>)
- 27. Fowler AK, Gray AR & Gwynne-Jones DP.** Hybrid fixation for total hip arthroplasty showed improved survival over cemented and uncemented fixation: a single-center survival analysis of 2156 hips at 12–18 years. *Journal of Arthroplasty* 2019 **34** 2711–2717. (<https://doi.org/10.1016/j.arth.2019.06.031>)
- 28.** American Academy of Orthopaedic Surgeons. Management of hip fractures in the elderly evidence-based clinical practice guidelines. Available at: <https://www.aaos.org/globalassets/quality-and-practice-resources/hip-fractures-in-the-elderly/hip-fractures-elderly-clinical-practice-guideline-4-24-19--2.pdf>. Accessed April 26, 2021 2014.
- 29.** National Clinical Guideline Centre: Management of Hip Fracture in Adults. Available at: www.ncgc.ac.uk. Accessed April 26 2021 2011.
- 30. Okike K, Chan PH, Prentice HA, Paxton EW & Burri RA.** Association between uncemented vs cemented hemiarthroplasty and revision surgery among patients with hip fracture. *JAMA* 2020 **323** 1077–1084. (<https://doi.org/10.1001/jama.2020.1067>)
- 31. Langslet E, Frihagen F, Opland V, Madsen JE, Nordsletten L & Figved W.** Cemented versus uncemented hemiarthroplasty for displaced femoral neck fractures: 5-year followup of a randomized trial. *Clinical Orthopaedics and Related Research* 2014 **472** 1291–1299. (<https://doi.org/10.1007/s11999-013-3308-9>)
- 32. Veldman HD, Heyligers IC, Grimm B & Boymans TA.** Cemented versus cementless hemiarthroplasty for a displaced fracture of the femoral neck: a systematic review and meta-analysis of current generation hip stems. *Bone and Joint Journal* 2017 **99–B** 421–431. (<https://doi.org/10.1302/0301-620X.99B4.BJJ-2016-0758.R1>)
- 33. Mulroy WF, Estok DM & Harris WH.** Total hip arthroplasty with use of so-called second generation cementing techniques. *Journal of Bone and Joint Surgery. American Volume* 1995 **77** 1845–1852. (<https://doi.org/10.2106/00004623-199512000-00008>)
- 34. Olsen F, Kotyra M, Houltz E & Ricksten SE.** Bone cement implantation syndrome in cemented hemiarthroplasty for femoral neck fracture: incidence, risk factors, and effect on outcome. *British Journal of Anaesthesia* 2014 **113** 800–806. (<https://doi.org/10.1093/bja/aeu226>)
- 35. Bunyoz KI, Malchau E, Malchau H & Troelsen A.** Has the use of fixation techniques in THA changed in this decade? The uncemented paradox revisited. *Clinical Orthopaedics and Related Research* 2020 **478** 697–704. (<https://doi.org/10.1097/CORR.0000000000001117>)
- 36. Hines CB.** Understanding bone cement implantation syndrome. *AANA Journal* 2018 **86** 433–441.
- 37. Rutter PD, Panesar SS, Darzi A & Donaldson LJ.** What is the risk of death or severe harm due to bone cement implantation syndrome among patients undergoing hip hemiarthroplasty for fractured neck of femur? A patient safety surveillance study. *BMJ Open* 2014 **4** e004853. (<https://doi.org/10.1136/bmjopen-2014-004853>)
- 38. Abdel-Kader KF, Allcock S, Walker DI & Chaudhry SB.** Boneloc bone-cement: experience in hip arthroplasty during a 3-year period. *Journal of Arthroplasty* 2001 **16** 811–819. (<https://doi.org/10.1054/arth.2001.25561>)
- 39. Topoleski LD, Ducheyne P & Cuckler JM.** Microstructural pathway of fracture in poly(methyl methacrylate) bone cement. *Biomaterials* 1993 **14** 1165–1172. ([https://doi.org/10.1016/0142-9612\(93\)90162-u](https://doi.org/10.1016/0142-9612(93)90162-u))
- 40. Culletton P, Prendergast PJ & Taylor D.** Fatigue failure in the cement mantle of an artificial hip joint. *Clinical Materials* 1993 **12** 95–102. ([https://doi.org/10.1016/0267-6605\(93\)90056-d](https://doi.org/10.1016/0267-6605(93)90056-d))
- 41. Maloney WJ, Jasty M, Burke DW, O'Connor DO, Zalenski EB, Bragdon C & Harris WH.** Biomechanical and histologic investigation of cemented total hip arthroplasties. A study of autopsy-retrieved femurs after in vivo cycling. *Clinical Orthopaedics and Related Research* 1989 **249** 129–140.
- 42. Topoleski LD, Ducheyne P & Cuckler JM.** A fractographic analysis of in vivo poly(methyl methacrylate) bone cement failure mechanisms. *Journal of Biomedical Materials Research* 1990 **24** 135–154. (<https://doi.org/10.1002/jbm.820240202>)