

Single Case – General Neurology

Small Fiber Neuropathy Triggered by COVID-19 Vaccination: Association with FGFR3 Autoantibodies and Improvement during Intravenous Immunoglobulin Treatment

Maria Mastropaolo M. Joshua Hasbani

Neurology, Frank H Netter MD School of Medicine at Quinnipiac University, North Haven, CT, USA

Keywords

Small fiber neuropathy · Intravenous immunoglobulin · COVID-19 vaccination

Abstract

Multiple case series have demonstrated the emergence of small fiber neuropathy following acute coronavirus disease 2019 (COVID-19) infections. Further, one large case supports that the COVID-19 vaccine has been reported to result in small fiber neuropathy. We report a case of a patient with confirmed small fiber neuropathy post-COVID-19 vaccination with positive FGFR3 antibodies. The effect of intravenous immunoglobulin (IVIg) has been recently explored for treatment of presumed autoimmune small fiber neuropathy. To our knowledge, this is the first published case report of COVID vaccination-induced FGFR3-associated small fiber neuropathy improving in the context of IVIg administration as demonstrated by normalization of small fiber density measured by skin biopsy accompanied by marked improvement in the patient's symptoms.

© 2023 The Author(s)
Published by S. Karger AG, Basel

Introduction

Although the COVID-19 vaccination has helped protect many against the COVID-19 virus, the vaccine has been associated with some complications. There are published patient cases of COVID-19 infection and Pfizer and Moderna vaccine administration causing neurological conditions

Correspondence to:
Maria Mastropaolo, mfmastropaolo@quinnipiac.edu

including Guillain-Barre syndrome, transverse myelitis, and small fiber neuropathy [1–8]. The mechanism underlying the development of small fiber neuropathy after COVID-19 vaccination is not known. Therefore, effective treatment remains unclear. It is suspected that small fiber neuropathy occurring after administration of the COVID-19 vaccine could be an immune-mediated process [4]. There is evidence that TS-HDS and/or FGFR3 antibodies are present in patients with small fiber neuropathy related autonomic dysfunction and burning parasthesias [9]. Unlike distal presentations of GBS, small fiber neuropathy can have a non-length dependent presentation and oddly involve the face and even tongue early on [4, 10]. If symptoms of small fiber neuropathy after COVID-19 vaccination are immune-mediated and associated with autoantibodies including TS-HDS and FGFR3, we and others have hypothesized that patients can experience both clinical pain improvement and recovery of nerve fiber density after treatment with intravenous immunoglobulin (IVIg) [11]. We present a case of a young man who developed FGFR3-associated small fiber neuropathy who experienced marked clinical improvement accompanied by biopsy-proven normalization of skin fiber density after treatment with Gamunex IVIg. The CARE Checklist has been completed by the authors for this case report, attached as supplementary material (for all online suppl. material, see www.karger.com/doi/10.1159/000528566).

Case Report

A 39-year-old male without previous history of vaccine reaction presented 134 days after receiving the first dose of the Pfizer COVID-19 vaccination in his left deltoid with subacute onset of left arm pain and numbness. The pain initially presented as achy pain in the left shoulder and progressed to the entirety of the left arm after day 10 post-vaccination. The patient also began noticing numbness and tingling in the left arm, median forearm, ulnar hand, and medial scapular region. These symptoms generalized rapidly over 3 weeks post-vaccination and persisted after presentation at our clinic. Symptoms generalized to the patient's right side in a non-length dependent symmetrical distribution, involving the proximal arms and legs. He also developed fasciculations in his extremities that progressed to burning dysesthesias and numbness in all his extremities over the same 3-week timeframe. On review of systems, the patient denied fevers, chills, weight loss, neck pain, back pain, urinary/fecal incontinence, bulbar involvement, rash, and tick bites.

On neurological exam, the patient was alert and oriented to person, place, time, and situation. Cranial nerves were intact. Motor exam revealed normal bulk and tone with 5/5 strength in upper and lower extremities. Notably, sensation to temperature was decreased over the area of complaint. Coordination was appropriate as determined by finger-nose-finger and heel-to-shin testing. Gait, including tandem gait, was normal, and Romberg was negative.

Normal electrodiagnostic study was performed 163 days after onset of symptoms (including right median, ulnar, peroneal, and tibial motor nerves; right median, sural, ulnar, and superficial radial sensory nerves; and needle examination of the right rectus femoris, vastus medialis, vastus lateralis, tibialis anterior, gastrocnemius, deltoid, biceps, triceps, extensor digitorum communis, and first dorsal interosseous muscles) with symptoms at this point equally generalized on the right and left upper and lower extremities. Skin biopsy collected 148 days after symptom onset to test epidermal nerve fiber density of the left calf, and left foot was abnormal (Fig. 1a). Left calf epidermal nerve fiber density was 2.95 (normal >4), and left foot epidermal nerve fiber density was 1.83 (normal >3). See Figure 1. Additionally, sweat gland nerve fiber density of the distal left arm was 7.4 (normal >39) and sweat gland nerve fiber density of the left calf was 3.0 (normal >36.5).

The following laboratory tests were normal or negative: complete blood count, comprehensive metabolic profile, hemoglobin A1c, vitamin B12, thyroid-stimulating hormone, Lyme

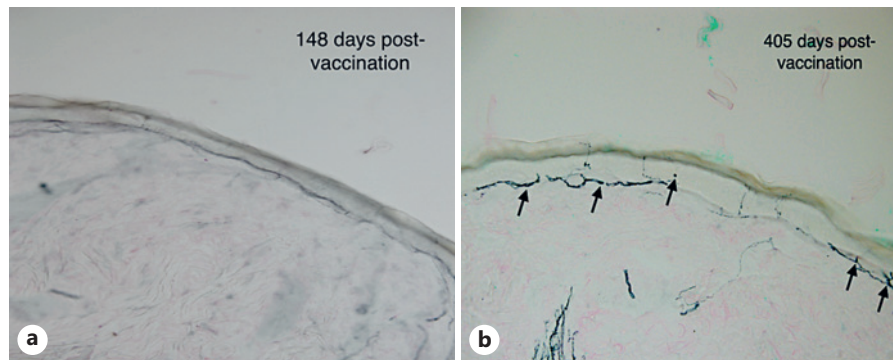


Fig. 1. Representative images from vertical sections from left calf (50 micron; anti-PGP9.5). **a** Note paucity of epidermal neurites on post-COVID day 131 before IVIG initiation. Left calf epidermal nerve fiber density: 2.95 (normal >4). Left foot epidermal nerve fiber density: 1.83 (normal >3). Sweat gland nerve fiber density of the distal left arm: 7.4 (normal >39). Sweat gland nerve fiber density: 3.0 (normal >36.5). **b** Increased epidermal neurites on day 162 of IVIG treatment (arrows). Left calf epidermal nerve fiber density: 8. Left foot epidermal nerve fiber density: 5.62. Sweat gland nerve fiber density test of the left foot: 20.5 (normal >3.48). Images provided by Dr. Jamie Jacobsohn, Therapath Inc (NY, USA).

disease antibodies, *Babesia duncani* antibody, *Ehrlichia chaffeensis* antibody, *Anaplasma phagocytophilum* antibody, *Bartonella* species antibody, antinuclear antibody screen, serum immunofixation, and protein electrophoresis. Neuromuscular antibody report from Washington University School of Medicine was notably positive for IgG versus FGFR3 of 17,000 (nrl <3,000) and negative for all other autoantibodies in the sensory neuropathy/neuronopathy panel (Fig. 2).

Based on these results, the patient was diagnosed with COVID vaccination-induced FGFR3 small fiber neuropathy and was treated with IVIG. The patient began receiving 45 g Gamunex IVIG daily \times 2 days q 4 weeks delivered over 3.5 h each day 290 days following onset of symptoms. Follow-up physical exam was within normal limits, and temperature sensation was restored in the affected areas. Repeat skin biopsy 405 days post-vaccination and status post-three IVIG sessions revealed a normal epidermal nerve fiber density of the left calf and left foot (8 and 5.62, respectively) (Fig. 1b). Sweat gland nerve fiber density test of the left foot was also still abnormal at a value of 20.5. At patient follow-up 430 days after symptom onset, he reported marked improvement of symptoms including numbness and pain.

Conclusion

There is strong epidemiological data suggesting that COVID vaccination can cause neuropathies such as Guillain-Barre syndrome [6]. Small fiber neuropathy, unlike Guillain-Barre syndrome and chronic inflammatory polyneuropathy, is not an established post-inflammatory or autoimmune condition [12] nor is it an FDA-approved condition for IVIG. This is particularly relevant since many patients have suffered with idiopathic small fiber neuropathies and can only be treated palliatively with non-narcotic nerve pain medication. Recent research has shown that retrospective evaluation of these idiopathic patients has led to the discovery of a significant proportion having autoantibodies [9] and that at least some of these neuropathies may therefore have an autoimmune basis. There have been case reports of small fiber neuropathy developing following viral infections such as Coxsackie B3, Coxsackie B5, and influenza A, H3N2 viruses [13], and most recently with COVID vaccination [1]. A proportion of these patients have identifiable autoimmune antibodies. It is likely that molecular mimicry is one pathophysiological mechanism underlying development of these

Report Date: 11/10/2021

Sensory Neuropathy/Neuronopathy Panel

<u>Antibody</u>	<u>Patient Values</u>	<u>Normal Values</u>
IgM vs GD1b	0	<3000
IgG vs GM1	0	<2000
IgG vs Sulfatide	0	<3000
IgM vs Sulfatide	0	<3000
IgM vs MAG	0	<3000
MAG Western Blot		Negative
IgM vs TS-HDS	0	<10,000
IgG vs FGFR3	17,000	<3000
IgM vs Histone H3	0	<5000
IgM vs GD1a	0	<2000
IgG vs Hu (Western Blot & IHC)	Negative	Negative
IgG vs CRMP-5 (Western Blot)	Negative	Negative

INTERPRETATION: IgG in this serum binds Fibroblast Growth Factor Receptor-3 (FGFR3) by ELISA assay. Serum IgG binding to FGFR3 has been associated with Axonal Sensory Neuropathies. Some patients have sensory ataxia or pain.

Fig. 2. Washington University School of Medicine Neuromuscular Clinical Laboratory: sensory neuropathy/ neuronopathy panel.

neuropathies given the presence of autoimmune antibodies associated with these conditions. Whether these antibodies participate in the disease or are epiphenomenon still needs to be established, but nonetheless suggest an inflammatory state. FGFR3 antibody-associated small fiber neuropathy has been described as affecting small fibers in the lower extremities predominantly sparing large fibers [14]. As further cases of FGFR3-associated small fiber neuropathy emerge, description of the clinical features of these cases may help distinguish this condition from other sensory neuropathies. It then follows that immunotherapies such as IVIG may be one effective treatment for these conditions as well.

We report the first case of recovery from FGFR3-associated small fiber neuropathy after COVID vaccination vis-a-vis restoration of nerve fiber density by biopsy. Although it is unclear whether this patient improved spontaneously or through intervention with IVIG, that patients can recover provides hope for resolution of these patients' suffering. In addition, the case report raises the hypothesis that IVIG might treat COVID-19 vaccination-induced small fiber neuropathy. FDA approval will depend on whether larger clinical trials can establish the efficacy of IVIG for antibody-mediated small fiber neuropathy.

Acknowledgments

We would like to acknowledge the contribution of Dr. Alan Pestronk and the Washington University School of Medicine Neuromuscular Laboratory in processing and testing patient serum and making diagnosis.

Statement of Ethics

Subjects have given their written informed consent to publish their case including images. Information revealing the subject's identity was avoided. Ethical approval is not required for this study in accordance with local or national guidelines. Written informed consent was obtained from participants for publication of the details of their medical case and any accompanying images.

Conflict of Interest Statement

The authors have no conflicts of interest to declare.

Funding Sources

No funding received.

Author Contributions

Maria Mastropaolo and Dr. Josh Hasbani were involved in writing and editing this case report along with analysis of data. The patient described in this case report is under the neurological care of Dr. Josh Hasbani.

Data Availability Statement

All data generated or analyzed during this study are included in this article. Further inquiries can be directed to the corresponding author.

References

- 1 Waheed W, Carey ME, Tandan SR, Tandan R. Post COVID-19 vaccine small fiber neuropathy. *Muscle and Nerve*. 2021;64(1):E1–2.
- 2 Khokhar F, Khan A, Hussain Z, Yu J. Small fiber neuropathy associated with the Moderna SARS-CoV-2 vaccine. *Cureus*. 2022;14(6):e25969–2.
- 3 Oaklander AL, Mills AJ, Kelley M, Toran LS, Smith B, Dalakas MC, et al. Peripheral neuropathy evaluations of patients with prolonged long COVID. *Neurol Neuroimmunol Neuroinflamm*. 2022 May 1;9(3):e1146.
- 4 Safavi F, Gustafson L, Walitt B, Lehky T, Dehbashi S, Wiebold A, et al. Neuropathic symptoms with SARS-CoV-2 vaccination. *medRxiv*. 2022;202205.16.22274439.
- 5 Lahoz Fernandez PE, Miranda Pereira J, Fonseca Risso I, Baleeiro Rodrigues Silva P, Freitas Barboza IC, Vieira Silveira CG, et al. Guillain-Barre syndrome following COVID-19 vaccines: a scoping review. *Acta Neurol Scand*. 2022 Apr 1;145(4):393–8.
- 6 Keh RYS, Scanlon S, Datta-Nemdharry P, Donegan K, Cavanagh S, Foster M, et al. COVID-19 vaccination and Guillain-Barré syndrome: analyses using the National Immunoglobulin Database. *Brain*. 2022 Feb 18;awac067.
- 7 Novak P, Giannetti MP, Weller E, Hamilton MJ, Mukerji SS, Alabsi HS, et al. Network autonomic analysis of post-acute sequelae of COVID-19 and postural tachycardia syndrome. *Neurol Sci*. 2022;43(12):6627–38.
- 8 Abrams RMC, Simpson DM, Navis A, Jette N, Zhou L, Shin SC. Small fiber neuropathy associated with SARS-CoV-2 infection. *Muscle Nerve*. 2022;65(4):440–3.
- 9 Trevino JA, Novak P. TS-HDS and FGFR3 antibodies in small fiber neuropathy and Dysautonomia. *Muscle Nerve*. 2021 Jul 1;64(1):70–6.
- 10 Gemignani F, Bellanova F, Saccani E, Pavesi G. Non-length-dependent small fiber neuropathy: not a matter of stockings and gloves. *Muscle Nerve*. 2022;65(1):10–28.
- 11 Gibbons C. IVIg for small fiber neuropathy with autoantibodies TS-HDS and FGFR3. *Clinicaltrials.gov*. 2021 Apr 19.
- 12 Kumar SS, Yong MH, Koh YH. Small fiber neuropathy in a patient with coronavirusdisease 2019 (COVID-19). *Neurol Asia*. 2022;27(1):195–7.
- 13 Tsakadze N, Catania J, Hoffmann M, Benes-lima L, Estevez AG, Franco MC. Case report: length-dependent small fiber polyneuropathy caused by Coxsackie and Influenza virus Co- infection. 2019;103–5.
- 14 Tholance Y, Moritz CP, Rosier C, Ferraud K, Lassablière F, Reynaud-Federspiel E, et al. Clinical characterisation of sensory neuropathy with anti-FGFR3 autoantibodies. *J Neurol Neurosurg Psychiatry*. 2020 Jan 1;91(1):49–57.