

## Horizontal Liver Cleft: A Rare Anatomic Variant

Department of Diagnostic Radiology, Tan Tock Seng Hospital, Singapore, Singapore

Authors' Contribution:  
Study Design A  
Data Collection B  
Statistical Analysis C  
Data Interpretation D  
Manuscript Preparation E  
Literature Search F  
Funds Collection G

E **Yong Han Ting**  
E **Kian Soon Lim**

**Corresponding Author:** Yong Han Ting, e-mail: [tingyonghan@gmail.com](mailto:tingyonghan@gmail.com)  
**Conflict of interest:** None declared

**Patient:** Female, 74  
**Final Diagnosis:** Horizontal liver cleft  
**Symptoms:** —  
**Medication:** —  
**Clinical Procedure:** —  
**Specialty:** Surgery

**Objective:** Congenital defects/diseases

**Background:** Improvements in hepatobiliary surgical techniques, with increased usage of segmental and subsegmental resection, make accurate preoperative radiological assessment delineation of the liver segments ever more crucial. Conventionally, this is done by drawing imaginary straight planes along the portal and hepatic veins. We herein report a rare case of a horizontal cleft between the superior and inferior liver segments seen on CT.

**Case Report:** A 74-year-old female patient with a known medical history of ovarian cancer with peritoneal metastasis and retroperitoneal lymphadenopathy was referred to our department for CT to assess disease response after treatment. On contrast-enhanced CT, apart from the ovarian cancer, the liver had a smooth, well-defined horizontally orientated cleft that broadly divided the organ into 2 halves. The cleft contained the right and left main portal veins, and consequently had a curved down-sloping configuration accommodating the curved course of these veins. This liver cleft was present from an earlier CT study performed 3 years ago, and there was no history of preceding liver surgery.

**Conclusions:** To the best of our knowledge, this is the first report of the anomaly of a horizontal liver cleft, which may be attributed to early cessation of the embryological formation of the liver. This liver cleft also illustrates the difficulties in liver segmentation using Couinaud's classification.

**MeSH Keywords:** Congenital Abnormalities • Liver • Radiology


**Full-text PDF:** <http://www.amjcaserep.com/abstract/index/idArt/892274>



784



4



10



## Background

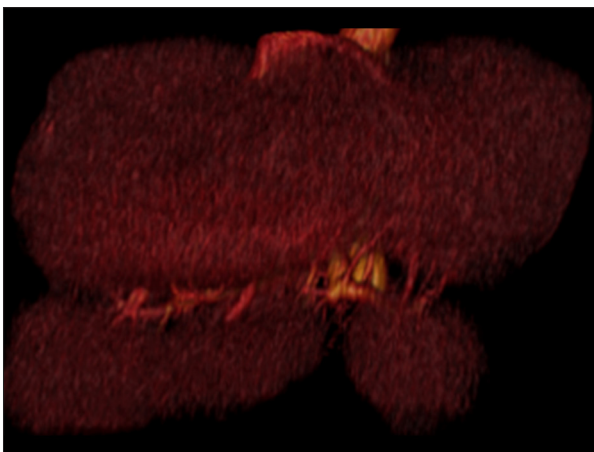Improvements in hepatobiliary surgical techniques, with increased usage of segmental and subsegmental resection, make accurate preoperative radiological assessment delineation of the liver segments ever more crucial. Conventionally, this is done by drawing imaginary straight planes along the portal and hepatic veins, but this is riddled with substantial reported inaccuracies.

In this report, we present a case of an incidental cleft between the superior and inferior liver segments. This patient with an unusual liver cleft illustrates the difficulties in liver segmentation using Couinaud's classification, as discussed below. Its not-so-straight configuration may be a case in point against using straight planes in liver segmentation.

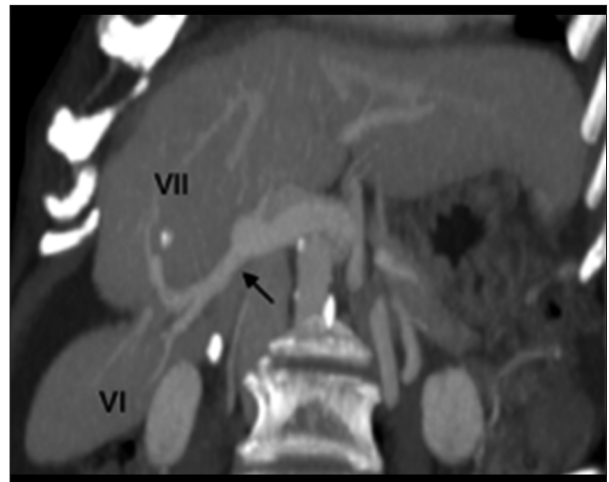
## Case Report

We report a 74-year-old female ovarian cancer patient of with peritoneal metastasis and retroperitoneal lymphadenopathy.

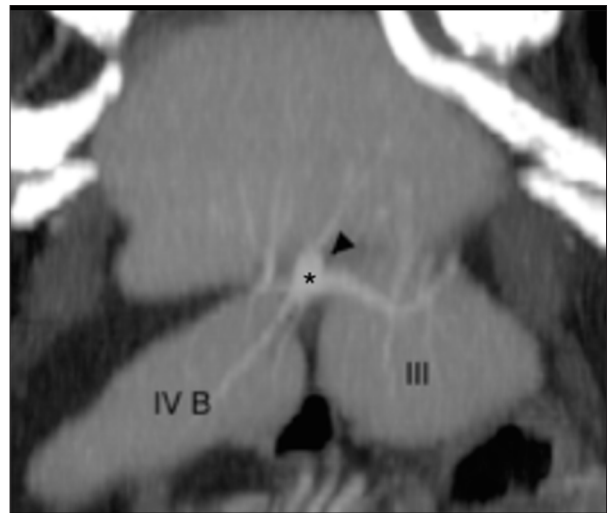On contrast-enhanced CT, apart from the ovarian cancer, we noted the liver had a smooth, well-defined, horizontally orientated cleft that broadly divided the organ into 2 halves (Figure 1). The cleft contained the right and left main portal veins, and consequently had a curved down-sloping configuration accommodating the curved course of these veins. Within the cleft, each portal vein gave rise to respective sectorial branches (Figures 2 and 3). The later in turn gave rise to respective segmental branches that were seen penetrating the liver segments. This liver cleft was present from an earlier CT study performed 3 years ago, and there was no history of preceding liver surgery.



**Figure 1.** 3D construction of the CT demonstrates a horizontal “open-lipped” cleft through both lobes of the liver, containing blood vessels.



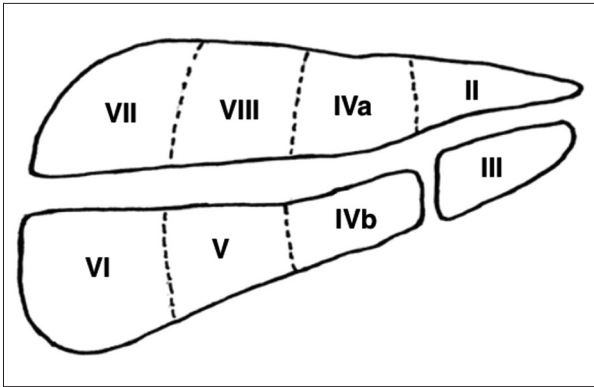
**Figure 2.** MIP (maximal intensity projection) CT shows the cleft containing the posterior sectorial branch (arrow) of the right portal vein, which in turn gives rise to segment 7 and 6 portal venules, respectively. The segmental veins are seen penetrating the respective liver segments.



**Figure 3.** MIP CT shows the cleft containing the left portal vein (arrowhead) and the medial sectorial branch (asterisk), which in turn gives rise to segment 4B and 3 portal venules, respectively. The segmental veins are seen penetrating the respective liver segments.

## Discussion

Hepatobiliary surgery is an evolving field, and with the increased application of segmental and subsegmental liver resection for malignant conditions there has been an increase in the demand for accurate radiological segmentation of the liver. Each segment is a self-contained unit of the liver, with centrally positioned branches of the portal vein, hepatic artery, and bile duct, and vascular outflow through the hepatic veins in its periphery [1].



**Figure 4.** Schematic diagram of the liver segments in relation to the liver cleft.

Historically, there have been a number of descriptions of hepatic segmentation, including those by Couinaud, Healy, and Schroy, Goldsmith and Woodburne, and Bismuth. [2–4]. Couinaud’s classification is most commonly used, and it employs imaginary straight planes, the portal and hepatic scissurae, to define the segments of the liver. The portal scissurae contain the vertically orientated hepatic veins, and the hepatic scissurae contain the portal pedicles. The hepatic scissurae divides the liver into cranial and caudal divisions. As this classification uses arbitrary planes to divide the liver into different segments, there are several factors that cause inaccuracies in the radiological determination of the liver segments.

Other authors have also shown discrepancies between the radiological segmentation and intra-operative findings. Nelson et al. [5] showed that CT localization disagreed with the extent observed at surgical resection in 11 of 36 (31%) lesions, and Soyer et al. [6] reported discrepancy in 8 of 36 (22%) cases. There are many areas of discrepancies in liver segmentation, most concerning the right lobe of the liver [7]. In particular, there is difficulty differentiating between segment 6 and segment 7. The assumption that the hepatic scissurae is linear and horizontal causes this difficulty.

## References:

1. Sexton CC, Zeman RK: Correlation of computed tomography, sonography, and gross anatomy of the liver. *Am J Roentgenol*, 1983; 141: 711–18
2. Fasel JH, Gailloud P, Terrier F et al: Segmental anatomy of the liver: a review and a proposal for an international working nomenclature. *Eur Radiol*, 1996; 6: 834–37
3. Soyer P: Segmental anatomy of the liver: utility of a nomenclature accepted worldwide. *Am J Roentgenol*, 1993; 161: 572–73
4. Bismuth H: Surgical anatomy and anatomical surgery of the liver. *World J Surg*. Springer-Verlag, 1982; 6(1):3–9
5. Nelson RC, Chezmar JL, Sugarbaker PH et al: Preoperative localization of focal liver lesions to specific liver segments: utility of CT during arterial portography. *Radiology*, 1990; 176: 89–94
6. Soyer P, Roche A, Gad M et al: Preoperative segmental localization of hepatic metastases: utility of three-dimensional CT during arterial portography. *Radiology*, 1991; 180: 653–58
7. Strunk H, Stuckmann G, Textor J, Willinek W: Limitations and pitfalls of Couinaud’s segmentation of the liver in transaxial imaging. *Eur Radiol*, 2003; 13: 2472–82
8. Lamadé W, Glombitza G, Fischer L et al: The Impact of 3-Dimensional Reconstructions on Operation Planning in Liver Surgery. *Arch Surg*, 2000; 135: 1256–61
9. Diehl-Jones WL, Askin DF: The neonatal liver, Part 1: embryology, anatomy, and physiology. *Neonatal Netw*, 2002; 21: 5–12
10. Dodds WJ, Erickson SJ, Taylor AJ: Caudate lobe of the liver: anatomy, embryology, and pathology. *Am J Roentgenol*, 1990; 154(1): 87–93

The liver cleft seen in this patient appeared to coincide with the “perfusion boundary” between the cranial and caudal segments in each liver sector as defined by the segmental portal vein blood supply (Figure 4). This strengthens the long-held notion that this boundary is curved and down-sloping in configuration and not horizontal and straight, as radiologists assumed. This finding lends further support to authors who advocate the use of 3D reconstructions of the vascular anatomy to accurately delineate the different hepatic segments [8].

The liver has embryological origins from a ventral foregut diverticulum, and its development involves complex interactions between the mesoderm and the epithelial cells of the endoderm [9,10]. The liver is formed around vascular and biliary pedicles forming the lobules, sub-segments, segments, and lobes. The evolution is centrifugal and stops when it encounters the other segments. Early cessation isolates segments and gives the liver a lobular appearance. This change primarily affects the lateral connections of anterior segments but it can also affect the upper connections and it explains a possible separation of a segment from the rest of the liver. This understanding of liver embryology may explain the horizontal cleft reported in this case.

## Conclusions

We report a patient with a rare anomaly of a liver cleft that followed the planes of the first branches of the portal vein. This illustrates the difficulty of differentiating the superior and inferior hepatic segments, particularly in the right lobe of the liver. To the best of our knowledge, this is the first report of this anomaly, which may be attributed to early cessation of the embryological formation of the liver.

## Conflict of interest statement

The authors declare no financial grants received or conflict of interest with regards to this case report.