

Original
Article

Secondary Carina and Lobar Bronchi Stenting in Patients with Advanced Lung Cancer: Is It Worth the Effort? A Clinical Experience

Roberto Marchese, MD,^{1,2,3} Grazia Poidomani, MD,¹ Vincenzo Davide Palumbo, MD, PhD,^{4,5} Chiara Lo Nigro, MD,³ Umberto Caterino, MD,¹ Attilio Ignazio Lo Monte, MD, PhD,⁴ and Massimo Cajozzo, MD, PhD⁴

Background: The lobar airway stenting remains an endoscopic procedure not well standardized in patients with locally advanced lung cancer disease. The goal of this study was to evaluate technical feasibility, clinical outcome, and complications of different stents in patients with malignant lesions involving lobar bronchi, primary and secondary carina.

Methods: Between November 2008 and October 2013, we retrospectively analyzed 146 patients with benign and malignant tracheobronchial stenosis who underwent airway stent insertion below main carina and main bronchi.

Results: In all, 170 airway stenting procedures were performed on 146 patients. In all, 51 of them with malignant peripheral airway stenosis underwent stents placement below main carina. In all but one patient, the deployment of stents was successful with improvement of symptoms. The chest radiograph after the procedure detected the lung re-expansion in 29 of 51 patients. The mean follow-up duration was 123 days \pm 157. Complications observed included stent migration, tumor overgrowth, infections, granulation tissue formation, and obstruction due to tenacious secretions. Longer survival was observed in patients who received additional treatment after airway stenting compared to those who did not ($p < 0.01$).

Conclusions: Stenting of lobar bronchi and primary or secondary carina is technically feasible, effective, and acceptably safe.

Keywords: lung cancer, airway stenosis, airway stenting

¹Interventional Pulmonology Unit, La Maddalena Cancer Center, Palermo, Italy

²Surgical Oncology Unit, La Maddalena Cancer Center, Palermo, Italy

³Thoracic Surgery Unit, La Maddalena Cancer Center, Palermo, Italy

⁴Department of Surgical, Oncological and Oral Sciences, University of Palermo, Palermo, Italy

⁵Euro-Mediterranean Institute of Science and Technology, Palermo, Italy

Received: February 4, 2019; Accepted: February 19, 2020

Corresponding author: Vincenzo Davide Palumbo, Department of Surgical, Oncological and Oral Sciences, University of Palermo, Via Del Vespro 129, Palermo 90127, Italy

Email: vincenzodavide.palumbo@unipa.it



This work is licensed under a Creative Commons Attribution-NonCommercial-NoDerivatives International License.

©2020 The Editorial Committee of *Annals of Thoracic and Cardiovascular Surgery*

Introduction

Airway stenting is an appealing mini-invasive palliative treatment option for locally advanced lung cancer in patients with airway involvement.

Most of the experience reported in literature are regarding the major airways stenting (trachea, carina, and proximal major bronchi).¹⁾

There is not a wide literature regarding lobar airway or peripheral carina, like right carina 1 (RC1; carina between the bronchus of the right upper lobe and the bronchus intermedius), RC2 (carina between the right middle lobe bronchus and the lower lobe bronchus), or left carina 2 (LC2; carina between the bronchus of the lingular segment of the left upper lobe and the left lower

lobe bronchus) stenting in patients with malignant or benign airway diseases.^{2,3)}

Recently, Oki et al.^{4,5)} have introduced a new bifurcated silicone stent for the treatment of stenosis around primary and left secondary carina, showing that its placement is feasible, effective, and acceptably safe.

We report our experience with airway stenting in the management of malignant airway lesions involving lobar bronchi and peripheral carina.

Patients and Methods

From November 2008 to October 2013, 170 airway stenting procedures performed at the Interventional Pulmonology Unit of La Maddalena Cancer Center were reviewed retrospectively.

This study was approved by the Institutional Ethic Committee of Palermo “P. Giaccone” University Hospital (protocol number 18, 1/2015). A written informed consent was obtained from all the patients before undergoing the procedure.

Out of the total 146 patients suffering from malignant airway diseases and considered for our study, only 51 (mean age 67 years, range 45–85 years, male: 41), affected by advanced unresectable lung cancer involving lobar bronchi and distal carina (RC1, RC2, or LC2), were recruited for our purposes.

All patients with tumors involving large airways or extending from the peripheral bronchus were excluded from the study.

Prior to stent placement, a written informed consent was obtained by all the patients.

Before each airway stent placement, a flexible bronchoscopy was performed (model 1T-180; Olympus America Inc.; Melville, NY) to evaluate airway anatomy and to plan the best approach for the treatment. A preliminary computed tomography (CT) scan allowed to assess the presence of sparing lung parenchyma distal to the stenosis.

Both metallic and silicone stents were used: fully covered self-expandable metallic stent (SEMS) Silmet[®] (Novatech, La Ciotat, France); covered Ultraflex[®] (Boston Scientific, Natick, MA, USA); Dumon stents straight, Y-shape; and Oki stent (Novatech).

Stenting procedures were performed by rigid bronchoscope (Dumon-Harrell type; Bryan Corp; Woburn, MA) under general anesthesia and jet ventilation (t_0). The airway lumen was re-established combining mechanical debulking, balloon dilatation, and laser treatment (λ 980 nm Ceralas D50/980/600; Biolitech; Siemensstrasse Bonn; Germany).

When bronchial patency could not be maintained with only one stent, a double Y-stent was implanted in telescopic position.⁵⁾

The retention of secretions was prevented by teaching patients to perform inhalation with a simple inhaler or with the temporary positive expiratory pressure (TPEP) device UNIKO-T-PEP (Medical Products Research, Legnano, Italy) for 15 minutes, three times daily.⁶⁾

The primary endpoint was to evaluate the technical feasibility of stent placement, whereas the secondary one was considered the clinical success.

Patients' quality of life was evaluated by means of the Modified Medical Research Council (MMRC) dyspnea scale (0–5), the Eastern Cooperative Oncology Group (ECOG) performance status measure score (0–5), and the Barthel Index (BI) (0–100).

The American Society of Anaesthesiologists (ASA) classification system was used for preoperative risk assessment.

Patients were evaluated within the first 24 hours after stent placement and at 1 (t1), 3 (t2), and 6 (t3) months after the procedure.

If the patients were symptomatic, a flexible bronchoscopy allowed to evaluate stent position and potential complication such as migration, granulation, fracture, or the presence of secretion plugs.

However, a chest X-ray was performed within 48 hours from implantation, to check the correct placement of the stent and lung re-inflation.

Qualitative and quantitative variables are presented as count, percentage (%), and mean (\pm standard deviation), respectively. Absolute values of each outcome variable were compared by Student's t-test. Wilcoxon and Friedman test were applied for non-parametric variables. A *p* value less than 0.05 indicated statistically significant differences. Overall survival was calculated using Kaplan–Meier method. All analyses were performed using Statview software[®].

Results

Of the 51 patients enrolled for the study, 8 of them showed an intrinsic airway obstruction, 10 showed extrinsic obstruction, and 31 were affected by combined lesions. The remaining two patients underwent stenting for malignant post-obstructive abscess of the left lower lobe. The baseline clinical features are reported in **Table 1**.

The bronchoscopic procedure was a treatment-naïve status on 35 patients, whereas 13 patients had previously

Table 1 Baseline clinical features of the enrolled patients (n = 51)

Variables	No (%)	Mean \pm SD
Age (range: 45–85)		67 \pm 10 y
Gender, male	41 (78)	
BMI		24 \pm 4
Smoking status before/ after stenting		
Smoker	28/12	
Ex-smoker	15/31	
Never smoker	8/8	
Oxygen saturation		95 \pm 2
Stage		
IIIA	8 (15)	
IIIB	14 (27)	
IV	29 (57)	
ECOG		1.8 \pm 0.7
Comorbidities		2.3 \pm 1.4
Barthel Index		85 \pm 10
Symptoms		
Dyspnea/MMRC	27 (52)	2.4 \pm 0.7
Cough	22 (42)	
Hemoptysis	7 (13)	
Chest pain	5 (9)	
Type of obstruction		
Intrinsic lesion	8 (16)	
Extrinsic lesion	10 (20)	
Combined lesion	31 (69)	
Treatment-naïve status upon bronchoscopic intervention	35 (69)	
Pre-procedural treatment	16 (30)	
Chemotherapy	13 (25)	
Chemoradiotherapy	3 (5)	
Post-procedural treatment	40 (75)	
Chemotherapy	33 (63)	
Radiotherapy	2 (3)	
Surgery	4 (7)	
Follow-up (days)		123 \pm 157 (15–653)

BMI: body mass index; ECOG: Eastern Cooperative Oncology Group; MMRC: Modified Medical Research Council; SD: standard deviation

undergone chemotherapy and three patients have been treated with chemoradiotherapy. In all patients, dyspnea and cough were the most common symptoms. A total of 52 stents were implanted on lobar bronchi and the peripheral carina to re-establish the airway patency. The type of stent and the site of airway stenting are summarized in **Table 2** and shown in **Fig. 1**.

In six patients, a double Y-stenting was performed with one prosthesis in the central airway and one into the distal one, displaced in telescopic fashion:

- In four patients, a Dumon Y stent was placed into the main carina, whereas the Oki stent was positioned into the RC1 (two patients) or the RC2 (two patients).

- In one patient, an Oki stent was placed on the RC2, whereas a straight Dumon was inserted into the right main bronchus (RMB) to cover the upper lobar bronchus completely replaced by the tumor.
- In one patient, an Oki stent was positioned into the LC2 with a Silmet stent inside the limb for the left lower lobar bronchus, to reach the basal pyramid.

In the two patients with malignant post-obstructive abscess of the left lower lobe, the airway stenting was essential for the drainage of purulent collections (**Fig. 2**).

The average duration of each procedure was 60 min (range: 20–140 min). Mechanical dilatation and stenting were performed in 31 patients (50%); the additional use of laser cauterization was performed in 19 patients (31%) with combined airway obstruction. Stent deployment was successful in all patients and the chest radiograph after the procedure detected lung re-expansion. Discharge occurred 2 \pm 3 days after the procedure and the mean follow-up duration was 123 days \pm 157 (range: 15–653 days). Modalities and outcomes of bronchoscopic intervention are summarized in **Table 3**.

Symptoms improved significantly from t_0 to t_1 . MMRC dyspnea score (2.6 \pm 0.8 vs 1.2 \pm 0.5; $p < 0.01$) and oxygen saturation (95 \pm 2 vs 96 \pm 2.4; $p < 0.01$) showed a significant improvement between t_0 and t_1 . The BI did not show any significant difference between t_0 and t_1 (82 \pm 2.5 vs. 86 \pm 1.1; $p = 0.07$).

The median overall survival was 118 \pm 21 days. The survival of patients with a double airway stent was worse than patients with a single one ($p < 0.01$). Death was not related to stent complications but it was attributable to disease progression associated with cachexia and metastases. No complications occurred during the airway stenting procedure. Early complication occurred in seven patients. Three patients needed mechanical ventilation in the post-operative for less than 8 hours, due to respiratory distress.

Two patients underwent antiarrhythmic pharmacological cardioversion. Retention of secretion which required bronchoscopic mucus removal, occurred in one patient. One patient underwent intravenous antibiotic therapy and pneumonia resolved immediately. Stent-related complications during follow-up occurred in 22 out of the 51 patients and included stent migration, granulation tissue, mucous plugging, and infection.

Stent migration occurred in 6 out of 22 patients and was treated by repositioning the existing in one patient, replacement with a larger stent in one patient, and removal in four patients. Small granuloma were removed

Table 2 Site and type of prosthesis

Site	Silmet		Oki	Type		Ultraflex	
	Linear	Conic		Silicone Straight	Y		
LLLb	19	5		4		5	33
LULb		1					1
LC2			1		1		2
RLLb				1			1
RC1			6		2		8
RC2			7				7
Total	19	6	14	5	3	5	52

LLLb: left lower lobe bronchus; LULb: left upper lobe bronchus; LC2: left secondary carina; RLLb: right lower lobe bronchus; RC1: right primary carina; RC2: right secondary carina

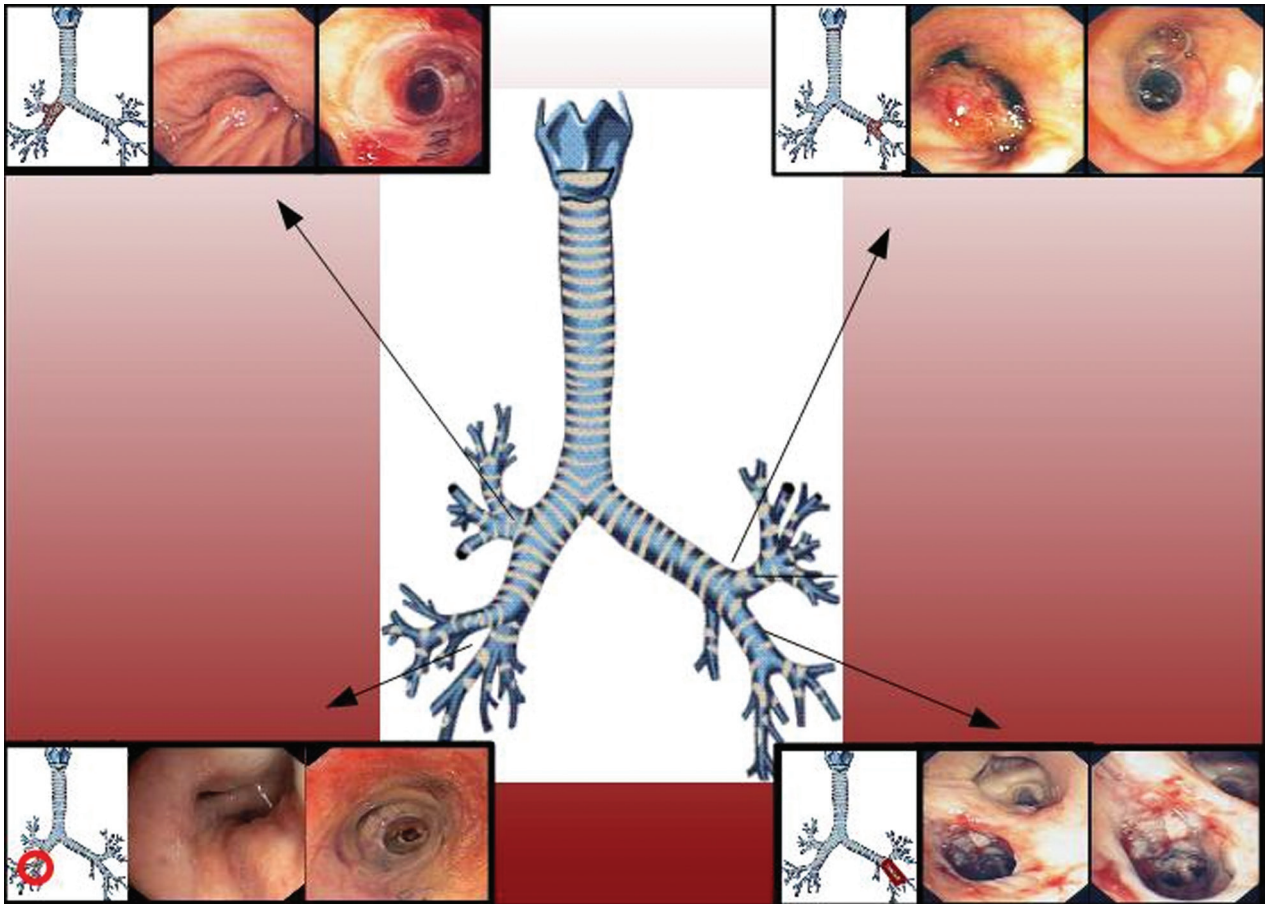


Fig. 1 Site of stent with the endoscopic view

by forceps at the proximal stent in four patients. Clinical or radiological signs of polymicrobial infection were observed in 7 out of 14 patients with positive microbiological cultures and required targeted antibiotic therapy.

The pathogens isolated on bronchoaspirate included the following: *Pseudomonas* (n = 3), *Staphylococcus* (n = 6), *Candida* (n = 6), *Spingomonas paucimobilis* (n = 1), *Enterobacteriaceae* (n = 3), *Haemophilus* (n = 1), *Streptococcus* (n = 1), *Alcaligenes xylosoxidans* (n = 1), and

Hafnia (n = 1). Overall complication rates are summarized in **Table 4**.

Discussion

This retrospective study investigated the technical success, the clinical outcome, and the complications associated with the use of stents in patients with advanced lung cancer involving lobar bronchi, primary and secondary carina.

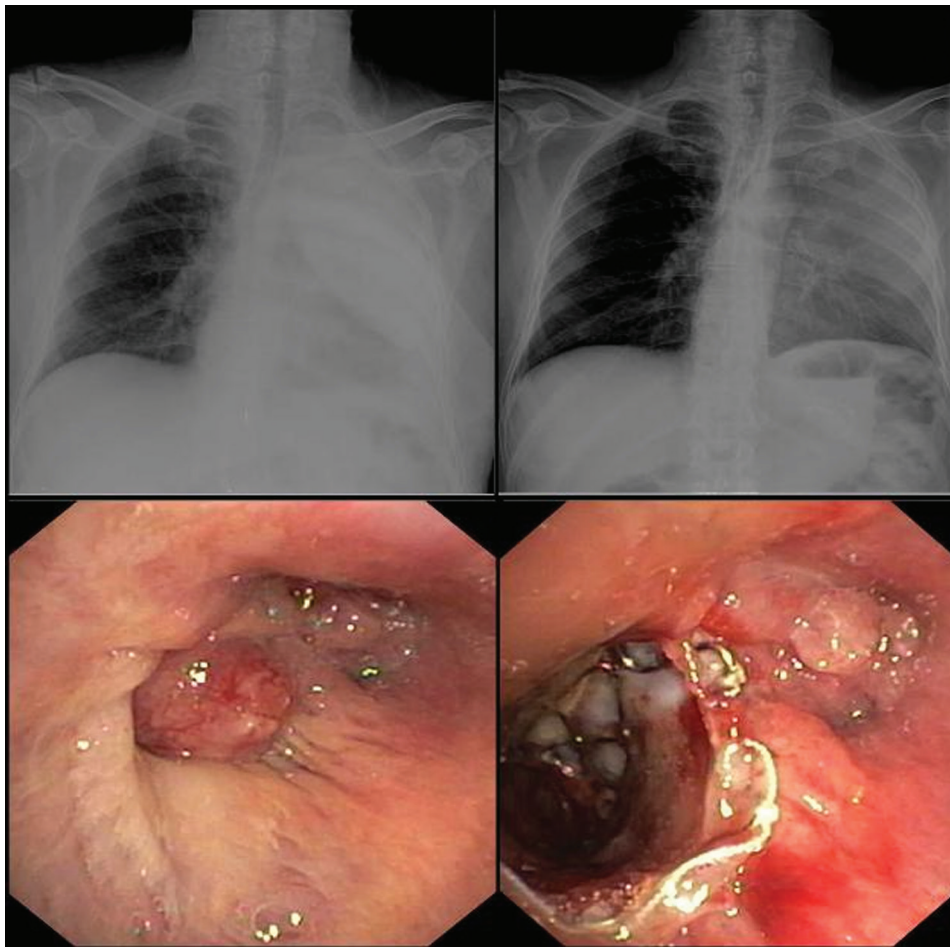


Fig. 2 Complex stenosis of the left lower lobe bronchus. A Silmet stent was inserted to drain the malignant post-obstructive abscess. Chest radiography performed after stenting showed the emptied cavity

Table 3 Modalities and outcomes of bronchoscopic intervention

Variables	No (%)	Mean ± SD
Duration procedure (minute)		60 ± 27
Mechanical dilatation	31 (59)	
Mechanical dilatation + laser	19 (36)	
Successful palliation	50 (99)	
Recovery days after stenting		2 ± 3

SD: standard deviation

Currently, the efficacy and safety of different stent models for the treatment of central airway stenosis have been well established.²⁾ Up to now, in absence of an ideal stent, silicone and expandable metallic stents have been largely used, showing all their advantages and disadvantages. Silicone stents are generally placed in major airway stenosis, unless a marked asymmetry or angulation occurs.⁷⁾ In patients with airway stenosis not suitable for silicone stenting, the placement of an expandable metallic

stent could be more indicated by its better adaptability to different airway diameters.^{2,8,9)}

Recent studies have reported the placement of dedicated bifurcated silicone stents for strictures of the primary RC1, secondary left carena (LC2), or of a lobar bronchus. Breitenbücher et al. reported an increased survival in seven patients with lobar bronchi stenting compared to patients who received only medical treatment.²⁾ In this study, the authors recommended distal airway stenting only in cases of extrinsic compression. In the present study, we demonstrated the feasibility of the most common stenting methods, even in those cases of distal airway stenosis secondary to extrinsic and/or intrinsic compression.

Different types of stents were implanted, according to a different airway stenosis grading. In the presence of tight and short lobar bronchus stenosis, a Silmet stent was implanted to elude possible tumor ingrowths. A Silmet

Table 4 Complication rates and time to detect complications after stent placement

Complications	No (%)	Time after implantation
		(days, mean ± SD)
Early complications after bronchoscopic intervention		
Atrial fibrillation	2 (3.9)	1
Respiratory distress? (non-invasive ventilation)	3 (5.8)	1
Pneumonia	1 (1.9)	2
Obstruction due to tenacious secretions	1 (1.9)	1
Late complications after bronchoscopic intervention		
Stent migration	6 (11)	72 ± 59
– Post-chemotherapy regression of tumor	2 (3.9)	135 ± 25
– Dislocation into cavitory abscess	2 (3.9)	30
– Stent related migration	2 (3.9)	
Granulation tissue formation	4 (7.6)	30
Infections	7 (13)	38 ± 14
Obstruction due to tumor outgrowth	5 (9.8)	40 ± 15

SD: standard deviation

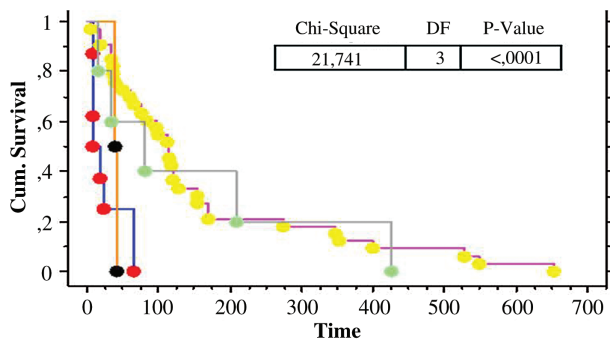


Fig. 3 Survival curve based on the post-bronchoscopic additional treatment ($p = 0.0001$), using Kaplan–Meier estimator. Orange line = radiotherapy; blue line = no treatment; grey line = chemo-radiotherapy; red line = chemotherapy alone

stent shows greater advantages due to its fully covered surface in comparison with SEMS, which show uncovered edges. In patients with complex airway stenosis involving lobar bronchi and the secondary carina, an Oki silicone stent was successfully placed, confirming the encouraging results of the previous reports.

According to Oki et al., double Y-stenting procedure relieved dyspnea in four patients with central and lobar airway tumoral strictures. The telescoping technique, using Dumon and Silmet stents inside OKI stent, allowed to restore airway patency in two patients with right and left long malignant airway stenosis, respectively. To the best of our knowledge, this latter procedure has not been previously reported in literature.

In two patients with malignant post-obstructive abscess of the left lower lobe, airway stenting was necessary to perform antitumoral chemotherapy; a negativity of microbiological cultures and a resolution of respiratory

symptomatology were obtained 2 months after the procedure. Overall, respiratory symptoms were improved in all patients and it was likely due to an improved ventilation/perfusion ratio.

Long-term complications included stent migration, granulation tissue formation, and mucus plugging. Thirty days after the procedure, stent migration was observed in 1% of silicone stent and 11% of SEMS stents. Stent granulation tissue formation was observed in only 7.6% of patients and was similar to data previously reported by the literature about the SEMS (2.9%–15.2%) and the Dumon stents (7.8%).^{2,7,10} Likely, the immunosuppressive effects of post-procedural chemotherapy and/or radiotherapy could explain this low granulation rate.

Obstruction, primarily due to tenacious secretions, occurred in 1.9% of cases and was considerably lower compared with data from literature.^{2,11} Bronchial secretion was measured by means of an endoscopic score, and only a slight increase was registered at the first examination; no secretions were observed at follow-up. This result was achieved thanks to a daily treatment with inhalation therapy with corticosteroids plus TPEP in all patients.⁶

The rate of bacterial colonization observed in our patients was 26%, whereas the evidence of infections was found only in 13% of patients, according to literature.^{12–14} No stent type was observed to favor respiratory infections, although a prevalence of staphylococci rather than Pseudomonas strains on bronchoaspirate samples, was reported.

Unlike literature, tumor ingrowth within stent lumen was not registered in patients with metallic stents. This observation was particularly true for Silmet stents, which show a complete polyester covering, whereas a greater

tumor ingrowth burdened SEMs stents that have both their edges uncovered. The mean overall survival after stent placement was 4.4 months and it was similar to that reported for SEMs (range: 4.2–5.3) and silicone stents (range: 3.4–4).^{2,15,16} Significantly, survival was prolonged in patients who receive adjuvant chemo- or radiotherapy after airway stenting (**Fig. 3**).

Conclusions

The airway stenting of lobar bronchi, primary and secondary carina is technically feasible, effective, and acceptably safe, being no technically more complicated than central trachea-bronchial stenting. The success depends on a multidisciplinary approach where interventional pulmonologist, thoracic surgeon, radiotherapist, and oncologist work together to achieve the best effective approach.

Disclosure Statement

All authors disclosure no conflict of interest.

References

- 1) Damiano G, Maione C, Palumbo VD, et al. Multidisciplinary approach for a relapsing goiter with severe tracheal stenosis: a case report in an elderly patient. *Int J Gerontol* 2012; **6**: 231-3.
- 2) Breitenbücher A, Chhajed PN, Brutsche MH, et al. Long-term follow-up and survival after Ultraflex stent insertion in the management of complex malignant airway stenoses. *Respiration* 2008; **75**: 443-9.
- 3) Oki M, Saka H. New dedicated bifurcated silicone stent placement for stenosis around the primary right carina. *Chest* 2013; **144**: 450-5.
- 4) Oki M, Saka H. Silicone Y-stent placement on the secondary left carina. *Respiration* 2015; **90**: 493-8.
- 5) Oki M, Saka H. Double Y-stenting for tracheobronchial stenosis. *Eur Resp J* 2012; **40**: 1483-8.
- 6) Clini E. Positive expiratory pressure techniques in respiratory patients: old evidence and new insights. *Breathe* 2009; **6**: 153-9.
- 7) Dumon JF, Cavaliere S, Diaz-Jimenez JP, et al. Seven-year experience with the Dumon prosthesis. *J Bronchol* 1996; **3**: 6-10.
- 8) Wood DE, Liu YH, Vallières E, et al. Airway stenting for malignant and benign tracheobronchial stenosis. *Ann Thorac Surg* 2003; **76**: 167-72; discussion 173-4.
- 9) Saad CP, Murthy S, Krizmanich G, et al. Self-expandable metallic airway stents and flexible bronchoscopy: long-term outcomes analysis. *Chest* 2003; **124**: 1993-9.
- 10) Martinez-Ballarín JI, Diaz-Jimenez JP, Castro MJ, et al. Silicone stents in the management of benign tracheobronchial stenoses. Tolerance and early results in 63 patients. *Chest* 1996; **109**: 626-9.
- 11) Miyazawa T, Yamakido M, Ikeda S, et al. Implantation of ultraflex nitinol stents in malignant tracheobronchial stenoses. *Chest* 2000; **118**: 959-65.
- 12) Agrafiotis M, Siempos II, Falagas ME. Infections related to airway stenting: a systematic review. *Respiration* 2009; **78**: 69-74.
- 13) Noppen M, Piérard D, Meysman M, et al. Bacterial colonization of central airways after stenting. *Am J Respir Crit Care Med* 1999; **160**: 672-7.
- 14) Grosu HB, Eapen GA, Morice RC, et al. Stents are associated with increased risk of respiratory infections in patients undergoing airway interventions for malignant airways disease. *Chest* 2013; **144**: 441-9.
- 15) Razi SS, Lebovics RS, Schwartz G, et al. Timely airway stenting improves survival in patients with malignant central airway obstruction. *Ann Thorac Surg* 2010; **90**: 1088-93.
- 16) Song JU, Park HY, Kim H, et al. Prognostic factors for bronchoscopic intervention in advanced lung or esophageal cancer patients with malignant airway obstruction. *Ann Thorac Med* 2013; **8**: 86-92.