

## CASE REPORT

## A Pseudoaneurysm of the Deep Palmar Arch After Penetrating Trauma to the Hand: Successful Exclusion by Ultrasound Guided Percutaneous Thrombin Injection

A. Bosman <sup>a,\*</sup>, H.T.C. Veger <sup>b</sup>, F. Doornink <sup>a</sup>, P.P.A. Hedeman Joosten <sup>a</sup>

<sup>a</sup> Department of Vascular Surgery, Alrijne Hospital, Leiderdorp, The Netherlands

<sup>b</sup> Department of Vascular Surgery, Zuyderland Medical Center, Brunssum, The Netherlands

**Introduction:** Pseudoaneurysm of the hand is a rare condition; most are treated surgically. Ultrasound guided thrombin injection has not previously been reported as a treatment option for pseudoaneurysms of the deep palmar arch.

**Report:** A man was referred to the emergency department with a swollen, painful hand after penetrating trauma. On physical examination, a pulsating tumor was found on the dorsum of the hand. Imaging revealed a pseudoaneurysm vascularized by the deep palmar arch. Ultrasound guided percutaneous thrombin injection was successfully performed.

**Conclusion:** Thrombin injection might be a safe alternative option in the treatment of pseudoaneurysm of the deep palmar arch.

© 2016 The Authors. Published by Elsevier Ltd on behalf of European Society for Vascular Surgery. This is an open access article under the CC BY-NC-ND license (<http://creativecommons.org/licenses/by-nc-nd/4.0/>).

Article history: Received 10 November 2015, Revised 2 March 2016, Accepted 6 March 2016,

**Keywords:** Deep palmar arch, Pseudoaneurysm, Thrombin injection

### INTRODUCTION

Pseudoaneurysms (false aneurysms) are commonly described as a result of arterial injury. The aneurysm develops secondary to partial disruption of the arterial wall by traumatic or iatrogenic injury. Pseudoaneurysms are frequently described as a complication of arterial catheterization of the femoral and radial artery. Ultrasound guided percutaneous thrombin injection for the management of femoral pseudoaneurysms is shown to be an effective, safe, and time and money saving procedure.<sup>1</sup>

Traumatic injuries to the hand occur frequently. Despite the high incidence of hand trauma, a pseudoaneurysm of the deep palmar arch is very rare. Conventional treatment consists of surgical resection of the pseudoaneurysm with or without bypass surgery. Ultrasound guided percutaneous thrombin injection has not previously been described as a treatment option for pseudoaneurysms of the deep palmar arch. This case report shows that ultrasound guided percutaneous thrombin injection is a safe and effective treatment for pseudoaneurysms of the deep palmar arch.

### REPORT

A 33 year old man was referred to the emergency department (ED) with a swollen, painful hand. Four weeks earlier the right handed patient had penetrated his left hand in the thenar eminence with a screwdriver. Plain radiographic images showed no evidence of foreign body, injury to the bones, or any other abnormalities due to the injury. The patient was treated conservatively by the general practitioner (GP). The tumor and hematoma persisted and the GP started amoxicillin/clavulanic acid as a treatment for possible infection. The patient's hand did not improve clinically. A pulsatile tumor developed on the dorsum of the hand between the first and second metacarpal bones. Full physical examination at the ED showed no signs of infection. Physical examination showed adequate vascularization of the digits. The radial and ulnar pulses were patent and considered normal.

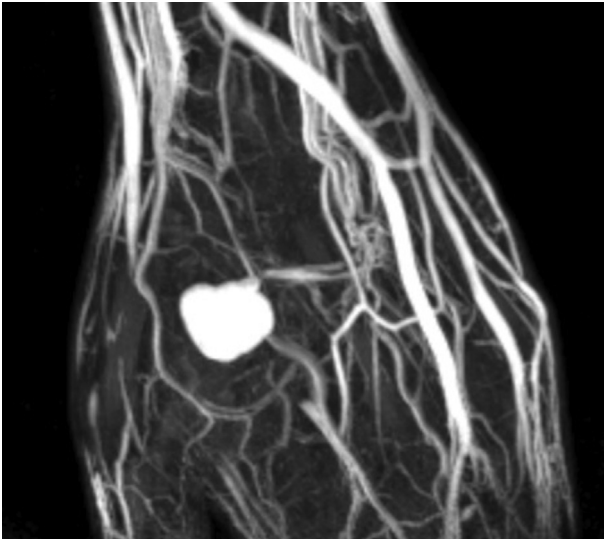
Ultrasonography revealed a pseudoaneurysm (false aneurysm) with a diameter of 25 mm and with a short and broad neck of 5 mm. Magnetic resonance angiography (MRA) imaging revealed an aneurysm arising from the deep palmar arch of the ulnar artery (Fig. 1). Digital subtraction angiography (DSA) was performed, which showed that the aneurysm was vascularized from the deep palmar arch (Fig. 2). The deep palmar arch showed an incomplete variant. The radial part of the incomplete arch was vascularized from a branch originating from the radial artery and the ulnar part by a branch from the metacarpal artery (from

\* Corresponding author.

E-mail address: [bosman.anne@gmail.com](mailto:bosman.anne@gmail.com) (A. Bosman).

2405-6553/© 2016 The Authors. Published by Elsevier Ltd on behalf of European Society for Vascular Surgery. This is an open access article under the CC BY-NC-ND license (<http://creativecommons.org/licenses/by-nc-nd/4.0/>).

<http://dx.doi.org/10.1016/j.ejvssr.2016.03.002>

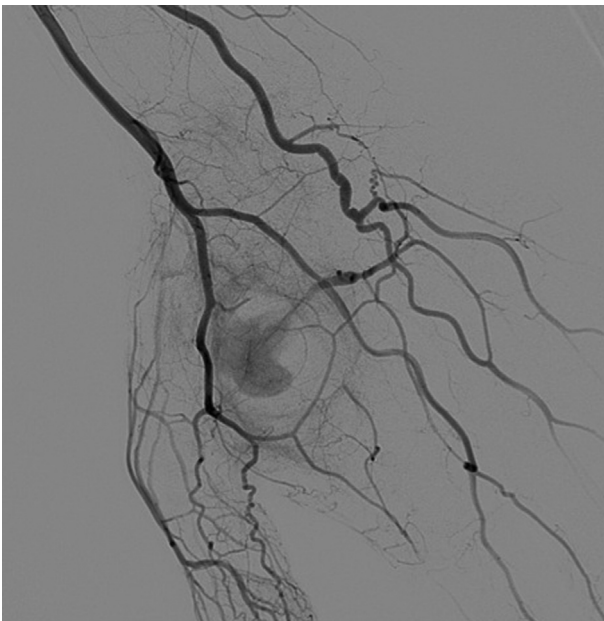


**Figure 1.** Magnetic resonance angiography reveals that the pseudoaneurysm arises from the deep palmar arch (originated from the ulnar artery).

the third and fourth finger). The pseudoaneurysm was located at the distal part of the ulnar arch.

Supplementary data related to this article can be found online at <http://dx.doi.org/10.1016/j.ejvsr.2016.03.002>

The following are the Supplementary data related to this article: Video 1 Magnetic resonance angiography images reveal that the pseudoaneurysm arises from the deep palmar arch (originated from the ulnar artery).



**Figure 2.** Digital subtraction angiography showing the pseudoaneurysm being vascularized from the deep palmar arch. The deep palmar arch is an anatomically incomplete variant: the radial part of the incomplete arch is vascularized from a branch originating from the radial artery and the ulnar part by a branch from the metacarpal artery (from the third and fourth finger).

Video 2 Digital subtraction angiography images showing the pseudoaneurysm being supplied from the deep palmar arch. The deep palmar arch is an anatomically incomplete variant: the radial part of the incomplete arch is vascularized from a branch originating from the radial artery and the ulnar part by a branch from the metacarpal artery (from the third and fourth finger).

Selective embolization was not feasible, considering the anatomical variation of the deep palmar arch. Ultrasound guided percutaneous thrombin injection resulted in a completely clotted pseudoaneurysm. The thrombin injection resulted in decreased swelling of the hand. The digits were considered well vascularized. No signs of distal embolization were found. After 3 weeks, ultrasonography showed that the size of the aneurysm had diminished.

## DISCUSSION

Pseudoaneurysms form when the arterial wall is damaged, resulting in blood flow out of the artery and into the surrounding tissue with a connection from the artery to the newly formed cavity. Organization of the hematoma results in the formation of a cavity with a thin intimal layer. Compared with the native vessel, the pseudoaneurysm is more susceptible to rupture, although rupture is uncommon.<sup>2</sup>

Pseudoaneurysms of the deep palmar arch are infrequently diagnosed and described in literature. Patients complain about a painful pulsatile mass at the location of the previous injury. The pseudoaneurysm compresses the surrounding tissue and nerve compression can be observed. Other complications of pseudoaneurysms are arterial occlusion, destruction of the surrounding tissue and abscess formation.<sup>3</sup> Ultrasonography can diagnose a pseudoaneurysm in most cases.<sup>3</sup>

Current medical literature describes surgery as the preferred treatment option. Arteries were repaired or resected, with or without performing bypass surgery.<sup>2-5</sup>

Ultrasound guided thrombin injection is found to be an effective, time saving, and safe procedure in the treatment of pseudoaneurysms of the femoral artery.<sup>1</sup>

Once the needle is in position, the injection of thrombin should be performed with continuous ultrasound monitoring while the thrombin is slowly injected into the aneurysm sac. Flow in the pseudoaneurysm is monitored, and the neck and underlying artery must be carefully avoided. Formation of thrombus generally occurs within seconds. Thrombin injection into an artery or vein should be avoided at all times.

In this case, MRA and DSA were used in addition to ultrasonography to image the anatomy of the pseudoaneurysm and the deep palmar arch.

Thrombin injection should be avoided as treatment in the case of an arteriovenous fistula, non-visualized pseudoaneurysm neck, or a wide neck.

This case report illustrates that a pseudoaneurysm of the deep palmar arch can be treated safely and effectively by ultrasound guided percutaneous thrombin injection.

### CONCLUSION

Ultrasound guided percutaneous thrombin injection is a safe alternative option in the treatment of deep palmar arch pseudoaneurysms.

### CONFLICT OF INTEREST

None.

### FUNDING

None.

### REFERENCES

- 1 Krüger K, Zähringer M, Söhngen FD, Gossmann A, Schulte O, Feldmann C, et al. Femoral pseudoaneurysms: management with percutaneous thrombin-injections—success rates and effects on systemic coagulation. *Radiology* 2003;**226**:452–8.
- 2 Sterett WI. Pseudoaneurysm of the superficial palmar arch. *J Bone Joint Surg* 1996;**78**:1089–91.
- 3 Knight M, Bremmer-Walcott M, Criddle J, Timoney N. An unusual case of traumatic wrist swelling. *Arch Dis Child* 2013;**98**: 980.
- 4 Hughes CD, Binette C, Babigian A. Pseudoaneurysm in the hand of a three year old boy: a case report. *J Emerg Med* 2012;**42**:87–9.
- 5 Fields JM, Chandra S, Au AK, Rotte M, Ku BS. Images in emergency medicine. Child with painful palmar mass. Superficial palmar arch pseudoaneurysm. *Ann Emerg Med* 2013;**62**:569–77.