



ORIGINAL STUDIES

EDITORIAL COMMENT: Expert Article Analysis for:
[Another promising device for peripheral CTO's: But what about long-term patency](#)

Performance of the Wingman catheter in peripheral artery chronic total occlusions: Short-term results from the international Wing-It trial

John R. Laird MD¹  | S. Jay Mathews MD, MS² | Marianne Brodmann MD³  |
Peter A. Soukas MD⁴ | Andrej Schmidt MD⁵ | The Wing-It Trial Investigators

¹Adventist Heart and Vascular Institute, Adventist St. Helena Hospital, St. Helena, California

²Bradenton Cardiology Center, Bradenton, Florida

³Division of Angiology, Medical University Graz, Graz, Austria

⁴Lifespan Cardiovascular Institute, The Miriam Hospital, Providence, Rhode Island

⁵Division of Angiology, Department of Internal Medicine, Neurology and Dermatology, University Hospital Leipzig, Leipzig, Germany

Correspondence

John R. Laird, MD, Adventist St. Helena Hospital, 6 Woodland Rd, Suite 304, St. Helena, CA 94574.
Email: lairdjr@ah.org

Abstract

Objectives: To determine the safety and effectiveness of a peripheral artery chronic total occlusion (CTO) crossing catheter following failed crossing attempts with standard guidewires.

Background: CTO crossing remains a challenge during peripheral artery interventions.

Methods: In this prospective, international, single-arm study, patients with a peripheral artery CTO that was uncrossable with standard guidewires were treated with a crossing catheter (Wingman, Reflow Medical). The primary efficacy endpoint of CTO crossing success was compared to a performance goal of 70.7%. The primary composite safety endpoint (major adverse event [MAE], clinically significant perforation or embolization, or grade C or greater dissection) was assessed over a 30-day follow-up period and compared to a performance goal of 13.0%.

Results: A total of 85 patients were treated using the Wingman catheter for peripheral artery CTO crossing. Key patient characteristics were mean age of 71±9 years, 66% male, and mean lesion length of 188±94 mm in the superficial femoral artery (71%), popliteal artery (15%), or infrapopliteal arteries (14%). Both primary endpoints of the trial were met^{3/4}CTO crossing success was 90% (lower confidence limit=82.5%) and 5 primary safety events occurred in 4 (4.8%) patients (upper confidence limit=10.7%). Over 30 days of follow-up, Rutherford score decreased by at least 2 categories in 74% patients; the percentage of patients with normal hemodynamics assessed with the ankle-brachial index increased from 1% to 51%.

Conclusions: Among patients with a CTO that was unable to be crossed with a standard guidewire, the Wingman catheter was able to cross 90% of occlusions with a favorable safety profile.

KEYWORDS

atherosclerosis, catheter design, critical, limb ischemia, peripheral arterial disease

This is an open access article under the terms of the Creative Commons Attribution-NonCommercial-NoDerivs License, which permits use and distribution in any medium, provided the original work is properly cited, the use is non-commercial and no modifications or adaptations are made.

© 2020 The Authors. Catheterization and Cardiovascular Interventions published by Wiley Periodicals LLC

1 | INTRODUCTION

Up to 40% of patients with peripheral arterial disease undergoing endovascular intervention present with a chronic total occlusion (CTO),^{1,2} that is comprised of dense collagenous lesions with variable length, plaque composition, and morphology. CTOs present a unique therapeutic challenge that increase procedure time, operator and patient radiation exposure, and the risk of periprocedural complications such as perforation, dissection, distal embolization and arteriovenous fistula. In nearly 50% of cases, the CTO cannot be crossed using a standard wire-catheter approach³ and therefore are responsible for a high procedure failure rate in daily practice.

Specially designed crossing catheters have been developed to improve CTO crossing rates by enabling penetration of the proximal cap to facilitate delivery of endovascular devices to the target lesion. Compared to a primary wire-catheter crossing strategy, CTO crossing devices are associated with a higher primary technical success rate and a lower risk of revascularization over 1-year of follow-up.³ While previous studies have reported results obtained with various dedicated CTO crossing devices,⁴⁻⁸ each employ different mechanisms by which CTO crossing is achieved. Thus, the efficacy and safety of these catheters may be device-specific and clinical studies with new CTO crossing catheters are warranted. The purpose of this study was to determine the safety and efficacy of a manually controlled catheter used to channel through peripheral artery CTOs after failed crossing attempts with standard guidewires.

2 | METHODS

2.1 | Study design

The Wing-It trial was a prospective, international, single-arm study of a novel crossing catheter used in peripheral artery CTOs after failed crossing attempts with standard guidewires. The protocol was approved by the ethics committee at each study site and all patients provided written informed consent before study participation. The trial was prospectively registered at ClinicalTrials.gov (NCT03403426).

2.2 | Patients

Participants were consecutively assessed for study eligibility at each site. Preprocedural evaluations included physical examination, review of medical history and medications, laboratory tests, ankle-brachial index (ABI), Rutherford classification of lower extremity disease, and initial angiographic imaging. Eligible patients presented with Rutherford category 2–5 ischemia, a target vessel at least 2 mm in diameter, one or two target lesions between 1 and 30 cm in length each, and a de novo or restenotic peripheral artery CTO that was unable to be crossed within 5 min continuously using a standard guidewire. Complete eligibility criteria are given in Table 1.

TABLE 1 Patient eligibility criteria

Inclusion criteria
1. Patient is willing and able to provide informed consent
2. Patient is willing and able to comply with the study protocol
3. At least 18-years-old
4. Peripheral arterial disease requiring revascularization evidenced by contrast CT or MR angiography
5. One or two occluded infrainguinal arteries that are 99–100% stenosed and no flow is observed in the distal lesion except the flow from collateral circulation
6. Target lesion(s) is ≥ 1 and < 30 cm in length by visual estimate
7. Target vessel is ≥ 2.0 mm in diameter
8. Rutherford classification of 2–5
9. Lesion cannot be crossed by concurrent conventional guidewire
10. Reconstitution of vessel at least 2 cm above bifurcation/trifurcation
11. Occlusion can be within previously implanted stent
Exclusion criteria
1. Sensitivity or allergy to contrast materials that cannot be adequately pretreated
2. Sensitivity or allergy to all antiplatelet medications
3. Pregnant or lactating
4. Coexisting disease or medical condition contraindicating percutaneous intervention
5. Target lesion within a bypass graft
6. Failed crossing attempt without an intervention on the target limb within the past 14 days
7. Planned surgical or interventional procedure within 30 days after the study procedure

2.3 | Procedures

Investigators made initial attempts to cross the CTO using standard guidewires. If this initial crossing was successful, the patient was treated at the investigator's discretion and was excluded from the trial. In cases where CTO crossing with standard guidewires was unsuccessful after 5 min of continuous attempt, patients were then enrolled in the trial and treated with the Wingman catheter (Reflow Medical, San Clemente, CA) prior to endovascular revascularization. The time period for attempted crossing with a standard guidewire was based off of precedent set by previous crossing catheter trials (usually 3 min in previous trials)^{4,5,9-17}. The Wingman catheter is an over-the-wire crossing catheter available in 0.014-, 0.018-, and 0.035-in. configurations and a working length up to 150 cm that utilizes an extendable, stainless steel or nitinol (dependent on size) beveled tip for CTO penetration. The hydrophilic-coated catheter was tracked over a standard guidewire to the CTO with the guide tip in a retracted position (Figure 1). Upon reaching the CTO, the radiopaque beveled guide tip was advanced forward, rotated, and then retracted. Advancement and retraction of the beveled guide tip creates a small channel allowing the guidewire to penetrate and cross the lesion. This step was repeated as many times as needed until the CTO was fully crossed. The catheter allows for exchange of guidewires and provides a




FIGURE 1 The Wingman crossing catheter, an over-the-wire crossing catheter available in 0.014-, 0.018-, and 0.035-in. configurations and a working length up to 150 cm that utilizes an extendable beveled tip for chronic total occlusion penetration [Color figure can be viewed at wileyonlinelibrary.com]

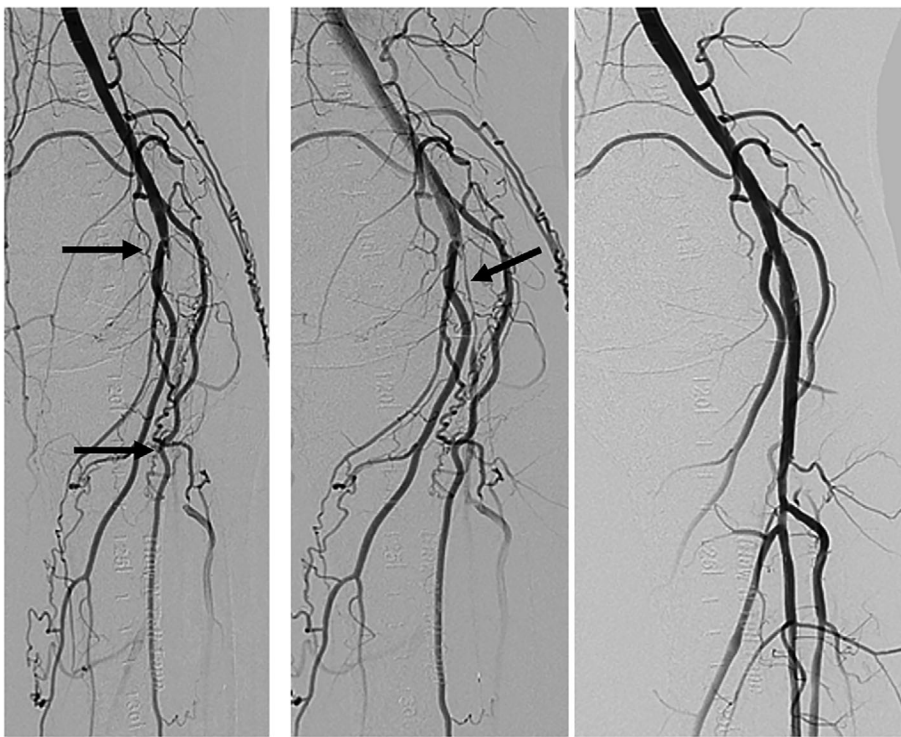


FIGURE 2 A 65-year-old female was treated for a popliteal artery (P2) chronic total occlusion (located between P2 and TPT, left panel). After failure to cross with a standard guidewire, the Wingman catheter successfully crossed the occlusion (arrow, middle panel) and facilitated endovascular treatment with balloon angioplasty resulting in 17% final diameter stenosis (right panel)

conduit for delivery of diagnostic and therapeutic devices. If CTO crossing was achieved, endovascular treatment was performed at the investigator's discretion. A representative angiographic sequence of procedural steps is shown in Figure 2. If CTO crossing was not achieved using the Wingman catheter, then additional attempts to cross the occlusion with other guidewires and devices, like subintimal re-entry devices could be attempted. Following hospital discharge, patients returned for a follow-up visit at 30 days post-procedure, which consisted of an adverse event assessment, ABI, and Rutherford classification.

2.4 | Outcomes

The primary efficacy endpoint of the trial was CTO crossing success, which was defined as angiographic confirmation of successful

guidewire placement in the distal true lumen and freedom from perforation requiring intervention. The primary safety endpoint was a composite outcome consisting of freedom from (a) major adverse event, (b) perforation requiring intervention, (c) clinically significant embolization (requiring intervention or resulting in distal ischemia), and (d) grade C or greater dissection. Angiographic images were evaluated by an independent core laboratory (Yale Cardiovascular Research Group, New Haven, CT), including assessments of lesion length, CTO length, reference vessel diameter, calcification, CTO crossing success, perforation, and dissection. An independent clinical events committee (Syntactx, New York, NY) adjudicated unanticipated adverse device effects and all events comprising the primary efficacy and safety endpoints. A data safety monitoring board (Syntactx, New York, NY) provided study oversight.

2.5 | Statistical analysis

The primary endpoints of the trial were statistically compared to performance goals that were calculated based on results from other CTO crossing catheters.^{4,5,9-17} Study success required the lower one-sided 95% confidence limit of the primary efficacy endpoint to exceed 70.7%, which was derived assuming an 83.2% crossing rate and a 12.5% margin. Similarly, the upper one-sided 95% confidence limit of the primary safety endpoint was not to exceed 13.0%, assuming an observed rate of 8.0% plus a 5.0% margin. Based on these assumptions and adjusting for an anticipated 5% loss to follow-up, a sample size of 85 patients provided at least 80% statistical power to test both primary hypotheses. Continuous data were reported as the mean and standard deviation or median and interquartile range if data were not normally distributed. Categorical data were reported as counts and percentages. Confidence intervals for proportions were calculated using the exact binomial distribution. Demographic and clinical predictors of CTO crossing failure were evaluated in univariate logistic regression. Data were analyzed using the SAS version 9.4 (SAS Institute, Cary, NC).

3 | RESULTS

Between March 2018 and May 2019, 85 patients with a peripheral artery CTO, that could not be successfully crossed with standard guidewire, were enrolled and treated at 12 sites in the United States, Germany, and Austria (Table S1). Mean patient age was 71 ± 9 years, 66% were male, 27% presented with critical limb ischemia, and most patients had a history of smoking (76%) and prior peripheral intervention (64%). Among 86 treated lesions, mean lesion length was 188 mm and target vessels were the superficial femoral artery (71%), popliteal artery (15%), and infrapopliteal arteries (14%) (Table 2).

Following failed crossing attempts with a standard guidewire, the rate of successful CTO crossing with the Wingman catheter was 90%, with an average crossing time of 12 min. The lower confidence limit was 82.5%, which exceeded the performance goal of 70.7%. Thus, the primary efficacy endpoint of the trial was met. After CTO crossing, revascularization was most commonly performed using angioplasty (80%), stent placement (60%), and/or atherectomy (36%), after which the final diameter stenosis was 29% (Table 3). Seventy (70) percent of patients had some degree of calcification, with 19% of lesions severely calcified. (Table 2). Twenty-eight percent of lesions were classified as moderately or severely calcified. In these heavily calcified lesions, 5 crossing attempts with the Wingman catheter were unsuccessful (20%). In contrast, 67% of lesions were classified as having no or mild calcification; 4 crossing attempts in this category were unsuccessful (7%). In univariate logistic regression, lesion characteristics, including lesion length and calcification, did not have a statistically significant impact on successful CTO crossing (Table 4). The successful CTO crossing rate in the femoral popliteal arteries was 91%

TABLE 2 Baseline patient and lesion characteristics

Characteristic	Value ^a
Demographics	
Age (year)	71±9 (85)
Male sex	66% (56/85)
Body mass index (kg/m ²)	28±5 (85)
Medical history	
Smoking history	76% (65/85)
Peripheral intervention	64% (54/85)
Diabetes mellitus	31% (26/85)
Percutaneous coronary intervention	25% (21/84)
Myocardial infarction	22% (18/83)
Coronary artery bypass graft	19% (16/84)
Amputation	5% (4/85)
Rutherford category	
2	2% (2/85)
3	71% (60/85)
4	14% (12/85)
5	13% (11/85)
Target vessel	
Superficial femoral artery	71% (61/86)
Popliteal artery	15% (13/86)
Infrapopliteal artery	14% (12/86)
Type of occlusion	
de novo	76% (65/86)
Restenotic	24% (21/86)
Lesion length (mm)	
	188±94 (81)
Calcification	
None	30% (26/86)
Mild	42% (36/86)
Moderate	9% (8/86)
Severe	19% (16/86)

^aData reported as mean \pm SD (n), or percentage (n/N).

(67/74), while the successful CTO crossing rate in the infrapopliteal arteries was 83.3% (10/12). (Table 5).

A total of 82 (96%) patients were available for follow-up at 30 days owing to 2 patient withdrawals and 1 patient death. The single patient death was caused by ventricular fibrillation on post-treatment day 4, which was determined by the clinical events committee to be unrelated to the crossing catheter. The primary safety endpoint of the trial was met as 4.8% of patients experienced a composite safety endpoint event through the 30-day follow-up visit. The upper confidence limit was 10.7%, which was less than the 13.0% performance goal. Five events reported in 4 patients comprised the primary safety endpoint included target vessel revascularization (2.4%), major amputation (1.2%), clinically significant perforation (1.2%), and death (1.2%) (Table 5). The perforation was caused by the study device, according to core lab adjudication, and sealed with manual compression; this resolved without sequelae. The target limb

major amputation occurred in a patient with Rutherford category 5 ischemia 14 days after the index procedure. This subject had unsuccessful crossing of the CTO with the study device followed by clinical deterioration in the target leg, necessitating an above-knee

amputation. The event was CEC-adjudicated as related to the index procedure but not related to the study device.

At the 30-day follow-up visit, the Rutherford score decreased by at least 2 categories in 57 (74%) patients and by at least 1 category in 62 (81%) patients (Figure 3). Normal lower limb hemodynamics, defined

TABLE 3 Procedural details

Characteristic	Value ^a
Vascular access	
Contralateral	62% (53/85)
Ipsilateral antegrade	27% (23/85)
Retrograde	9% (8/85)
Pedal	1% (1/85)
Failed standard guidewire attempts	
1	67% (56/83)
2	33% (27/83)
Crossing guidewire attempts	
1	78% (67/86)
2	17% (15/86)
3	3% (3/86)
Crossing device time (min)	12 ± 12 (106) ^b
Total fluoroscopic time (min)	30 ± 18 (85)
Total procedure time (min)	102 ± 48 (85)
Successful Wingman CTO crossing	90% (77/86) ^c
Revascularization methods ^a	
Angioplasty	80% (69/86)
Stent	60% (52/86)
Atherectomy	36% (31/86)
Laser ablation	16% (14/86)
Other	16% (14/86) ^d
None	8% (7/86)
Lesion success	93% (77/83)
Procedure success	93% (76/82)
Final diameter stenosis (%)	29 ± 21 (83)

Abbreviation: CTO, chronic total occlusion.

^aData reported as mean ± SD (n), or percentage (n/N).

^bReported on a per-device basis.

^cThe lower confidence limit was 82.5% which exceeded the performance goal of 70.7%. Thus, the primary efficacy endpoint was met.

^dOther revascularization methods included drug-coated balloon, scoring balloon, lithoplasty, and/or laser atherectomy.

TABLE 5 Complications through 30 days follow-up

Complication	Value ^a
Any CEC-adjudicated primary safety endpoint event	4.8% (4/83) ^b
Major adverse event	4.8% (4/83)
All-cause mortality	1.2% (1/83)
Major amputation	1.2% (1/83)
Target vessel revascularization	2.4% (2/83)
Clinically significant perforation	1.2% (1/83)
Clinically significant embolization	0% (0/83)
Dissection grade C or greater	0% (0/83)

Abbreviations: CEC, clinical events committee; MedDRA, Medical Dictionary for Regulatory Activities.

^aData reported as mean ± SD (n), or percentage (n/N).

^bThe upper confidence limit was 10.7% which did not exceed the performance goal of 13.0%. Thus, the primary safety endpoint was met.

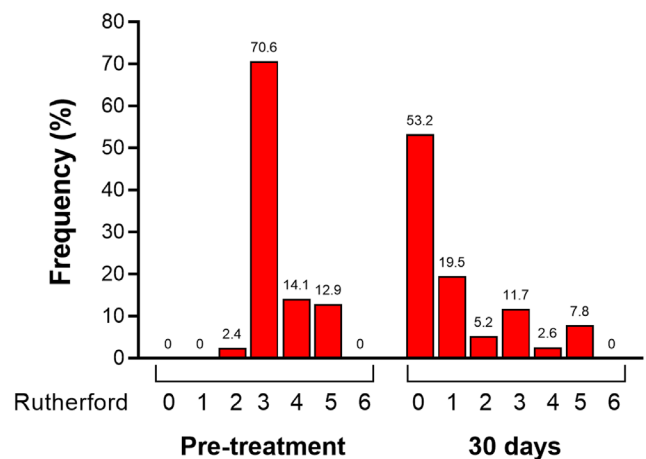


FIGURE 3 Change in Rutherford classification from pretreatment to 30 days after endovascular therapy for peripheral artery chronic total occlusion facilitated by the Wingman crossing catheter [Color figure can be viewed at wileyonlinelibrary.com]

TABLE 4 Univariate logistic regression of factors associated with unsuccessful Wingman CTO crossing

Characteristic	Unit of measure	Odds ratio	95% CI	p-value
Contralateral vascular access	Yes versus no	0.58	0.24, 1.43	.24
Lesion length	Per 50 mm	1.10	0.90, 1.36	.35
Occlusion type	De novo versus restenotic	0.68	0.27, 1.70	.69
Target vessel	SFA versus popliteal/infrapopliteal	0.78	0.21, 2.84	.90
Calcification	None versus any	0.94	0.21, 4.23	.94

Abbreviations: CTO, chronic total occlusion; SFA, superficial femoral artery.

TABLE 6 Change in ankle-brachial index over 30 days post-treatment

ABI category	ABI range	Preprocedure	Post-procedure	30 days
Critical limb ischemia	<0.40	14% (11/81)	1% (1/72)	0% (0/73)
Intermittent claudication	0.40–0.60	37% (30/81)	6% (4/72)	5% (4/73)
Mild peripheral artery disease	0.61–0.95	44% (36/81)	50% (36/72)	37% (27/73)
Normal	0.96–1.30	1% (1/81)	38% (27/72)	51% (37/73)
Noncompressible	>1.30	4% (3/81)	6% (4/72)	7% (5/73)

Abbreviation: ABI, ankle-brachial index.

as an ABI between 0.96 and 1.30, were present in only 1% of patients at baseline and, following CTO crossing and revascularization, increased to 38% post-procedurally and 51% at the 30-day follow-up visit (Table 6).

4 | DISCUSSION

Vascular specialists will encounter a CTO in approximately 40% of peripheral revascularization cases^{1,2} and it is paramount that operators possess the techniques and tools necessary to achieve successful and safe CTO recanalization. Endovascular treatment of peripheral artery CTOs presents a therapeutic challenge due to the inability of standard guidewires to penetrate the proximal cap or deflection of the guidewire into the subintimal space. Subintimal techniques have been used to cross CTOs with reasonable success rates, but these techniques demand significant experience and may not be suitable for treatment of long or severely calcified lesions. In addition, intraluminal CTO crossing may be preferred over subintimal crossing in certain situations, such as prior to use of atherectomy devices or drug coated balloons. Purpose-built CTO crossing catheters have been developed to allow vascular specialists to cross CTOs using various technologies including microdissection, laser, vibrational energy, and intravascular ultrasound imaging. These dedicated CTO devices are often costly and may require the purchase of additional capital equipment for their use. In the current trial, we evaluated the utility of a simple, non-mechanical CTO crossing catheter in a wide range of CTO morphologies as well as above-the-knee and below-the-knee lesions. The primary efficacy and safety endpoints were met and trial results demonstrated that CTOs that could not be crossed within 5 min with standard guidewires were successfully crossed with the Wingman catheter in 90% of cases with little associated morbidity.

The Wingman catheter was developed to effectively cross CTOs using manual maneuvers that require no specialized training and without the need for expensive mechanical recanalization techniques. A review of the medical literature regarding peripheral artery CTO crossing catheters reveals a weighted historical crossing success rate of 83%.^{4,5,9-17} The 90% crossing rate observed in the current trial compares favorably with these historical results and was achieved despite the inclusion of very long lesions (mean lesion length of 188 ± 94 mm) in this trial. The device is simple in design and allows relatively quick crossing (mean crossing time of 12 ± 12 min) and comes in three sizes, allowing for the use of 0.014, 0.018, or 0.035 in. guidewires. The learning curve for this device is short, as documented

by the fact that many of the investigators gained their first experience with this device in patients that were enrolled in the trial. The device can be easily used for antegrade and retrograde crossing techniques. The device was similarly effective for femoropopliteal and infrapopliteal CTOs.

The safety profile of the Wingman catheter was excellent in this trial. Based on the experience with this device in the trial that included a heterogeneous mix of patients with peripheral artery CTO, we offer several observations that may be useful to operators in order to optimize CTO crossing while minimizing the risk of procedural complications. The Wingman catheter is indicated after crossing with conventional wires are unsuccessful. Excessive attempts may lead to subintimal guidewire passage, which will decrease the subsequent effectiveness of the Wingman catheter, as any device used will also then tend to veer subintimal if the channel is large.¹⁸ If the guidewire does not cross with initial attempts, early conversion to the Wingman catheter should be considered. Furthermore, the excellent pushability of the device may allow for advancement through the CTO without advancement of the extendable beveled tip. For resistant lesions, the beveled tip can be extended and rotated to penetrate the hard, fibrous cap. Slow advancement technique and repetitive extension and rotation of the beveled tip may be required for calcified CTOs ("coring technique"). In addition, utilization of a high tip load wire may enhance crossing, although the increased tip load offered by the Wingman device allows for use of workhorse wires of the operator's discretion. The Wingman may also be used as a support catheter to exchange and lead with conventional guidewires, once the most resistant segment of the CTO has been crossed. The 0.035 guidewire catheter may be preferred for femoropopliteal occlusions, while the 0.014 and 0.018 catheters are optimally employed for BTK CTOs. For operators, there may be benefit from early conversion to a retrograde approach in instances where cap morphology is unfavorable from an antegrade approach or if there is a large subintimal plane.¹⁹ In the current study, the only factor associated with a risk of reduced CTO crossing by logistic regression analysis was the presence of critical limb ischemia (CLI). This may be the reflection of increased plaque burden and lesion calcification in this high-risk patient population; however, in this study, degree of calcification was not correlated with reduced of CTO crossing.

The main strengths of this study included international site participation, which improves the generalizability of study results and the broad range of patient characteristics that were treated including femoropopliteal and infrapopliteal lesions across an array of disease

severities ranging from moderate claudication to CLI with ischemic ulcers. There were also several limitations to the study that warrant consideration. Patients were only followed for 30 days post-procedure and the study did not utilize a control group. Therefore, it remains unclear how clinical outcomes in patients treated with the Wingman crossing may compare to alternate CTO crossing strategies. Second, this study was not designed to assess the influence of operator experience on CTO crossing rates. However, prior experience with the Wingman catheter was not required for participating physicians, which further improves the generalizability of trial results. Finally, while cost data were not collected in this study, it would be interesting to determine the cost effectiveness of the Wingman catheter in relation to other dedicated CTO crossing devices by considering device cost, crossing rate, and the utilization and cost of additional devices employed for failure to cross.

5 | CONCLUSIONS

Among patients with a peripheral artery CTO that was unable to be crossed with a standard wire-catheter approach, the Wingman catheter was able to cross 90% of occlusions with little associated morbidity. This device may prove useful within patients with complex disease by reducing procedural time and overall success.

ACKNOWLEDGMENTS

We thank Larry Miller, PhD for providing critical review and editorial support.

DATA AVAILABILITY STATEMENT

The data that support the findings of this study are available from the corresponding author upon reasonable request.

ORCID

John R. Laird  <https://orcid.org/0000-0003-2095-2191>

Marianne Brodmann  <https://orcid.org/0000-0001-6493-3799>

REFERENCES

- Johnston KW. Femoral and popliteal arteries: reanalysis of results of balloon angioplasty. *Radiology*. 1992;183:767-771.
- Conrad MF, Cambria RP, Stone DH, et al. Intermediate results of percutaneous endovascular therapy of femoropopliteal occlusive disease: a contemporary series. *J Vasc Surg*. 2006;44:762-769.
- Banerjee S, Sarode K, Patel A, et al. Comparative assessment of guidewire and microcatheter vs a crossing device-based strategy to traverse infrainguinal peripheral artery chronic total occlusions. *J Endovasc Ther*. 2015;22:525-534.
- Laird J, Joye J, Sachdev N, et al. Recanalization of infrainguinal chronic total occlusions with the crosser system: results of the PATRIOT trial. *J Invasive Cardiol*. 2014;26:497-504.
- Pigott JP, Raja ML, Davis T, Connect Trial Investigators. A multicenter experience evaluating chronic total occlusion crossing with the wildcat catheter (the CONNECT study). *J Vasc Surg*. 2012;56:1615-1621.
- Sethi S, Mohammad A, Ahmed SH, et al. Recanalization of popliteal and infrapopliteal chronic total occlusions using Viance and CrossBoss crossing catheters: a multicenter experience from the XLPAD registry. *J Invasive Cardiol*. 2015;27:2-7.
- Sewall LE. Treatment of chronic total occlusions using the Avinger ocelot crossing catheter. *Semin Intervent Radiol*. 2015;32:370-373.
- Lee HJ, Park SW, Chang IS, Jeon HJ, Park JH. Strategies for successful percutaneous revascularization of chronic total occlusion of the femoropopliteal arteries when the antegrade passage of a guide wire fails. *Korean J Radiol*. 2012;13:467-475.
- Bosiers M, Diaz-Cartelle J, Scheinert D, Peeters P, Dawkins KD. Revascularization of lower extremity chronic total occlusions with a novel intraluminal recanalization device: results of the ReOpen study. *J Endovasc Ther*. 2014;21:61-70.
- Gandini R, Volpi T, Pipitone V, Simonetti G. Intraluminal recanalization of long infrainguinal chronic total occlusions using the crosser system. *J Endovasc Ther*. 2009;16:23-27.
- Kirvaitis RJ, Heuser RR, Das TS, et al. Usefulness of optical coherent reflectometry with guided radiofrequency energy to treat chronic total occlusions in peripheral arteries (the GRIP trial). *Am J Cardiol*. 2004;94:1081-1084.
- Kirvaitis RJ, Parr L, Kelly LM, Reese A, Kaminen R, Heuser RR. Recanalization of chronic total peripheral arterial occlusions using optical coherent reflectometry with guided radiofrequency energy: a single center experience. *Catheter Cardiovasc Interv*. 2007;69:532-540.
- Michalis LK, Tsetis DK, Katsamouris AN, Rees MR, Sideris DA, Gourtsoyiannis NC. Vibrational angioplasty in the treatment of chronic femoropopliteal arterial occlusions: preliminary experience. *J Endovasc Ther*. 2001;8:615-621.
- Mossop PJ, Amukotuwa SA, Whitbourn RJ. Controlled blunt microdissection for percutaneous recanalization of lower limb arterial chronic total occlusions: a single center experience. *Catheter Cardiovasc Interv*. 2006;68:304-310.
- Saket RR, Razavi MK, Padidar A, Kee ST, Sze DY, Dake MD. Novel intravascular ultrasound-guided method to create transintimal arterial communications: initial experience in peripheral occlusive disease and aortic dissection. *J Endovasc Ther*. 2004;11:274-280.
- Scheinert D, Laird JR Jr, Schroder M, et al. Excimer laser-assisted recanalization of long, chronic superficial femoral artery occlusions. *J Endovasc Ther*. 2001;8:156-166.
- Staniloae CS, Mody KP, Yadav SS, Han SY, Korabathina R. Endoluminal treatment of peripheral chronic total occlusions using the crosser(R) recanalization catheter. *J Invasive Cardiol*. 2011;23:359-362.
- Cronenwett JL, Johnston KW. *Rutherford's Vascular Surgery*. 8th ed. Philadelphia, PA: Elsevier Saunders; 2014.
- Saaf F, Jaff M, Diaz-Sandoval L, et al. Chronic total occlusion crossing approach based on plaque cap morphology: the CTOP classification. *J Endovasc Ther*. 2018;25(3):284-291.

SUPPORTING INFORMATION

Additional supporting information may be found online in the Supporting Information section at the end of this article.

How to cite this article: Laird JR, Mathews SJ, Brodmann M, Soukas PA, Schmidt A, The Wing-It Trial Investigators. Performance of the Wingman catheter in peripheral artery chronic total occlusions: Short-term results from the international Wing-It trial. *Catheter Cardiovasc Interv*. 2021;97:310-316. <https://doi.org/10.1002/ccd.29366>