

An adult case of single atrium diagnosed using three-dimensional echocardiography

Bernas Altıntaş, Barış Yaylak, Erkan Baysal
Department of Cardiology, Diyarbakır Gazi Yaşargil Research and Education Hospital; Diyarbakır-Turkey

Introduction

Previously, complete absence of an interatrial septum (IAS) was thought to be a form of an atrioventricular septal defect involving the cleft mitral valve and interventricular communication. Ellis et al. (1) defined this condition as common atrium (CA). This congenital cardiac anomaly is especially observed in association with heterotaxy syndrome. Levy et al. (2) reported a case of complete absence of IAS without other cardiac defects; however, this condition was different from CA defined by Ellis et al. (1). They used the term single atrium (SA) to denote this anomaly.

Two-dimensional transthoracic echocardiography (2-D-TTE) is the preferred imaging method for the examination of IAS and concomitant congenital cardiac pathologies (3). Three-dimensional TTE (3-D-TTE) is a recently introduced tool for examining the heart; it enables the visualization of 3-D, complex and dynamic anatomic aspects of relevant cardiac structures. There has not been any case of SA diagnosed using 3-D-TTE. Here we present a unique case of an adult patient with SA diagnosed using 3-D-TTE.

Case Report

A 43-year-old woman was admitted to the emergency room with dyspnea and palpitation. On her physical examination, diastolic murmur of 3/6 degree severity, labial cyanosis, and digital clubbing were found. Electrocardiography (ECG) revealed atrial fibrillation with a ventricular rate of 116 beats/min. Apical 2-D-TTE views (Fig. 1) revealed the absence of IAS and the presence of right ventricular enlargement along with severe pulmonary hypertension and severe pulmonary insufficiency. The findings were consistent with Eisenmenger syndrome. 3-D-TTE examination showed complete absence of IAS (Fig. 2, Video 1). Mitral and tricuspid valves did not show any defects (Fig. 3, Video 2, 3). Other congenital heart defects were not detected via 3-D-TTE examination. Other pathologies associated with heterotaxy syndrome were not detected. The patient was treated with bosentan (for Eisenmenger syndrome) as well as furosemid and calcium channel blocker (for heart rate control). The symptoms were alleviated, and she attained New York Heart Association functional class I-II following 4-week

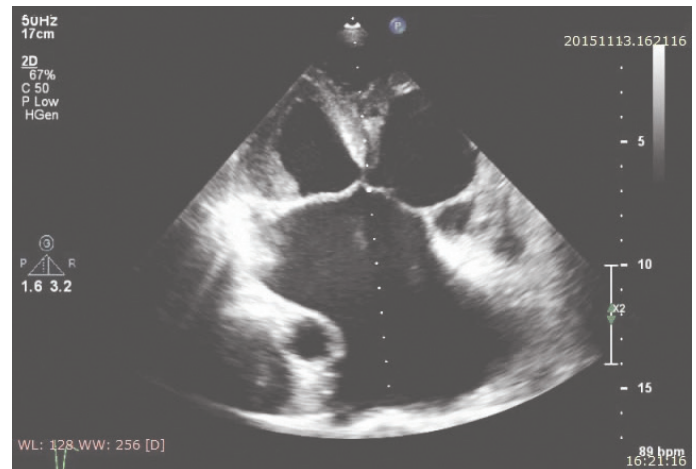


Figure 1. Two-dimensional apical four-chamber image of single atrium

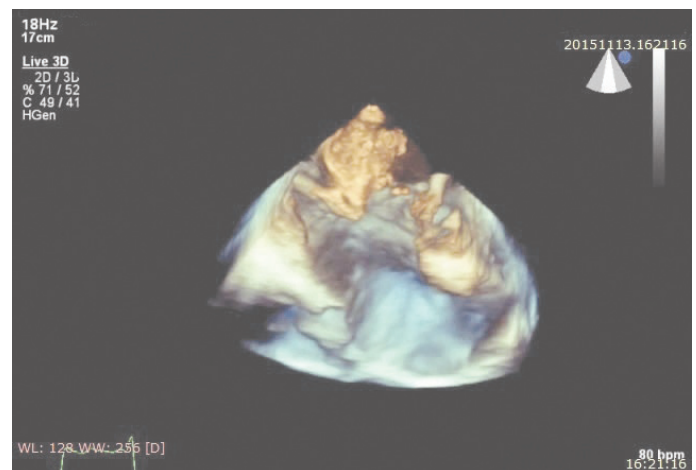


Figure 2. Three-dimensional image of single atrium. Complete absence of interatrial septum

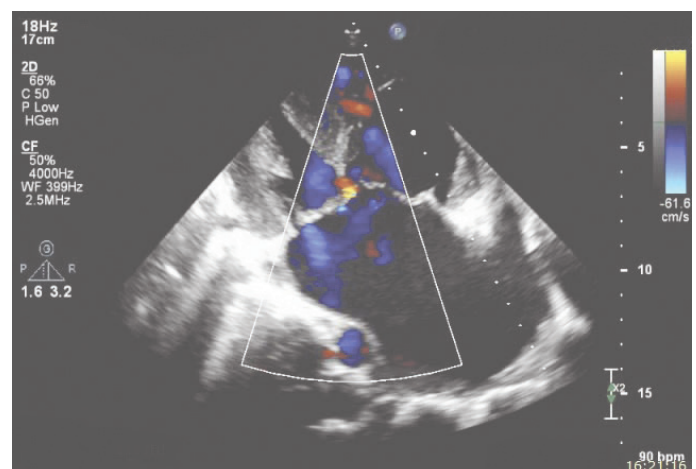


Figure 3. Two-dimensional apical four-chamber color Doppler image of atrioventricular (AV) valves

treatment. The patient received anticoagulation treatment with dabigatran 150 mg bid.

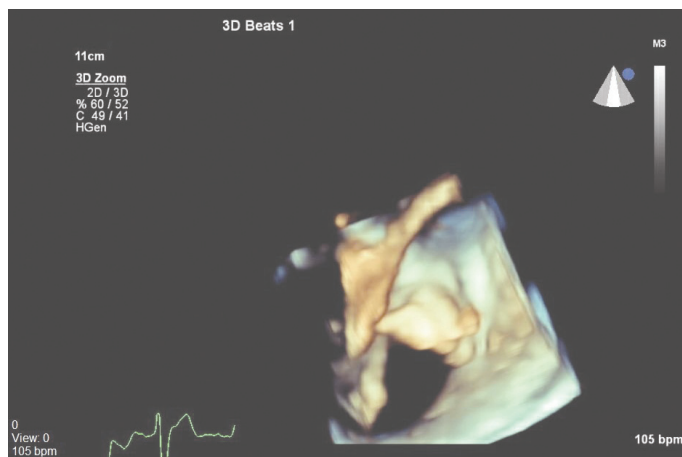


Figure 4. Three-dimensional image of mitral valve

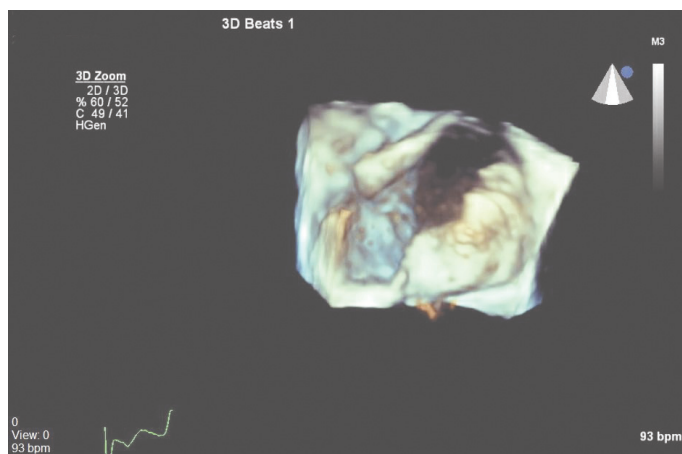


Figure 5. Three-dimensional image of tricuspid valve

Discussion

We present a case of SA evaluated in detail using 3-D-TTE. SA can be differentiated from CA by the absence of an atrioventricular valve pathology. Although clinical, physical, and hemodynamic findings of large-size atrial septal defect (ASD) are similar to those of SA, 2-D-TTE findings may not be enough to differentiate SA from these conditions and may often require use of TEE or cardiac magnetic resonance imaging.

Because IAS is a 3-D, complex and dynamic anatomic structure, 2-D-TTE examination can have limitations with respect to its evaluation (4). 3-D-TTE provides important additional data related to patients with difficult imaging windows or a complex 3-D anatomy (5). Further, 3-D imaging provides unique views of IAS and particularly enables face viewing of ASD and the surrounding fossa, thereby allowing accurate determination of the size and shape (6). Additionally, 3-D imaging reveals the relationship of ASD with surrounding cardiac structures such as the rims of surrounding tissue as well as helps view the existence of atrial superior and inferior limbic band tissues, the aortic root, and the atrioventricular valves (7). Moreover, 3-D-TTE can determine the precise size of the

defect and provide information that may be important for selecting the treatment modality (e.g., transcatheter closure or surgical repair) (8, 9). In our patient, 3-D-TTE accurately showed the absence of an interatrial septal remnant both at the roof of atria and the atrioventricular junction without any additional cardiac defect. Thus, we diagnosed our case with pure SA rather than large-size ASD.

We additionally examined the mitral and tricuspid valves to rule out a cleft mitral valve and concomitant tricuspid pathology using 3-D-TTE because 3-D-TTE has a higher image resolution for valvular structures and their relationship with the annulus, subchordal apparatus, and left ventricular cavity without the need for semi-invasive procedures such as TEE (Fig. 4, 5) (10). Our findings suggested that in patients with a good acoustic window, the data provided by 3-D-TTE allow SA to be differentiated from CA without need for an additional imaging procedure. Further, 3-D imaging facilitates the diagnosis of the cleft on the mitral or tricuspid valve, which is the key feature of CA.

Conclusion

We present the first adult case of SA using 3-D-TTE. This evaluation can provide complementary and valuable information that aids in the diagnosis and differentiation of adult congenital cardiac anomalies.

Video 1. Three-dimensional echocardiographic apical four chamber.

Video 2. Three-dimensional echocardiographic evolution of mitral valve.

Video 3. Three-dimensional echocardiographic evolution of tricuspid valve.

References

1. Ellis FH Jr, Kirklin JW, Swan HJ, Dushane JW, Edwards JE. Diagnosis and surgical treatment of common atrium. *Surgery* 1959; 45: 160-72.
2. Levy MJ, Salomon J, Vidne BA. Correction of single and common atrium, with reference to simplified terminology. *Chest* 1974; 66: 444-6.
3. Silvestry FE, Cohen MS, Armsby LB, Burkule NJ, Fleishman CE, Hijazi ZM, et al. Guidelines for the Echocardiographic Assessment of Atrial Septal Defect and Patent Foramen Ovale: From the American Society of Echocardiography and Society for Cardiac Angiography and Interventions. *J Am Soc Echocardiogr* 2015; 28: 910-58.
4. Perk G, Lang RM, Garcia-Fernandez MA, Lodato J, Sugeng L, Lopez J, et al. Use of real-time three-dimensional transesophageal echocardiography in intracardiac catheter based interventions. *J Am Soc Echocardiogr* 2009; 22: 865-82.
5. Kutty S, Smallhorn JF. Evaluation of atrioventricular septal defects by three-dimensional echocardiography: benefits of navigating the third dimension. *J Am Soc Echocardiogr* 2012; 25: 932-44.
6. Roberson DA, Cui W, Patel D, Tsang W, Sugeng L, Weinert L, et al. Three-dimensional transesophageal echocardiography of atrial septal defect: a qualitative and quantitative anatomic study. *J Am Soc Echocardiogr* 2011; 24: 600-10.

7. Seo JS, Song JM, Kim YH, Park DW, Lee SW, Kim WJ, et al. Effect of atrial septal defect shape evaluated using three-dimensional transesophageal echocardiography on size measurements for percutaneous closure. *J Am Soc Echocardiogr* 2012; 25: 1031-40.
8. Watanabe N, Taniguchi M, Akagi T, Toh N, Kusano K, Ito H, et al. Usefulness of the right parasternal approach to evaluate the morphology of atrial septal defect for transcatheter closure using two-dimensional and three-dimensional transthoracic echocardiography. *J Am Soc Echocardiogr* 2012; 25: 376-82.
9. Biaggi P, Greutmann M, Crean A. Utility of three-dimensional transesophageal echocardiography: anatomy, mechanism, and severity of regurgitation in a patient with an isolated cleft posterior mitral valve. *J Am Soc Echocardiogr* 2010; 23: 1114.
10. Barrea C, Levasseur S, Roman K, Nii M, Coles JG, Williams WG, et al. Three-dimensional echocardiography improves the understanding of left atrioventricular valve morphology and function in atrioventricular septal defects undergoing patch augmentation. *J Thorac Cardiovasc Surg* 2005; 129: 746-53.

Address for Correspondence: Dr. Bernas Altıntaş
Diyarbakır Gazi Yaşargil Eğitim ve Araştırma Hastanesi,
Kardiyoloji Bölümü, Peyas Mahallesi, Selahaddin Eyyubi Bulvarı,
229. Sokak, Hamzaoğulları Stesi, B-blok, No: 20
Kayapınar/Diyarbakır-*Türkiye*
Fax:+90 412 258 00 60 E-mail: drbernas@yahoo.com.tr
©Copyright 2017 by Turkish Society of Cardiology - Available online
at www.anatoljcardiol.com
DOI:10.14744/AnatolJCardiol.2017.7702



From Prof. Dr. Arif Akşit's collection's