



Case Report

Double neuraxial catheter (Subarachnoid and epidural) in obese patient cancer surgery: A case report

Lou'i Al-Husinat^{a,*}, Fannia Barletta^b, Vittoria Gammaldi^c, Alameen Alsabbah^d, Domenico Gammaldi^e

^a Department of Clinical Medical Sciences, Faculty of Medicine, Yarmouk University, Irbid, 21163, Jordan

^b Università degli Studi della Campania "Luigi Vanvitelli", Napoli, Italy

^c Università degli Studi di Napoli "Federico II", Napoli, Italy

^d Faculty of Medicine, Yarmouk University, Irbid, Jordan

^e AORN ed Alta Specialità "San Giuseppe Moscati", Avellino, Italy



ARTICLE INFO

Keywords:

Cancer
Double anesthesia
Obesity
Epidural
Subarachnoid

ABSTRACT

Introduction: Morbid obesity is one of the major concerns when performing surgeries, due to higher risks of anesthetic complications. Combined spinal and epidural (CSE) anesthesia technique is used effectively in variety of surgical procedures.

Case presentation: Our patient is a 58-year old female with a Body Mass Index (BMI) of 44.53 who presented to the emergency department complaining of an abdominal pain of a renal nature. She was found to have an abdominal mass suggestive of an axial mass or a Gastro Intestinal Stromal Tumor (GIST) and was scheduled for surgery. Due to the risks associated with general anesthesia, a double neuraxial catheter (subarachnoid and epidural) was the anesthetic method of choice.

Discussion: Overweight and obesity represent a rapidly growing threat to the health of populations in an increasing number of countries. The first report using the double catheter technique described a parturient with a BMI of 76 kg/m² who had a lumbar Combined Spinal Epidural (CSE) catheter placed for intraoperative anesthesia and postoperative pain management. In the published literature CSE technique use is limited to obstetric procedure of obese females.

Conclusion: In our case it is highlighted how an obese patient, with severe comorbidities that can jeopardize the success of the treatments, can be discharged in a few days by performing an "unconventional" but effective anesthetic technique.

1. Introduction

Obesity is defined as a Body Mass Index (BMI) of 30 kg/m² or more [1]. In the period between 1980 and 2013 the prevalence of obesity is 47.1% for children and 27.5% for adults [2]. The use of general anesthesia (GA) in major surgeries of high risk obese patients has its documented disadvantages [3]. Combined spinal and epidural (CSE) anesthesia technique is used effectively in pain relief and wide spectrum of surgical procedures. CSE technique may reduce the disadvantages associated with the use of spinal or epidural anesthesia alone alongside the preservation of their advantages. CSE technique offers faster onset, higher efficacy, minimal local toxicity, less rates of inadequate block and prolongation of time under analgesia into the post-operative period [4].

CSE technique has been reported to be used in variety of procedures including general surgery, gynecological and urological surgery, and trauma and orthopedic surgery of lower limb [5]. This case report demonstrates one of the methods of anesthesia that can be safely used in high-risk morbidly obese patients. The work has been reported in line with the SCARE 2020 criteria [6].

2. Case presentation

A 58-year-old female presented to the emergency department complaining from a renal colic pain. The patient has a Body Mass Index (BMI) of 44.53 (weight of 114kg and height of 160cm) and a blood pressure of 135/80. She is known to have essential arterial hypertension,

* Corresponding author.

E-mail address: Loui.husinat@yu.edu.jo (L. Al-Husinat).

<https://doi.org/10.1016/j.amsu.2022.104446>

Received 1 July 2022; Received in revised form 1 August 2022; Accepted 12 August 2022

Available online 17 August 2022

2049-0801/© 2022 The Authors. Published by Elsevier Ltd on behalf of IJS Publishing Group Ltd. This is an open access article under the CC BY-NC-ND license (<http://creativecommons.org/licenses/by-nc-nd/4.0/>).

non-obstructive hypertrophic cardiopathy, hypercholesterolemia, hypertriglyceridemia, obesity, chronic respiratory failure with Obstructive Sleep Apnea Syndrome (OSAS) with an apnea hypopnea index >30 and under treatment with nighttime CPAP. There is no history of smoking or alcohol consumption. She is on Verapamil Hydrochloride (80mg three times a day); Omeprazole (20mg once a day); Furosemide (25mg once a day); Olmesartan Medoxomil + Hydrochlorothiazide (20/12.5mg once a day); Ezetimibe (10mg once a day); Acetylsalicylic acid (100mg once a day); Buccal Lorazepam (1mg twice a day).

The patient underwent a Computerized Tomography (CT) urogram that showed a stone in the left kidney of 15mm in diameter. Above the uterine fundus and indissociable from it, a voluminous oval mass of about 14.7*12*12.7 cm was observed, with an uneven density due to the presence of a more hypodense internal area, with clear and regular margins without significant contrasting impregnation. A liquid layer was associated in the right iliac fossa, in the space of the Retzius and in the Douglas (Fig. 1).

A Magnetic Resonance Image (MRI) was performed to the patient and showed a voluminous oval neof ormation in the mesogastric site with clear and regular margins and with the impregnation of the solid component in the late phase. As from the predominant stromal component, the lesion is clearly separated from the left ovary and uterus while making intercourse with the right ovary and with the sigmoid that may be suggestive of adnexial mass or a Gastro Intestinal Stromal Tumor (GIST) (Fig. 2).

An Esophagogastroduodenoscopy (EGD) was performed and showed, at the angulus level, a pedunculated polyp of 15–20 mm with an adenomatous glandular pattern which was resected during the surgery (Fig. 3).

A cardiological consultation with Electrocardiogram (ECG) and cardiac echocolor Dopplergraphy were requested. Cardiac auscultation showed a systolic murmur 2/6. and ECG showed a sinus rhythm in addition to a left axis deviation. On echocardiogram, a left ventricle of normal size moderately hypertrophic, with greater apical expression was noticed, in the absence of a dynamic gradient. An aortic sclerosis with mild stenosis of an 8 mm Hg pressure gradient were noticed.

The patient has retrognathism (Angle class II), with the presence, in the upper dental arch, of fragile and unstable teeth associated with a macroglossia (Fig. 4) and reduced mobility of the neck which led to hypothesize, with high probability, a difficulty in orotracheal intubation as the neck has a circumference of more than 40 cm. The patient has been classified to class 3 of the Mallampati classification. A high Mallampati score (class 3 or 4) is associated with more difficult intubation as well as a higher incidence of obstructive sleep apnea.

After consultation with the surgeon, and after informing the patient in detail about the procedures to be performed, the patient's consent to the anesthetic technique was acquired and the surgery was scheduled.

A central line was placed using ultrasonography using the Seldinger

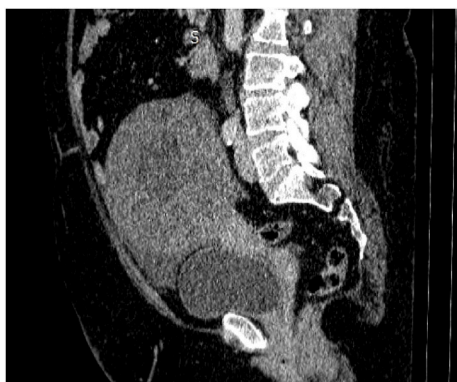

Fig. 1. Computed Tomography scan of the pelvic mass.

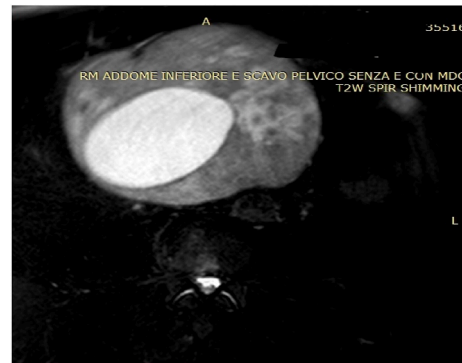

Fig. 2. A Pelvic Mass on a T2 weighted MRI at the level of L1 vertebra.

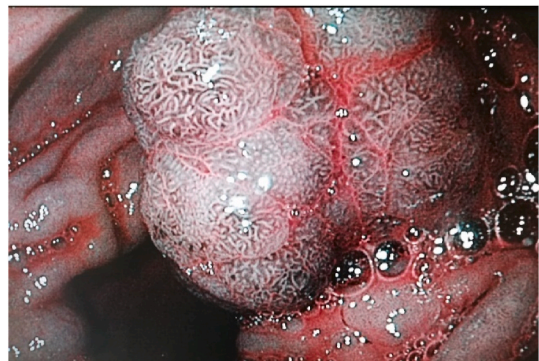

Fig. 3. Upper endoscopy showing a pedunculated polyp of the gastric antrum.

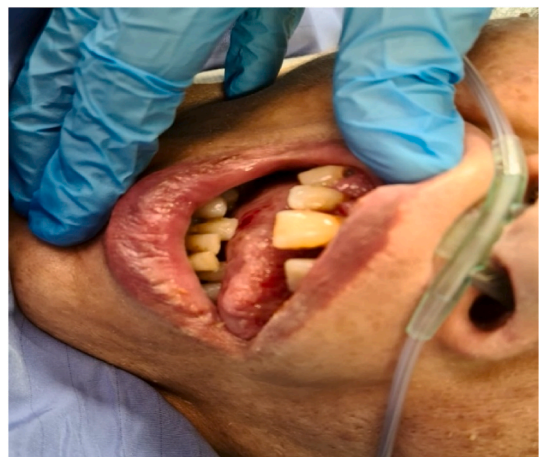

Fig. 4. Fragile and unstable teeth associated with a macroglossia.

technique the day before the surgery in the right internal jugular vein. The control of correct positioning was performed with carotid ultrasound and with X-ray of the chest.

The choice of anesthetic technique was made by examining different elements including severe obesity, the presence of OSAS under treatment with night CPAP, high predictivity of difficult access to the airways, wide median laparotomy (xipho-pubic), the use of a Thompson type retractor, high probability of intestinal resection, waiting time for extemporaneous histological examination, and the need to perform an endoscopic resection of a large pedunculated polyp of the gastric antrum to the same patient. The previously mentioned elements lead to an unpredictable estimation of the duration of the surgical procedure.

On arrival in the operating room, premedication was performed with

Dexmedetomidine 110mcg via an intranasal mucosal atomization device, 55 mcg per nostril. Pantoprazole 40mg, Ondansetron 8mg, and Dexamethasone 8mg were administered preoperatively to prevent postoperative nausea and vomiting in addition to a preoperative prophylactic antibiotic. The right radial artery was catheterized with the Seldinger technique for monitoring blood pressure. Through the central venous catheter (CVC), sedation was initiated with Dexmedetomidine at 0.6/mcg/h.

As shown in (Fig. 5A) an epidural catheter was placed. In the sitting position of the patient and with continuous monitoring of pulse oximetry, accurate disinfection of the area chosen for the puncture is carried out with packaging of the operating field. The choice fell on the T8/T9 space, for the analgesic coverage of the C7/T12 dermatomes, by carrying out a paramedian access, preceded by a superficial (25G needle) and deep (21G needle) local anesthesia wheal of the space was selected for access with Lidocaine 2%.

The set used was a Temena® with a 17G Tuohy Needle. The search for the epidural space was easy, at the first attempt and with the liquid mandrel technique. Five milliliters of normal saline were injected to correct space dilation. A 19G catheter, with a total length of 90cm, was inserted for 4cm of depth. A subcutaneous tunneling was performed with an external rescue loop that prevented inadvertent and inappropriate external tractions from acting on the tip of the correctly positioned catheter. A transparent Tegaderm-type patch dressing allowed the catheter and connector assembly to be guided to the patient's left arm where it is secured with premedicated adhesive gauze.

As shown in (Fig. 5A), a subarachnoid catheter was placed. By maintaining the patient's sitting position and with continuous monitoring of pulse oximetry, accurate disinfection of the area chosen for puncture is carried out with packaging of the operating field.

The choice fell on the L2/L3 space, for the analgesic coverage of the T4/S4 dermatomes, using a median approach, preceded by a superficial (25G needle) and deep (18G needle) local anesthesia wheal of the space selected for access with Lidocaine 2%. The set used was a Temena® with 21G Tuohy Needle. The search of the subarachnoid space was easy, at the first attempt and with evidence of clear liquor. A 24G mandrel catheter was inserted inside the subarachnoid space for about 6 cm, covering the external path with a protective sheath and medicating, also here with a transparent adhesive plaster type Tegaderm allows to lead the catheter and connector assembly up to the patient's left arm where it was fixed with a premedicated adhesive gauze.

The two catheters were clearly distinguishable from each other due to the different structure, consistency and color of the connectors which are always visible to the anesthetist (Fig. 5B).

In the subarachnoid catheter and 10 minutes before the surgical incision Levobupivacaine 0.5% 5mg (1ml), Dexmedetomidine (200mcg/50ml) 10mcg (2.5ml) and Saline Solution (1ml) were administered.

Moreover, in the epidural catheter, and 5 minutes before the surgical incision a first bolus of Levobupivacaine 0.5% 10mg (2ml), Dexmedetomidine 50mcg (0.5ml), and Ketamine 100mg/10ml 30mg (3ml) in addition to normal saline up to 12ml were administered. Then 45 minutes after the first bolus, a second bolus of Levobupivacaine 0.5% 5mg and 10ml of normal saline was administered. Afterwards (55 minutes after the second bolus) a third bolus of Levobupivacaine 0.5% 5mg and 10ml of normal saline was given. When starting the suture of the abdominal wall, an elastomer is placed with Levobupivacaine 275mg and 275ml of normal saline (14ml/h for 30 minutes, then 10ml/h). Multi-parameter monitoring was performed with 2-lead ECG, pulse oximetry, arterial blood pressure, central venous pressure, bispectral index, urine output, and blood loss. The patient was sedated but not intubated (continuous neurological contact).

Hemodynamic, respiratory and neurological parameters remained stable for the entire duration of the surgery. In particular, the Bispectral Index was maintained at values between 70 and 90 by virtue of sedation with intravenous Dexmedetomidine and, in addition, of Propofol in refracted boluses with an average dosage of 10mg every 25–30 minutes.

At the end of the surgery, the patient was painless and alert. A Xiphopubic incision was made then a Thompson's dilator was placed with subcostal and pelvic blades. Abundant ascitic fluid upon opening was noticed. In the right adnexal site, neoformation of the right ovary without apparent infiltrative relationships with the pelvic or abdominal organs was seen (Fig. 6A). No macroscopic signs of peritoneal carcinosis nor of repetitive intra-abdominal lesions were found. A Section with Echelon flex vascular load of the ovarian peduncle and the round ligament and en bloc removal of the ovary and right tuba were performed. Resection with echelon flex vascular load of the gastrocolic ligament and omentectomy were done (Fig. 6B). The extemporaneous histological examination orientates for thecoma with absence of neoplastic cells. In the light of this report, it was decided not to proceed with hysterioansectomy.

During the operation, and pending the extemporaneous histological examination, resection, in Endoscopy and after infiltration with Adrenaline, with diathermic loop, of the polyp with short peduncle (Fig. 6C) and wide implant base with a head of about 20 mm and with a glandular pattern was performed. The two fragments were recovered with RothNet.

At the end of the surgery, the subarachnoid catheter was removed, and the patient returned to the ward calmly and without pain.

Checkups were carried out at 3, 6, 12, 24 hours of the analgesia status which confirmed its excellent control. Canalized during the night (12 hours after the end of the intervention). The postoperative course continues satisfactorily to the extent that it was possible to be discharged at home on the 4th day.

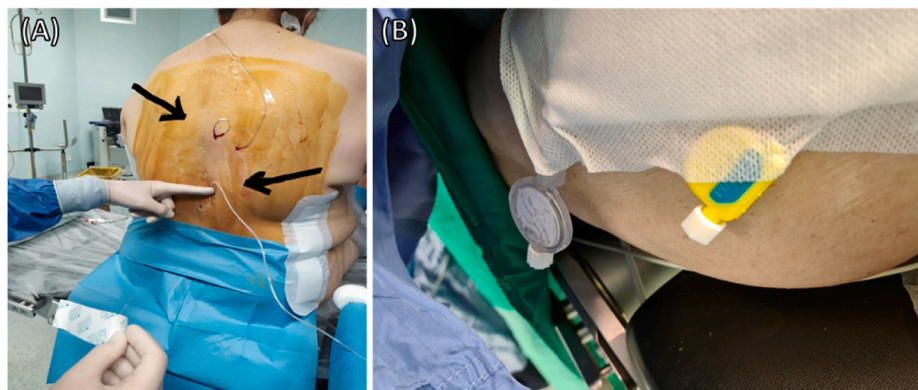


Fig. 5. A: The upper arrow indicates the positioned epidural catheter, and the down arrow indicates the positioned subarachnoid catheter. B: Connectors and filter on the patient's left arm. Yellow corresponds to the subarachnoid catheter, white to the epidural catheter. . (For interpretation of the references to color in this figure legend, the reader is referred to the Web version of this article.)

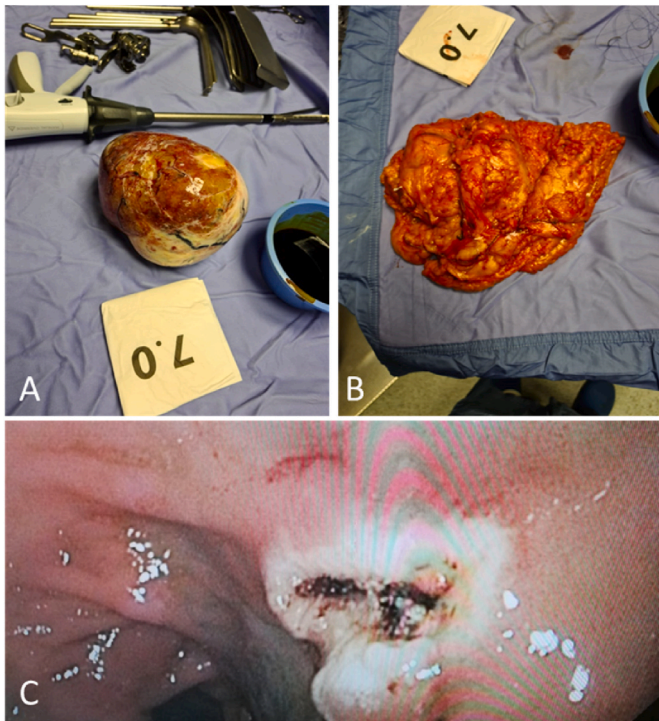


Fig. 6. A: a pelvic mass, B: the resected omentum, and C: a resected polyp.

3. Discussion

Overweight and obesity represent a rapidly growing threat to the health of populations in an increasing number of countries. Indeed, they are now so common that they are replacing more traditional problems such as malnutrition and infectious diseases as the most significant causes of ill-health. Obesity comorbidities include coronary heart disease, hypertension and stroke, certain types of cancer, non-insulin-dependent diabetes mellitus, gallbladder disease, dyslipidemia, osteoarthritis and gout, and pulmonary diseases, including sleep apnea [7].

Among the sequelae of severe obesity that interests our discussion there is Obstructive Sleep Apnea Syndrome (OSAS), characterized by repetitive partial or complete airway collapse during sleep causing hypoxemia and/or hypercarbia [8].

Through a literature review and expert opinion, a prevalence of 12,329,614 patients with moderate-severe OSA (S) in Italy (27% of the adult population) is estimated, of which 65% are males, and an overall prevalence of over 24 million people aged between 15 and 74 years (54% of adult's population). Based on expert opinions and data provided by the Italian association of apneic patients, it is estimated that only 460,000 moderate-severe patients are diagnosed (4% of the estimated prevalence) and 230,000 treated (2% of the estimated prevalence), suggesting a substantial gap in both diagnosis and treatment [9].

Undiagnosed and hence unsuspected OSA may lead to perioperative complications including difficult mask ventilation and/or intubation, postoperative reintubation, cardiac dysrhythmias and increased hospital length of stay [10–12].

Among the risk factors for the development of OSA, obesity has the most influence especially in those <50 years old. and this is bidirectional [13].

Studies on the relationship between weight change and progression and regression of OSA have found a strong correlation [14].

OSA is also associated with increased sensitivity to central and peripheral effects of opioids.

Physical examination of obese and OSAS patients who are candidates for surgery should also include: airway, nasopharyngeal anatomy, neck circumference and tongue volume.

While anesthetic drug-dosing is typically based on patient weight and clinical condition, in obesity the pharmacokinetic parameters of medications are altered. In obese patients, the amount of adipose tissue increases in proportion to the increase in total body weight, while the amount of lean body weight remains relatively constant resulting in a reduced proportion of lean body weight per kilogram. Consequently, the volume of distribution for lipophilic drugs is increased in obesity [15].

Several studies have reported that obesity is an independent risk factor for perioperative venous thromboembolism (VTE) [16].

The already high risk for VTE is further exacerbated with progressively higher BMI, prolonged surgical time, older age, male sex, history of OSA, obesity hypoventilation syndrome and a previous history of VTE [17].

The American Society for Bariatric and Metabolic Surgery in association with American Association of Clinical Endocrinologists and The Obesity Society issued guidelines which recommend that all bariatric surgical patients receive mechanical prophylaxis, early ambulation and chemoprophylactic interventions with low molecular weight heparin (LMWH) or unfractionated heparin [18].

For some time, it has been seen that the single Continuous Thoracic Spinal or Peridural Anesthesia without resorting to tracheal intubation, therefore subjected to simple light sedation, is a valid alternative to general anesthesia in high-risk older patients undergoing major abdominal surgery [19]. But the idea of the double neuraxial catheter is linked to the intra and perioperative management of obese pregnant women who are candidates for caesarean section.

The first report using this double catheter technique described a parturient with a BMI of 76 kg/m² who had a lumbar Combined Spinal Epidural (CSE) catheter placed for intraoperative anesthesia and a low thoracic epidural catheter used for postoperative pain management [20]. A 2015 case series reported the use of a low thoracic epidural catheter combined with a continuous lumbar spinal catheter in three super obese parturients (BMI 73–95 kg/m²) who had high vertical midline incisions for cesarean delivery [21].

4. Conclusion

The cases of anesthesia with double neuraxial catheter described in the literature are almost exclusively referred to obese or super obese pregnant women for the management of caesarean section.

In our case it is highlighted how an obese patient, with severe comorbidities that can jeopardize the success of the treatments, can be discharged in a few days by performing an “unconventional” but effective anesthetic technique, not only for surgical anesthesia but also for a satisfactory perioperative course.

The double catheter technique is therefore far from being considered routine in major abdominal surgery, but it can become an arrow in the quiver of an experienced anesthetist, in selected cases where the risk of complex IOT, severe obesity and severe respiratory disease and complexity of surgery may all be together, the cause of possible perioperative complications.

Ethical approval

Ethical approval for case reports and case series are waived from any institutional review board approval according to the ongoing regulations of Yarmouk university.

Sources of funding

The author received no specific funding for this work.

Author contributions

Lou'i Al-Husinat and Fannia Barletta: Case report design and patient medical and surgical care.

Lou'i Al-Husinat, Vittoria Gammaldi, and Alameen Alsabbah: Wrote the initial draft of the case report.

Domenico Gammaldi: revised the manuscript.

All authors read and approved the content of the submitted case report.

Registration of research studies

This case report is not eligible for obtaining a research registry since it only contains a report of a known entity with no new surgical or medical interventions.

Guarantor

Lou'i Al-Husinat.

Declaration of competing interest

The authors declare no conflict of interest.

References

- [1] C.M. Apovian, Obesity: definition, comorbidities, causes, and burden, *Am. J. Manag. Care* 22 (7 Suppl) (2016) s176–s185.
- [2] M. Ng, T. Fleming, M. Robinson, B. Thomson, N. Graetz, C. Margono, et al., Global, regional, and national prevalence of overweight and obesity in children and adults during 1980–2013: a systematic analysis for the Global Burden of Disease Study 2013, *Lancet* (London, England) 384 (9945) (2014) 766–781.
- [3] R. Domi, H. Laho, Anesthetic challenges in the obese patient, *J. Anesth.* 26 (5) (2012) 758–765.
- [4] N. Rawal, A. Van Zundert, B. Holmström, J.A. Crowhurst, Combined spinal-epidural technique, *Reg. Anesth.* 22 (5) (1997) 406–423.
- [5] N. Rawal, B. Holmström, The combined spinal–epidural technique, *Best Pract. Res. Clin. Anaesthesiol.* 17 (3) (2003) 347–364.
- [6] R.A. Agha, T. Franchi, C. Sohrabi, G. Mathew, A. Kerwan, The SCARE 2020 guideline: updating consensus surgical CAse REport (SCARE) guidelines, *Int. J. Surg.* 84 (2020) 226–230.
- [7] Obesity: preventing and managing the global epidemic, World Health Organ. Tech. Rep. Ser. 894 (i–xii) (2000) 1–253. Report of a WHO consultation.
- [8] L.H. Lang, K. Parekh, B.Y.K. Tsui, M. Maze, Perioperative management of the obese surgical patient, *Br. Med. Bull.* 124 (1) (2017) 135–155.
- [9] P. Armeni, L. Borsoi, F. Costa, G. Donin, A. Gupta, Cost-of-Illness Study of Obstructive Sleep Apnea Syndrome (OSAS) in Italy, 2019.
- [10] S. Sato, M. Hasegawa, M. Okuyama, J. Okazaki, Y. Kitamura, Y. Sato, et al., Mask ventilation during induction of general anesthesia: influences of obstructive sleep apnea, *Surv. Anesthesiol.* 126 (1) (2017) 28–38.
- [11] Y.J. Kondo, T. Okutomi, S.J.A. Hoka, Analgesia, Beware of gastric tube! 95 (4) (2002) 1122.
- [12] T. Moore, S. Gullisby, T. Rabben, PJCad Eriksson, Sleep-disordered breathing: a novel predictor of atrial fibrillation after coronary artery bypass surgery, *Coron. Artery Dis.* 7 (6) (1996) 475–478.
- [13] S.A. Joosten, G.S. Hamilton, M.T.J.C. Naughton, Impact of weight loss management in OSA, *Chest.* 152 (1) (2017) 194–203.
- [14] A.B. Newman, G. Foster, R. Givelber, F.J. Nieto, S. Redline, TJAoim Young, Progression and regression of sleep-disordered breathing with changes in weight: the Sleep, Heart Health Study 165 (20) (2005) 2408–2413.
- [15] Y. Leykin, L. Miotto, T. Pellis, Pharmacokinetic considerations in the obese, *Best Pract. Res. Clin. Anaesthesiol.* 25 (1) (2011) 27–36.
- [16] A. Sood, F. Abdollah, J.D. Sammon, K. Majumder, M. Schmid, J.O. Peabody, et al., The effect of body mass index on perioperative outcomes after major surgery: results from the national surgical quality improvement program (ACS-NSQIP) 2005–2011, *World J. Surg.* 39 (10) (2015) 2376–2385.
- [17] M.K. Gould, D.A. Garcia, S.M. Wren, P.J. Karanicolas, J.I. Arcelus, J.A. Heit, et al., Prevention of VTE in nonorthopedic surgical patients: antithrombotic therapy and prevention of thrombosis, 9th ed: American college of chest physicians evidence-based clinical practice guidelines, *Chest* 141 (2 Suppl) (2012) e227S–e77S.
- [18] ASMBS updated position statement on prophylactic measures to reduce the risk of venous thromboembolism in bariatric surgery patients, *Surg. Obes. Relat. Dis. : Off. J. Am. Chem. Bariat. Surg.* 9 (4) (2013) 493–497.
- [19] P. Vincenzi, R. Starnari, L. Faloia, R. Grifoni, R. Bucchianeri, L. Chiodi, et al., Continuous thoracic spinal anesthesia with local anesthetic plus midazolam and ketamine is superior to local anesthetic plus fentanyl in major abdominal surgery, *Surg. Open. Sci.* 2 (4) (2020) 5–11.
- [20] C.M. Polin, B. Hale, A.A. Mauritz, A.S. Habib, C.A. Jones, Z.Y. Strouch, et al., Anesthetic management of super-morbidly obese parturients for cesarean delivery with a double neuraxial catheter technique: a case series, *Int. J. Obstet. Anesth.* 24 (3) (2015) 276–280.
- [21] N.J. McDonnell, M.J. Paech, The management of a super morbidly obese parturient delivering twins by caesarean section, *Anaesth. Intensive Care* 35 (6) (2007) 979–983.