

Rehabilitation of an ocular defect with intraorbital implant and custom-made prosthesis using digital photography and gridded spectacle

Dolanchanpa Dasgupta, Kaustubh Das¹, Rajwinder Singh²

Department of Prosthodontics and Crown and Bridge, Kusum Devi Sunderlal Dugar Jain Dental College and Hospital, ¹Department of Maxillofacial Surgery, Apollo Gleneagles Hospitals, ²Department of Prosthetic Dentistry, North Bengal Dental College, Kolkata, West Bengal, India

Abstract

Accidental trauma involving the eye may necessitate surgical removal of the eye ball. Immediate management should consider future prosthetic rehabilitation. Insertion of eye ball implant after enucleation or evisceration preserves socket anatomy, maintains sulcus and fornix which ensures proper retention of ocular prosthesis in future. Placement of intraorbital ball implant also reduces the weight as well as enhances motility of the prosthesis, thus imparting life-like appearance. Custom-made acrylic prosthesis has been shown to deliver superior functional and esthetic result. Exact positioning of the iris disc on a custom-made scleral blank is critical from esthetic point of view. This clinical report describes prosthetic rehabilitation of an anophthalmic socket where intraorbital ball implant was inserted during evisceration. Custom-made acrylic ocular prosthesis with a prefabricated iris button was used. Here, digital photography and a specially fabricated spectacle gridded with mm scale were used for positioning iris button on the ocular prosthesis. These two methods of centration of iris button may be used to reduce chairside time and increase patient cooperation with a positive clinical outcome.

Keywords: Centration of iris, eye ball implant, ocular prosthesis

Address for correspondence: Dr. Dolanchanpa Dasgupta, 3 Nandan Palli, P. O. Barisha, Kolkata - 700 008, West Bengal, India.

E-mail: drdolanchanpa@gmail.com

Received: 12th July, 2018, **Accepted:** 06th June, 2019

INTRODUCTION

Accidental trauma or any pathology involving the eye may necessitate surgical removal of the eye ball. Depending on the severity of the situation, surgical management may include evisceration, enucleation, or exenteration.^[1] The deformities that result from enucleation of an eye include enophthalmos, retraction of the upper eyelid, deep upper lid sulcus, lower lid laxity, and ptosis that are summarized as “Post Enucleation/


Post Evisceration Socket Syndrome” (PESS).^[2] PESS causes significant functional impairment and psychological distress to the patient.^[3] Rehabilitation with a prosthetic eye can restore the social acceptance, help alleviate the psychological wellbeing, and improve the quality of life.^[4]

Several techniques have been used for fabrication of artificial eyes. Empirically fitting a stock eye, modifying

This is an open access journal, and articles are distributed under the terms of the Creative Commons Attribution-NonCommercial-ShareAlike 4.0 License, which allows others to remix, tweak, and build upon the work non-commercially, as long as appropriate credit is given and the new creations are licensed under the identical terms.

For reprints contact: reprints@medknow.com

How to cite this article: Dasgupta D, Das K, Singh R. Rehabilitation of an ocular defect with intraorbital implant and custom-made prosthesis using digital photography and gridded spectacle. J Indian Prosthodont Soc 2019;19:266-71.

Access this article online	
Quick Response Code:	Website: www.j-ips.org
	DOI: 10.4103/jips.jips_226_18

a stock eye, and the custom eye technique are the most commonly used techniques. The custom-made acrylic resin ocular prosthesis provides more esthetic and precise results.^[4,5]

Ideally, the volume of the prosthetic eye should be about 2 ml whereas removal of an eye ball results in a volume deficit of 7 ml. Rehabilitation of around 7 ml defect with acrylic prosthesis makes it heavier, which cannot be supported indefinitely by the lower eyelid as it stretches because of its laxity.^[3] The lost volume can be shared between the prosthesis and a buried eyeball implant enveloped within the sclera. A volume replacement of about 4 ml by a ball implant with the scleral covering is possible. Finally, a light acrylic prosthesis of about 2 ml volume supported by a ball implant can best restore the cosmetic eye.^[3] Pneumatic orbital implant can also be used to make lightweight prosthesis.^[6] However, intraorbital implants stimulate intraorbital growth, reduce socket contracture, prevent the occurrence of PESS, provide an ideal socket with adequately deep fornices, and thus enhance the prosthetic outcome.^[2] Ball implant also improves the motility of the artificial eye, thereby contributing to the normal appearance of the anophthalmic orbit.^[2,3]

Iris and pupil from a prefabricated eye which closely matches the natural eye can be used on a custom-made scleral blank to avoid the complex painting procedure. The centration of the iris and marking of the corneal plane are critical to avoid squint-eyed appearance and to achieve life-like appearance.^[7,8] Various methods used to achieve symmetry of the two eyes are using the interpupillary distance, using Hirschberg's test (light reflex is kept at the center of the acrylic model), inscribing a circle (based on the visual judgment) in the acrylic base, using iris corneal buttons (positioned on wax and symmetries by trial and error), using facial landmarks, using a pupillometer, using transparent grid, etc.^[8,9] Every method has its own merits and demerits. The recording of facial measurements is technique sensitive and largely depends on patient cooperation because of the movement of the eye ball.

This case report presents a novel approach for exact positioning of the iris using digital photography^[4] and gridded acrylic glasses^[8,10] during the fabrication of the ocular prosthesis. The objective of this report is to try a simple procedure which will be feasible to use in every clinical setup. This report also highlights the essential role of ball implant in prosthetic ocular rehabilitation.

CASE REPORT

A 32-year-old healthy, qualified construction worker was using a grinding machine wearing safety goggles. Unfortunately, the blade of the machine came off and struck his face at high velocity, rupturing the right eyeball. There was soft-tissue laceration involving the right cheek, upper and lower eyelids, eyebrow, forehead, and right orbit [Figure 1].

Surgical procedure

Once under general anesthesia, the dissection was done along the choroid to remove remnants of the globe. After evisceration, a 14 mm diameter hydroxyapatite ball implant (G-EYE Modified Hydroxyapatite eye sphere, size MHAE 14, Surgiwear) was inserted into the intraconal fat, was covered with sclera, and was secured with 8-0 polyglactin 910 (Vicryl® Ethicon) suture [Figure 2].^[10] Finally, the sclera and cornea were sutured using 6-0 polyglactin 910 (Vicryl® Ethicon) and 6-0 Nylon. The eyelids were repositioned in unstrained relationship and closed with 6-0 Nylon (Ethilon®, Ethicon). Finally, the scalp soft tissue was closed in layers using 3-0 polyglactin 910 (Vicryl® Ethicon) and 6-0 Nylon (Ethilon®, Ethicon). The size of the implant was selected using the formula: axial length of the contralateral eye – 3 mm = implant diameter for evisceration, which allows a space for a prosthesis of 1.5 to 2.5 mL.^[11,12]

Prosthetic rehabilitation

The definitive ocular prosthesis can be done 10–14 days following surgery.^[13] The patient came for the prosthetic replacement of the lost eye after 4 months of the surgery. Socket was evaluated to determine the internal anatomy, presence of cicatricial bands, tissue undercuts, depth of fornices, degree of mobility, the position of the palpebral

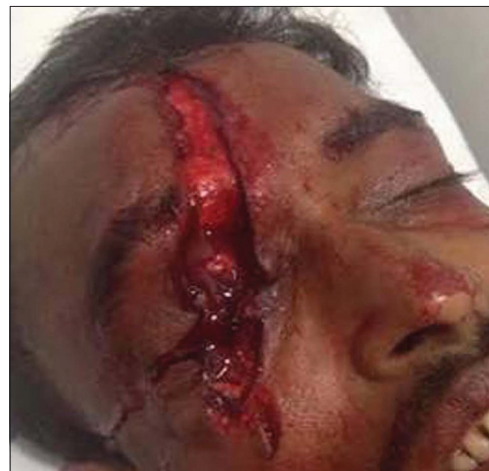

Figure 1: Patient

fissure, etc. [Figure 3].^[8,9] Blinking and tearing reflex were optimal. Primary impression was made using medium body addition silicone impression material which was reinforced with twisted orthodontic wire to hold it in place and for ease of removal. The final impression was recorded with putty addition silicone along with light body silicone using acrylic special tray.^[14] A scleral wax pattern was fabricated on the master cast. The wax pattern was inserted into the socket. The thickness of the wax pattern was adjusted so that the eyelid closure was possible, and the eye contour and proper support for the eyelids were achieved at the same time.^[4]

Method 1: Positioning of the iris button using facial landmarks and digital portrait photography

A full face photograph of the patient was recorded with Canon DSLR camera (Canon EOS 1100D; Canon Inc., Tokyo, Japan. with f/4.5; FL 32 mm). The patient was seated in an upright position without head support, looking straight ahead at a distant object, at least 4 feet away.^[8] The nose was in the center of the portrait, which placed the head in the center of the frame. The camera was positioned at the eye level, and with the patient looking directly, the shot was framed horizontally, showing the top of the head to just below the chin.^[15] This was done in such a way so that the reflection of the flash light was visible in the center of the pupil of the natural eye on the photograph. The midline of face was marked along with the position of the natural iris on the photograph. The distance from the midline to the center of the pupil of the natural eye (a), the horizontal distance of the pupil from mesial (b) and distal (c) canthus, as well as vertical distance of the pupil from upper (d), and lower eyelid (e) at the mid horizontal point were noted [Figure 4].^[8] Any magnification error was calculated considering the ratio between exact facial dimension and photographic dimension. The measurements were then transferred to the wax blank in the socket of the patient and utilized for selection of size and positioning the artificial iris. A stock eye was selected to match the shade and size of contralateral iris. The iris button was then removed from the stock eye using acrylic trimming bur. The pattern was taken out, and the iris was joined with the wax pattern in the engraved position. The wax pattern was then tried clinically. The anatomical landmarks which were utilized for the measurements on the printed photograph were now marked on the patient's face with an indelible pencil.^[8] Size and position of the iris was verified comparing with the facial landmarks and contralateral eye.

Method 2: Positioning the iris button with a specially fabricated spectacle gridded with mm scale

A specially designed spectacle [Figure 5] was prepared by attaching a 1 mm gridded transparent paper on the

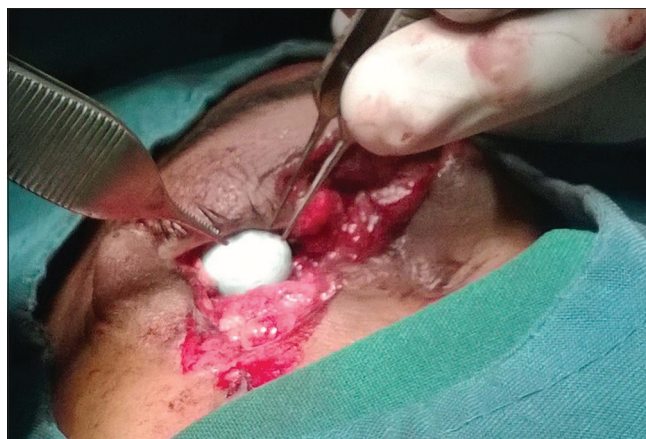

Figure 2: Insertion of eye ball implant under the sclera

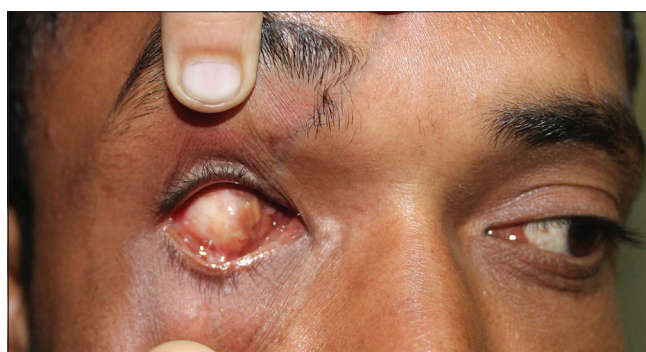

Figure 3: Eye socket after 4 months of surgery showing the convex tissue surface

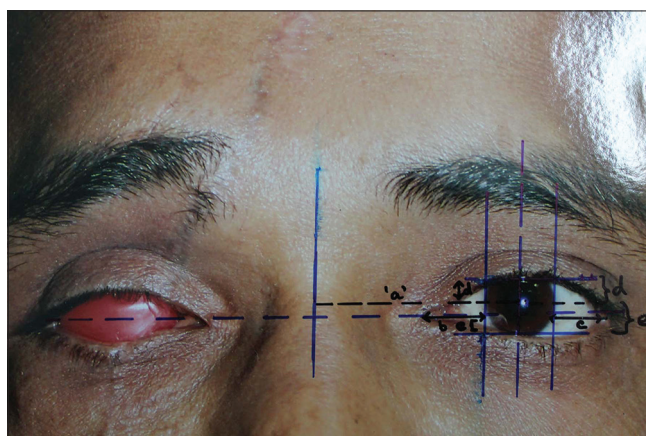


Figure 4: Anatomical landmarks and measurements done on printed photograph of natural eye

frontoparallel acrylic glasses. It is almost like Kestenbaum glasses, which are used in ophthalmology for the easy assessment of horizontal and vertical eye movements and ocular motility.^[10] At the try-in stage, the patient was asked to wear this gridded spectacle. The facial markings were transferred to the gridded glass to determine the pupil position and corneal plane of the natural eye. Those markings were transposed onto the side of defect utilizing

the measurements on the “x” and “y” axis of the grid.^{18]} The markings of the grid were then transferred to the wax scleral blank in the socket. Size of the iris button was selected from the measurements recorded, and the iris button was positioned on the wax pattern accordingly. The exact position of the iris button was verified again. The vertical and horizontal position of the iris on the sclera blank was coinciding with the determined position on the glass [Figure 6a]. The simulation of eye movements and complete closure of eyelids were verified. Finally, the wax pattern was evaluated for esthetics, comfort, and acceptance of the patient.

Processing and insertion

The wax pattern was then processed conventionally and characterized with small red cotton rayon thread to simulate the blood vessels. The shade of the heat-cured tooth-colored acrylic was selected by matching with the sclera of the existing eye. After processing, the polished




Figure 5: Spectacle with 1 mm grid paper attached on it

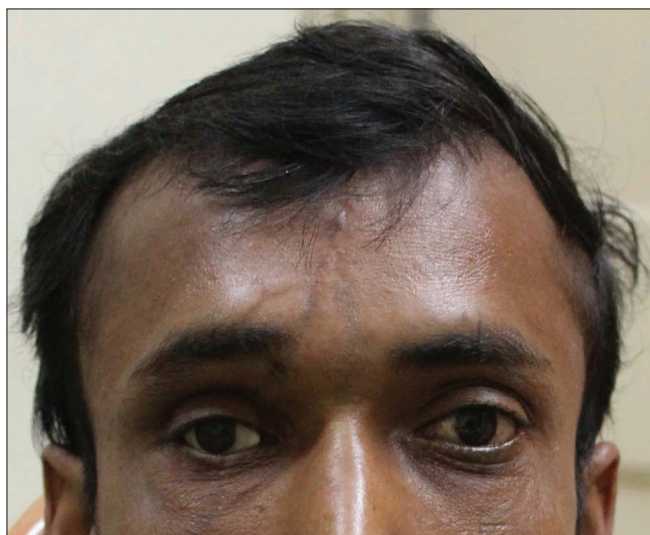


Figure 7: Patient looking straight with finished and polished prosthesis

prosthesis was inserted in the socket and evaluated for comfort, stability, esthetics [Figures 6b and 7], and motility [Figures 8 and 9]. The patient was followed up for a year. It was obvious that the rehabilitation of the defect and the psychological well-being of the patient were well established and satisfactory.

DISCUSSION

Maxillofacial trauma is associated with ophthalmologic injuries in as many as 20% of patients.^{116]} Annual report of American Academy of Ophthalmology, 2008, stated that 10% of the eye injuries are caused due to tools and power tools.^{117]} This type of injury may necessitate evisceration, enucleation, or exenteration with resulting disfigurement, functional impairment, and psychological distress. Rehabilitation of patients with such deformities is a challenge for the clinician to enhance the esthetics and give psychological strength to the patient. The objectives of custom-made ocular prosthesis are to retain the shape of the socket, prevent collapse of eyelid, allow proper movement of prosthetic eyeball and eyelid, reestablish the correct route of the lachrymal secretion, prevent accumulation in the socket, and mimic the color, position, proportion, and gaze of the contralateral natural eye. The success of an ocular prosthesis depends largely on the accurate orientation of the iris disk assembly. The literature suggests many techniques for positioning the iris on the ocular prosthesis. Every technique has its own merits and demerits.

In this case, insertion of an eye ball implant helped in fabricating a lightweight acrylic prosthesis, thereby

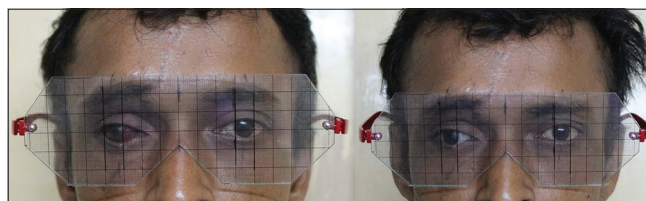


Figure 6: (a) Verification of position of the iris on wax pattern using gridded spectacle (left side) and (b) Checking position of iris on sclera on prosthesis using gridded spectacle (right side)

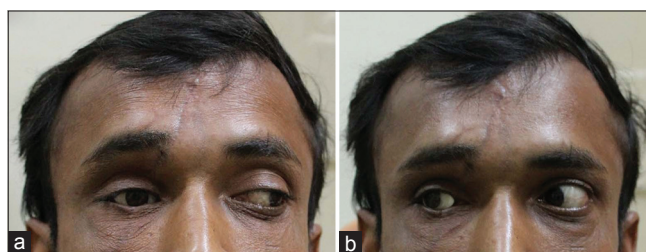

Figure 8: (a) Motility of ocular prosthesis in adduction. (b) Motility of ocular prosthesis in abduction

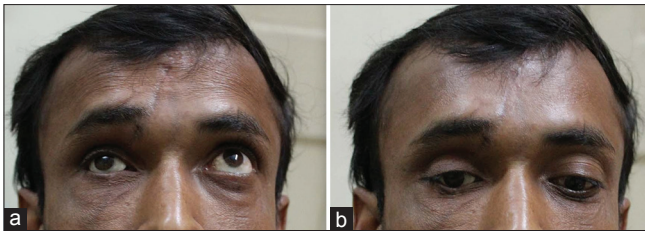

Figure 9: (a) Motility of ocular prosthesis in elevation. (b) Motility of ocular prosthesis in depression

increasing patient tolerance. It also improved life-like motility of the prosthetic eye [Figures 8a, b and 9a, b].

Using digital imaging for accurate positioning of the iris and then verifying it clinically presented several advantages such as increased patient cooperation, avoiding movement of contralateral eye, and avoiding complex armamentarium. Here, facial measurements, selection of size, and position of iris button were done on the photograph, without involving the patient. Then, try-in was done on patient for subjective and objective verification.

Transparent grid template was used earlier for centration of iris.^[8] However, method of holding the transparent grid was not standardized. The second method described here utilizing spectacles gridded with mm scale was shown to provide satisfactory result with increased patient cooperation. Spectacle can position the grid paper more securely with than holding grid paper in front of the face of the patient. Furthermore, using the same spectacle in every appointment maintains the fixed distance of the grid paper from the face, which is difficult to standardize with handheld grid paper. Thus, spectacle helps to reproduce same measurements in every appointment.

CONCLUSION

This case report underpins the purpose and necessity of effective management of a traumatic ocular deformity to avoid 'PESS' and also to preserve the socket anatomy, the sulcus and fornix preserving the ocular motility as well. In this case, insertion of an eye ball implant helped in fabricating a lightweight acrylic prosthesis, thereby increasing patient tolerance. It also improved life-like motility of the prosthetic eye. The crux of the method that is used involves a novel approach of positioning the iris button on the ocular prosthesis using digital photography and specially fabricated gridded spectacle which is less demanding, more precise, and reproducible method for achieving the desired goal. The measurements of the natural iris made on the digital photograph and the gridded spectacle can be used to determine the accurate

size of the prosthetic iris. Both the methods can be used separately for positioning of the iris. Alternatively, the digital photograph can be used for positioning of the iris, and then, gridded spectacle can be used for final adjustment and verification, which will ensure less chairside time and increase patient cooperation. Finally, the paper explores the dynamism in rehabilitation of ocular deformities and puts forward the relevance of this singular approach as a systematic, reproducible, and conclusive method for definitive rehabilitation.

Declaration of patient consent

The authors certify that they have obtained all appropriate patient consent forms. In the form the patient(s) has/have given his/her/their consent for his/her/their images and other clinical information to be reported in the journal. The patients understand that their names and initials will not be published and due efforts will be made to conceal their identity, but anonymity cannot be guaranteed.

Acknowledgments

Authors would like to thank Dr. Snehasis Basu FRCS (Edin), MS, DNB; Senior Consultant Eye Surgeon for his valuable guidance and support.

Financial support and sponsorship

Nil.

Conflicts of interest

There are no conflicts of interest.

REFERENCES

1. Perman KI, Baylis HI. Evisceration, enucleation, and exenteration. *Otolaryngol Clin North Am* 1988;21:171-82.
2. Aggarwal H, Kumar P, Eachempati P, Alvi HA. Different intraorbital implant situations and ocular prosthetic rehabilitation. *J Prosthodont* 2016;25:687-93.
3. Tyers AG, Collin JR. Baseball orbital implants: A review of 39 patients. *Br J Ophthalmol* 1985;69:438-42.
4. Artopoulos II, Montgomery PC, Wesley PJ, Lemon JC. Digital imaging in the fabrication of ocular prostheses. *J Prosthet Dent* 2006;95:327-30.
5. Ow RK, Amrith S. Ocular prosthetics: Use of a tissue conditioner material to modify a stock ocular prosthesis. *J Prosthet Dent* 1997;78:218-22.
6. Aggarwal H, Kumar P, Singh RD. A simplified method to fabricate a pneumatic ocular prosthesis for large ocular defects. *J Indian Prosthodont Soc* 2014;14:106-9.
7. Kumar P, Aggarwal H, Singh RD, Chand P, Jurel SK, Alvi HA, et al. A simplified approach for placing the iris disc on a custom made ocular prosthesis: Report of four cases. *J Indian Prosthodont Soc* 2014;14:124-7.
8. Guttal SS, Patil NP, Vernekar N, Porwal A. A simple method of positioning the iris disk on a custom-made ocular prosthesis. A clinical report. *J Prosthodont* 2008;17:223-7.
9. Raizada K, Rani D. Ocular prosthesis. *Cont Lens Anterior Eye* 2007;30:152-62.

10. Smit TJ, Koornneef L, Groet E, Zonneveld FW, Otto AJ. Prosthesis motility with and without intraorbital implants in the anophthalmic socket. *Br J Ophthalmol* 1991;75:667-70.
11. Kaltreider SA, Lucarelli MJ. A simple algorithm for selection of implant size for enucleation and evisceration: A prospective study. *Ophthalmic Plast Reconstr Surg* 2002;18:336-41.
12. Yeshawante B, Choudhary N, Baig N. Ocular prosthesis – A review. *IOSR J Dent Med Sci* 2015;14:63-7.
13. Choubisa D. A simplified approach to rehabilitate an ocular defect: Ocular prosthesis. *J Indian Prosthodont Soc* 2017;17:89-94.
14. Kale E, Meşe A, Izgi AD. A technique for fabrication of an interim ocular prosthesis. *J Prosthodont* 2008;17:654-61.
15. Digital Photography: The First Step in the Record-Gathering Process. Shannon Pace Schmidt, Digital Photography Guidelines, the Dawson Academy. Available from: <http://thedawsonacademy.typepad.com/files/digital-photography-Guidelines>. [Last accessed on 2015 Jul 09].
16. Ashar A, Kovacs A, Khan S, Hakim J. Blindness associated with midfacial fractures. *J Oral Maxillofac Surg* 1998;56:1146-50.
17. Roisental A, Gilbey P, Pikkell J. Remote penetrating orbital trauma due to a snooker cue through the mouth. *Dent Traumatol* 2011; 27: 247-9. doi: 10.1111/j.1600-9657.2011.00999.x.