




# Facial Nerve Hemangioma of the Lateral Portion of the Internal Acoustic Canal: A Case Report and a Review of Literature

J.M. Monteiro<sup>1,6</sup>  J.I.R. Ramos<sup>2</sup> F. H. Oliveira<sup>3</sup> J. Lavinsky<sup>4,5</sup> G.R. Isolan<sup>1,5,6</sup>

<sup>1</sup> Department of Neurosurgery, The Center for Advanced Neurology and Neurosurgery (CEANNE), Porto Alegre, Brazil

<sup>2</sup> Department of Oral & Maxillofacial Surgery and Periodontology, School of Dentistry of Ribeirão Preto at University of São Paulo, Ribeirão Preto, Brazil

<sup>3</sup> Department of Pathology, Moinhos de Vento Hospital, Porto Alegre, Brazil

<sup>4</sup> Department of Anatomy, Federal University of Rio Grande do Sul, Porto Alegre, Brazil

<sup>5</sup> Department of Neurotology, The Center for Neurotology and Acoustic Neuromas (CNNA), Porto Alegre, Brazil

<sup>6</sup> Postgraduate Program in Principles of Surgery, Mackenzie Evangelical College of Paraná, Curitiba, Brazil

**Address for correspondence** Gustavo Rassier Isolan, MD, PhD, Department of Neurosurgery, The Center for Advanced Neurology and Neurosurgery (CEANNE) – Rua Vicente da Fontoura 2354 sala 704, Porto Alegre, RS, Brazil (e-mail: gisolan@yahoo.com.br).

J Neurol Surg Rep 2023;84:e31–e36.

## Abstract

**Introduction** Facial nerve hemangiomas (FNH) are rare tumors. Although it can occur in any portion of the nerve, it predominantly appears near the geniculate ganglion. We present a case of facial nerve hemangioma of an unusual location.

**Case Report** A 30-year-old woman presented with right-sided severe hearing loss and progressive facial palsy. Magnetic resonance showed a 5 mm lesion in the lateral portion of the right internal auditory canal. Due to facial palsy, the patient was submitted to a translabyrinthine approach and a total tumor resection, followed by hypoglossal-facial nerve anastomosis.

**Discussion** The facial nerve is susceptible in its path to expansive lesions, which have high morbidity. FNH is a rare and difficult-to-diagnose lesion. Computerized tomography and nuclear magnetic resonance can be used in its diagnosis. The differential diagnosis of FNH includes, in addition to schwannomas, meningiomas, cholesteatomas, paragangliomas, and other temporal bone tumors. There is no well-established consensus on the best approach. Because of its slow growth and benign behavior, some studies suggest conservative treatment and serial imaging. However, surgery is the cornerstone of treatment, as it is the only curative option.

**Conclusion** FNHs are often small but very symptomatic. Its high morbidity demands early diagnosis and, sometimes, surgical treatment.

## Keywords

- ▶ facial nerve hemangioma
- ▶ mastoid approach
- ▶ intratemporal tumors

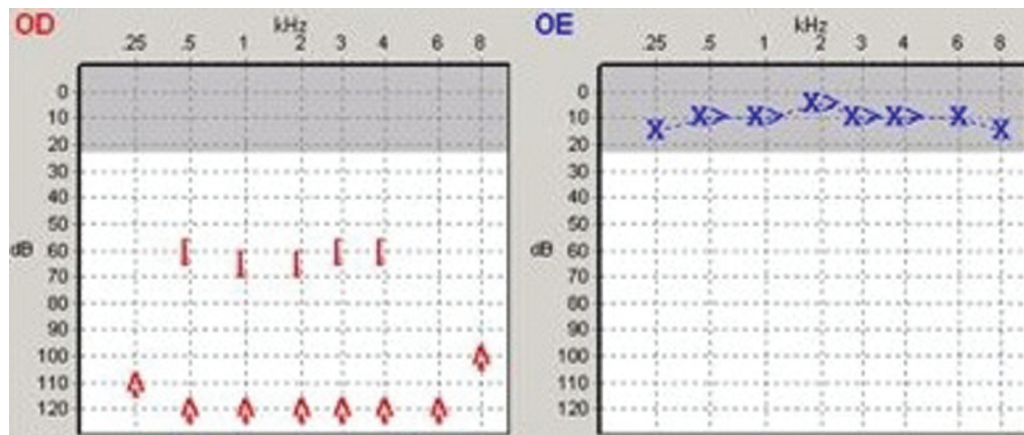
received  
June 20, 2021  
accepted after revision  
January 26, 2023

DOI <https://doi.org/10.1055/s-0043-1764394>.  
ISSN 2193-6358.

© 2023. The Author(s).

This is an open access article published by Thieme under the terms of the Creative Commons Attribution-NonDerivative-NonCommercial-License, permitting copying and reproduction so long as the original work is given appropriate credit. Contents may not be used for commercial purposes, or adapted, remixed, transformed or built upon. (<https://creativecommons.org/licenses/by-nc-nd/4.0/>)

Georg Thieme Verlag KG, Rüdigerstraße 14, 70469 Stuttgart, Germany



**Fig. 1** Right-ear unilateral profound sensorineural hearing loss.

## Introduction

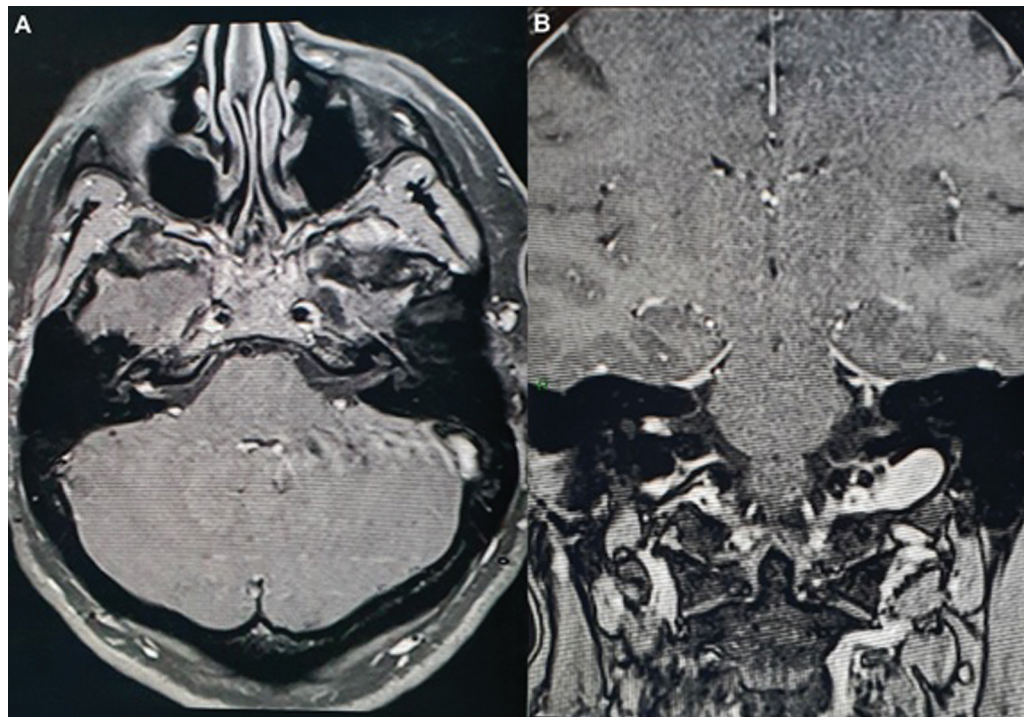
Facial nerve hemangioma (FNH) constitutes only 0.7% of intratemporal tumors.<sup>1,2</sup> Although it can occur in any portion of the facial nerve, it predominantly appears near the geniculate ganglion, being quite uncommon in other portions.<sup>1,3</sup> Facial palsy (mild and progressive, recurrent or spasms) and hearing loss are the most common symptoms. Depending on the tumor location in the fallopian canal, one or another is more evident.<sup>1,3</sup> Its diagnosis is made through complementary imaging exams and requires a high level of suspicion, especially in symptomatic small lesions.

We present a case of facial nerve hemangioma of an unusual location, located at the lateral portion of the internal acoustic canal.

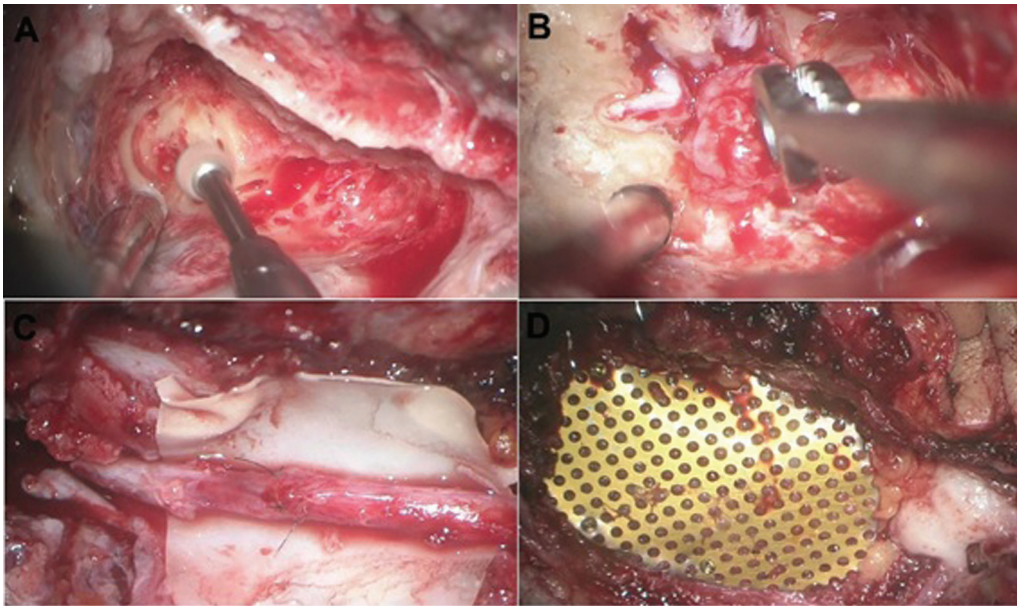
## Case Report

We report the case of a 30-year-old woman referred to our service with severe hearing loss in the right ear and right-sided facial palsy House–Brackmann (HB) grade II. Pure-tone audiometry revealed right-ear unilateral profound sensorineural hearing loss (→ **Fig. 1**). Magnetic resonance imaging (MRI) showed a 5 mm lesion in the lateral portion of the right internal auditory canal with contrast-enhancement to gadolinium, suggestive of vestibular schwannoma (→ **Fig. 2**). It was opted for a watchful waiting protocol. In the following 12 to 24 months, the facial palsy progressed to an HB IV.

The patient was then submitted to a translabyrinthine approach and a total tumor resection (→ **Fig. 3**). The facial nerve was sectioned from the tympanic portion,



**Fig. 2** T1-weighted gadolinium-enhanced MRI showing heterogeneous gadolinium-enhanced lesion in the distal portion of the internal acoustic canal. (A) Axial image. (B) Coronal image. MRI, magnetic resonance imaging.



**Fig. 3** Intraoperative images. (A) Translabirithyne approach. (B) Tumor resection. (C) Hypoglossal-facial nerve anastomosis. (D) Cranial reconstruction with fat and titanium mesh.

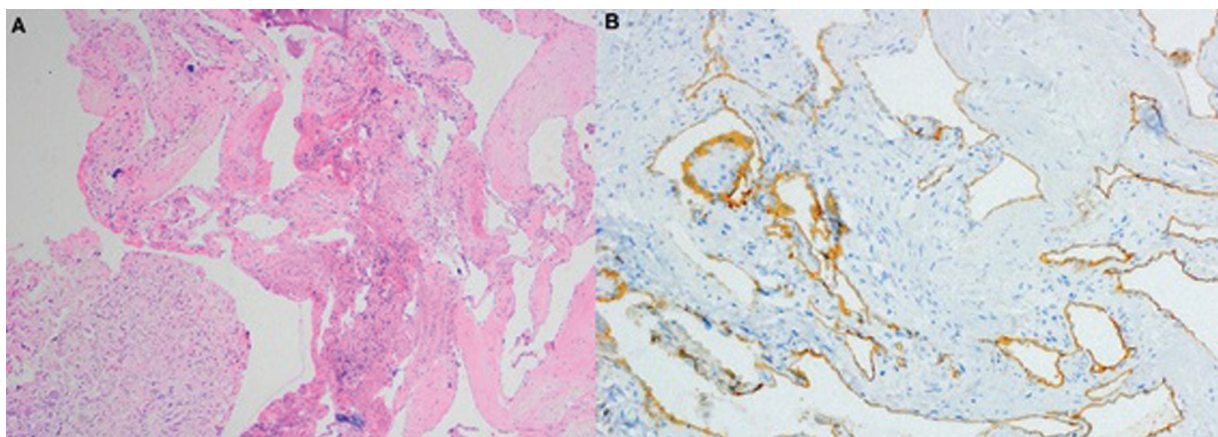
decompressed from the fallopian canal, and rotated inferiorly to a hypoglossal-facial nerve anastomosis. Anatomopathological study was compatible with facial nerve hemangioma (► **Fig. 4**). Postoperative MRI after 6 months showed complete resection (► **Fig. 5**). The patient evolved with HB VI facial paralysis in the immediate postoperative period (► **Fig. 6**) but showed improvement in facial mobility in a 6-month follow-up (HB III), with mild tongue palsy (► **Fig. 7**).

## Discussion

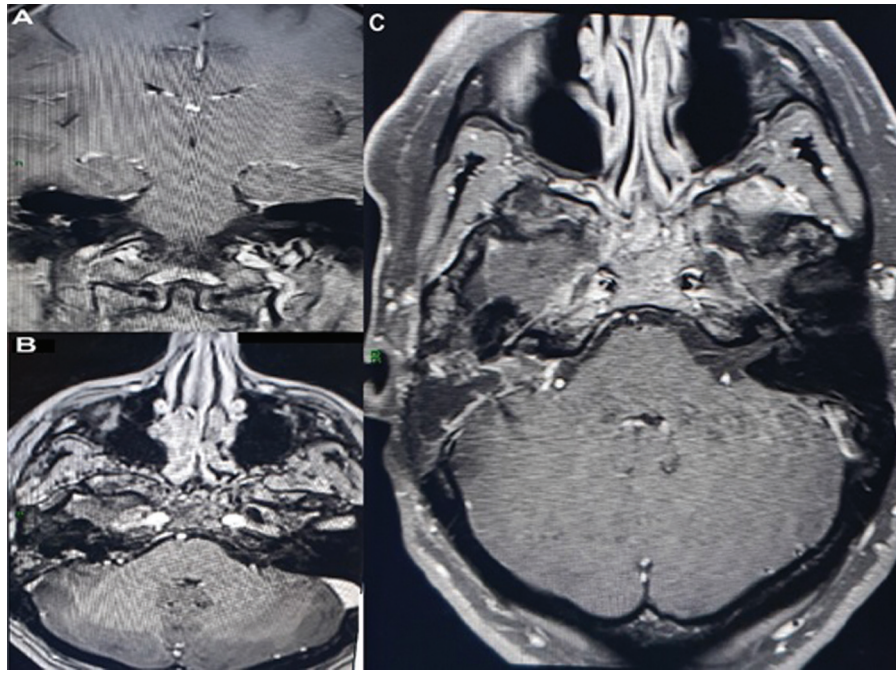
The facial nerve (VII cranial nerve) is responsible for facial motricity, taste sensitivity of the anterior 2/3 of the tongue, tactile sensitivity of the external ear, in addition to parasympathetic innervation of the sublingual, submandibular, lacrimal, and nasomucosal glands.<sup>4,5</sup> The most common symptom related to its involvement is

peripheral facial paralysis,<sup>4</sup> although hearing loss can also occur due to the proximity of the vestibulocochlear nerve (VIII cranial nerve) and auditory structures. The main cause of facial nerve dysfunction is inflammatory (Bell's palsy);<sup>4</sup> however, it is susceptible in its path to expansive lesions, whether intrinsic to the nerve or external that cause its compression. Such tumors, although rare, have high morbidity and sequelae.


FNH is a rare and difficult-to-diagnose lesion. It occurs more frequently in the most proximal portions of the facial nerve, which causes difficult differentiation with vestibular schwannomas. They are slow-growing lesions derived from the perineural capillaries, which are very present mainly around the geniculate ganglion, hence their predilection for this location.<sup>1,2</sup> Despite being classically called hemangiomas, these lesions do not present typical aspects of classic infantile hemangiomas, but rather irregular and dilated



**Fig. 4** Anatomopathological study compatible with facial nerve hemangioma. (A) Hematoxylin and eosin (H&E) staining showing coarse vessels with conjunctival fibrous thickening. (B) CD31 marker emphasizes the vascular nature of the lesion.



**Fig. 5** Postoperative MR showing no residual tumor within the internal acoustic canal. (A) T1 weighted gadolinium-enhanced coronal image. (B) T1-weighted gadolinium-enhanced axial image. (C) T1-weighted image, no gadolinium. Notice signs of mastoid manipulation (petrosectomy). MR, magnetic resonance.

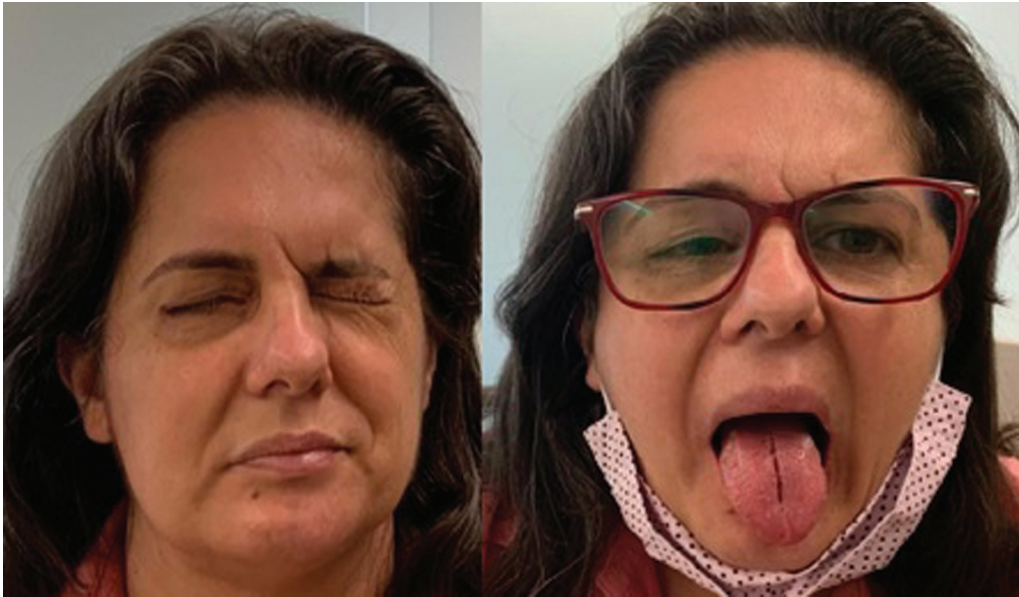

**Fig. 6** Early postoperative facial palsy.

vessels without an elastic inner layer associated with vascular smooth muscle.<sup>2</sup> They also have intratumoral calcified spicules, derived from the adjacent bone tissue.<sup>6</sup> Such features confer more characteristics of vascular malformations than of hemangiomas, but the nomenclature remains in the literature.<sup>2,3</sup>

Computerized tomography (CT) and nuclear MRI can be used in facial nerve hemangioma diagnosis. In the CT, the lesion has undefined borders. However, if the bone spikes are visible, they ease the diagnosis.<sup>2,6</sup> On MRI, hemangiomas show a variable intensity signal at T1 (normally slightly hyperintense), hyperintense signal at T2, and have a heterogeneous contrast enhancement—due to the bone spikes.<sup>1,2,6</sup> They are usually small lesions that infiltrate the nerve. This is the main reason that it is a symptomatic lesion even when small, unlike schwannoma, which, due to the lack of nerve infiltration, usually present symptoms when with a significant volume.<sup>6</sup> Other hindering factor to its diagnosis is the anatomy of the facial nerve canal in the temporal bone: contrast enhancement in the labyrinthine portion of the facial nerve or in the lateral portion of the internal acoustic canal is, normally, pathological. However, when the lesion is proximal (meatal or geniculate ganglion), it has a differential diagnosis with schwannomas which are more common. When distal to the geniculate ganglion (labyrinthine portion), the MRI hypersignal can be physiological, due to a rich vascular plexus.<sup>6</sup> Therefore, the diagnosis depends on a high degree of suspicion when faced with small and very symptomatic lesions.

The differential diagnosis of facial nerve hemangioma includes, in addition to schwannomas, meningiomas, cholesteatomas, paragangliomas, and other temporal bone tumors.<sup>6</sup> Schwannomas of the facial nerve are less common than those of the vestibulocochlear nerve. Like these, they can be associated with neurofibromatosis type 2.<sup>6</sup> These tumors can occur with no facial palsy in up to 30% of cases. They are normally rounded, well-defined lesions that can



**Fig. 7** Late postoperative facial palsy.

occupy the cerebellopontine angle, internal acoustic canal, or the facial nerve canal. MRI evidences hyperintense signal in T1 and T2 and intense contrast enhancement in T1 weighted images (it may show a heterogeneous enhancement in a large tumor).<sup>6</sup> Meningiomas, although extremely rare in this region, can appear in any portion of the facial nerve canal. No more than 20 cases of meningiomas of the geniculate ganglion have been reported in the literature.<sup>7</sup> Imaging exams show thickened meninges and lesions with significant contrast enhancement, often surrounded by heterogeneous and poorly delimited bone tissue. When present, the dural-tail, common in meningiomas, can be confused with “the labyrinthine tail” of schwannomas.<sup>7</sup> Cholesteatomas, primary or secondary, can affect the region. They present hypo or isointense images in T1 and T2, without contrast impregnation. Paragangliomas, histiocytosis, are also among the possible tumoral lesions that, although rare, can occur in the region.

As a result of the low incidence of facial nerve hemangioma, there is no well-established consensus on the best approach. Because of its slow growth and benign behavior, some studies suggest conservative treatment and serial imaging.<sup>1</sup> However, surgery is the cornerstone of treatment, as it is the only curative option. As the best facial palsy HB grade achieved through surgery is III, patient should undergo surgery when the HB passes this point.<sup>7</sup> Surgical approach should be chosen based on the hearing level. Resection via the middle fossa or transmastoid should be used to preserve hearing function and the translabyrinthine approach may be preferred when the hearing loss is total.<sup>7</sup>

In the reported case, we opted for conservative treatment while the facial palsy grade was lesser than the best one we could achieve with surgery, as we knew that we could not

improve the hearing loss. As it got worse, surgery was indicated. As there was no risk of hearing worsening, we performed a translabyrinthine approach, with total tumor resection, facial nerve section, and translocation followed by end-to-side hypoglossal nerve anastomosis. The facial palsy worsened (HB VI) in the immediate postoperative period, as expected. However, in the 6-month follow-up, the patient already showed significant improvement in facial mimicry, achieving a lesser HB (grade III) compared with the preoperative period. According to the current literature, a significant improvement beyond this point is not expected. Complete tumor resection with preservation of the facial nerve shows better functional results, but it is not always possible.<sup>4,7</sup>

## Conclusions

FNHs are often small but very symptomatic. Its high morbidity demands early diagnosis and, when necessary, surgical treatment. Due to its rare incidence, it demands a high level of suspicion to its diagnosis. Although clinical and radiological features may not differentiate the facial nerve hemangioma from other lesions that may arise in the facial nerve canal, it must be in the differential diagnosis of small infiltrating tumors of the facial nerve.

## Conflict of Interest

None declared.

## References

- Costa LEM, Castro RF, Costa FMM, Santos MAO. Facial nerve hemangioma in the middle ear. *Einstein (Sao Paulo)* 2018;16(04):eRC4509

- 2 McRackan TR, Wilkinson EP, Rivas A. Primary tumors of the facial nerve. *Otolaryngol Clin North Am* 2015;48(03):491–500
- 3 Benoit MM, North PE, McKenna MJ, Mihm MC, Johnson MM, Cunningham MJ. Facial nerve hemangiomas: vascular tumors or malformations? *Otolaryngol Head Neck Surg* 2010;142(01):108–114
- 4 Shelton C, Brackmann DE, Lo WW, Carberry JN. Intratemporal facial nerve hemangiomas. *Otolaryngol Head Neck Surg* 1991;104(01):116–121
- 5 Mortazavi MM, Latif B, Verma K, et al. The fallopian canal: a comprehensive review and proposal of a new classification. *Childs Nerv Syst* 2014;30(03):387–395
- 6 Veillon F, Taboada LR, Eid MA, et al. Pathology of the facial nerve. *Neuroimaging Clin N Am* 2008;18(02):309–320, x
- 7 Gao W, Zi D, Lu L. Facial nerve meningioma: a case mimicking facial nerve schwannoma. *Ear Nose Throat J* 2020;101(06):402–404