

# A case of chronic myeloid leukemia presenting as oral ulcers

Neethu Telagi, B R Mujib Ahmed

Department of Oral Pathology and Microbiology, Bapuji Dental College and Hospital, Davangere, Karnataka, India

## Abstract

The oral signs and symptoms may reflect undetected serious systemic diseases. Depending on the oral manifestation, the dentists and physicians make attention and focusing on specific diagnoses. Here, we represent one such case which was diagnosed after oral signs and symptoms followed by peripheral smear report as chronic myeloid leukemia. Leukemia is among the most prevalent neoplasia, which represents between 30% and 51% of that total. Leukemia is characterized by uncontrolled production of immature white blood cells, causing a series of clinical and oral manifestations, which are important in disease diagnosis. Due to their clinical importance, all such lesions deserve the full attention of dental doctors. Early detection of leukemia is very important because it provides a favorable prognosis.

**Keywords:** Chronic myeloid leukemia, immature blast cells, oral ulcers

**Address for correspondence:** Dr. Neethu Telagi, Department of Oral Pathology and Microbiology, Bapuji Dental College and Hospital, Davangere - 577 004, Karnataka, India.

E-mail: neethutelagi@gmail.com

**Submitted:** 14-Jun-2019, **Accepted:** 18-May-2021, **Published:** 31-Aug-2021

## INTRODUCTION

The oral signs and symptoms may reflect undetected serious systemic diseases. Depending on the oral manifestation, the dentists and physicians make attention and focusing on specific diagnoses. In some cases, oral involvement may frequently herald the onset of the disease which requires the dentists to a better knowledge of changes in the oral cavity.<sup>[1]</sup>

Here we represent one such case which was diagnosed after oral signs and symptoms followed by peripheral smear report as chronic myeloid leukemia (CML).

Leukemia is among the most prevalent neoplasia, which represents between 30% and 51% of that total. Leukemia is characterized by uncontrolled production of immature white blood cells, causing a series of clinical and oral manifestations, which are important in disease diagnosis.

In the oral cavity, local symptoms and findings of leukemia include paleness of the oral mucosa with gingival bleeding that develops into painless gingival hyperplasia, petechiae, hemorrhages and ulcerative necrotic lesions.

Due to their clinical importance, all such lesions deserve the full attention of the dental doctors.<sup>[1]</sup>

The oral symptoms of leukemia may sometimes precede systemic manifestations. The knowledge of such systemic diseases is of utmost importance to dental surgeons as they may help in early and prompt diagnosis as these diseases may sometimes go undiagnosed.<sup>[2]</sup> Early detection of leukemia is very important because it provides a favorable prognosis.<sup>[3]</sup>

## CASE REPORT

A 53-year-old male patient has been reported to the department of oral medicine and radiology with a chief

This is an open access journal, and articles are distributed under the terms of the Creative Commons Attribution-NonCommercial-ShareAlike 4.0 License, which allows others to remix, tweak, and build upon the work non-commercially, as long as appropriate credit is given and the new creations are licensed under the identical terms.

**For reprints contact:** WKHLRPMedknow\_reprints@wolterskluwer.com

**How to cite this article:** Telagi N, Mujib Ahmed BR. A case of chronic myeloid leukemia presenting as oral ulcers. *J Oral Maxillofac Pathol* 2021;25:372-3.

### Access this article online

#### Quick Response Code:

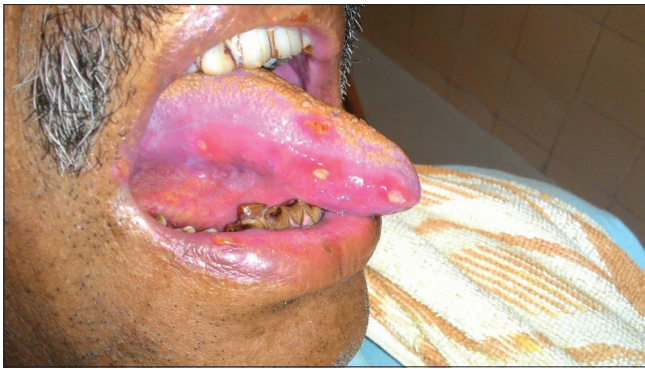

#### Website:

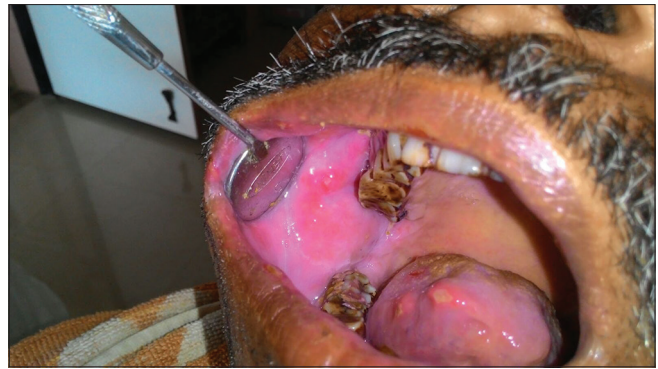www.jomfp.in

#### DOI:

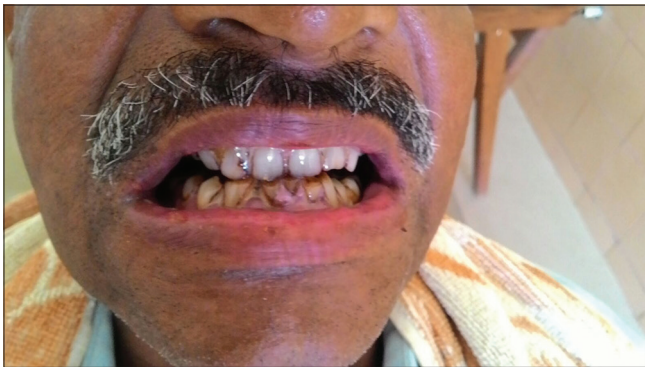10.4103/0973-029X.325260



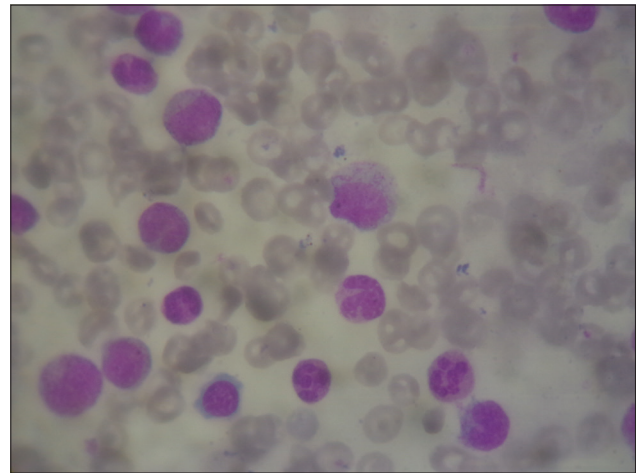
**Figure 1:** Clinical photograph showing ulcers on the lateral border of the tongue



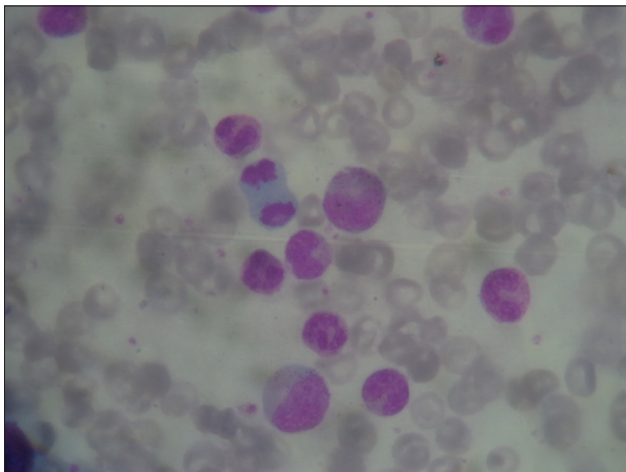
**Figure 2:** Clinical photograph showing ulcers on the lateral border of the tongue and right buccal mucosa



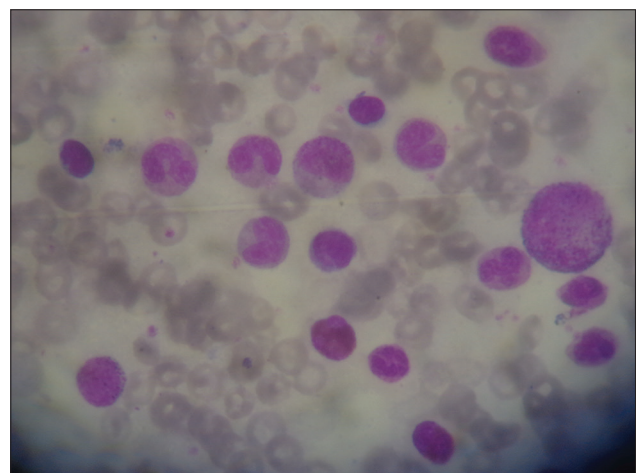
**Figure 3:** Clinical photograph showing ulcers on the lower lip



**Figure 4:** Photomicrograph ( $\times 100$ ) of peripheral smear shows immature cells



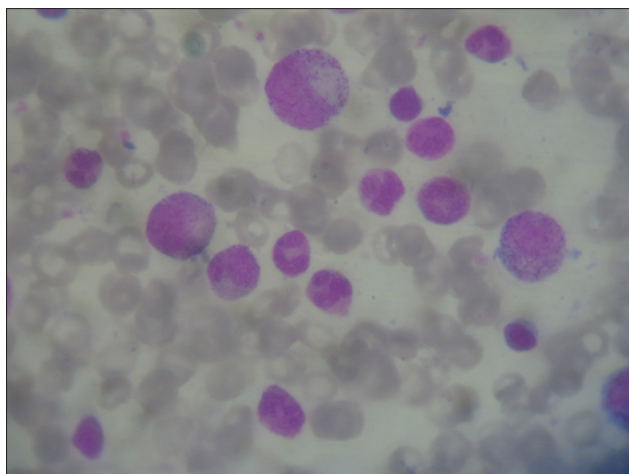
**Figure 5:** Photomicrograph ( $\times 100$ ) of peripheral smear shows abnormal mitotic cell



**Figure 6:** Peripheral smear shows numerous white blood cells exhibiting immature blast cells

complaint of painful ulcers on the tongue and right buccal mucosa for 3 days. He gives a history of similar recurrent ulcers 2 years back. The patient was a chronic betel nut and tobacco chewer for 21 years and chews 4–5 times/day. On extraoral examination right submandibular lymph nodes were palpable, tender and movable, measuring approximately 1.5 cm in size. Intraoral examination [Figures 1-3] revealed ulcers on the dorsum of the tongue, right lateral border of the tongue, on right buccal mucosa

and also on the right corner of the mouth which were irregular in shape and surrounded by erythematous border covered with yellowish slough. On palpation, the ulcers were tender.



**Figure 7:** Peripheral smear shows numerous white blood cells exhibiting different phases of maturity

**Table 1: Consideration in dental treatment in leukemic patients**

Prior to dental treatment	During dental treatment
Dental treatment should be performed always after consultation with the specialist	Bleeding tendency
It is important to carry out a detailed history, a comprehensive oral and dental evaluation and a complete radiographic exam	Increased risk of infection
Dental treatment should be performed before starting the chemo/radiotherapy	Risk of developing osteonecrosis of the jaw
Patients in long-term remission can undergo dental treatment, while patients with advanced or relapsed disease with reserved prognosis should receive palliative or urgent treatment only	Anemia
	Corticosteroids treatment
	Secondary malignancies
	Specific considerations

The patient was advised for a complete hemogram. Hematology results revealed a low hemoglobin level characteristic of anemia. A very low platelet count indicated the presence of thrombocytopenia. An increased leukocyte count was evident and a differential count of the white cells revealed a significant elevation in monocyte levels [Figures 4-7].

## DISCUSSION

The mouth is considered to be a mirror of the body and sometimes undetected systemic diseases are diagnosed via the oral signs and symptoms as they herald prior to the systemic manifestations.<sup>[1,2]</sup> One such disorder being leukemia, a malignant neoplasm characterized by proliferation of abnormal white blood cells and their precursors which leads to immature cells in the circulating bloodstream.<sup>[2]</sup>

A number of systemic diseases including hematologic disorders have manifestations in the orofacial region (Francisconi CF *et al* 2016). Although nonpathognomonic, these

manifestations may often represent early signs of the underlying hematopoietic disease. Leukemia is the most common neoplastic disease of the white blood cells which is important as a pediatric malignancy and has an incidence of 9 cases per 100,000 population. Oral manifestations occur frequently in leukemic patients and may present as initial evidence of the disease or its relapse. The symptoms include gingival enlargement and bleeding, oral ulceration, petechia, mucosal pallor, noma, trismus and oral infections. Oral lesions arise in both acute and chronic forms of all types of leukemia.<sup>[4]</sup>

The most common leukemias are generally classified as (1) acute lymphocytic, (2) acute myeloid, (3) chronic lymphocytic and (4) chronic myeloid. The classification criterion of leukemia is histological and is based on (a) the similarity between the leukemic cells and normal cells (myeloid versus lymphoid) and (b) the clinical course of the disease (acute versus chronic).<sup>[5]</sup>

Acute leukemia involves poorly differentiated blast cells while chronic leukemia involves the matured leukocyte cells.<sup>[2]</sup>

CML is called by several other names, including:

- Chronic myelogenous leukemia
- Chronic granulocytic leukemia
- Chronic myelocytic leukemia.

CML does not completely interfere with the development of mature red cells, white cells and platelets.

CML is a myeloproliferative neoplasm with an incidence of one to two cases per 100,000 adults.

Leukemias have a diverse etiology ranging from viruses, chromosomal abnormalities to chronic exposure to benzol and aniline dyes and related chemicals. The most commonly reported chromosomal abnormality is the Philadelphia chromosome seen mostly in patients with CML.<sup>[2]</sup>

Central to the pathogenesis of CML is the fusion of the Abelson murine leukemia (ABL1) gene on chromosome 9 with the breakpoint cluster region (BCR) gene on chromosome 22. This results in expression of an oncoprotein termed BCR-ABL1.<sup>[3]</sup> BCR-ABL1 is a constitutively active tyrosine kinase that promotes growth and replication through downstream pathways such as RAS, RAF, JUN kinase, MYC and STAT.<sup>[2,4-9]</sup> This influences leukemogenesis by creating a cytokine-independent cell cycle with aberrant apoptotic signals in response to cytokine withdrawal.<sup>[6]</sup>



Acute leukemias are common in children and young adults while chronic leukemias are mostly seen in the older age group. Symptoms include fever, weight loss, weakness, pain in joints and muscles, generalized swelling of lymph nodes, petechial or ecchymotic hemorrhages in the skin and mucous membranes and local infections.

Chronic leukemia, with a less pronounced marrow failure, has an indolent course that usually lasts several years.<sup>[7]</sup>

Oral manifestations usually arise from an underlying thrombocytopenia, neutropenia, or impaired function.<sup>[8]</sup>

Oral lesions may be the presenting feature of acute leukemias and are therefore important diagnostic indicators of the disease.<sup>[2]</sup> Such lesions may occur due to direct leukemic infiltration of tissues, or be secondary to immunodeficiency, anemia and thrombocytopenia. Typical oral manifestations of acute leukemias include gingival swelling, oral ulceration, spontaneous gingival bleeding, petechiae, mucosal pallor, herpetic infections and candidosis.<sup>[9]</sup>

The insertion of dentistry in the multidisciplinary context of hematology-oncology is an important part of the success of cancer treatment. Oral complications can compromise the protocols of chemotherapy, possibly making it necessary to decrease the administered dose, the change in treatment protocol, or even discontinuation of antineoplastic therapy, directly affecting patient survival.<sup>[5]</sup>

Considerations in dental treatment of patients with hematologic malignancies by Franch AM *et al* [Table 1].<sup>[7]</sup>

Dental treatment should start before antineoplastic treatment to minimize morbidity and improve the general health of patients during therapy.

## CONCLUSIONS

The 5-year relative survival rates for all forms of leukemia have almost quadrupled between 1960–2005. As the survival rates of patients with leukemic conditions increase, the incidence of rare intraoral tumors such as myeloid sarcoma may become more common.<sup>[10]</sup> Oral health care professionals should be aware of the importance of recognizing oral manifestations of systemic diseases. The dentist, and mainly the periodontists and oral pathologist, plays a fundamental role in the early diagnosis of leukemia

knowing that the first symptoms of the disease occur in the oral cavity with normal or show subtle changes in initial laboratory tests.

The presentation of oral lesions in general dental practice requires a high index of suspicion and necessitates immediate referral, which may be lifesaving.

## Declaration of patient consent

The authors certify that they have obtained all appropriate patient consent forms. In the form the patient (s) has/have given his/her/their consent for his/her/their images and other clinical information to be reported in the journal. The patients understand that their names and initials will not be published and due efforts will be made to conceal their identity, but anonymity cannot be guaranteed.

## Financial support and sponsorship

Nil.

## Conflicts of interest

There are no conflicts of interest.

## REFERENCES

1. Deliverska1 EG, Krasteva A. Oral signs of leukemia and dental management – Literature data and case report. J IMAB Ann Proc (scientific papers) 2013;19:388-391. doi: 10.5272/jimab.2013194.388.
2. Leukemia GW. The oral perspective. Int J Oral Health Med Res 2015;2:113-4.
3. Emidio TC, Maeda YC, Teixeira AS, Rontani RM. Oral manifestations of leukemia and antineoplastic treatment – A literature review (part II) Braz J Health 2010;1:136-49.
4. Francisconi CF, Caldas RJ, Oliveira Martins LJ, Fischer Rubira CM, da Silva Santos PS. Leukemic oral manifestations and their management. Asian Pac J Cancer Prev 2016;17:911-5.
5. Zimmermann C, Meurer MI, Grando LJ, Gonzaga Del Moral JÂ, da Silva Rath IB, Schaefer Tavares S. Dental treatment in patients with leukemia. J Oncol 2015;2015:571739.
6. Jabbour E, Kantarjian H. Chronic myeloid leukemia: 2016 update on diagnosis, therapy, and monitoring. Am J Hematol 2016;91:252-65.
7. Franch AM, Esteve CG, Pérez MS. Oral manifestations and dental management of patient with leukocyte alterations. J Clin Exp Dent 2011;3:e53-9.
8. Silva BA, Siqueira CR, Castro PH, Araujo SS, Volpato LE. Oral manifestations leading to the diagnosis of acute lymphoblastic leukemia in a young girl. J Indian Soc Pedod Prevent Dent 2012;30:166-8.
9. Dean AK, Ferguson JW, Marvan ES. Acute leukaemia presenting as oral ulceration to a dental emergency service. Aust Dent J 2003;48:195-7.
10. Yap M, Hewson I, McLean C, Ciciulla J. Oral myeloid sarcoma: Two case reports. Aust Dent J 2014;59:511-5.