

## CLINICAL IMAGE

# Mass-forming Retroperitoneal Endometriosis Including a Fat Component: A Diagnostic Dilemma

Yusuke Kyuragi<sup>1\*</sup>, Akihiro Nishie<sup>1</sup>, Yukihisa Takayama<sup>2</sup>, Yoshiki Asayama<sup>1</sup>,  
Kousei Ishigami<sup>1</sup>, Takashi Ueki<sup>3</sup>, Minako Hirahashi<sup>4</sup>, and Hiroshi Honda<sup>1</sup>

### Clinical Imaging

The patient was a 49-year-old Japanese female with a history of surgery for ovarian endometriosis and adenomyosis. A retroperitoneal mass was also identified preoperatively. A later computed tomography (CT) examination revealed that the mass had grown. On unenhanced CT, the mass with a diameter of 4.5 cm was located to the right of the rectum and in front of the sacrum. It consisted of soft tissue and fat density. T<sub>1</sub>-weighted magnetic resonance (MR) images showed high-intensity areas inside the mass whose signals were partly decreased on fat-suppressed T<sub>1</sub>-weighted images (Fig. 1A, B). The presence of both fat and a hemorrhage was suggested. On T<sub>2</sub>-weighted images, low- and high-intensity areas were mixed inside the mass. A cordlike structure was also identified between the cul-de-sac and the mass (Fig. 2). Post-contrast T<sub>1</sub>-weighted images showed slight enhancement of the solid component inside the mass.

Based on these findings, we diagnosed the mass as dedifferentiated liposarcoma or angiomyolipoma. After surgery the tumor was macroscopically described as a grayish-white mass demarcated from the surrounding adipose tissue. Uterine endometrial glands and stroma were microscopically identified in the fibrous interstitial tissue of the mass, and hemosiderin-containing macrophages were scattered around them. Fibrous interstitial tissues permeated adjacent adipose tissue. The final diagnosis was deep endometriosis.

Deep endometriosis was arbitrarily defined as endometriosis infiltrating the peritoneum to a depth of >5 mm. Pathologically, both typical and deep endometriosis

include endometrial glands and stroma, and adjacent fibrosis and hemorrhage may be observed. In contrast, in infiltrative deep endometriosis, the endometrial glands and stroma elicit smooth muscle proliferation and a fibrous reaction.<sup>1</sup> In such lesions, low- to intermediate-intensity with punctate high-intensity (hemorrhage) areas are identified on T<sub>1</sub>-weighted images, whereas uniform low intensity is observed on T<sub>2</sub>-weighted images. Enhancement is also observed due to the abundant fibrous tissue.<sup>1</sup>

Our patient exhibited these MR findings. However, a few findings that were atypical for deep endometriosis were observed. The first was the presence of a fat component within the mass. Itoga et al.<sup>2</sup> reported that fibrosis widely extends into fat and connective tissues as well as within the endometriotic tissue in severely fibrotic areas of rectovaginal endometriosis. In our patient's case, we suspect that adipose tissues existed inside the mass in the process of disease development.

The second atypical finding was the location of the mass, which was away from the peritoneum and apparently in the retroperitoneum. We focused on a subtle finding, i.e., the cordlike structure between the posterior cul-de-sac and the mass, which had not been emphasized preoperatively. Considering that the posterior cul-de-sac is one of the frequent sites of deep endometriosis,<sup>1</sup> this structure may represent a tract of disease development, that is, disease progression from the posterior cul-de-sac to the right side of the rectum. The detection of this finding might increase the likelihood of deep endometriosis.

Finally, the large size of a mass as observed in the present case (4.5 cm) might also make a preoperative diagnosis difficult, because deep endometriosis usually presents as a single nodule with a diameter of <1 cm.<sup>3</sup> In a sense our case may be included in the category of polypoid endometriosis, which appears polypoid from the gross aspect and mimics malignancy at presentation, although this entity is usually described as polypoid masses projecting from a serosal/mucosal surface or from the lining of an endometrial cyst. Findings such as those presented by our patient should be recognized as a variation of deep endometriosis.

### Acknowledgment

We thank Drs. Yasuhiro Ushijima, Daisuke Okamoto and Nobuhiro Fujita, Department of Clinical Radiology, Kyushu

<sup>1</sup>Departments of Clinical Radiology, Kyushu University, 3-1-1 Maidashi, Higashi-ku, Fukuoka 812-8582, Japan

<sup>2</sup>Radiology Informatics and Network, Kyushu University, Fukuoka, Japan

<sup>3</sup>Surgery and Oncology, Kyushu University, Fukuoka, Japan

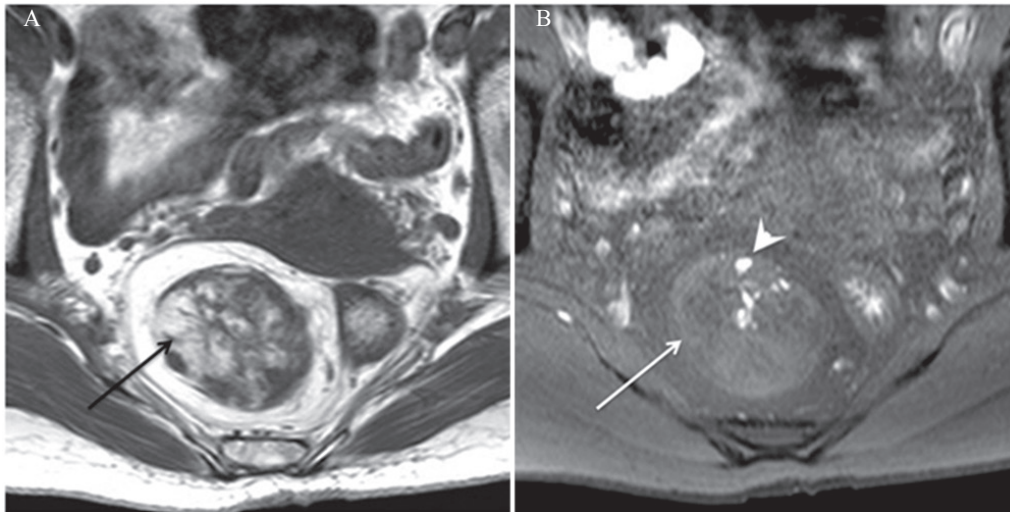
<sup>4</sup>Anatomic Pathology, Kyushu University, Fukuoka, Japan

\*Corresponding author, Phone: 81-92-642-5695, Fax: 81-92-642-5708, E-mail: anishie@radiol.med.kyushu-u.ac.jp

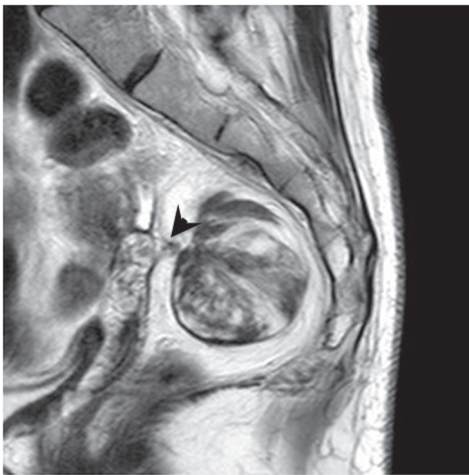
©2016 Japanese Society for Magnetic Resonance in Medicine

This work is licensed under a Creative Commons Attribution-NonCommercial-NoDerivatives International License.

Received: May 16, 2016 | Accepted: October 26, 2016



**Fig 1.** (A) An axial T<sub>1</sub>-weighted image shows the high-intensity areas inside the mass (arrow). (B) On the axial fat-suppressed T<sub>1</sub>-weighted image, the high-intensity areas seen on the T<sub>1</sub>-weighted image partly show signal reduction. The presence of both fat (arrow) and hemorrhage (arrow-head) is suggested.



**Fig 2.** On this sagittal T<sub>2</sub>-weighted image, low- and high-intensity areas are mixed inside the mass. A cordlike structure connecting the posterior cul-de-sac to the mass is also identified (arrowhead).

University, for clinical discussion of this case and editing this manuscript.

### Conflicts of Interest

The authors declare that they have no conflicts of interest.

### References

1. Del Frate C, Girometti R, Pittino M, Del Frate G, Bazzocchi M, Zuiani C. Deep retroperitoneal pelvic endometriosis: MR imaging appearance with laparoscopic correlation. *Radiographics* 2006; 26:1705–1718.
2. Itoga T, Matsumoto T, Takeuchi H, et al. Fibrosis and smooth muscle metaplasia in rectovaginal endometriosis. *Pathol Int* 2003; 53:371–375.
3. Koninckx PR, Ussia A, Adamyan L, Wattiez A, Donnez J. Deep endometriosis: definition, diagnosis, and treatment. *Fertil Steril* 2012; 98:564–571.