

Quantitative evaluation of palatal bone thickness for the placement of orthodontic miniscrews in adults with different facial types

Yunji Wang, MD, Ye Qiu, MD, Henglang Liu, MD, Jinlong He, MD, Xiaoping Fan, PhD.

ABSTRACT

الأهداف: لتقييم سمك عظام الحنك في البالغين كمياً مع أنواع الوجه المختلفة باستخدام شعاع التصوير المقطعي (CBCT).

الطريقة: وقد تم دراسة البيانات الحجمية CBCT بأثر رجعي لعدد 123 البالغين (متوسط العمر، 26.8 عام) التي تم جمعها خلال الفترة من أغسطس 2014م وأغسطس 2016م. تم تقسيم الأفراد إلى مجموعة زاوية منخفضة (39 فرد)، ومجموعة زاوية طبيعية (48 فرد) ومجموعة عالية الزاوية (36 فرد) على أساس أنواع الوجه المخصصة من قبل التصوير الشعاعي الرأسي. تم تقييم سمك العظم الحنكي عند نقاط محددة. استخدم تحليل متغير لقياس التباين (ANOVA-rm) لاختبار العلاقة بين أنواع الوجه وسماكة العظام الحنكية.

النتائج: وبالمقارنة مع مجموعة الزاوية المنخفضة، كان لدى مجموعة الزاوية العالية عظام الحنك أرق بكثير ($p < 0.05$)، باستثناء خط الوسط الأمامي، والأوسط ووسط خط الوسط.

الخاتمة: المنطقة الأكثر أماناً لوضع الزرعات هو الجزء الأمامي من الحنك المجاور للناصف. يجب على الأطباء إيلاء اهتمام خاص لوجود احتمالات رقة لوحة العظام وخطر الثقب في مجموعة المرضى زاوية عالية.

Objectives: To quantitatively evaluate palatal bone thickness in adults with different facial types using cone beam computed tomography (CBCT).

Methods: The CBCT volumetric data of 123 adults (mean age, 26.8 years) collected between August 2014 and August 2016 was retrospectively studied. The subjects were divided into a low-angle group (39 subjects), a normal-angle group (48 subjects) and a high-angle group (36 subjects) based on facial types assigned by cephalometric radiography. The thickness of the palatal bone was assessed at designated points.

A repeated-measure analysis of variance (rm-ANOVA) test was used to test the relationship between facial types and palatal bone thickness.

Results: Compared to the low-angle group, the high-angle group had significantly thinner palatal bones ($p < 0.05$), except for the anterior-midline, anterior-medial and middle-midline areas.

Conclusion: The safest zone for the placement of microimplants is the anterior part of the paramedian palate. Clinicians should pay special attention to the probability of thinner bone plates and the risk of perforation in high-angle patients.

*Saudi Med J 2017; Vol. 38 (10): 1051-1057
doi: 10.15537/smj.2017.10.20967*

From the Department of Orthodontics, Stomatological Hospital of Chongqing Medical University; Chongqing Key Laboratory of Oral Diseases and Biomedical SciencesChina; Chongqing Municipal Key Laboratory of Oral Biomedical Engineering of Higher Education, Chongqing, China

Received 9th May 2017. Accepted 12th July 2017.

Address correspondence and reprint request to: Dr. Xiaoping Fan, Department of Orthodontics, Stomatological Hospital of Chongqing Medical University; Chongqing Key Laboratory of Oral Diseases and Biomedical SciencesChina; Chongqing Municipal Key Laboratory of Oral Biomedical Engineering of Higher Education, Chongqing, China. E-mail: qytougao@163.com

Miniscrews have been widely used in orthodontic clinics. Their application has increased the viability of skeletal anchorage due to their ability to be positioned in many areas including the buccal alveolus and the hard palate.^{1,2} However, the interradicular spaces are limited by the proximity of neighboring roots or of the periodontium, resulting in failure. These

risk factors can be avoided by the use of “rootless areas” such as the hard palate.³ The palate is a suitable location for the implantation of miniscrews due to its richly keratinized mucosa, low risk of potential root or blood vessel injury and ease of access.^{4,6} The palate consists of cortical bone, which is sufficiently thick and dense to support a miniscrew and to sustain orthodontic loads. Many orthodontists have used palatal miniscrews to move the entire frontal group back and for molar distalization without loss of anchorage.⁷⁻⁹ The thickness of the palate bone is crucial to the suitability of selected implantation sites. Sufficient bone depth would prevent inserted implants from perforating the nasal floor or the maxillary sinus. The morphology of the maxillomandibular complex may be related to the surrounding muscular system, which can affect vertical face patterns.¹⁰ Ozdemir et al¹¹ reported that, in high-angle patients, all miniscrew insertion sites on both jaws have significantly lower values than in low-angle patients. Palatal bone thicknesses will also differ in patients with different facial patterns.

Three-dimensional measurements and analyses of parameters of the maxillomandibular complex such as the morphology and cortical bone thickness of the mandible have become popular recently.^{10,12} Studies have demonstrated that cone beam computed tomography (CBCT) can provide noninvasive tridimensional (3D) images of oral structures. Cone beam computed tomography can reflect the structure of palatal bones. Evaluation of palatal bone depth with CBCT is easy and accurate. Previous studies have investigated palatal bone thickness with CBCT.^{13,14} However, in these studies, subjects with different facial types were not studied. Few comprehensive studies have investigated how palatal bone thickness, as related to mini-implant insertion sites, is affected by different vertical patterns. The objective of the present study was to investigate total palatal bone depth for the placement of orthodontic miniscrews in adults with different facial types.

Disclosure. Authors have no conflict of interests, and the work was not supported or funded by any drug company. The study was funded by the Program for Innovation Team Building at Institutions of Higher Education in Chongqing in 2016 (CXTDG201602006), Chongqing Municipal Key Laboratory of Oral Biomedical Engineering of Higher Education, Health and Family Planning Commission of Chongqing (2015MSXM053) and by Chongqing Research Program of Basic Research and Frontier Technology ([2014]42), Chongqing, China.

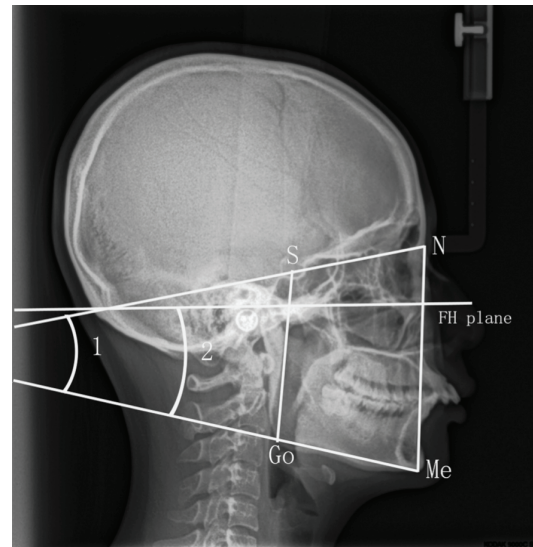


Figure 1 - Cephalometric data showing skeletal variables. N - nasion; S - sella turcica, Me - menton, Go - gonion. $\angle 1$ - S-N/Go-Me angle, $\angle 2$ - FH/Go-Me angle. Vertical facial types were assessed on the basis of the S-Go/N-Me ratio, FH/Go-Me and the S-N/Go-Me angle. FH - Frankfort Horizontal

Methods. All participating individuals provided written informed consent before CBCT scanning, and this study was approved by the Ethical Committee of the Chongqing Medical University, Chongqing, China, which complies with the Declaration of Helsinki. The inclusion criteria were patients with malocclusion who were between 18 and 40 years old. Subjects were excluded if they had a history of orthodontics; facial asymmetry; severe skeletal abnormalities, anomalies, or asymmetric occlusions; impacted teeth or any systemic illnesses. After all inclusive and exclusive criteria were applied, 123 adults (57 men, 66 women) aged 18 to 35 years (mean age, 26.8 years) were selected.

The subjects were divided into 3 groups according to vertical facial types, which were assessed by one senior orthodontist on the basis of the sella turcica (S)-gonion (Go)/nasion (N)-menton (Me) ratio, Frankfort Horizontal (FH)/Go-Me and the S-N/Go-Me angle as measured on lateral cephalograms (Figure 1). Subjects were defined as high- and low-angle if they had S-Go/N-Me ratios less than 61% or greater than 69%, respectively, and the remaining subjects were classified as normal-angle.¹⁵ Patients with FH/Go-Me angles less than 22°, between 22° and 32° and greater than 32° was classified as low-, normal- and high-angle, respectively. Patients with S-N/Go-Me angles less than 27°, between 27° and 37° and greater than 37° were classified as low-, normal- and high-angle, respectively.¹⁶

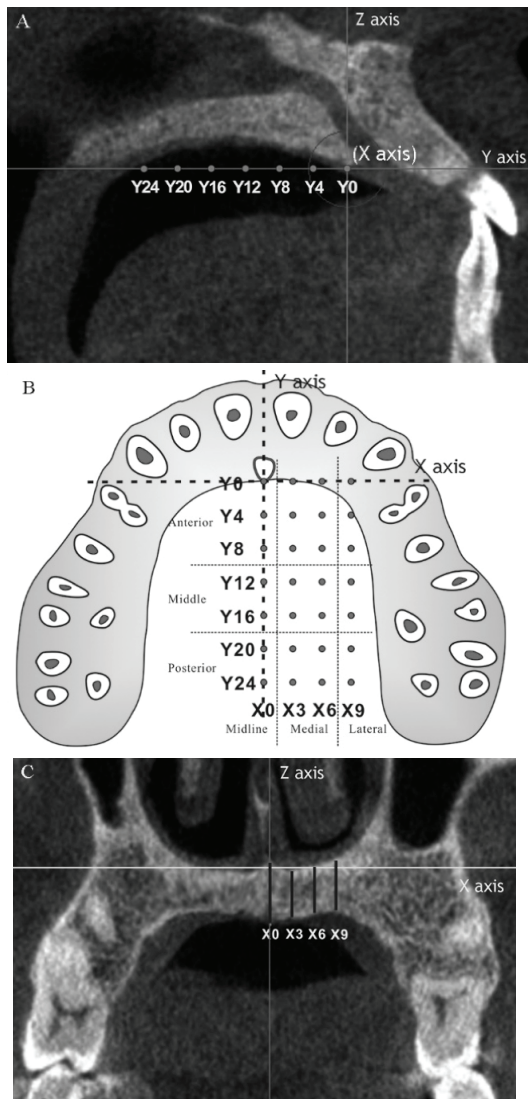


Figure 2 - Measurements of total palatal bone depth. A) Sagittal view showing the designated points along the midline. The line passing through the midpoint of the posterior border of the foramen incisivum and the posterior nasal spine (PNS) was defined as Y axis and midline. On the sagittal view, The line passing through the midpoint of the posterior border of the foramen incisivum and perpendicular to the Y axis was defined as Z axis. The line passing through the midpoint of the posterior border of the foramen incisivum and perpendicular to the Y axis and Z axis was defined as X axis (not shown). The measurement points on the Y axis with intervals of 4 mm anteroposteriorly were numbered from Y0 to Y24. B) The sketch map of measurement points on the horizontal plane. For easier understanding, The plane passing through the X axis and Y axis was defined as the horizontal plane. 28 measurement points were arranged in 4 rows at intervals of 3 mm mediolaterally and 7 lines at intervals of 4 mm anteroposteriorly. The measurement points were divided mediolaterally and anteroposteriorly into 9 areas. C) Coronal view showing a the measurement of bone depth. The dark line passing through each measurement point indicates the bone depth.

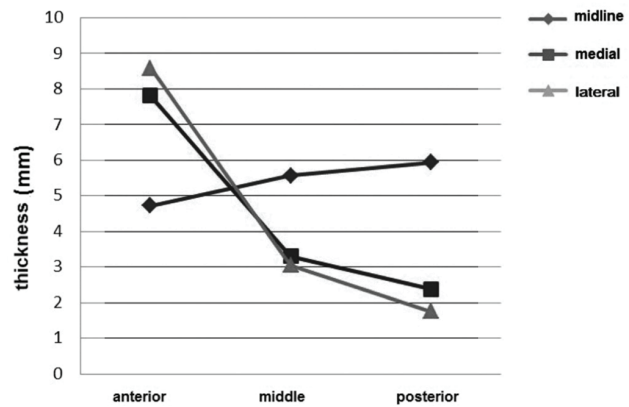


Figure 3 - The bone thicknesses at different areas of the palate. The thickness of mediolateral areas were shown in different shapes. Thickness unit: millimeter (mm).

Subjects with measurements that were inconsistent or borderline were excluded. However, no subject was excluded during the assessment of facial types. The CBCT scans of 123 patients were analyzed. According to vertical facial types, Group A (the low-angle group) included 39 subjects (22 males, 17 females); group B (the normal-angle group) consisted of 48 subjects (26 males, 22 females); and group C (the high-angle group) comprised 36 subjects (17 males, 19 females).

Data were obtained using a KaVo 3D eXam (KavoSybron, Orange, CA). The settings used were as follows: 120 kV, 50 mA, 13×10 cm field of view, exposure time 4 seconds. Digital volumetric tomograms were reconstructed with a 0.4 mm slice thickness in Invivo 5.0 software (Anatomage, San Jose, CA, USA).

The line passing through the midpoint of the posterior border of the foramen incisivum and the posterior nasal spine (PNS) was defined as the midline (Figure 2A). Along the midline, the midsagittal plane was created by multiplanar reconstruction. The line perpendicular to the midsagittal plane was defined as the X-axis. The image was rotated around the X-axis to align the midline on a horizontal plane. On the horizontal plane, 28 measurement points were arranged in 4 rows at intervals of 3 mm mediolaterally; each row contained 7 measurement points with intervals of 4 mm anteroposteriorly¹⁷ (Figure 2B). In the coronal view, bone thickness was measured parallel to the Z-axis at each measurement point (Figure 2C). Measurements were taken twice by one operator. As previous studies have reported, no significant differences were found between the left and right sides of the palate; hence, only data obtained from the left side were analyzed further. Cone beam computed tomography scans from 20 subjects were selected randomly and re-assessed

by the same person, 2 weeks after the initial survey. The intraclass correlation coefficient was used to test intraexaminer reliability.

Statistics analysis. Data analysis was performed using SPSS (Release 13.0, standard version; SPSS, Chicago, IL). The measured bone thickness values were divided mediolaterally and anteroposteriorly into 9 areas¹⁸ (Figure 3). Three designated mediolateral areas were defined: the midline area at the midline palatine suture, the medial area at the reference lines 3 and 6 mm lateral to the midline palatine suture and the lateral area at the line 9 mm lateral to the midline palatine suture. Similarly, three anteroposterior areas were defined: the anterior area at lines 0, 4 and 8 mm; the middle area at lines 12 and 16 mm; and the posterior area at 20 and 24 mm posterior to the distal margin of the foramen incisivum (Figure 3). The repeated-measure analysis of variance (rm-ANOVA) test was used to test for differences among measurements at designated areas, and Fisher's LSD test was used for pairwise comparison. $p < 0.05$ was considered statistically significant.

Results. The intraclass correlation coefficient (ICC) between the 2 assessments showed high reliability ($p > 0.8$). Significant differences in palatal bone thickness were found among the anterior, middle, and posterior areas.¹³ The anterior bone thickness was significantly

lower than the posterior bone thickness in the midline area ($p < 0.05$), but thickness decreased consistently in the posterior direction in the medial and lateral areas ($p < 0.05$). Additionally, we found significant differences among bone thicknesses in the lateral, medial and midline areas ($p < 0.05$). Bone thickness in the midline area decreased progressively in the lateral direction in the middle and posterior areas, except for the anterior area (Table 1, Figure 3). The association between bone thickness and facial types was statistically significant ($p < 0.05$) in the same area of the palate except for the anterior-midline, anterior-medial and middle-midline areas. We found that bone in the low-angle and normal-angle groups was significantly thicker than in the high-angle group in the posterior areas ($p < 0.05$). Further, the bone thicknesses in the low-angle group were significantly higher than in the high-angle group in the anterior-lateral, middle-medial and middle-lateral areas ($p < 0.05$) (Table 2, Figure 4).

Discussion. Depending on mechanical requirements, either buccal or palatal sites of insertion can be useful. Interradicular sites may allow for the stable buccal insertion of skeletal anchorage in most cases. The paramedian palate (PP) is considered an alternative site for the insertion of miniscrews. Another advantage of palatal insertion is that miniscrews with

Table 1 - The thickness of palatal bone in different regions.

Region	Midline	Medial	Lateral	F value	P-value
Anterior	4.72 ± 1.29	7.81 ± 2.29	8.58 ± 2.43	120.38	0.000
Middle	5.56 ± 1.47	3.30 ± 1.47	3.04 ± 1.81	93.41	0.000
Posterior	5.93 ± 1.59	2.37 ± 1.14	1.75 ± 0.96	395.87	0.000
F value	22.38	249.31	481.07		
P value	0.000	0.000	0.000		

Values are expressed as mean ± SD. P - probability, F - freedom

Table 2 - Comparison of the thickness of palatal bone in volunteers with different facial types.

Region	Facial types			F value	P value	Pairwise comparison
	Low-angle (a)	Normal-angle (b)	High-angle (c)			
Anterior-midline	4.75 ± 1.20	4.94 ± 1.37	4.36 ± 1.27	1.939	0.148	-
Anterior-medial	8.13 ± 2.19	7.87 ± 2.29	7.29 ± 2.38	1.289	0.279	-
Anterior-lateral	9.39 ± 2.47	8.55 ± 2.30	7.53 ± 2.21	5.853	0.004†	a>c
Middle-midline	5.59 ± 1.18	5.80 ± 1.59	5.18 ± 1.61	1.693	0.188	-
Middle-medial	3.59 ± 1.48	3.39 ± 1.41	2.77 ± 1.46	3.108	0.048*	a>c
Middle-lateral	3.54 ± 1.83	3.03 ± 1.80	2.34 ± 1.62	4.264	0.016*	a>c
Posterior-midline	6.20 ± 1.43	6.28 ± 1.56	5.06 ± 1.57	7.264	0.001†	a, b>c
Posterior-medial	2.72 ± 1.24	2.47 ± 0.97	1.73 ± 0.97	8.117	0.000†	a, b>c
Posterior-lateral	1.92 ± 0.93	1.86 ± 1.04	1.34 ± 0.76	4.167	0.018*	a, b>c

P - probability, F - freedom, * $p < 0.05$, † $p < 0.01$

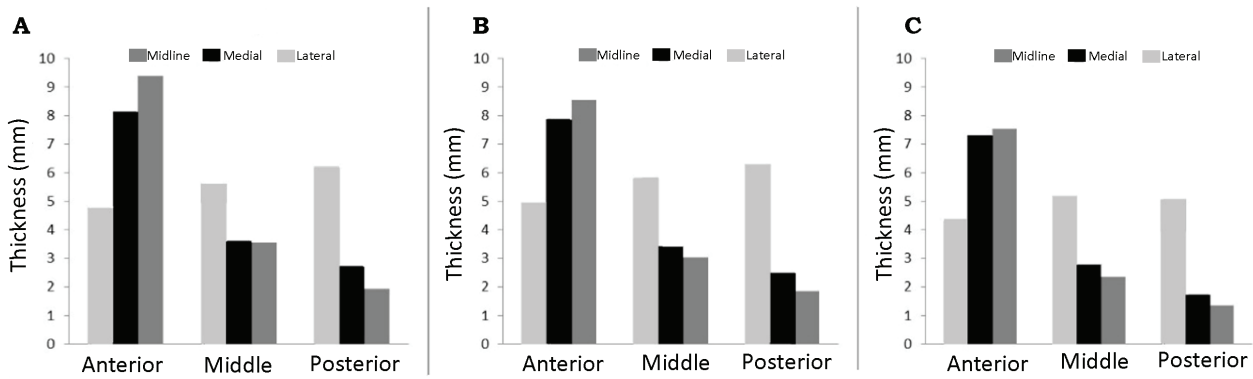


Figure 4 - The bone thicknesses of subjects with different facial types showing the A) low-angle, B) normal-angle, C) high-angle. The thickness of mediolateral areas were shown in different grayscale. Thickness unit: millimeter (mm).

wider diameters can be used, improving stability. Anatomy, particularly bone depth, may directly influence the safety of insertion.¹⁹ Thicker bone can support longer mini-implants, which provide greater primary stability,^{20,21} a factor related to the success of the implant.²² The anatomy of the PP must be determined, with special attention to mapping bone thickness and classifying potential sites for implanting miniscrews. Cone beam computed tomography can provide excellent measurements of bone thickness in the PP, allowing the 3D quantitative measurement of a region of interest (ROI). Surveys of bone thickness in designated planes of the PP have been reported in the literature.^{23,24} Using CBCT to examine an ROI provides a precise method for evaluating bone depth at these locations, and for detecting critical structures such as the canalis incisivus and maxillary sinus.

In this study, the thickest palatal bones were measured in the medial and lateral parts of the anterior area, except for the anterior midline area. In the midline area, the anterior bone thickness was found to be significantly lower compared with the posterior bone thickness. This might be due to the incisive canal, which extends in a posterior-superior direction in the anterior part of the midline area. As our study indicates, the anterior part of the paramedian palate provides sufficient bone volume for microimplants. Consistent with our study, Kang et al¹⁸ and Ryu et al²⁵ reported reduced palatal bone thickness along the lateral and posterior directions in adults. In the middle-medial, middle-lateral, posterior-medial and posterior-lateral areas, the palatal bone thickness was lower compared with that in the midline and anterior areas. Clinicians inserting implants in these areas should either pay more attention to the risk of perforating the nasal cavity or choose shorter mini-implants. According to this study,

bone thickness along the anterior midline is less than in the anterior medial region. This information is also valuable for the clinicians to take into account when inserting long miniscrews in the midpalatal suture in patients with all facial types.²⁶

Poon et al²⁷ found that palatal bone thickness is not associated with tongue position, the existence of a posterior crossbite, or palatal morphology. However, in females, the FMA angle is significantly inversely associated with palatal bone thickness, primarily in the middle to posterior region of the palate. In the present study, we found that palatal bone thickness was significantly related to facial type. The palatal bone depth in high-angle facial type group was significantly thinner than in the low-angle group. These results are in agreement with those of previous studies that evaluated other parameters of different facial types.^{11,28-30} Fulya et al¹¹ found that the cortical bone thickness of both the maxilla and mandible is significantly related to facial type. Low-angle subjects had significantly higher cortical bone thicknesses than high-angle subjects. Similarly, Li et al²⁹ found correlations between facial types and cortical bone thickness in their studies on 3-dimensional images of 101 Asian participants. In the mandibular molar region, cortical bone thicknesses in the low-angle group were significantly thicker than those in the high-angle group. In a clinical study by Moon et al,³¹ success rates and influencing factors of 778 mini-implants were evaluated, and subjects with a high Frankfort-mandibular plane angle and a low-angle facial type were found to have significantly lower odds ratios than those with other facial types. Facial types cause differences in cortical bone thickness, thereby affecting the success of diverse microimplants. Our study found that, for all facial types, the safest zone in the palate for the placement of microimplants was

the anterior part of the paramedian palate. However, clinicians should pay special attention to the probability of thinner bone plates and the risk of perforation in high-angle patients.

The success of mini-implant insertion is influenced by many factors. The minimum bone thickness necessary for microimplant insertion remains controversial, particularly when stability and the protection of other anatomic structures are taken into consideration. Further research regarding palatal bone density, palatal shape and arch form type could provide more information for clinicians.

In conclusion, the anterior part of the paramedian palate provides sufficient bone volume for the insertion of microimplants. For all facial types, the safest zone in the palate for the placement of microimplants is the anterior part of the paramedian palate. Clinicians should pay special attention to the probability of thinner bone plates and the risk of perforation in high-angle patients.

Acknowledgment. *The study was fund by Program for Innovation Team Building at Institutions of Higher Education in Chongqing in 2016 (CXTDG201602006), Chongqing Municipal Key Laboratory of Oral Biomedical Engineering of Higher Education, Health and Family Planning Commission of Chongqing (2015MSXM053) and by Chongqing Research Program of Basic Research and Frontier Technology ([2014]42), Chongqing, China.*

References

1. Ludwig B, Glasl B, Kinzinger GS, Lietz T, Lisson JA. Anatomical guidelines for miniscrew insertion: Vestibular interraderic sites. *J Clin Orthod* 2011; 45: 165-173.
2. Poggio PM, Incorvati C, Velo S, Carano A. "Safe zones": a guide for miniscrew positioning in the maxillary and mandibular arch. *Angle Orthod* 2006; 76: 191-197.
3. Lee J, Miyazawa K, Tabuchi M, Kawaguchi M, Shibata M, Goto S. Midpalatal miniscrews and high-pull headgear for anteroposterior and vertical anchorage control: cephalometric comparisons of treatment changes. *Am J Orthod Dentofacial Orthop* 2013; 144: 238-250.
4. Kyung SH, Lee JY, Shin JW, Hong C, Dietz V, Gianelly AA. Distalization of the entire maxillary arch in an adult. *Am J Orthod Dentofacial Orthop* 2009; 135 (4 Suppl): S123-S132.
5. Ludwig B, Glasl B, Kinzinger GS, Walde KC, Lisson JA. The skeletal frog appliance for maxillary molar distalization. *J Clin Orthod* 2011; 45: 77-84.
6. Watanabe Y, Miyamoto K. A palatal locking plate anchor for orthodontic tooth movement. *J Clin Orthod* 2009; 43: 430-437.
7. Mah SJ, Kim JE, Ahn EJ, Nam JH, Kim JY, Kang YG. Analysis of midpalatal miniscrew-assisted maxillary molar distalization patterns with simultaneous use of fixed appliances: A preliminary study. *Korean J Orthod* 2016; 46: 55-61.

8. Park HS. A miniscrew-assisted transpalatal arch for use in lingual orthodontics. *J Clin Orthod* 2006; 40: 12-16.
9. Kircelli BH, Pektas ZO, Kircelli C. Maxillary molar distalization with a bone-anchored pendulum appliance. *Angle Orthod* 2006; 76: 650-659.
10. Chan HJ, Woods M, Stella D. Mandibular muscle morphology in children with different vertical facial patterns: a 3-dimensional computed tomography study. *Am J Orthod Dentofacial Orthop* 2008; 133: 10.e1-10.e13.
11. Ozdemir F, Tozlu M, Germec-Cakan D. Cortical bone thickness of the alveolar process measured with cone-beam computed tomography in patients with different facial types. *Am J Orthod Dentofacial Orthop* 2013; 143: 190-196.
12. Masumoto T, Hayashi I, Kawamura A, Tanaka K, Kasai K. Relationships among facial type, buccolingual molar inclination, and cortical bone thickness of the mandible. *Eur J Orthod* 2001; 23: 15-23.
13. Deguchi T, Nasu M, Murakami K, Yabuuchi T, Kamioka H, Takano-Yamamoto T. Quantitative evaluation of cortical bone thickness with computed tomographic scanning for orthodontic implants. *Am J Orthod Dentofacial Orthop* 2006; 129: 721.e7-e12.
14. King KS, Lam EW, Faulkner MG, Heo G, Major PW. Vertical bone volume in the paramedian palate of adolescents: a computed tomography study. *Am J Orthod Dentofacial Orthop* 2007; 132: 783-788.
15. Horn AJ. Facial height index. *Am J Orthod Dentofacial Orthop* 1992; 102: 180-186.
16. Riedel RA. The relation of maxillary structures to cranium in malocclusion and in normal occlusion. *The Angle Orthodontist* 1952; 22: 142-145.
17. Lai RF, Zou H, Kong WD, Lin W. Applied anatomic site study of palatal anchorage implants using cone beam computed tomography. *Int J Oral Sci* 2010; 2: 98-104.
18. Ryu JH, Park JH, Vu Thi Thu T, Bayome M, Kim Y, Kook YA. Palatal bone thickness compared with cone-beam computed tomography in adolescents and adults for mini-implant placement. *Am J Orthod Dentofacial Orthop* 2012; 142: 207-212.
19. Rodriguez JC, Suarez F, Chan HL, Padiol-Molina M, Wang HL. Implants for orthodontic anchorage: success rates and reasons of failures. *Implant Dent* 2014; 23: 155-161.
20. Nienkemper M, Wilmes B, Pauls A, Drescher D. Impact of mini-implant length on stability at the initial healing period: a controlled clinical study. *Head Face Med* 2013; 9: 30.
21. Pithon MM, Figueiredo DS, Oliveira DD. Mechanical evaluation of orthodontic mini-implants of different lengths. *J Oral Maxillofac Surg* 2013; 71: 479-486.
22. Cheng SJ, Tseng IY, Lee JJ, Kok SH. A prospective study of the risk factors associated with failure of mini-implants used for orthodontic anchorage. *Int J Oral Maxillofac Implants* 2004; 19: 100-106.
23. Bernhart T, Vollgruber A, Gahleitner A, Dortbudak O, Haas R. Alternative to the median region of the palate for placement of an orthodontic implant. *Clin Oral Implants Res* 2000; 11: 595-601.
24. Gahleitner A, Podesser B, Schick S, Watzek G, Imhof H. Dental CT and orthodontic implants: imaging technique and assessment of available bone volume in the hard palate. *Eur J Radiol* 2004; 51: 257-262.

25. Kang S, Lee SJ, Ahn SJ, Heo MS, Kim TW. Bone thickness of the palate for orthodontic mini-implant anchorage in adults. *Am J Orthod Dentofacial Orthop* 2007; 131 (4 Suppl): S74-S81.
26. Wilmes B, Nienkemper M, Ludwig B, Kau CH, Pauls A, Drescher D. Esthetic Class II treatment with the Beneslider and aligners. *J Clin Orthod* 2012; 46: 390-398.
27. Poon YC, Chang HP, Tseng YC, Chou ST, Cheng JH, Liu PH, et al. Palatal bone thickness and associated factors in adult miniscrew placements: A cone-beam computed tomography study. *The Kaohsiung Journal of Medical Sciences* 2015; 31: 265-270.
28. Horner KA, Behrents RG, Kim KB, Buschang PH. Cortical bone and ridge thickness of hyperdivergent and hypodivergent adults. *Am J Orthod Dentofacial Orthop* 2012; 142: 170-178.
29. Li H, Zhang H, Smales RJ, Zhang Y, Ni Y, Ma J, et al. Effect of 3 vertical facial patterns on alveolar bone quality at selected miniscrew implant sites. *Implant Dent* 2014; 23: 92-97.
30. Turkyilmaz I, Tumer C, Ozbek EN, Tozum TF. Relations between the bone density values from computerized tomography, and implant stability parameters: a clinical study of 230 regular platform implants. *J Clin Periodontol* 2007; 34: 716-722.
31. Moon CH, Park HK, Nam JS, Im JS, Baek SH. Relationship between vertical skeletal pattern and success rate of orthodontic mini-implants. *Am J Orthod Dentofacial Orthop* 2010; 138: 51-57.

Authorship entitlement

Excerpts from the Uniform Requirements for Manuscripts Submitted to Biomedical Journals updated November 2003.
Available from www.icmje.org

The international Committee of Medical Journal Editors has recommended the following criteria for authorship; these criteria are still appropriate for those journals that distinguish authors from other contributors.

Authorship credit should be based on 1) substantial contributions to conception and design, or acquisition of data, or analysis and interpretation of data; 2) intellectual content; and 3) final approval of the version to be published. Authors should meet conditions 1, 2, and 3.

Acquisition of funding, collection of data, or general supervision of the research group, alone, does not justify authorship.

An author should be prepared to explain the order in which authors are listed.