

Delayed right external iliac artery disruption after radical cystectomy: A case report and literature review

LIHUAN DU and ZHEWEI ZHANG

Department of Urology, The Second Affiliated Hospital of Zhejiang University, Hangzhou, Zhejiang 310009, P.R. China

Received April 13, 2023; Accepted July 20, 2023

DOI: 10.3892/mco.2023.2670

Abstract. A 60-year-old male patient underwent laparoscopic radical cystectomy with bilateral pelvic lymph node dissection and urinary diversion as a treatment for muscle-invasive bladder cancer and was discharged two weeks later. One month later, the patient was readmitted with septic and haemorrhagic shock, and was diagnosed with right external iliac artery disruption. The patient underwent an exploratory operation and a vessel split of the right external iliac artery was found. The artery split was covered by a vascular stent. *Klebsiella pneumoniae* subsp. *Pneumoniae* was isolated in blood culture and the patient then received adequate antibiotics based on the drug sensitivity test. The patient eventually had a good recovery and was discharged five weeks later. In summary, although iliac artery injury after successful pelvic surgery is a rare event, this life-threatening complication should be taken into full consideration, particularly in patients with high-risk factors such as diabetes mellitus.

Introduction

Bladder cancer is one of the 10 predominant malignancies globally, with an estimated 573,278 new cases and 212,536 deaths recorded in 2020 (1). It can be divided into muscle-invasive bladder cancer (MIBC) and non-MIBC. MIBC accounts for ~25% of bladder cancer cases at the time of initial diagnosis (2). Radical cystectomy with extended pelvic lymphadenectomy remains the guideline-recommended treatment for MIBC and may provide optimal cancer control (3). Vascular complications, such as intraoperative injury to blood vessels, which results in massive bleeding, are commonly reported complications of radical cystectomy, which is a catastrophic event and may potentially have an unfavorable effect on surgical mortality rates (4,5). Iliac artery pseudoaneurysm

and arterioureteral fistula are rare complications following radical cystectomy (6,7). The present study described another rare case of delayed right external iliac artery disruption that occurred one month after laparoscopic radical cystectomy, without any obvious evidence of iliac artery pseudoaneurysm or arterioureteral fistula.

Case report

A 60-year-old male patient was admitted to the emergency department of the Second Affiliated Hospital of Zhejiang University (Hangzhou, China) in May 2019 with a 2-day history of acute anaemia and fever. The patient had a medical history of poorly controlled diabetes mellitus. Furthermore, the patient had been subjected to a successful laparoscopic radical cystectomy with bilateral pelvic lymph node dissection and urinary diversion and was discharged one month prior. The patient presented with septic and haemorrhagic shock on admission. Enhanced abdominal CT showed diffuse extravasation of the contrast medium from the right external iliac artery, without any evidence of iliac artery pseudoaneurysm or arterioureteral fistula (Fig. 1A). Based on these findings, a diagnosis of right external iliac artery disruption was made.

Broad-spectrum antibiotics (imipenem) were started empirically and then, an open, exploratory operation was undertaken immediately, during which extensive adhesion formation and inflammation around the ileal bladder and external iliac artery were found. More importantly, a vessel split of the right external iliac artery was found after removing the visible blood clots and hematoma around it. Therefore, the diagnosis of disruption and bleeding of the right external iliac artery was confirmed. A vascular stent was inserted to cover the artery split by a vascular surgeon. The patient was then transferred to the intensive care unit for further resuscitation.

Klebsiella pneumoniae subsp. *Pneumoniae* (KPSP) was isolated in blood culture which was performed according to standard protocols three days later. The standard drug susceptibility test determined that KPSP was more sensitive to tigecycline and imipenem. Appropriate antibiotics (tigecycline plus imipenem) were then administered based on the above results of bacterial culture and drug sensitivities. The vital signs and corresponding blood tests of the patient became normal within three weeks. Furthermore, repeat enhanced CT indicated no effusion of the contrast medium one month later

Correspondence to: Dr Lihuan Du, Department of Urology, The Second Affiliated Hospital of Zhejiang University, 88 Jiefang Road, Hangzhou, Zhejiang 310009, P.R. China
E-mail: dlh1984@zju.edu.cn

Key words: iliac artery disruption, *Klebsiella pneumoniae*, radical cystectomy, urinary diversion, lymph node dissection

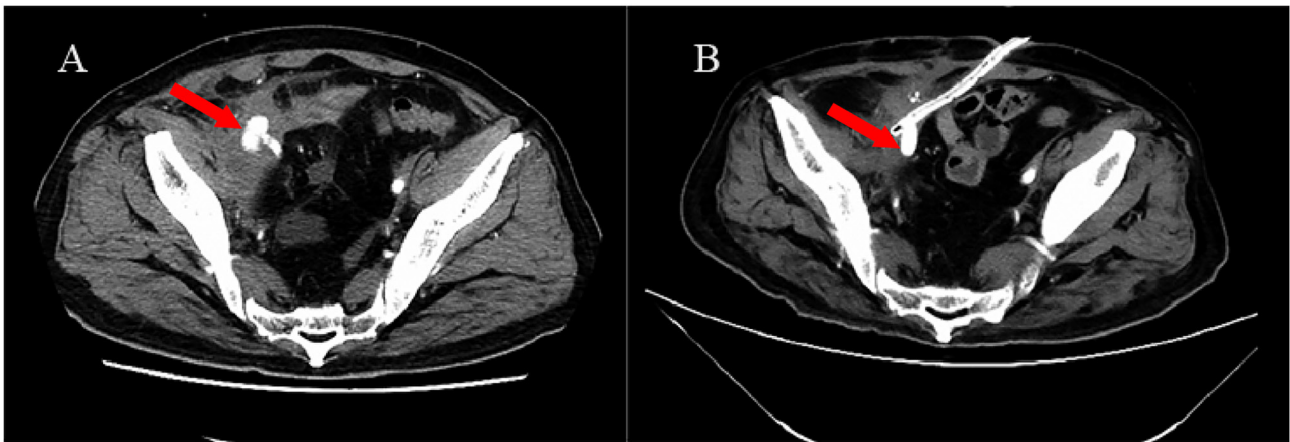


Figure 1. (A) Abdominal enhanced CT scan showed diffuse extravasation of the contrast medium from the right external iliac artery before surgery, as indicated by the red arrow. (B) Postoperative CT scan showed no medium effusion after surgery, with placement of a vascular stent and abdominal drainage tube.

(Fig. 1B). The patient was discharged one week after the repeat CT scan. Follow-up was carried out every 3 months in the first year and every 6 months thereafter. To date, the patient has been followed up for nearly 4 years with no relapse.

Discussion

KP is a common pathogen that causes infections involving the urinary tract, lungs, surgical sites, abdominal cavity, intravascular devices, soft tissues and subsequent bacteremia, particularly in alcoholics and diabetic patients (8,9). For the patient of the present study, diabetes mellitus and immunosuppression due to a major operation were possible risk factors for KP infection in the blood.

Previous studies indicated that KP entry through an overt or occult break in the skin resulted in initial bacteremia (10). The subsequent spread of bacteremia may lead to various complications, such as endophthalmitis, meningitis and aneurysm (11-13). As a gram-negative encapsulated rod, KP has a higher tendency to expand and rupture the vessel wall where it colonizes (14). It was thus speculated that KPSP, which belongs to the KP family, was seeded from the initial bacteremia and then colonized into the right external iliac artery, causing uncontrollable sepsis and arteritis. KPSP infection eventually leads to such catastrophic vessel rupture. The corresponding antibiotics for KPSP were subsequently changed based on the drug sensitivity test to control the bacterial infection and the vessel wall exhibited no evidence of split recurrence at the time of writing the present report.

As interventions, endovascular treatments such as vascular stent grafts are now suggested to be a better choice than conventional surgical vessel repair because severe vessel injuries destabilize the haemodynamic status of the patient and preclude open repair of the lesion (8). In the present case, vascular stent insertion but not vessel suturing was carried out. Both antibiotics and endovascular operation had an important role in the quick recovery of the patient.

In conclusion, timely detection, adequate antibiotic treatment and emergency vascular stent insertion are important strategies for physicians to manage this rare but life-threatening condition. However, large-scale, prospec-

tive, controlled trials are in high demand to comprehensively evaluate the effectiveness and feasibility of these antibiotic and surgical treatments.

Acknowledgements

Not applicable.

Funding

This study was supported by the Natural Science Foundation of Zhejiang Province (grant no. LQ20H1 60032) and the Natural Science Foundation of Fujian Province (grant no. 2018J05124).

Availability of data and materials

The datasets used and/or analysed during the current study are available from the corresponding author upon reasonable request.

Authors' contributions

LD contributed to the conception and design of the study, obtained the raw data of the patient, such as laboratory data and imaging examinations, and wrote the manuscript. LD and ZW participated in the diagnosis and treatment of the patient. LD and ZW checked and confirmed the authenticity of all the raw data. Both authors have read and approved the final manuscript.

Ethics approval and consent to participate

The present study was approved by the Ethics Committee of the Second Affiliated Hospital of Zhejiang University (Hangzhou, China).

Patient consent for publication

The patient provided written consent for the publication of the case details and any associated images.

Competing interests

The authors declare that they have no competing interests.

References

- Sung H, Ferlay J, Siegel RL, Laversanne M, Soerjomataram I, Jemal A and Bray F: Global Cancer Statistics 2020: GLOBOCAN estimates of incidence and mortality worldwide for 36 cancers in 185 countries. *CA Cancer J Clin* 71: 209-249, 2021.
- Comperat E, Larre S, Roupert M, Neuzillet Y, Pignot G, Quintens H, Houede N, Roy C, Durand X, Varinot J, *et al*: Clinicopathological characteristics of urothelial bladder cancer in patients less than 40 years old. *Virchows Arch* 466: 589-594, 2015.
- Russell B, Liedberg F, Khan MS, Nair R, Thurairaja R, Malde S, Kumar P, Bryan RT and Van Hemelrijck M: A systematic review and Meta-analysis of delay in radical cystectomy and the effect on survival in bladder cancer patients. *Eur Urol Oncol* 3: 239-249, 2020.
- Konety BR, Allareddy V and Herr H: Complications after radical cystectomy: Analysis of population-based data. *Urology* 68: 58-64, 2006.
- Lazzeri M, Benaim G, Turini D, Beneforti P and Turini F: Iatrogenic external iliac artery disruption during open pelvic lymph node dissection: Successful repair with hypogastric artery transposition. *Scand J Urol Nephrol* 31: 205-207, 1997.
- Laddha A, Pooleri GK and Thomas A: External iliac artery pseudoaneurysm following radical cystectomy: A report of two cases. *Indian J Urol* 36: 56-58, 2020.
- Jiang Z, Wang J, Cui J, Chen S, Qu S, Wang W, Guo H, Shi B and Zhu Y: Arterioureteral fistula after radical cystectomy and ureterocutaneostomy: Two case reports and a systematic literature review. *BMC Urol* 22: 117, 2022.
- Wu CY, Hung YN, Liu YH and Ko PJ: Endovascular treatment of iatrogenic iliac artery disruption in lumbar disc surgery. *Ann Vasc Surg* 23: 255.e7-11, 2009.
- Lin YT, Wang FD, Wu PF and Fung CP: *Klebsiella pneumoniae* liver abscess in diabetic patients: Association of glycemic control with the clinical characteristics. *BMC Infect Dis* 13: 56, 2013.
- Shon AS, Bajwa RP and Russo TA: Hypervirulent (hypermucoviscous) *Klebsiella pneumoniae*: A new and dangerous breed. *Virulence* 4: 107-118, 2013.
- Namikawa H, Yamada K, Fujimoto H, Oinuma KI, Tochino Y, Takemoto Y, Kaneko Y, Shuto T and Takeya H: Two unusual cases of successful treatment of hypermucoviscous *Klebsiella pneumoniae* invasive syndrome. *BMC Infect Dis* 16: 680, 2016.
- Wu KM, Li LH, Yan JJ, Tsao N, Liao TL, Tsai HC, Fung CP, Chen HJ, Liu YM, Wang JT, *et al*: Genome sequencing and comparative analysis of *Klebsiella pneumoniae* NTUH-K2044, a strain causing liver abscess and meningitis. *J Bacteriol* 191: 4492-4501, 2009.
- Maruno T, Ooiwa Y, Takahashi K, Kodama Y, Takakura S, Ichiyama S and Chiba T: A liver abscess deprived a healthy adult of eyesight: Endogenous endophthalmitis associated with a pyogenic liver abscess caused by serotype K1 *Klebsiella pneumoniae*. *Intern Med* 52: 919-922, 2013.
- Molacek J, Treska V, Baxa J, Certik B and Houdek K: Acute conditions caused by infectious aortitis. *Aorta (Stamford)* 2: 93-99, 2014.



Copyright © 2023 Du and Zhang. This work is licensed under a Creative Commons Attribution-NonCommercial-NoDerivatives 4.0 International (CC BY-NC-ND 4.0) License.