

MAJOR PAPER

Prediction of Sufficient Liver Enhancement on the Gadoxetate Disodium-enhanced Hepatobiliary Phase Imaging Using Transitional Phase Images and Albumin–bilirubin Grade

Yasuo Takatsu^{1,2*}, Masafumi Nakamura³, Satoshi Kobayashi², and Tosiaki Miyati²

Purpose: To investigate whether the contrast enhancement effect in hepatobiliary phase (HBP) images can be predicted using transitional phase (3-min delay) images on liver magnetic resonance imaging (MRI) based on the quantitative liver–spleen contrast ratio (Q-LSC) and albumin–bilirubin (ALBI) grade.

Methods: Overall, 212 patients (124 men and 88 women; mean age 66.7 ± 11.1 years) who underwent blood tests (assessed within 1 month of performing MRI) were included; patients with diffuse tumor, hepatectomy, splenectomy, Gamna–Gandy bodies in the spleen, and movement artifacts were excluded. Q-LSC was calculated using the signal intensity of the liver divided that of the spleen. Q-LSC > 1.5 (cut-off value) indicates a relatively higher sensitivity for detecting of hepatic lesions. To predict the contrast enhancement effect in HBP using Q-LSC of 3-min delay images, Q-LSC of 10- and 15-min delay images were compared for each ALBI grade based on Q-LSC of 3-min delay images. Furthermore, to verify the accuracy of this prediction, the proportion of cases with Q-LSC > 1.5 in 10- and 15 min delay images was calculated based on Q-LSC on 3-min delay images.

Results: The higher the Q-LSC on the 3-min delay image, the higher was the Q-LSC on its 10- and 15-min delay images. The proportion of cases with Q-LSC > 1.5 in 10- and 15-min delay images was higher for ALBI grade 1 than for ALBI grades 2 and 3 even in the same Q-LSC on 3-min delay images. Q-LSC was <1 in a 3-min delay image and <1.5 in a 15-min delay image in 62.2% of patients with ALBI grade 1 and 82.1% of patients with ALBI grades 2 and 3.

Conclusion: The liver contrast enhancement effect in HBP images could be predicted using a 3-min delay image based on Q-LSC and ALBI grade.

Keywords: magnetic resonance imaging, gadolinium–ethoxybenzyl–diethylenetriamine penta-acetic acid, delay time, quantitative liver–spleen contrast ratio, albumin–bilirubin grade

Introduction

At present, gadolinium–ethoxybenzyl–diethylenetriamine penta-acetic acid (Gd–EOB–DTPA; Primovist; Bayer Schering Parma AG, Berlin, Germany) is widely used in magnetic resonance imaging (MRI) of the liver. Gd–EOB–DTPA accumulates in the liver over time.¹

¹Department of Radiological Technology, Faculty of Health and Welfare, Tokushima Bunri University, Kagawa, Japan

²Division of Health Sciences, Graduate School of Medical Sciences, Kanazawa University, Ishikawa, Japan

³Department of Radiology, Otsu City Hospital, Shiga, Japan

*Corresponding author: Department of Radiological Technology, Faculty of Health and Welfare, Tokushima Bunri University, 1314-1, Shido, Sanuki, Kagawa 769-2193, Japan. Phone: +81-87-899-7293, Fax: +81-87-894-4201, E-mail: pblue2@yahoo.co.jp

©2020 Japanese Society for Magnetic Resonance in Medicine

This work is licensed under a Creative Commons Attribution-NonCommercial-NoDerivatives International License.

Received: August 13, 2019 | Accepted: April 4, 2020

The contrast between liver tumor and liver parenchyma is increased in the hepatobiliary phase (HBP), which aids in the diagnosis. The degree of contrast medium uptake in HBP imaging depends on the transporters^{2,3} or liver function.^{4–7} The indocyanine green clearance test performed at 15 min after injection correlates with the Gd–EOB–DTPA uptake in HBP images.^{7–10} In addition, the albumin–bilirubin (ALBI) grade is a simple measure of liver function^{11–13} and also correlates with the Gd–EOB–DTPA uptake in HBP images.¹⁴

The quantitative liver–spleen contrast ratio (Q-LSC) has been used for evaluating the Gd–EOB–DTPA uptake in HBP images^{7,9,15} because a Q-LSC of >1.5, which is the cut-off value, has a relatively higher sensitivity for detecting hepatic lesions.¹⁵

A suitable delay time of HBP is needed for the diagnosis of hepatic lesions. Regarding the scan timing for HBP, several delay times after Gd–EOB–DTPA administration have been reported.^{5,16–18} According to previous reports,

a 10-min delay is sufficient for diagnosis in patients without a history of chronic liver disease.^{16,17} whereas a 15-min delay is sufficient for diagnosis in those with mild liver dysfunction; however, a delay of >5 min is ineffective for diagnosis in patients with moderate or severe liver dysfunction.¹⁸ Furthermore, the liver relative enhancement between pre- and HBP image was a statistically significant improvement on HBP-30 relative to HBP-20.⁵

If the extended delay time of HBP is identified beforehand, imaging can be performed on another patient instead of wasting time while waiting. Thereafter, after imaging is performed in the other patient, examination of the previous patient can be continued.

It is necessary to predict an appropriate delay time to avoid long examination times for the diagnosis of patients, thereby facilitating the imaging examination in more patients in a short time and avoiding fatigue in patients.

However, to the best of our knowledge, the prediction of the contrast enhancement effect in HBP using dynamic phase (DP) images has not been reported to date. In general, several DP images are obtained before HBP. The uptake tendency of Gd–EOB–DTPA could be directly obtained from the DP images.

Q-LSC and ALBI grades are well correlated and discriminated in comparison with the Child–Pugh score;¹⁴ therefore, we focused on determining a correlation between Q-LSC and ALBI grades.

The purpose of this study was to investigate whether the contrast enhancement effect in HBP images can be predicted

using transitional phase (3-min delay) images on liver MRI based on Q-LSC and ALBI grades.

Materials and Methods

Patients

This retrospective study was approved by the ethics committee of Otsu City Hospital (Otsu, Shiga, Japan). A total of 305 consecutive patients underwent liver MRI with Gd–EOB–DTPA between April 2015 and December 2016. When multiple examinations were performed in follow-up cases, only the most recent examinations were considered.

Blood test (assessed within 1 month of performing MRI) and pathological data were obtained using an electronic medical record system (EGMAIN-GX version 7, Fujitsu, Tokyo, Japan). In 20 patients, the interval between MRI and blood tests was more than 1 month. Furthermore, blood test data (albumin or bilirubin) were absent in 33 patients. Finally, 252 patients were available for the analysis of blood data (interval between MRI and blood test: average 6.5 days; range –31 to 31 days) (Fig. 1).

Exclusion criteria were the presence of a diffuse tumor ($n = 9$), hepatectomy ($n = 9$), splenectomy ($n = 8$), Gamna–Gandy bodies in the spleen ($n = 2$), and movement artifacts ($n = 15$).

We excluded a total of 93 patients based on the above-mentioned exclusion criteria and analyzed the data of 212 patients (124 men and 88 women; mean age 66.7 ± 11.1 years) (Fig. 1). The Child–Pugh score in these patients were Child–Pugh A ($n = 86$), B ($n = 126$), and C ($n = 0$).

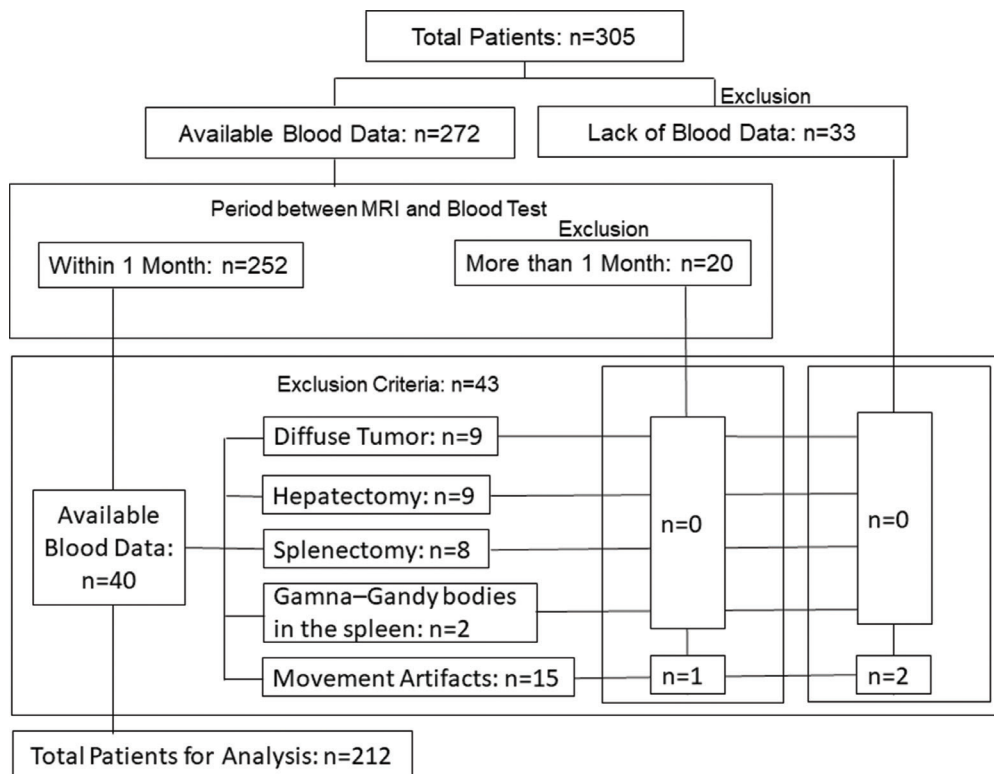


Fig. 1 Patient flow chart in this study.

These patients had the following liver diseases: hepatitis B ($n = 43$) or C ($n = 80$), including liver cirrhosis ($n = 40$), primary biliary cirrhosis ($n = 5$), alcoholic chronic hepatitis ($n = 18$), and chronic liver disease without hepatitis virus infection or alcohol abuse ($n = 28$). Moreover, 38 patients had no chronic liver disease or pathology.

The following pathologies were noted in the analyzed patients: liver tumor ($n = 115$), hepatocellular carcinoma ($n = 69$), hemangioma ($n = 24$), and metastasis ($n = 22$); of which 18 underwent radio frequent ablation ($n = 16$), transcatheter arterial chemoembolization ($n = 1$), and percutaneous ethanol injection therapy ($n = 1$).

Calculation of ALBI grade

ALBI was calculated as follows:¹¹

$$\text{Linear predictor} = (\log_{10} \text{bilirubin} \times 0.66) + (\text{albumin} \times -0.085),$$

where bilirubin is in $\mu\text{mol/L}$ and albumin in g/L . ALBI was categorized into three groups according to previously described cut-offs as follows: grade 1 ≤ -2.60 , grade 2 > -2.60 to ≤ -1.39 , and grade 3 > -1.39 .

Magnetic resonance imaging

MRI was performed using a 3T MRI unit (Ingenia, anterior coil; Philips Medical Systems, Best, The Netherlands) with fat-saturated three-dimensional gradient echo sequences, such as enhanced T_1 high resolution isotropic volume excitation (e-Thrive) with TR, 2.86 ms; TE, 1.38 ms; sensitivity encoding factor, 2; flip angle, 11° ; field of view, 360×306 mm; matrix, 240×204 (frequency \times phase direction); slice thickness, 3 mm (overcontiguous, 1.5 mm); number of slices, 140; bandwidth, 868.1 Hz per pixel; and scan time, 16.8 s. For all examinations, the entire liver could be covered using 140 slices. Dynamic images were obtained at 30 s, 1 min 20 s, and 3 min, whereas HBP images were obtained at 10 and 15 min after injecting Gd-EOB-DTPA at a dose of 0.1 mL/kg body weight. A 20-min delay during HBP imaging was not obtained because it has been reported that a 15-min delay is adequate for capturing HBP.¹⁸

Data analysis

Assessment of parenchymal enhancement: Q-LSC was calculated from the signal intensity (SI) of the liver and spleen⁷ for the transitional phase (3 min after Gd-EOB-DTPA injection) and HBP images (10 and 15 min after Gd-EOB-DTPA injection) using the following equation:

$$\text{Q-LSC} = \frac{\text{SI}_L}{\text{SI}_S}$$

where SI_L is the mean signal intensity of the region of interest (ROI) in normal liver parenchyma and SI_S is the mean signal intensity in the homogeneous region of the spleen.

To calculate Q-LSC while measuring SI using transaxial images, the ROI (circle or oval) was carefully set to exclude large vessels and reduce any error due to macroscopic flow.

ROIs were drawn in two locations of the anterior and posterior segment of the right lobe and a medial segment in the left lobe for hepatic parenchymal SI. The location was 1 cm from the inner edge of the liver and three locations in a homogeneous region of the spleen. The left lateral segment was excluded because it was relatively easy to influence that artifact of the heart. Each ROI was approximately 200 mm^2 . Details of the ROI setting for the liver parenchyma and spleen have been reported previously.¹⁴

MRI data were analyzed using a clinical workstation (SYNAPSE VINCENT version 4.1.0003; FUJIFILM Medical, Tokyo, Japan) by a single radiological technologist with 18 years of experience in MRI who was blinded to the diagnosis and medical background of patients.

Prediction of the liver contrast enhancement in HBP

To predict the contrast enhancement effect in HBP from Q-LSC of 3-min delay images, first, changes over time in Q-LSC were confirmed. The Q-LSC of 10- and 15-min delay images were compared with the Q-LSC of its 3-min delay image for each ALBI grade.

Second, to prove the accuracy of this prediction, the proportion of cases with $\text{Q-LSC} > 1.5$ (i.e., the cut-off value of Q-LSC) in 10- and 15-min delay images was calculated based on Q-LSC of its 3-min delay image.

Comparisons of the Q-LSC of HBP images at 3-, 10-, and 15-min delays

Quantitative liver-spleen contrast ratio was calculated and the data presented as the median and interquartile range (IQR). Q-LSC values of 3-, 10-, and 15-min delay images were compared depending on the ALBI grades. Moreover, Q-LSC of 3-min delay images was divided into five groups (" <0.9 ," " $\geq 0.9, <1$," " $\geq 1, <1.1$," " $\geq 1.1, <1.2$," and " ≥ 1.2 "), which was then compared with the Q-LSC of 10- and 15-min delay images.

The Friedman test, Kruskal-Wallis one-way analysis of variance, and Steel-Dwass multiple comparison test were used for statistical analyses (R v. 2.8.1). P -values of <0.05 were considered statistically significant.

Calculation of the proportion of cases with Q-LSC > 1.5 at each time point

As reported previously, Q-LSC greater than the cut-off value of 1.5 is associated with satisfactory enhancement of liver parenchyma for the detection of hepatic lesions.¹⁵ Therefore, the proportion of cases with $\text{Q-LSC} > 1.5$ was calculated using Q-LSC of 10- and 15-min images, which were based on the Q-LSC of 3-min delay images that were divided into five groups (see Section "Comparisons of the Q-LSC of HBP images at 3-, 10-, and 15-min delays").

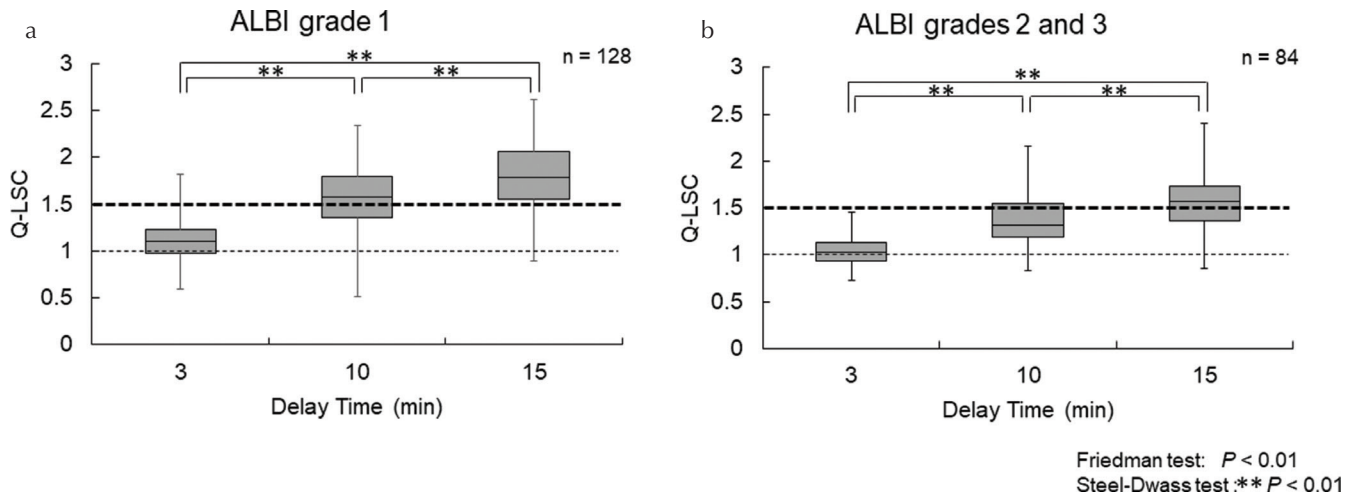


Fig. 2 Comparison of quantitative liver-spleen contrast ratio (Q-LSC) among 3-, 10-, and 15-min delays by the albumin-bilirubin (ALBI) grade. ALBI grade 1 (a) and ALBI grades 2 and 3 (b).

Calculation of inter- and intrareader reliabilities

For the measurement of Q-LSC, inter- and intrareader reliabilities were investigated by calculating intraclass correlation coefficients (ICC) using complete data of the analyzed patients (212 patients) for two radiological technologists with 18 and 20 years of experience in MRI.

Results

We analyzed the data of 212 patients for ALBI grades (grade 1, $n = 128$; grade 2, $n = 81$; and grade 3, $n = 3$).

Comparisons of the Q-LSC of the HBP images at 3-, 10-, and 15-min delays

The longer was the delay time, the higher was the Q-LSC. Because the number of patients in ALBI grade 3 was small ($n = 3$), the patients in grade 3 were combined with those in ALBI grade 2. The findings of Q-LSC of 3-, 10-, and 15-min delay images are shown in Fig. 2. The median (IQR) Q-LSC for ALBI grade 1 was higher than that for ALBI grades 2 and 3. Friedman test and Steel-Dwass multiple comparison test revealed significant difference in Q-LSC values among 3-, 10-, and 15-min delay images in ALBI grade 1 and ALBI grades 2 and 3 ($P < 0.01$; Fig. 2).

For the range of Q-LSC on 3-min delay images, significant differences were observed for all the ranges, except between “ ≥ 1 , < 1.1 ” and “ ≥ 1.1 , < 1.2 ” in 10-min delay ($P = 0.053$) and between “ < 0.9 ” and “ ≥ 0.9 , < 1 ” in 15-min delay ($P = 0.148$) for ALBI grade 1, between “ ≥ 1.1 , < 1.2 ” and “ ≥ 1.2 ” in 10-min delay ($P = 0.159$), between “ < 0.9 ” and “ ≥ 0.9 , < 1 ” ($P = 0.129$), between “ ≥ 0.9 , < 1 ” and “ ≥ 1 , < 1.1 ” ($P = 0.071$), between “ ≥ 1 , < 1.1 ” and “ ≥ 1.1 , < 1.2 ” ($P = 0.091$), and between “ ≥ 1.1 , < 1.2 ” and “ ≥ 1.2 ” ($P = 0.076$) in 15-min delay for ALBI grades 2 and 3, as per Kruskal-Wallis one-way analysis of variance and Steel-Dwass multiple comparison

test (Fig. 3). The higher the Q-LSC on 3-min delay images, the higher was the Q-LSC of 10- and 15-min delay images.

Proportion of cases with Q-LSC > 1.5 at each time point

The proportion of cases with Q-LSC > 1.5 of 10- and 15-min delay images was higher for ALBI grade 1 than for ALBI grades 2 and 3 even in the same Q-LSC of 3-min delay images. When Q-LSC at a 3-min delay was ≥ 1.2 , it was ≥ 1.5 at 10-min delay in 100% of patients with ALBI grade 1 and 81.8% of patients with ALBI grades 2 and 3. Q-LSC was < 1 at a 3-min delay and < 1.5 at a 15-min delay in 62.2 % of patients with ALBI grade 1 and 82.1% of patients with ALBI grades 2 and 3 (Fig. 4).

Inter- and intrareader reliabilities

Intraclass correlation coefficients values were 0.990 (inter-reader) and 0.963 (intrareader).

Sample images

In sample images, when Q-LSC was ≥ 1.5 at 10- and 15-min delay, the contrast between the liver parenchyma and the spleen was clear, respectively. However, when Q-LSC was < 1.5 at a 15-min delay, the contrast between the liver parenchyma and spleen was unclear (Fig. 5).

Discussion

We obtained accuracy data to verify the prediction using late dynamic imaging based on the ALBI grades because of the tendency for direct uptake of the contrast medium and the good correlation between the ALBI grade and HBP image.¹⁴

When the delay time was extended, Q-LSC was increased at least with a 15-min delay in cases of each ALBI grade. According to a previous report, a 15-min delay is sufficient for

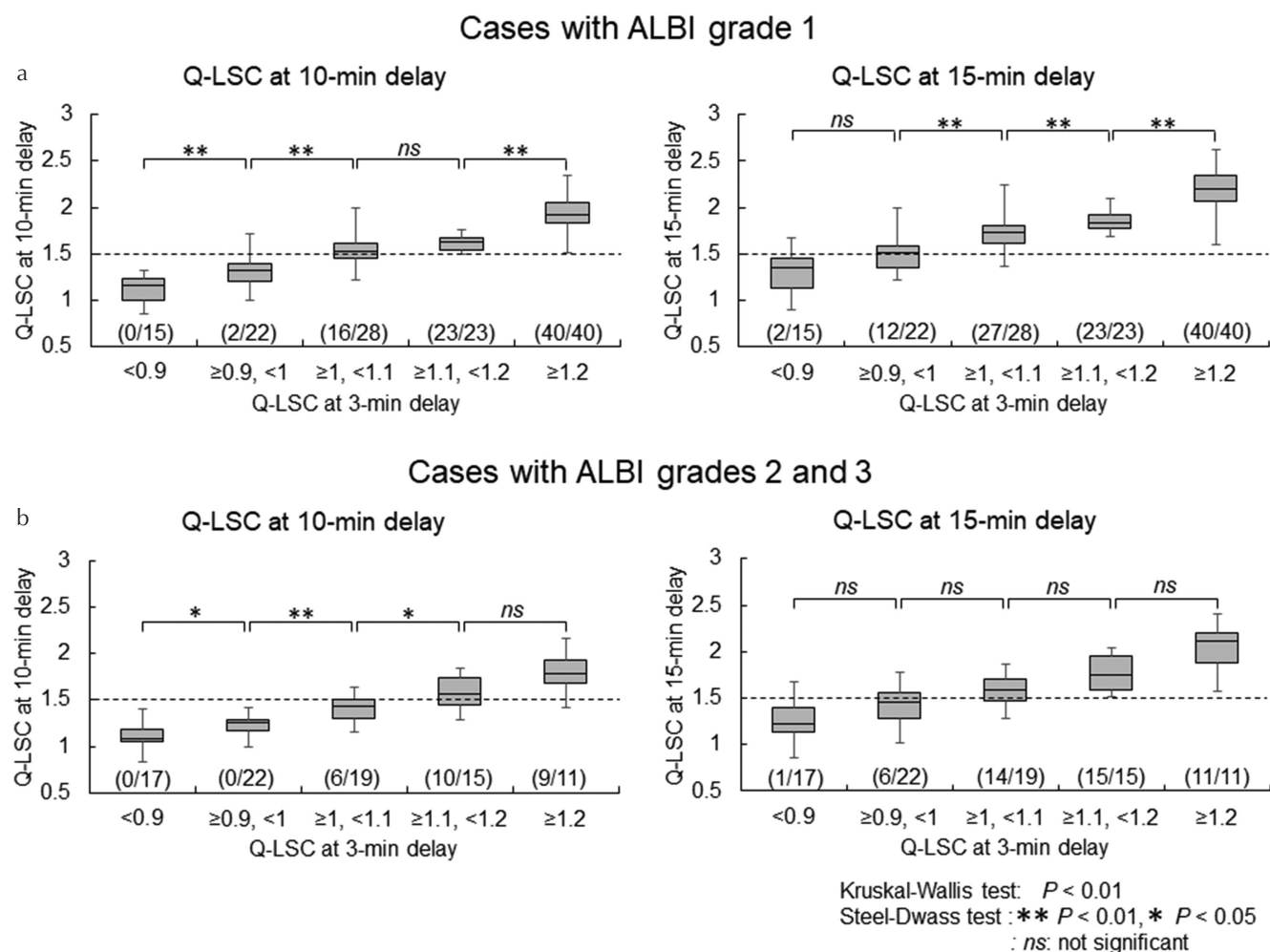


Fig. 3 Comparison of quantitative liver–spleen contrast ratio (Q-LSC) among 3-, 10-, and 15-min delays. Q-LSC of 3-min delay images was divided into five groups, these were then compared with the Q-LSC of 10- and 15-min delay images. Q-LSC at 10-min and 15-min delays of cases with albumin–bilirubin (ALBI) grade 1 (a) and of those with ALBI grades 2 and 3 (b) (Number of cases with cut-off value of Q-LSC ≥ 1.5 /total number of cases).

diagnosis in patients with mild liver dysfunction; however, a >5-min delay is irrelevant for diagnosis in patients with moderate or severe liver dysfunction.¹⁸ However, in the present study, Q-LSC was increased from 10 to 15 min, and relatively fewer patients had ALBI grade 3 ($n = 3$). We believe that further study is warranted to confirm these findings and obtain more accurate data for a super delay phase (e.g., >30 min) for this conclusion.

It has been reported that in cases wherein the Gd–EOB–DTPA uptake is insufficient, an extended delay time is useful;⁵ therefore, a super delay phase can be considered. If this uptake is increased, the contrast between the liver parenchyma and tumor will increase, thus leading to accurate detection of the tumor.

When Q-LSC at a 3-min delay was ≥ 1.2 , it was ≥ 1.5 at a 10-min delay. However, when Q-LSC at 3-min delay was < 1 , 62.2% of patients with ALBI grade 1 and 82.1% of patients with ALBI grades 2 and 3 could not achieve Q-LSC of 1.5 at a 15-min delay. Therefore, if Q-LSC at a 3-min delay is < 1 ,

such as in “case 3” of the sample images (Fig. 5), it is better to perform the analysis with the super delay phase (e.g., >30 min) instead of waiting for 15 min.

For example, for the cases presented herein, when a 15- or 20-min delay was skipped, the HBP (super delay phase) could be performed after another patient. However, at the transition zone, when Q-LSC is ≥ 0.9 but < 1 at a 3-min delay, it may be necessary to wait for 15 min to achieve results. The detectability of the liver tumor can be improved when the Q-LSC is ≥ 1.5 , which is the cut-off value.¹⁵ If the delay time was extended, then Q-LSC of ≥ 1.5 could be expected.

Q-LSC was < 1 at 3-min delay leads to concerns that the result could be influenced by insufficient breath hold, body movement, and poor physical condition due to patient’s fatigue after several randomized short-span scans or a long study time.^{19,20} We considered that an HBP image wherein Q-LSC of ≥ 1.5 could be obtained when performing a smooth study, thereby increasing the throughput with an early decision for a super delay.

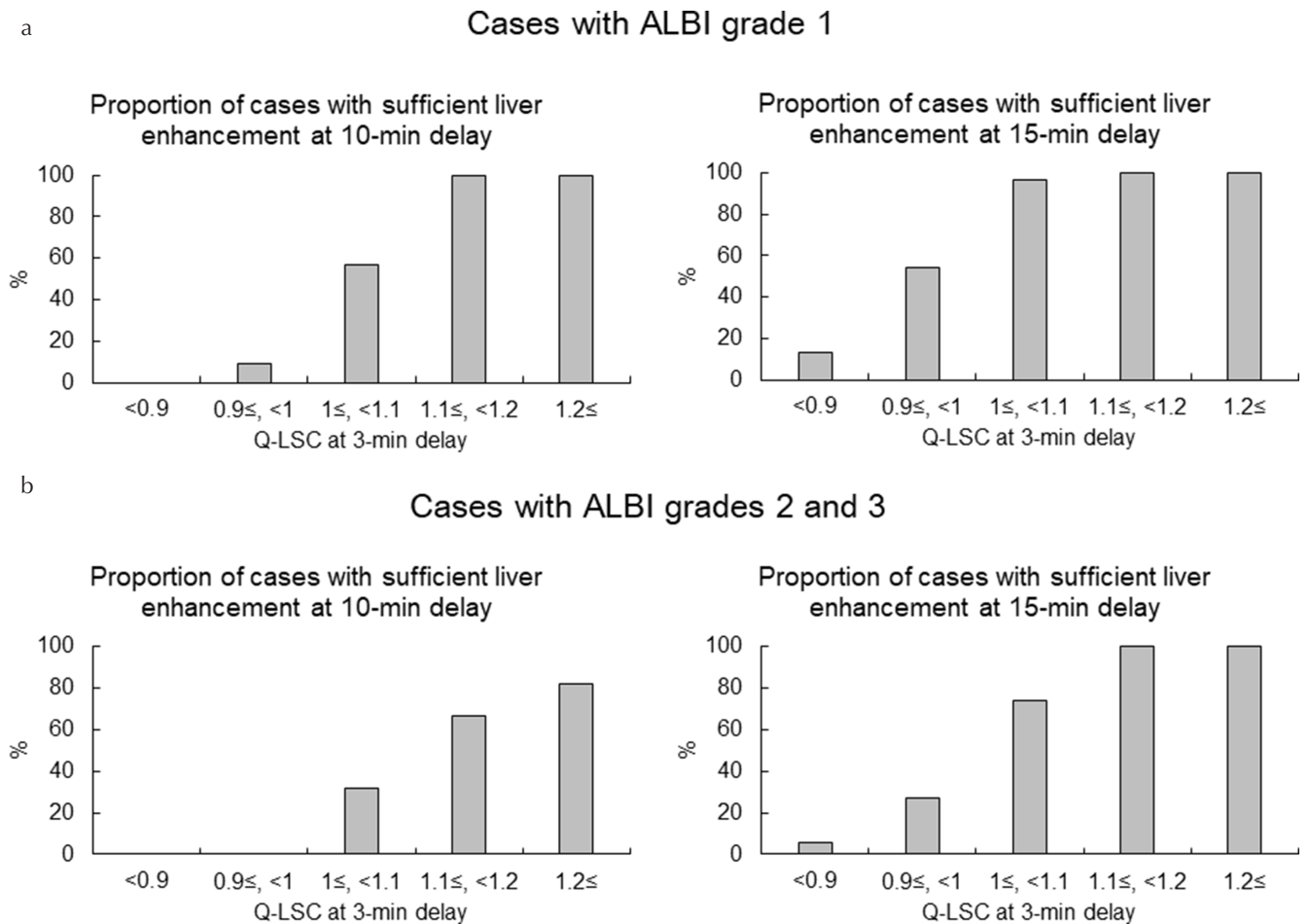


Fig. 4 Proportion of sufficient liver enhancement at 10- and 15-min delays. The proportion of cases with quantitative liver–spleen contrast ratio (Q-LSC) > 1.5 was calculated using Q-LSC of 10- and 15-min images, which were based on the Q-LSC of 3-min delay images that were divided into five groups. Proportion of cases with sufficient liver enhancement at Q-LSC of 10-min delay and 15-min delay of cases with albumin–bilirubin (ALBI) grade 1 (a) and of those with ALBI grades 2 and 3 (b).

Regarding fatigue and throughput, the study should be completed as soon as possible. According to a previous report, when prothrombin activity was at least 86.9%, the delay time could be reduced until HBP.²¹ In the present study, when Q-LSC was ≥ 1.1 at a 3-min delay in patients with ALBI grade 1 and ≥ 1.2 in those with ALBI grades 2 and 3, 100% and 81.8% of patients, respectively, had Q-LSC ≥ 1.5 at a 10-min delay; therefore, the study could be completed at 10 min.

Thus, a well-managed study could be performed with a 3-min delay image based on ALBI grades because the delay time for HBP could be predicted beforehand.

The present study had several limitations. Regarding a delay time to obtain HBP with Q-LSC ≥ 1.5 , we did not evaluate the other liver functions and a common tendency about changing the Gd–EOB–DTPA uptake in HBP instead of the ALBI grade. Therefore, whether our method could be used for other liver functions to confirm if it was influenced by liver function remains unclear. However, using ALBI grade was convenient and suitable in the present study.

When the delay time was extended in patients with ALBI grade 3, Q-LSC may not be > 1.5 because the rate of increase was low, and this needs to be evaluated in further studies. Moreover, we did not evaluate an active membrane transport system, such as organic anion transporting polypeptide.^{2,3} This information could be added to the present study to more accurately decide if the delay time of Q-LSC > 1.5 . However, we considered that predicting the contrast enhancement effect in HBP with 15-min delay images using the 3-min delay image was effective for obtaining a suitable HBP image.

Moreover, a concrete delay time of Q-LSC ≥ 1.5 was not evaluated, and the accuracy of diagnosis was not assessed. Furthermore, although this study showed that the longer the delay time, the higher was the Q-LSC, the usefulness of the super delay phase was not assessed, indicating the need for further studies.

In present study, emphasis should be placed on the predictive value of a 3-min delay image in combination with the ALBI grade for shortening the scan delay time of HBP for performing a smooth and well-managed study.

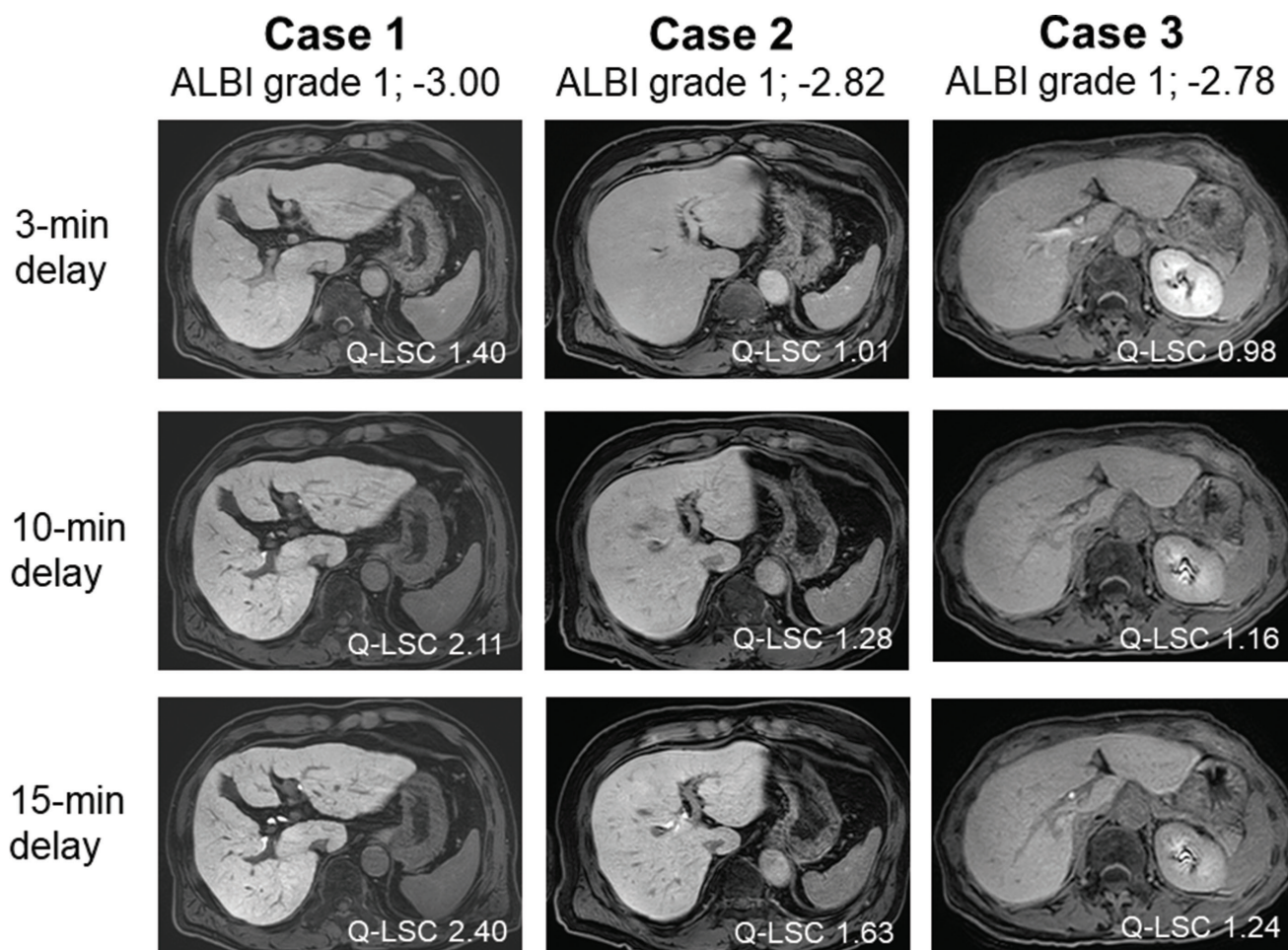


Fig. 5 Sample images. Quantitative liver–spleen contrast ratio (Q-LSC) was >1.5 at 10- (case 1) and 15-min (case 2) delays and <1.5 at a 15-min delay (case 3).

Conclusion

Liver contrast enhancement effect in HBP image could be predicted using a 3-min delay image based on Q-LSC and ALBI grades.

Conflicts of Interest

There are no conflicts of interest to declare.

References

1. Van Beers BE, Grandin C, Pauwels S, et al. Gd-EOB-DTPA enhancement pattern of hepatocellular carcinomas in rats: comparison with Tc-99m-IDA uptake. *J Magn Reson Imaging* 1994; 4:351–354.
2. Narita M, Hatano E, Arizono S, et al. Expression of OATP1B3 determines uptake of Gd-EOB-DTPA in hepatocellular carcinoma. *J Gastroenterol* 2009; 44:793–798.
3. Leonhardt M, Keiser M, Oswald S, et al. Hepatic uptake of the magnetic resonance imaging contrast agent Gd-EOB-DTPA: role of human organic anion transporters. *Drug Metab Dispos* 2010; 38:1024–1028.
4. Higaki A, Tamada T, Sone T, et al. Potential clinical factors affecting hepatobiliary enhancement at Gd-EOB-DTPA-enhanced MR imaging. *Magn Reson Imaging* 2012; 30:689–693.
5. Esterson YB, Flusberg M, Oh S, Mazzariol F, Rozenblit AM, Chernyak V. Improved parenchymal liver enhancement with extended delay on Gd-EOB-DTPA-enhanced MRI in patients with parenchymal liver disease: associated clinical and imaging factors. *Clin Radiol* 2015; 70:723–729.
6. Kim HY, Choi JY, Park CH, et al. Clinical factors predictive of insufficient liver enhancement on the hepatocyte-phase of Gd-EOB-DTPA-enhanced magnetic resonance imaging in patients with liver cirrhosis. *J Gastroenterol* 2013; 48:1180–1187.
7. Motosugi U, Ichikawa T, Sou H, et al. Liver parenchymal enhancement of hepatocyte-phase images in Gd-EOB-DTPA-enhanced MR imaging: which biological markers of the liver function affect the enhancement? *J Magn Reson Imaging* 2009; 30:1042–1046.
8. Takao H, Akai H, Tajima T, et al. MR imaging of the biliary tract with Gd-EOB-DTPA: effect of liver function on signal intensity. *Eur J Radiol* 2011; 77:325–329.

9. Okubo H, Mogami M, Ozaki Y, et al. Liver function test by gadolinium-ethoxybenzyl-diethylenetriamine penta-acetic acid-enhanced magnetic resonance imaging with consideration of intrahepatic regional differences. *Hepatology* 2013; 60:1547–1551.
10. Kamimura K, Fukukura Y, Yoneyama T, et al. Quantitative evaluation of liver function with T_1 relaxation time index on Gd-EOB-DTPA-enhanced MRI: comparison with signal intensity-based indices. *J Magn Reson Imaging* 2014; 40:884–889.
11. Johnson PJ, Berhane S, Kagebayashi C, et al. Assessment of liver function in patients with hepatocellular carcinoma: a new evidence-based approach—the ALBI grade. *J Clin Oncol* 2015; 33:550–558.
12. Chan AW, Chan RC, Wong GL, et al. New simple prognostic score for primary biliary cirrhosis: albumin-bilirubin score. *J Gastroenterol Hepatol* 2015; 30:1391–1396.
13. Amrani B, Achour H, Louhibi S, Tebboune A, Sekkal N. First principles study of ALBI. *Solid State Commun* 2008; 148:59–62.
14. Takatsu Y, Kobayashi S, Miyati T, Shiozaki T. Hepatobiliary phase images using gadolinium-ethoxybenzyl-diethylenetriamine penta-acetic acid-enhanced MRI as an imaging surrogate for the albumin-bilirubin grading system. *Eur J Radiol* 2016; 85:2206–2210.
15. Motosugi U, Ichikawa T, Tominaga L, et al. Delay before the hepatocyte phase of Gd-EOB-DTPA-enhanced MR imaging: is it possible to shorten the examination time? *Eur Radiol* 2009; 19:2623–2629.
16. van Kessel CS, Veldhuis WB, van den Bosch MA, van Leeuwen MS. MR liver imaging with Gd-EOB-DTPA: a delay time of 10 minutes is sufficient for lesion characterisation. *Eur Radiol* 2012; 22:2153–2160.
17. Sofue K, Tsurusaki M, Tokue H, Arai Y, Sugimura K. Gd-EOB-DTPA-enhanced 3.0 T MR imaging: quantitative and qualitative comparison of hepatocyte-phase images obtained 10 min and 20 min after injection for the detection of liver metastases from colorectal carcinoma. *Eur Radiol* 2011; 21:2336–2343.
18. Liang M, Zhao J, Xie B, et al. MR liver imaging with Gd-EOB-DTPA: the need for different delay times of the hepatobiliary phase in patients with different liver function. *Eur J Radiol* 2016; 85:546–552.
19. Deepho C, Watanabe H, Sakamoto J, Kurabayashi T. Mandibular canal visibility using a plain volumetric interpolated breath-hold examination sequence in MRI. *Dentomaxillofac Radiol* 2018; 47:20170245.
20. Park HY, Cho HJ, Kim EM, Hur G, Kim YH, Lee BH. Detection of hepatic lesion: comparison of free-breathing and respiratory-triggered diffusion-weighted MR imaging on 1.5-T MR system. *J Korean Soc Magn Reson Med* 2011; 15:22–31.
21. Okada M, Murakami T, Kuwatsuru R, et al. Biochemical and clinical predictive approach and time point analysis of hepatobiliary phase liver enhancement on Gd-EOB-DTPA-enhanced MR images: a multicenter study. *Radiology* 2016; 281:474–483.