

Novel techniques in scleral buckling

P Mahesh Shanmugam, Rajesh Ramanjulu, K C Divyansh Mishra, Pradeep Sagar

Scleral buckling is a surgical technique that is employed successfully to treat rhegmatogenous retinal detachments (RRD) for more than 60 years. With the introduction of pars plana vitrectomy (PPV), there is a growing trend towards the use of PPV for treatment of retinal detachment. There is a reluctance to perform scleral buckling (SB) in RRD due to the perceived steep learning curve, declining mastery over indirect ophthalmoscopy, and poor ergonomics associated with SB. In this article, we discuss the surgical challenges and tips to overcome these in four headings: localization of the break, retinopexy, SB, and subretinal fluid (SRF) drainage. Localization of the break can be performed by the use of forceps or illuminated scleral depressor. It can be facilitated by prior drainage of SRF in cases with bullous RRD. Chandelier with wide-angle viewing system can be used for easier localization of break and cryopexy. Sutureless buckling and suprachoroidal buckling are easier and faster alternatives to the conventional technique. Reshaping the silicone segment helps in accommodating the wider circumferential band. Modified needle drainage, laser choroidotomy, and infusion-assisted drainage can make SRF drainage easier and safer. The above techniques and other practical tips have been explained in detail with the illustrations to make the process of learning the art of SB easier.

Key words: Retinal detachment, retinopexy, scleral buckling, subretinal fluid drainage

Scleral buckling (SB) is an elegant surgery that enables a surgeon to reattach the retina with a simple extraocular procedure. It is an attractive procedure compared to pars plana vitrectomy, particularly in young patients.^[1] Vitreous substitutes used to tamponade the break are associated with risk of development and progression of cataract.^[2,3] Refractive error induced by the vitreous substitute results in temporary poor vision.^[4-6] SB may induce a small refractive error,^[7] but it has the advantage of an earlier visual rehabilitation.

Despite the obvious advantages, there is a reluctance to learn and perform SB in retinal detachment (RD) due to the perceived steep learning curve, declining mastery over indirect ophthalmoscopy and poor ergonomics associated with the surgery.

We, in this article, describe a few modifications to some of the steps of SB to make them safer, more precise and make the process of learning the art of SB easier.

Localization of the Break

Issues

- Precise localization of the break can be difficult, particularly in bullous RD
- Difficulty in assessing whether the point of scleral depression seen is from the tip of the instrument or the shaft.

Solutions

- The tip of the forceps should be used to depress the ora serrata in the meridian of the break and then gently

eased posteriorly toward the break, under indirect ophthalmoscopic visualization [Fig. 1]

- Chandelier-assisted SB: Using a chandelier and a wide-angle fundus viewing system in lieu of an indirect ophthalmoscope has the advantages of better visualization, familiarity to the predominantly vitrectomy trained surgeons and improved ergonomics. The limitations are the need for additional instruments such as a wide-angle viewing system and chandelier illumination system, making it more expensive and instrument dependent [Fig. 2]^[8]
- Drainage of subretinal fluid (SRF) in bullous RD enables precise localization. However, pigment release and hemorrhage due to hypotony associated with SRF drainage lead to media haze, which may preclude visualization. This can be countered by simultaneous injection of fluid into the vitreous cavity to make up the volume lost by SRF drainage
- A novel technique to improve localization employed by us is to use an illuminated scleral depressor (unpublished data). One can easily create an illuminated scleral depressor out of a 20G light pipe by gently bending its tip. The illuminated tip improves the precision of localization, effectively removing the “shaft indentation” factor. The trans-scleral illumination also allows one to see the break in great detail and also screen doubtful areas effectively [Fig. 3].

This is an open access journal, and articles are distributed under the terms of the Creative Commons Attribution-NonCommercial-ShareAlike 4.0 License, which allows others to remix, tweak, and build upon the work non-commercially, as long as appropriate credit is given and the new creations are licensed under the identical terms.

For reprints contact: reprints@medknow.com

Cite this article as: Shanmugam PM, Ramanjulu R, Mishra KC, Sagar P. Novel techniques in scleral buckling. Indian J Ophthalmol 2018;66:909-15.

Access this article online

Website:
www.ijoo.in

DOI:
10.4103/ijoo.IJO_136_18

Quick Response Code:



Department of Vitreo-Retina and Ocular Oncology, Sankara Eye Hospital, Bengaluru, Karnataka, India

Correspondence to: Dr. Mahesh Shanmugam, Department of Vitreo-Retina and Ocular Oncology, Sankara Eye Hospital, Varthur Road, Kundalahalli Gate, Bengaluru - 560 037, Karnataka, India. E-mail: shanmugam1998@yahoo.com

Manuscript received: 26.01.18; Revision accepted: 21.03.18

Retinopexy

Issues

- Akin to the localization issue, imprecise localization of the cryoprobe tip and false indentation with the shaft can lead to inadvertent posterior cryopexy. Unnecessary and imprecise cryotherapy can result in increased retinal pigment epithelial release and increased risk of proliferative vitreoretinopathy.

Solutions

- Similar to localization of the break, the cryopexy probe should be used to depress the ora serrata and then gently guided posteriorly to the break under indirect ophthalmoscopic visualization [Fig. 4]. Ensuring that the tip is indeed the one in contact with the sclera helps. This can be achieved by ensuring that the direction-indicating knob on the handle of the cryoprobe is always facing away from the surgeon (if the probe has direction indicating knob)
- Chandelier-assisted SB: Similar to localization, chandelier can be used to achieve precise cryopexy [Fig. 5]

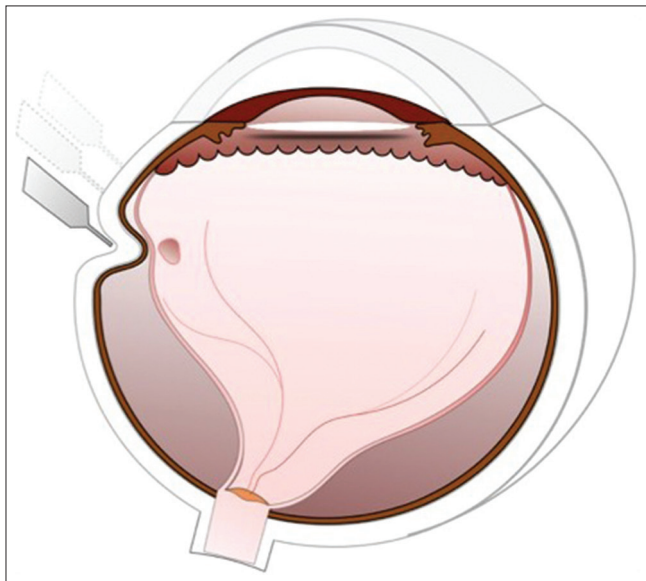


Figure 1: Localization of break with forceps

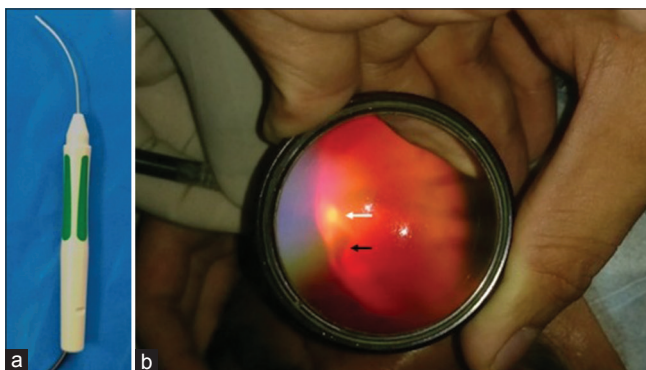


Figure 3: Illuminated scleral indenter. (a) The tip of the light pipe (preferably 20G) is bent. (b) View through 20D lens. The glow of light pipe tip (white arrow) seen on the retina adjacent to the lateral edge of tear (black arrow) by trans-scleral illumination

- Drainage of SRF followed by cryopexy ensures precise retinopexy and less intravitreal release of pigments
- We use an illuminated cryopexy probe to aid precise cryotherapy (unpublished data). An illuminated cryopexy probe can be created (DIY-Do It Yourself), using the light pipe. The handle of a light pipe is removed, and the optical fiber is positioned along the cryoprobe, and both of them are encased in a bit of intravenous tubing [Fig. 6].

Scleral Buckling

Issues

- Deciding the extent and type of explant
- Securing the explant with sutures can be challenging with the risk of inadvertent perforation of the globe. Placing sutures in certain locations such as beneath a muscle can be challenging as well.

Solutions

- Earlier teaching was to support all the lesions in the detached retina with an explant. However, it is not really necessary. Retinal tears should be supported with an explant. Associated lattices and atrophic holes can be

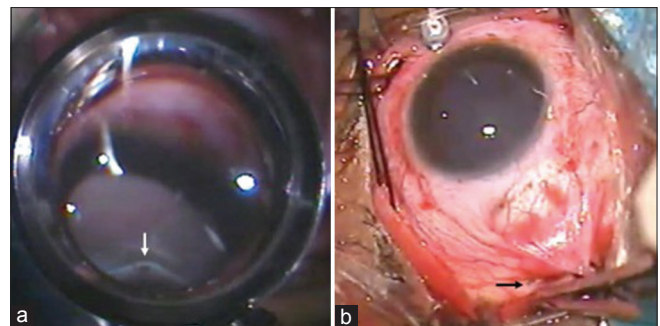


Figure 2: Localization of break in chandelier-assisted surgery. (a) Break is seen (white arrow) at the summit of indent through the wide-angle viewing system. (b) Grey dot on sclera (black arrow) due to indentation by forceps tip corresponding to the break

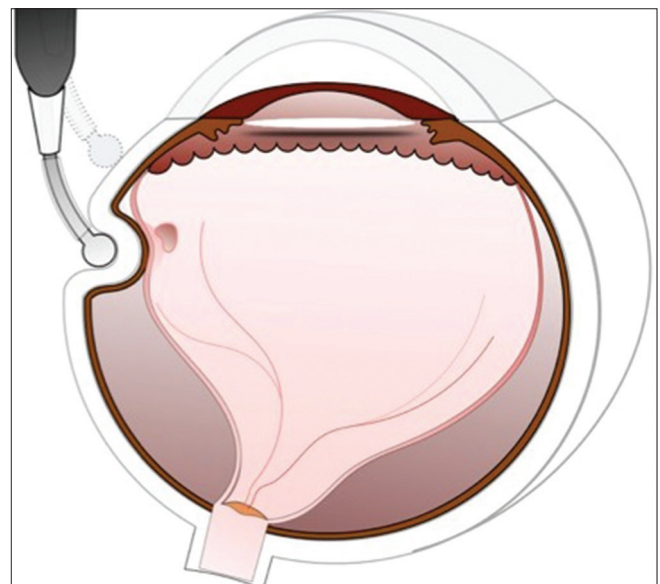


Figure 4: Location of the break with cryoprobe

supported by an encerclage. However, if RD is due to lattice associated atrophic holes, it may be preferable to support the lattice with an explant rather than only with an encerclage. In eyes with 360° lattices and atrophic holes, a broader encerclage (4 mm) alone, placed to support the posterior-most lattice may also suffice. The presence of formed vitreous and absence of extensive posterior vitreous detachment in RD associated with atrophic holes allow one to get away without extensive buckling. In such cases, the formed vitreous tamponades the break even with narrow buckle effect [Fig. 7]

- Sutureless buckling can be performed in most eyes with rhegmatogenous RD. Areas up to 1½ clock hours or ½ a quadrant can be treated with the sutureless technique. More than one explant can also be placed in multiple quadrants in eyes with multiple breaks. Sutureless buckling is simple, fast, and safe [Fig. 8]^[9]
- In eyes with extensive lattices and retinal tear, one can consider using a broader encerclage (4 mm) along with an explant beneath the retinal tear. The 2.5 mm groove in the

explant, meant for the encerclage can be carved using a crescent knife or blade to make it wider to accommodate a 4 mm band. Extending the groove by half the width of the crescent knife on either side can widen it to the necessary width to accommodate 4 mm band [Fig. 9]

- In eyes with a single retinal break, an intrascleral buckle can be placed. A circumferential partial thickness scleral incision is fashioned over the break, and a scleral pocket is created anteriorly and posteriorly to house the silicone segment. The silicone segment is placed in the scleral pocket, and a single suture is used to close the pocket. It is adequate to provide the requisite buckle effect. This is an extremely localized buckle and does not cause much refractive changes. The usual teaching is that the anterior extent of the buckle should reach up to the ora serrata. This is not necessary in most cases. A buckle can be placed posterior to the ora serrata in cases with posterior breaks, but the anterior edge of indent should extend at least 3 mm anterior to the break [Fig. 10]
- Minimal segmental buckling is a fast, simple, effective technique for repair of RD.^[10,11] It is best suited for cases with single break or breaks restricted to few clock hours (ideally <3 clock hours). In this technique, a silicon segment is placed either circumferentially or radially to support all the breaks. Circumferential segment is preferably used

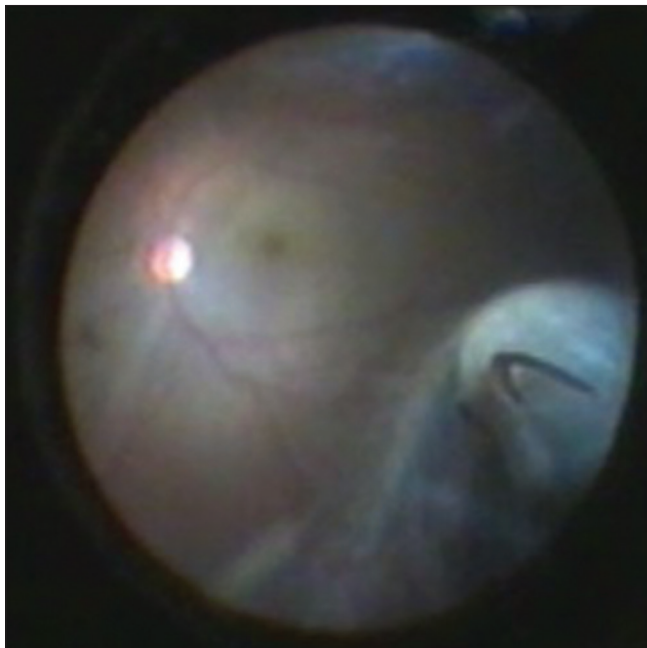

Figure 5: Cryotherapy in chandelier-assisted surgery. Cryo edema is seen around the horse shoe tear through the wide angle viewing system

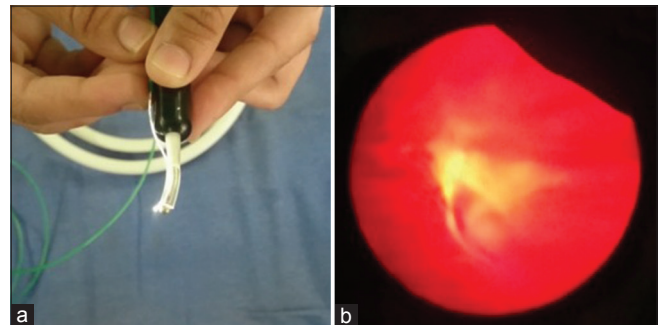


Figure 6: (a) Illuminated cryoprobe. (b) View through 20D lens. Cryo edema around the horse shoe tear. Red glow is due to the illuminated tip

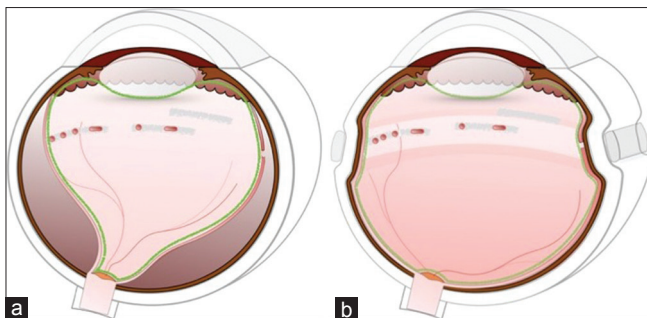

Figure 7: (a) Retinal detachment with multiple lattices with holes and absence of vitreous detachment (green). (b) 4 mm band to support the posterior most lesion. Vitreous plugs the holes and allows retinal reattachment

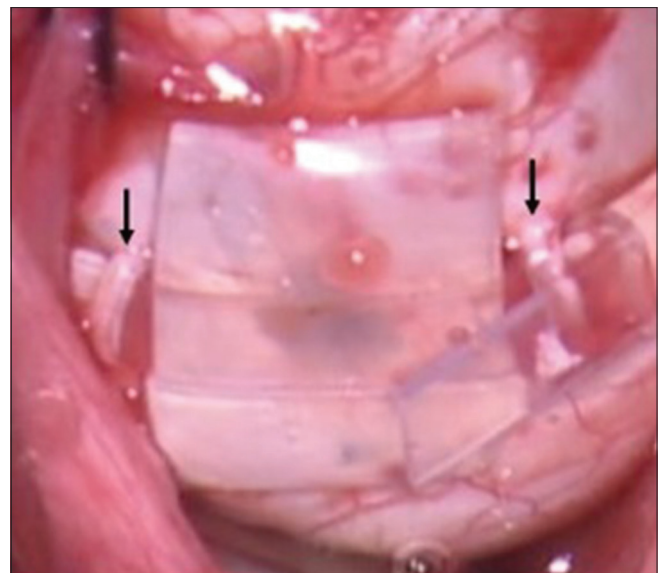


Figure 8: Suture less scleral buckling. Buckle is placed in between the two scleral tunnels (black arrow) and supported by encerclage

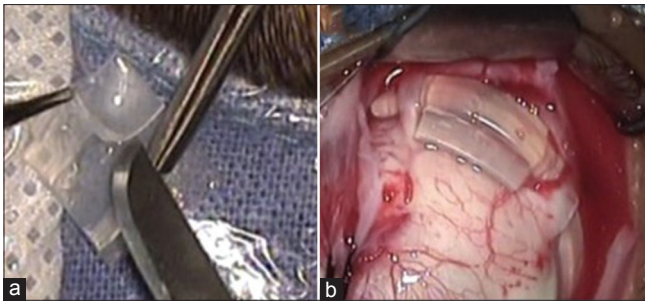


Figure 9: (a) Increasing the width of the groove on the buckle. (b) Suture less buckle placed beneath 4 mm band

in cases with multiple breaks and retinal dialysis. Radial segment is best suited in cases with horseshoe tear. Suture bites are oriented parallel to the limbus for circumferential segments and radially for radial segments. The buckling effect is achieved with sutures. To achieve adequate buckle height, the assistant has to hold the knot between the throws to avoid slippage. It is preferable to use this technique in cases with the absence of other lesions which can predispose to RD in rest of the quadrants. Minimal segmental buckling needs minimal manipulation and may have less postoperative pain

- El Reyes and Elborgy described a technique of threading an illuminated catheter from the pars plana, posteriorly to the break in the suprachoroidal space and injecting long-acting viscoelastic material at the site of break.^[12] This self-absorbing buckle is suprachoroidal and temporary. This can be used to support posterior breaks. In the absence of the specially designed illuminated cannula, we have devised a way to perform suprachoroidal buckling with a regular metal cannula. Once the break is localized, a radial incision is placed at a distance in such a way that the distal part of the cannula can reach the localization mark. The choroid is separated from the sclera gently at the site of sclerotomy by injecting a small quantity of viscoelastic. Then, the cannula is threaded in the suprachoroidal space to reach the mark. A volume of 0.1–0.2 ml of viscoelastic is injected into the suprachoroidal space at the site of break. This provides the adequate buckling effect. Care should be taken to avoid areas close to the vortex vein, as this can result in suprachoroidal hemorrhage [Figs. 11 and 12]
- In cases with posterior break which cannot be supported even by the widest buckle available, the break can be supported by the following technique. Superficial part of the segment anterior to the groove is shaved off [Fig. 13a and b]. This “modified buckle” is placed beneath the other buckle so that the width of the indent can be increased [Fig. 13c]. This method can also be employed in cases with failed buckling when the posterior edge of break is not supported adequately by the buckle. The “modified buckle” can be inserted beneath the preexistent segment to support the posterior edge [Fig. 14a and b].

Subretinal Fluid Drainage

Issues

- Incomplete drainage, dry tap, retinal incarceration, subretinal hemorrhage (hypotony related and otherwise) and retinal break.

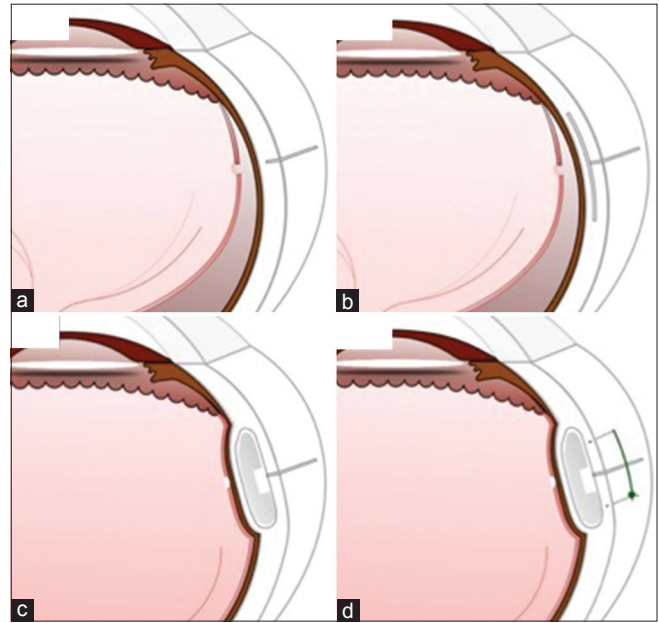


Figure 10: Intrasceral buckle. (a) Circumferential partial thickness scleral incision over the break. (b) Scleral pocket is created anteriorly and posteriorly. (c) The silicone segment is placed in the scleral pocket. (d) Suture is used to close the pocket

Solutions

As many of the above complications are interrelated, techniques to avoid them will be discussed in together.

The traditional cut-down technique of drainage has the risk of

1. Incomplete drainage, if the scleral fibers are not completely dissected to allow prolapse of the choroidal knuckle
2. Retinal and vitreous incarceration due to the large unprotected area of exposure
3. Bleeding as the choroidal vessels are pierced
4. Sudden hypotony due to the copious drainage.

Alternate “safer” techniques of drainage:

- Trans-scleral needle drainage: A 26 gauge ½ inch needle can be used to perforate the sclera to drain the SRF. Advantage of the needle is that the entry site is small making the risk of hemorrhage and incarceration negligible.^[13]

Some of our modifications of needle drainage for safe use are:

- Oblique entry – avoids accidental retinal injury
- The bevel of the needle should face the surgeon during entry – this avoids retinal incarceration as the needle port would be facing the RPE
- After entry – the needle is retracted back partially such that the bevel is retained within the track to keep it open. This would result in near complete drainage [Fig. 15].

Laser choroidotomy

Following a scleral cut-down and prolapse of the choroidal knuckle, an endolaser probe can be used to create the choroidotomy. This would coagulate the choroidal vessels and also avoid iatrogenic retinal damage. This technique is particularly useful in shallow RD and when draining

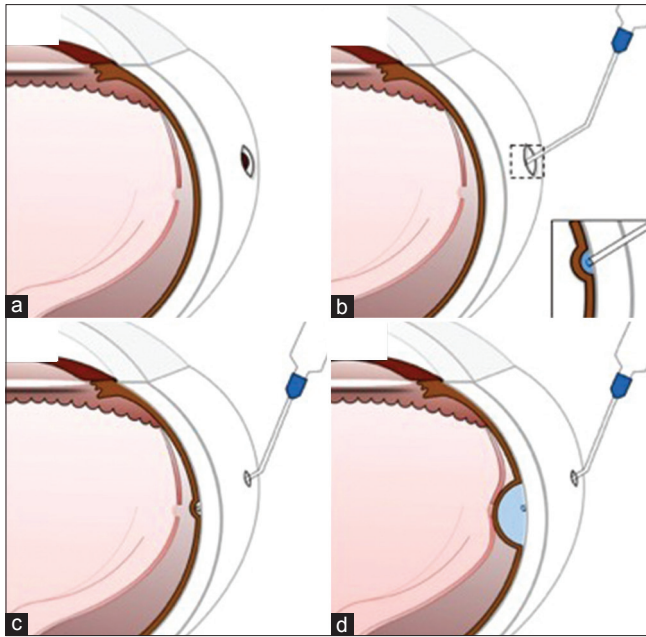


Figure 11: Suprachoroidal buckling. (a) A radial incision is placed at a distance from the localization mark. (b) The choroid is separated gently at the site of sclerotomy by injecting viscoelastic. (c) Cannula is threaded in the suprachoroidal space to reach the mark. (d) Viscoelastic is injected in the suprachoroidal space at the site of break. Laser photocoagulation is performed around the break with laser indirect ophthalmoscope

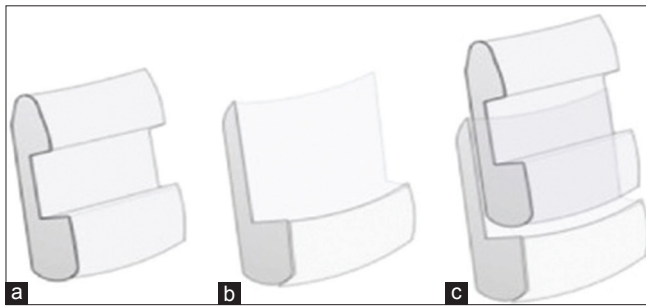


Figure 13: (a) Silicone segment. (b) Superficial part of the segment anterior to the groove is shaved off. (c) The modified buckle is placed beneath another buckle

SRF close to the vortex veins. Laser power of 200–300 mw, duration of 200 ms is used with the probe close to, but not touching the choroidal knuckle to create the choroidotomy [Fig. 16].^[14]

Infusion-assisted drainage

To combat the hypotony during drainage, a 25G infusion can be placed (as in vitrectomy) and turned on during SRF drainage. This would ensure maintenance of intraocular pressure during drainage and also assists in draining. The infusion cannula is placed in the same quadrant as the one selected for drainage. Infusion cannula is placed just before drainage of SRF. For example, if the SRF is to be drained in the inferotemporal quadrant, the infusion cannula is placed 3.5 mm–4 mm from the limbus in the same quadrant. Placement of the cannula in the same quadrant avoids inadvertent kinking of the cannula

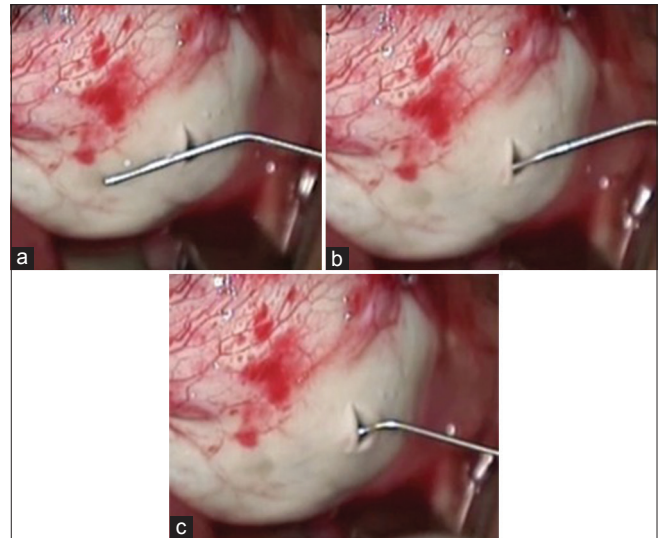


Figure 12: Suprachoroidal buckling. (a) Radial incision made at a distance from the mark so that the tip of metal cannula can reach the mark. (b) Choroid is separated gently at the site of sclerotomy. (c) Cannula is threaded in the suprachoroidal space to reach the mark

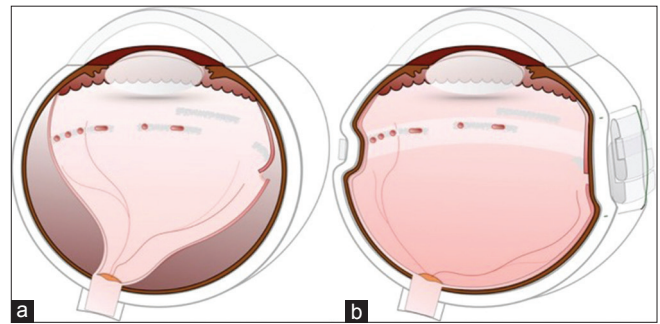


Figure 14: (a) Posterior tear with extensive lattices with holes. (b) Tear supported by the technique described in Figure 13

and lens damage when rotating the eye for visualizing the drainage site [Fig. 17].

Needle drainage under visualization

This is particularly useful in the presence of shifting fluid. Rolling the eye to expose the area of drainage would shift the SRF to the opposite quadrant in the presence of shifting SRF, resulting in a dry tap and retinal injury during drainage. In such cases, a 26G ½ inch needle loaded on to a 2 ml syringe (with plunger removed) can be obliquely inserted into the subretinal space under visualization with indirect ophthalmoscope or with chandelier-assisted visualization. Gently depressing the sclera with the tip of the needle would indicate its position in relation to the area of SRF and the needle can then be guided obliquely through the sclera into the subretinal space. The needle entry into the subretinal space and the drainage process can be visualized, making it a relatively safe process as well.

Some key points are as follows:

- The bevel of the needle should be facing the retinal pigment epithelium to prevent retinal incarceration
- Oblique entry, almost hugging the contour of the globe

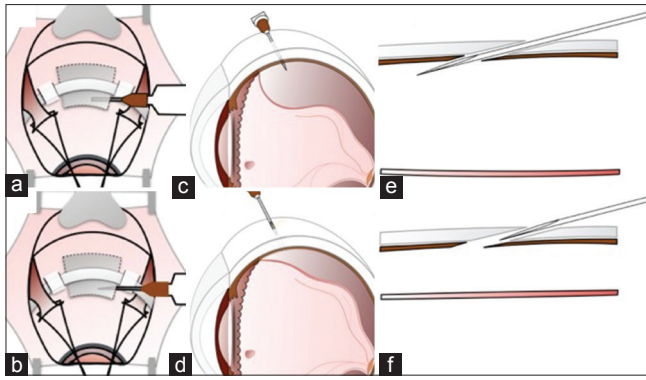


Figure 15: Modifications of needle drainage. (a, c and e) Needle is inserted obliquely with the bevel facing upward (toward the choroid, e). (b, d, and f) Needle is retracted back partially such that the bevel is retained within the track

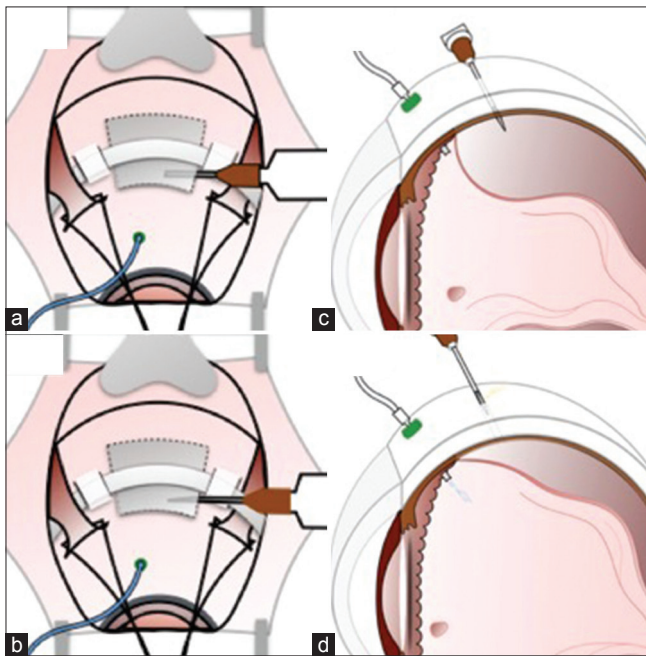


Figure 17: Infusion-assisted drainage in bullous retinal detachment. Infusion cannula is placed in the same quadrant of drainage. (a and c) Needle is inserted obliquely with the bevel facing upwards. (b and d) Needle is retracted back partially. Subretinal fluid starts draining and simultaneous infusion combats hypotony

- Visualization with the indirect ophthalmoscope for drainage has a steep learning curve requiring extensive prior practice on model eyes
- The exit of the needle should be in the same track as that of entry to minimize risk of hemorrhage
- A preplaced infusion cannula can avoid hypotony. Or an assistant can inject the balanced salt solution into the vitreous cavity with a 30G needle attached to a syringe through the pars plana
- The tip of the needle can be slowly angled toward the RPE as the SRF drains and the retina drapes over the needle. The needle is slowly withdrawn as the retina

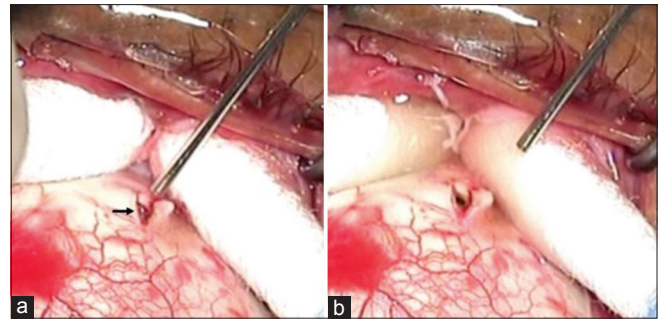


Figure 16: Laser choroidotomy. (a) After the scleral cut down. The aiming beam (red dot indicated by the arrow) of laser from the endolaser probe is directed to the choroid. (b) Successful drainage of subretinal fluid after the laser shot

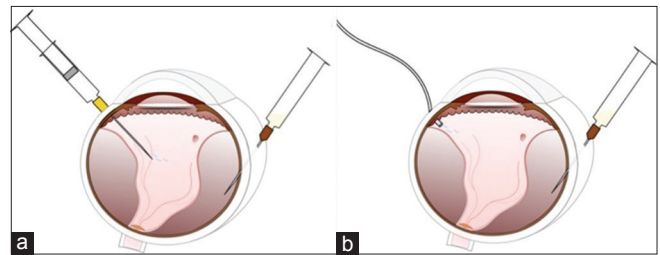


Figure 18: Needle drainage under visualization. 26G needle loaded on to a syringe (with plunger removed) is obliquely inserted in the eye under visualization with indirect ophthalmoscope. (a) Assistant aided injection of balanced salt solution to combat hypotony. (b) Simultaneous infusion to combat hypotony

begins to drape over the needle, thus completing the drainage [Fig. 18].

These small steps can make learning and practicing SB surgery safer, easier, predictable, and rewarding.

Financial support and sponsorship

Nil.

Conflicts of interest

There are no conflicts of interest.

References

1. Park SW, Kwon HJ, Byon IS, Lee JE, Oum BS. Impact of age on scleral buckling surgery for rhegmatogenous retinal detachment. *Korean J Ophthalmol* 2017;31:328-35.
2. Feng H, Adelman RA. Cataract formation following vitreoretinal procedures. *Clin Ophthalmol* 2014;8:1957-65.
3. Blodi BA, Paluska SA. Cataract after vitrectomy in young patients. *Ophthalmology* 1997;104:1092-5.
4. Hotta K, Sugitani A. Refractive changes in silicone oil-filled pseudophakic eyes. *Retina* 2005;25:167-70.
5. Stefánsson E, Anderson MM Jr., Landers MB 3rd, Tiedeman JS, McCuen BW 2nd. Refractive changes from use of silicone oil in vitreous surgery. *Retina* 1988;8:20-3.
6. Stefánsson E, Tiedeman J. Optics of the eye with air or silicone oil. *Retina* 1988;8:10-9.
7. Sharma YR, Karunanithi S, Azad RV, Vohra R, Pal N, Singh DV,

- et al.* Functional and anatomic outcome of scleral buckling versus primary vitrectomy in pseudophakic retinal detachment. *Acta Ophthalmol Scand* 2005;83:293-7.
8. Gogia V, Venkatesh P, Gupta S, Kakkar A, Garg S. Endoilluminator-assisted scleral buckling: Our results. *Indian J Ophthalmol* 2014;62:893-4.
 9. Shanmugam PM, Singh TP, Ramanjulu R, Rodrigues G, Reddy S. Sutureless scleral buckle in the management of rhegmatogenous retinal detachment. *Indian J Ophthalmol* 2015;63:645-8.
 10. Kreissig I. View 1: Minimal segmental buckling without drainage. *Br J Ophthalmol* 2003;87:782-4.
 11. Kreissig I, Rose D, Jost B. Minimized surgery for retinal detachments with segmental buckling and nondrainage. An 11-year follow-up. *Retina* 1992;12:224-31.
 12. El Rayes EN, Elborgy E. Suprachoroidal buckling: Technique and indications. *J Ophthalmic Vis Res* 2013;8:393-9.
 13. Azad R, Kumar A, Sharma YR, Rajpal. Modified needle drainage. A safe and efficient technique of subretinal fluid drainage in scleral buckling procedure. *Indian J Ophthalmol* 2004;52:211-4.
 14. Bovino JA, Marcus DF, Nelsen PT. Argon laser choroidotomy for drainage of subretinal fluid. *Arch Ophthalmol* 1985;103:443-4.