

EARLY CAREER PERSPECTIVE

# Transcatheter Aortic Valve Replacement in the Coronavirus Disease 2019 (COVID-19) Era

Amgad Mentias , MD, MSc; Hani Jneid, MD

**O**n January 20, 2020, the first case of coronavirus disease 2019 (COVID-19), caused by the severe acute respiratory syndrome coronavirus-2, was identified in the United States.<sup>1</sup> Since then, the pandemic has spread across the United States, and as of April 14, 2020, there were 600 000 cases and at least 25 000 deaths. As a result, cardiovascular societies have recommended postponing all nonemergent cardiac procedures.<sup>2</sup> There is no clear consensus on what constitutes elective versus a time-sensitive indication for some cardiac procedures. Transcatheter aortic valve replacement (TAVR) has expanded significantly since its approval in 2011, with >50 000 TAVR procedures done in 2017 and >550 hospitals performing TAVR in 2018. This was projected to further increase with the Food and Drug Administration approval of TAVR for low-risk patients with severe symptomatic aortic stenosis (AS) in 2019.<sup>3</sup> However, the COVID-19 pandemic has raised tremendous challenges and practically brought to a halt the performance of TAVR in many centers in the United States and across the globe, with many hospitals transitioning patient care to telemedicine and virtual encounters. Furthermore, structural heart disease training, which is already fragmented and inconsistent between programs,<sup>4</sup> is markedly affected by the lower number and limited scope of procedures performed in the COVID-19 era. In many institutions, the interventional fellows are providing backup clinical support to clinical cardiology fellows

and critical care physicians in their efforts combatting the COVID-19 outbreak in their local community. This will undoubtedly result in diminished experience and exposure of fellows to structural heart disease procedures, even among those enrolled in the few dedicated structural heart disease training programs in the United States. If the COVID-19 pandemic continues abated, societal guidance is needed to revisit the certification volume requirements and provide alternative means to complement the fellows' training (eg, online didactic and case review sessions, webinars, and simulation programs). Given the COVID-19 outbreak in the United States, the heart team should meticulously deliberate about the risks, benefits, and alternatives of aortic valve replacement (AVR) in patients with severe AS, as well as the best therapeutic strategy (TAVR versus surgical AVR) and its timing. The American College of Cardiology/Society for Cardiovascular Angiography and Interventions released a guidance statement for triaging patients referred for structural heart interventions that describes some scenarios for patients' presentations and recommended management.<sup>5</sup>

The current COVID-19 outbreak in the United States is placing an unparalleled strain and new challenges for the healthcare system in the United States. Therefore, when the heart team discusses whether to perform a TAVR procedure and its timing, 3 basic questions may arise and answers to those may help guide their decision making.

**Key Words:** aortic stenosis ■ COVID-19 ■ transcatheter aortic valve replacement

See Editor's Note in this Issue

Correspondence to: Amgad Mentias, MD, University of Iowa, 200 Hawkins Dr, E315 GH, Iowa City, IA 52242. E-mail: amgad-mentias@uiowa.edu, dr.amgadgamal@gmail.com

For Sources of Funding and Disclosures, see page 4.

© 2020 The Authors. Published on behalf of the American Heart Association, Inc., by Wiley. This is an open access article under the terms of the Creative Commons Attribution-NonCommercial-NoDerivs License, which permits use and distribution in any medium, provided the original work is properly cited, the use is non-commercial and no modifications or adaptations are made.

JAHA is available at: [www.ahajournals.org/journal/jaha](http://www.ahajournals.org/journal/jaha)

## IS THE PATIENT WITH SEVERE AS SEVERELY ILL?

Severe AS results in diminished cardiac output and increased afterload on the left ventricle (LV), resulting in LV remodeling.<sup>6</sup> Patients can remain asymptomatic for a long time, but once symptoms develop, their risk of sudden cardiac death precipitously increases.<sup>7</sup> There is evidence that subclinical LV damage and fibrosis occur even before symptoms develop, with the degree of fibrosis directly associated with outcomes.<sup>6</sup> The small RECOVERY (Randomized Comparison of Early Surgery Versus Conventional Treatment in Very Severe Aortic Stenosis) trial demonstrated a reduction in cardiovascular mortality with early surgical AVR compared with conservative care in asymptomatic patients with severe AS.<sup>8</sup> Although interesting, the findings of the small multicenter RECOVERY trial need to be confirmed in future clinical trials and duplicated using TAVR as the treatment strategy. In the COVID-19 era, we believe TAVR should be predominantly reserved for symptomatic patients with severe AS. Severe AS can present with angina pectoris, heart failure, syncope, or a mixture of these symptoms.<sup>7</sup> Different symptoms portend different prognostic implications. Earlier reports suggested that heart failure symptoms conferred the worse prognosis.<sup>7</sup> More recent reports suggest that syncope is an underestimated symptom that also confers high short- and long-term mortality even after AVR.<sup>9</sup> In addition, TAVR is occasionally performed as a life-saving procedure in a hospitalized critical AS patient with cardiogenic shock or refractory heart failure.<sup>10</sup> On the other hand, angina carries a relatively more benign prognosis and can be attributable to a myriad of factors, such as epicardial coronary artery disease, microvascular dysfunction, high LV wall stress, or increased demand from excessive LV hypertrophy.<sup>11</sup> It is important to obtain a good history and actively probe for any of the aforementioned symptoms. Patients may have difficulty communicating while using telemedicine. They may also deny or delay reporting of their symptoms in the current environment to avoid encounters with the healthcare system and potential hazards of infection.

Overall, we believe that truly asymptomatic patients with severe AS should not undergo TAVR in the current era of florid COVID-19 outbreak. A rare exception may be that of a patient with critical AS who has unrelated limitation to his/her functional capacity, which prevents expression of his/her symptoms. Notably, in the RECOVERY trial, cardiac death in asymptomatic patients with severe AS was significantly reduced by early surgery (within 2 months from randomization), and the survival curves seemed to diverge early in follow-up. The American College of Cardiology/Society for Cardiovascular Angiology and Interventions statement recommends

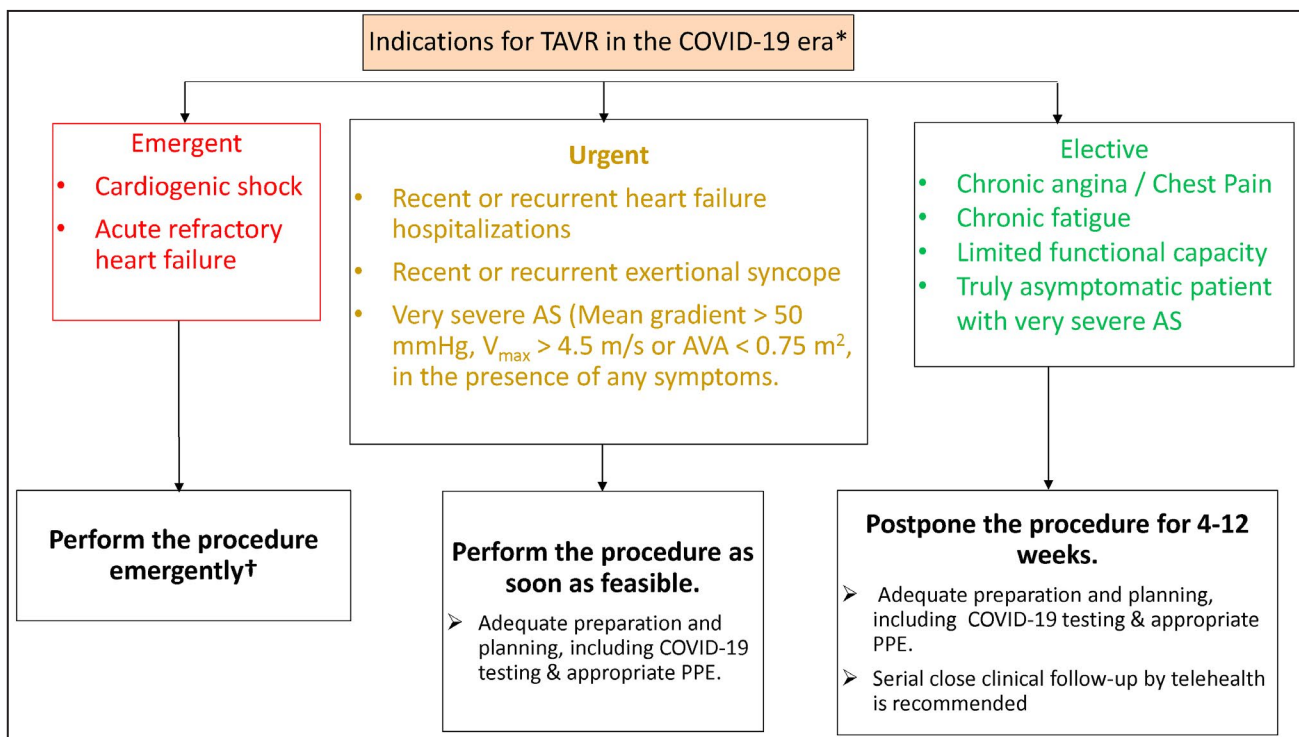
that patients with deferred TAVR procedure should be followed up by telephone calls on a weekly basis to ensure that their symptoms are not worsening.<sup>5</sup> We propose an algorithm that may aid the heart team members in their decision making as they deliberate the timing of a planned TAVR procedure (Figure).

## ARE THERE UNTOWARD RISKS TO PATIENTS UNDERGOING THE TAVR PROCEDURE?

Patients with severe AS who undergo the TAVR procedure are usually elderly individuals, with a significant burden of comorbidities. COVID-19 case fatality rate is highest in elderly individuals and in people with preexisting cardiac disease.<sup>12</sup> Therefore, it is important to recognize the potential risk of a nosocomial COVID-19 infection in a patient who is admitted for the TAVR procedure. Patients who require TAVR may need multiple encounters with the healthcare system before the procedure, for many reasons, including, but not limited to: cardiovascular imaging (eg, echocardiography and computed tomography) to assess the aortic valve and the iliofemoral vessels, outpatient clinic visits with a cardiologist and a surgeon for a shared decision making by the patient and the heart team, and a preprocedural coronary angiogram.<sup>13</sup> To reduce the risk of infection, innovative measures, such as telehealth clinics and virtual visits, should be used. Imaging studies with remote reading capabilities for the staff would be advisable. After the TAVR procedure, patients should be placed in private single rooms, with limited numbers of visitors and with the minimum necessary encounters with healthcare workers. Patients should be discharged as early as possible after the procedure, and efforts should aim to discharge the patient directly to home, instead of a nursing facility or a rehabilitation center.<sup>14</sup>

## ARE THERE RISKS TO HEALTHCARE WORKERS PERFORMING THE TAVR PROCEDURE?

COVID-19 is a contagious disease with high risk of transmissibility. The severe acute respiratory syndrome coronavirus-2 virus can remain viable for up to 3 hours in aerosols and up to 72 hours on plastic and stainless steel surfaces, which could result in aerosol and fomite transmission.<sup>15</sup> Furthermore, recent reports have shown that presymptomatic transmission is possible and was responsible for several clusters of infections worldwide.<sup>16</sup> Actually, recent reports suggest that patients may have the highest risk of transmitting infection before the onset of symptoms. In 18 days after the first COVID-19 case was identified in a long-term care facility in Washington,



**Figure.** Proposed algorithm for timing of a planned transcatheter aortic valve replacement (TAVR) procedure.

\*In case the patient has a severe illness attributable to coronavirus disease 2019 (COVID-19) or other noncardiac conditions, and if no COVID-19 personal protective equipment (PPE) is available in a patient with a definite infection, the heart team and the hospital ethics committee should carefully deliberate the utility and safety of the TAVR procedure, while engaging the patient and family in a process of shared decision making. †As COVID-19 testing is usually not feasible given an emergency situation; all COVID-19 PPE and precautions should be taken, assuming the patient has COVID-19. AS indicates aortic stenosis; AVA, aortic valve area; and  $V_{max}$ , maximum transvalvular flow velocity.

50 healthcare workers became infected.<sup>17</sup> Thus, performing a TAVR procedure in a potential COVID-19 patient poses significant risk to the structural heart team and the ancillary staff. Healthcare workers should be trained in proper infection control measures, including proper placement and removal of personal protective equipment. TAVR patients should be screened before the procedure for any fever, respiratory or constitutional symptoms, or recent sick contacts. If available, and the procedure is not emergent, we recommend screening all patients for potential asymptomatic infection with real-time reverse transcription–polymerase chain reaction test for a nasopharyngeal swab and blood testing for immunoglobulin titers 1 day before the procedure.

## TAVR TECHNICAL AND PROCEDURAL CONSIDERATIONS

The TAVR procedure involves a multidisciplinary heart team approach, often including nurses, a radiology technician, an interventionalist cardiologist, a cardiac surgeon, and an anesthesiologist. Although the American College of Cardiology/Society for Cardiovascular Angiography and Interventions statement affirms that interventional

care provided to TAVR patients should not be compromised,<sup>5</sup> several measures can be placed to ensure the safety of the team and patients. TAVR procedures should be preferably performed in a designated negative pressure catheterization laboratory with an anteroom, or the operating room. The number of ancillary healthcare workers in the room should be minimized, and it is highly advisable to use a minimalist approach with conscious sedation instead of general anesthesia and omission of intraprocedural transesophageal echocardiography guidance (hoping this may reduce the length of stay).<sup>18</sup> If a patient has a critical coronary artery disease, such as left main or proximal left descending artery critical stenosis, that precludes a safe TAVR, we suggest performing the percutaneous coronary intervention in the same setting as the TAVR procedure to minimize the risk of infection, while minimizing contrast use with novel approaches, such as a “contrast-zero TAVR” strategy.<sup>19</sup>

## CONCLUSIONS AND FUTURE DIRECTIONS

There is no doubt that the COVID-19 pandemic represents an unprecedented challenge to cardiovascular

care delivery. However, with prompt recognition of barriers, coordination between team members and specialties, and prudent planning, we can deliver advanced cardiac care, such as TAVR, to patients who need it, in a safe setting without overwhelming the limited available resources. We have proposed an algorithm that can provide guidance to clinicians as they triage and prioritize TAVR procedures in the current COVID-19 era. Our proposed algorithm should be individualized and adapted to the local practice. It should also be viewed as a dynamic algorithm and revised continually, as the availability of resources and the status of the outbreak in the local community change. For those whose TAVR procedures are deferred, it is important to conduct serial virtual clinical follow-up to monitor symptoms and determine future tentative dates for their procedures.

## ARTICLE INFORMATION

### Affiliations

From the Division of Cardiology, Department of Internal Medicine, University of Iowa, Iowa City, IA (A.M.); and Division of Cardiology, Baylor College of Medicine, Houston, TX (H.J.).

### Sources of Funding

Dr Mentias received support from National Institutes of Health National Research Service Award Institutional Grant (T32 HL007121) to the Abboud Cardiovascular Research Center.

### Disclosures

None.

## REFERENCES

- Holshue ML, DeBolt C, Lindquist S, Lofy KH, Wiesman J, Bruce H, Spitters C, Ericson K, Wilkerson S, Tural A, et al. First case of 2019 novel coronavirus in the United States. *N Engl J Med*. 2020;382:929–936.
- Welt FGP, Shah PB, Aronow HD, Bortnick AE, Henry TD, Sherwood MW, Young MN, Davidson LJ, Kadavath S, Mahmud E, et al. Catheterization laboratory considerations during the coronavirus (COVID-19) pandemic: from ACC'S Interventional Council and SCAI. *J Am Coll Cardiol*. 2020;75:2372–2375. [Epub ahead of print].
- Mack MJ, Leon MB, Thourani VH, Makkar R, Kodali SK, Russo M, Kapadia SR, Malaisrie SC, Cohen DJ, Pibarot P, et al. Transcatheter aortic-valve replacement with a balloon-expandable valve in low-risk patients. *N Engl J Med*. 2019;380:1695–1705.
- Kavinsky CJ, Poulin MF, Mack MJ. Training in structural heart disease: call to action. *Circulation*. 2018;138:225–228.
- Shah PB, Welt FGP, Mahmud E, Phillips A, Kleiman NS, Young MN, Sherwood M, Batchelor W, Wang DD, Davidson L, et al. Triage considerations for patients referred for structural heart disease intervention during the coronavirus disease 2019 (COVID-19) pandemic: an ACC/SCAI Consensus Statement. *JACC Cardiovasc Interv*. 2020. DOI: 10.1016/j.jcin.2020.04.001. [Epub ahead of print].
- Treibel TA, Badiani S, Lloyd G, Moon JC. Multimodality imaging markers of adverse myocardial remodeling in aortic stenosis. *JACC Cardiovasc Imaging*. 2019;12:1532–1548.
- Braunwald E. Aortic stenosis: then and now. *Circulation*. 2018;137:2099–2100.
- Kang DH, Park SJ, Lee SA, Lee S, Kim DH, Kim HK, Yun SC, Hong GR, Song JM, Chung CH, et al. Early surgery or conservative care for asymptomatic aortic stenosis. *N Engl J Med*. 2020;382:111–119.
- Gollasch G, Kammerlander AA, Nitsche C, Dona C, Schachner L, Ozturk B, Binder C, Duca F, Aschauer S, Laufer G, et al. Syncope: the underestimated threat in severe aortic stenosis. *JACC Cardiovasc Imaging*. 2019;12:225–232.
- Elbadawi A, Elgendy IY, Mentias A, Saad M, Mohamed AH, Choudhry MW, Ogunbayo GO, Gilani S, Jneid H. Outcomes of urgent versus nonurgent transcatheter aortic valve replacement. *Catheter Cardiovasc Interv*. 2019. DOI: 10.1002/ccd.28563. [Epub ahead of print].
- Gould KL, Carabello BA. Why angina in aortic stenosis with normal coronary arteriograms? *Circulation*. 2003;107:3121–3123.
- Onder G, Rezza G, Brusaferro S. Case-fatality rate and characteristics of patients dying in relation to COVID-19 in Italy. *JAMA*. 2020;323:1775–1776.
- Expert Panel on Cardiac Imaging and Vascular Imaging, Leipsic JA, Blanke P, Hanley M, Battle JC, Bolen MA, Brown RKJ, Desjardins B, Eberhardt RT, Gornik HL, Hurwitz LM, et al. ACR appropriateness criteria(RR) imaging for transcatheter aortic valve replacement. *J Am Coll Radiol*. 2017;14:S449–S455.
- Wood DA, Lauck SB, Cairns JA, Humphries KH, Cook R, Welsh R, Leipsic J, Genereux P, Moss R, Jue J, et al. The Vancouver 3M (Multidisciplinary, Multimodality, but Minimalist) clinical pathway facilitates safe next-day discharge home at low-, medium-, and high-volume transfemoral transcatheter aortic valve replacement centers: the 3M TAVR Study. *JACC Cardiovasc Interv*. 2019;12:459–469.
- van Doremalen N, Bushmaker T, Morris DH, Holbrook MG, Gamble A, Williamson BN, Tamin A, Harcourt JL, Thornburg NJ, Gerber SI, et al. Aerosol and surface stability of SARS-CoV-2 as compared with SARS-CoV-1. *N Engl J Med*. 2020;382:1564–1567.
- Wei WE, Li Z, Chiew CJ, Yong SE, Toh MP, Lee VJ. Presymptomatic transmission of SARS-CoV-2—Singapore, January 23–March 16, 2020. *MMWR Morb Mortal Wkly Rep*. 2020;69:411–415.
- McMichael TM, Currie DW, Clark S, Pogojans S, Kay M, Schwartz NG, Lewis J, Baer A, Kawakami V, Lukoff MD, et al. Epidemiology of COVID-19 in a long-term care facility in King County, Washington. *N Engl J Med*. 2020. DOI: 10.1056/NEJMoa2005412. [Epub ahead of print].
- Attinger-Toller A, Htun NM, Murdoch D, Perlman GY, Alenezi A, Sathananthan J, Blanke P, Leipsic J, Thompson C, Ye J, et al. Transcatheter aortic valve-in-valve implantation for failed surgical bioprosthetic valves: a minimalist approach without contrast aortography or echocardiographic guidance. *Catheter Cardiovasc Interv*. 2020;95:45–53.
- Castriota F, Nerla R, Micari A, Squeri A, Cremonesi A. Contrast-zero transcatheter aortic valve replacement for patients with severe renal dysfunction: a single-center experience. *JACC Cardiovasc Interv*. 2018;11:820–822.