

What are the benefits of the anti-FGF23 antibody burosumab on the manifestations of X-linked hypophosphatemia in adults in comparison with conventional therapy? A review

Marie-Hélène Lafage-Proust 

Abstract

X-linked hypophosphatemia (XLH) is a genetic disease mostly related to PHEX gene mutations which increases FGF23 serum levels, leading to hypophosphatemia and osteomalacia in adults, while affected children, in addition, develop rickets. Most of adults with XLH suffer from reduced quality of life and physical disability due to chronic bone and joint pain related to limb deformities, early osteoarthritis, delayed-healing of insufficiency fractures, and enthesopathies. Dental infections, muscle dysfunction, and deafness are also frequent. The current treatment consists of 2–5 times daily oral administration of phosphate combined to active vitamin D, often badly tolerated with immediate digestive side effects, responsible for poor compliance. In the long term, it may induce nephrocalcinosis and hyperparathyroidism. Burosumab, an anti-FGF23 blocking antibody, was approved for treating children with XLH in many countries. A randomized 24-week-long placebo-controlled trial, followed by an open-label period of equal duration was conducted in 134 XLH adults treated with 1 mg/kg burosumab/4 weeks. During burosumab treatment, 94% of the patients normalized serum phosphate values *versus* 7% in the placebo group. Fracture healing was increased 16.7 times compared with placebo-treated patients. All pain and disability tests improved significantly in a time-dependent manner. Burosumab for 48 weeks improved histological lesions of osteomalacia in a single-arm longitudinal study analyzing paired bone biopsies. Another single-arm, open-label study investigated the long-term safety and efficacy of burosumab in 20 adult patients followed for 3.2 years. Burosumab was beneficial on pain and disability scores and on bone remodeling markers. No major side effects especially no hyperphosphatemic episodes were reported. Overall, the benefit/risk ratio of burosumab is positive in adult patients with clinical and/or biological complications of XLH. Burosumab corrects hypophosphatemia, promotes fracture healing, and induces a modest but significant effect on XLH-induced subjective pain and disability symptoms.

Ther Adv Rare Dis

2022, Vol. 3: 1–10

DOI: 10.1177/
26330040211074702

© The Author(s), 2022.
Article reuse guidelines:
[sagepub.com/journals-
permissions](https://sagepub.com/journals-permissions)

Plain language title and summary

Effects of conventional treatment and burosumab in adults with X-linked hypophosphatemia.

X-linked hypophosphatemia (XLH) is a disease of genetic origin that affects mineralized tissues (skeleton and teeth) and impairs muscle function. It induces a decrease in blood phosphate levels. This leads to under mineralization of bones and insufficiency fractures

Correspondence to:
Marie-Hélène Lafage Proust
SAINBIOSE, INSERM
U1059, Université Jean
Monnet, CHU Saint-
Etienne, F-42055 Saint-
Etienne, France.
[mh.lafage.proust@univ-
st-etienne.fr](mailto:mh.lafage.proust@univ-st-etienne.fr)

that heal slowly, associated with poor dental health characterized by spontaneous dental abscesses. Adults with XLH suffer from chronic pain and limb deformities that alter their quality of life. They are currently treated with daily administration of vitamin D and several daily doses of phosphate. This treatment may induce parathyroid gland dysfunction and mineral deposits in the kidney. If not tightly monitored, these side effects may lead to tertiary hyperparathyroidism and the need for parathyroid gland surgery, or to nephrocalcinosis which may proceed to chronic kidney disease. Burosumab is an antibody that blocks the action of FGF23 the factor that circulates in excess in blood and is responsible for phosphate renal leak in XLH. Three studies demonstrated that burosumab, injected every 4 weeks, is efficient and safe for treating adults with XLH.

Keywords: adults, burosumab, FGF23, hypophosphatemia

Received: 25 June 2021; revised manuscript accepted: 3 January 2022.

Introduction

X-linked hypophosphatemia (XLH) has a prevalence of approximately 1:20,000 births.¹ It is a genetic disease linked to an inactivating mutation of the gene *PHEX* (phosphate-regulating gene with homologies to endopeptidases on the X chromosome) in the majority of the cases. The *PHEX* mutation leads to compromised function of the *PHEX* protein, which results in high serum levels of FGF23 (fibroblast growth factor 23), a hormone secreted by late osteoblasts and osteocytes in bone. The precise regulation of FGF23 by *PHEX* remains poorly understood^{2,3} (Figure 1). FGF23 decreases renal tubular phosphate reabsorption (TmP/GFR) by inhibiting the expression of the sodium/phosphate co-transporters, NaPi2a and NaPi2c, at the apical membrane of renal proximal tubule epithelial cells. This leads to excessive urinary phosphate excretion and hypophosphatemia. The second renal role of FGF23 is to inhibit CYP27B1, a α 1-hydroxylase which transforms 25-OH cholecalciferol into calcitriol, the active form of vitamin D, and to activate CYP24A1, a 24-hydroxylase inactivating vitamin D. Therefore, low to inappropriately normal levels of 1,25(OH)₂D are present, the hypophosphatemia taken into account, and are a major feature of XLH (Figure 1). Mutations in other genes may also lead to hypophosphatemic rickets, not linked to the X chromosome, including those involved in the posttranslational regulation of FGF23 expression, illustrated in Figure 1. In adults as well as in children, low phosphate serum levels combined to inappropriate levels of 1,25(OH)₂D and other

mechanisms that are still being investigated⁴ contribute to a defect in bone mineralization, namely osteomalacia.

The aim of this review was to confront literature data about conventional and recent treatments of XLH in adults. We summarized the clinical features of XLH in adults. We recapitulated the scarce information related to the effects of oral phosphate and vitamin D, the reference treatment until the advent of burosumab, an anti-FGF23 antibody. Then, we made a systematic review of the clinical studies evaluating the effects of burosumab administration in XLH adults, via PubMed (keyword: adults, XLH, clinical trial) and clinicaltrials.gov, as well as the burosumab Assessment Report available on the of the European Medicine Agency website.

Symptoms in adults

A majority of adult XLH patients report reduced quality of life⁵ due to pain, physical disability with abnormal gait, and global fatigue.⁶ However, some adult patients have been reported as asymptomatic⁷ while their serum parameters or bone histology did not differ from symptomatic patients.

Symptoms experienced by patients. In treated patients, side effects from conventional treatment may also appear⁸ (see paragraph 3). Various musculoskeletal disorders are described. Adults have a short stature⁹ (♀ ~ -5% and ♂ ~ -8% versus healthy subjects) even if they received a conventional

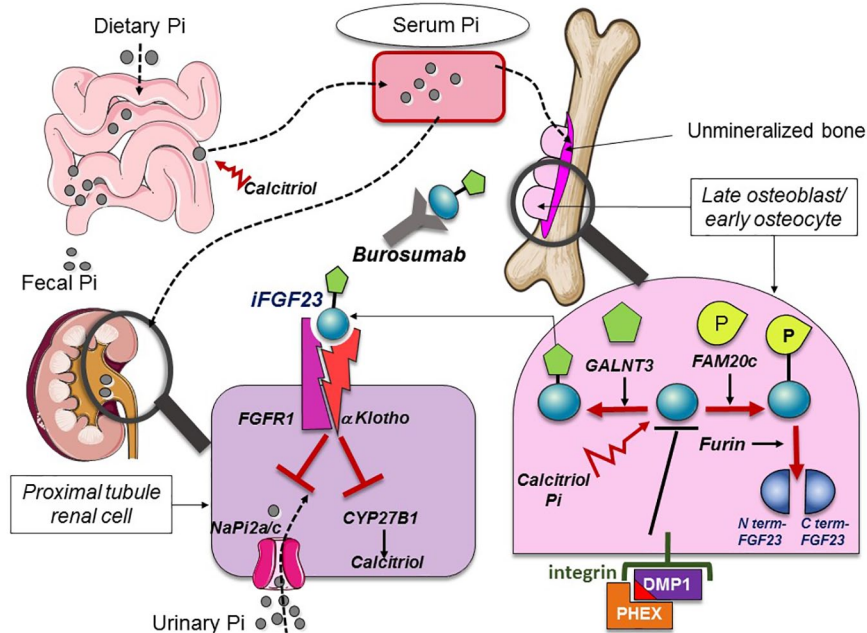


Figure 1. Summary of phosphate and FGF23 metabolism. Serum phosphate levels depend on dietary phosphate intake and intestinal absorption and on renal urine excretion. Serum phosphate is essential for bone mineralization. FGF23 (blue circle) is a hormone synthesized by early osteocytes and late osteoblasts in bone. Its expression is stimulated by vitamin D [calcitriol] and phosphate dietary load and is inhibited by DMP1, an extracellular matrix protein. Binding of DMP1 to PHEX via an ASARM (acidic serine- and aspartate-rich MEPE-associated) motif (red triangle) and to an integrin results in downregulation of FGF23 expression. FGF23 undergoes posttranslational modifications that condition its biological activity. When glycosylated (green pentagon) by GALNT3, it remains intact (iFGF23), circulates, and binds to the FGFR1 receptor and α -klotho, its coreceptor, in epithelial renal cells. This leads to the withdrawal of the sodium/phosphate transporters NaPi2a/c from the renal epithelial cell membrane, inducing a leak of urinary phosphate. FGF23 also exerts anti-vitamin D effects via inhibition of CYP27B1, a 1α -hydroxylase which activates the synthesis of calcitriol and upregulation of 24-hydroxylase that promotes calcitriol destruction (not shown). When phosphorylated by FAM20c, FGF23 is cleaved by a furin leading to the release of N and C-terminal fragments. PHEX mutations are responsible for the majority of X-linked hypophosphatemia, whereas mutations of FAM20 C, DMP1, or FGF23 lead to other forms of hypophosphatemic rickets. Burosumab is a blocking anti-FGF23 antibody that prevents FGF23 binding to the FGFR1/Klotho receptor.

treatment during their childhood. Osteomalacia is constant but of variable severity¹⁰ and may induce pseudofractures or fractures (reported by 50–60% of the patients^{5,11}) that consolidate poorly. There is no increase but rather a decrease in the risk of low trauma fractures such as those seen in primary osteoporosis, in XLH adults, as reported by Beck-Nielsen *et al.*¹²

Patients present with diffuse bone and joint pain (~60%)⁵ and 30–67% of the patients take analgesics or nonsteroidal anti-inflammatory drugs (NSAIDs).⁵ Lower limb deformities such as bending, acquired during growth, include coxa vara, genu varum, and valgum. They promote the early onset of osteoarthritis, often before the age of 30,¹³ requiring osteotomies and then prosthetic

replacement.¹⁴ Proximal muscle weakness¹⁵ is often observed in adults and reduces walking ability. An increase in birth deliveries by cesarean section compared with healthy controls is mentioned in some reports in XLH females¹⁰ (76% in a cohort of 40 adult females with XLH *versus* 27% in the general UK population⁹) but not in others.^{5,6,7,11,12}

In adults, the disease also specifically induces ossification of the entheses,¹⁶ most often, but not exclusively, located at the pelvis and the spine, which can lead to joint stiffness and pain and may lead to stenosis of the lumbar or cervical canal (2% to 19% of patients)^{13,17} sometimes requiring decompressive surgery. Optic atrophy¹⁸ and deafness¹⁹ (~15%) related to hyperostosis of the skull base are reported. Dental involvement is common (90–60%)²⁰ and is

specifically characterized by endodontic dental infections associated with an increased risk of periodontitis. XLH disrupts not only the formation of alveolar bone and dentin but also of the cementum and is associated with a constitutional defect of the dental attachment apparatus.²¹ The radiological signs of XLH in adults intensify with age;²² however, there are no reports in the literature dedicated to populations of elderly (>65 years) XLH patients.

XLH patients often complain of fatigue after physical exertion even if it is mild. Their muscle strength is objectively lower than that of control subjects while their muscle size is normal.²³ Hyp mice, the preclinical model of XLH, which have a PHEX mutation and reproduce the major features of XLH, exhibit lower grip strength which is significantly improved by the administration of FGF23 blocking antibodies.²⁴ Recent data suggest that rates of insulin-stimulated myocyte ATP flux are severely reduced in hypophosphatemic mice. Moreover, ATP synthetic flux correlated directly with cellular and mitochondrial phosphate uptake in two rodent myocyte cell lines, as well as in freshly isolated myocyte mitochondria.²⁵ This suggests that reduced muscle ATP flux may underlie the myopathy seen in patients with XLH.

While it has been shown that increases in FGF23 serum levels are linked to ventricular hypertrophy in hyperphosphatemic patients with chronic kidney disease (CKD), the potential effects of FGF23 excess on the cardiac function of XLH patients remain poorly documented. Hyp mice do not exhibit ventricular hypertrophy.²⁶ However, a recent study of 24 XLH pediatric patients receiving conventional treatment found that they have echocardiographic measurements of ventricular mass within normal reference values, albeit above the mean, and 18% have left ventricular mass index suggestive of left ventricular hypertrophy.²⁷ However, Takashi *et al.*²⁸ did not find ventricular hypertrophy in 23 XLH patients aged 17 to 76 years. In addition, one third of XLH young patients receiving conventional therapy have been shown to be overweight or obese.²⁹ The pathophysiological relationships between the excess of FGF23 and this metabolic profile remain obscure.³⁰ Again, we do not know whether some adults with XLH retain this trait except that two thirds of the patients included in the pivotal burosumab studies conducted on adults were overweight.³¹

Current therapeutic strategy

According to international recommendations, conventional treatment in symptomatic adults combines oral administration of phosphate (750–1600 mg) in two to four daily doses to α 1-hydroxylated derivatives of vitamin D (0.50–0.75 μ g/d for calcitriol and 0.75–1.5 μ g/d for alfacalcidol).^{32,33} The aim of this treatment is to compensate for the relative deficit in active vitamin D and increase the intestinal absorption of phosphate. If started early in childhood, treatment with phosphate and vitamin D, that was first proposed in the 1960s,³⁴ can minimize the later consequences of rickets and the reduction in height achieved in adulthood. In contrast, there is little evidence to support the notion that initiating or maintaining treatment in adults improves outcomes.³² Shanbhogue *et al.* followed for 6 years a group of 27 XLH adult patients, including 16 untreated patients and 11 patients treated with phosphate and active vitamin D. They did not find any difference between baseline and follow-up values in terms of serum levels of calcium, phosphate, PTH, or FGF23, regardless of the treatment group. Interestingly, they found that serum CTX increased with time in the treated group only, while they did not observe any significant changes in BMD measured by DXA in either group.³⁵ Only one prospective noncontrolled, nonrandomized study evaluated the effects of this treatment on clinical symptoms and blood test parameters as well as on bone histology, in 16 adult patients (mean age 37) over a 4.2-year period. Eighty-seven percent reported lower bone pain under treatment.³⁶ Serum phosphate increased and alkaline phosphatase decreased, whereas PTH and creatinine levels remain stable. Treatment reduced the histological signs of osteomalacia but did not fully restore bone mineralization. In an observational and cross-sectional study of 52 XHL patients older than 18 years, Connor *et al.* analyzed radiographic and dental outcomes according to the proportion of adult life with treatment. Forty-seven percent of those patients treated throughout all of adult life had severe dental disease, whereas 75% of those with no treatment during adult life were severely affected.³⁷ Che *et al.*⁵ reported that current treatment with phosphate supplements and vitamin D in 53 XLH adults was significantly associated with a better self-evaluating health score (SF36). Active vitamin D and phosphate administration increases serum concentration of intact FGF23 in XLH patients³⁸ by stimulating its synthesis by bone

(Figure 1). This treatment may lead to peaks of hyperphosphatemia or induce episodes of hypercalcemia and hypercalciuria related to the increased intestinal absorption of dietary calcium. As a consequence, urinary lithiasis or nephrocalcinosis (40%)³⁹ may occur potentially followed by renal failure, the prevalence, and natural course of which is not well known in adults.⁴⁰ This treatment may aggravate pre-existing secondary hyperparathyroidism (~85% of patients) which amplifies urinary phosphate leakage.⁴¹ In addition, secondary hyperparathyroidism may evolve into tertiary hyperparathyroidism,⁴² requiring parathyroid surgery.^{43,44} Phosphate oral intake also induces digestive disorders such as nausea, vomiting, and abdominal pain in a dose-dependent manner. These side effects together with the need to take the treatment several times a day are a substantial hurdle to optimal patient compliance. The risk of phosphate intake is not so much acute severe hyperphosphatemia, as repeated episodes of moderate hyperphosphatemia, the long-term cardiovascular toxicity of which has been reported in the general populations even in CKD-free subjects.⁴⁵ Cinacalcet (a calcium receptor agonist) has been shown to minimize the blood test parameters associated with secondary hyperparathyroidism in XLH patients. However, it is rarely used in routine practice in XLH because its off-label use is not recommended.⁴⁶ Conventional management also consists of symptomatic treatment of bone and joint pain with analgesics, NSAIDs, intra-articular, peritendinous or epidural infiltrations, regular physiotherapy, orthopedic or neurosurgical treatment of joint complications, as well as dental and nephrological follow-up.

Summary of studies evaluating burosumab in adults

Burosumab (KRN23, Crysivita™) is an IgG1 monoclonal human antibody which blocks the action of circulating FGF23. It binds the N-terminal domain of FGF23 that interacts with the binding portion of the receptor FGFR1, associated with its co-receptor Klotho, thus preventing FGF23 canonical signaling (Figure 1). It rescues the bone phenotype in Hyp mice and has been approved in many countries worldwide for the treatment of children with XLH over the last 5 years. Burosumab pharmacokinetics and efficacy on biological features of XLH were first tested in adults.^{31,47,48} A randomized, double-blind, placebo-controlled (phosphate and vitamin

D supplements stopped) study⁴⁹ (CL303) analyzed 134 adult patients (mean age 40 years, range: 19–66 years, 46 males) with HLX. The inclusion criteria were phosphate renal leak, pain score higher than 4, absence of renal insufficiency or tertiary hyperparathyroidism. They were treated with burosumab (1 mg/kg/4 weeks, Max 90 mg/injection) or placebo for 24 weeks followed by a 24-week open-label period during which all patients received burosumab.⁵⁰ The primary endpoint was the percentage of patients who had normalized blood phosphorus levels between two doses over the 24 weeks. The secondary endpoints were pain and functional ability scores evaluating the most severe pain, the Brief Pain Inventory (BPI), stiffness, and physical function (Western Ontario and McMaster Universities Osteoarthritis Index, WOMAC). The exploratory criteria included fracture and pseudofracture healing, enthesopathies, 6-minute walking test, and scores for pain (BPI) or most intense and total fatigue (BFI). The percentage of patients who normalized serum phosphorus levels was 7.6% (confidence interval [CI]: 3.3–16.5) versus 94.1% (CI: 85.8–97.7) in the placebo and burosumab groups, respectively, $p < 0.0001$. At baseline, nearly one in two patients had fractures and pseudofractures, and the odds ratio of healing a fracture was 16.7 (4.9–56.9) for burosumab, $p < 0.0001$. New fracture was reported in one patient in the burosumab group and in two patients in the control group. At week 24, the stiffness score was significantly lower and the improvement in walking distance was better in the burosumab group than in controls, the other scores for pain and functional ability being not significantly different between the two groups. All tests improved significantly at the end of the study compared with baseline, and the decrease in symptoms was time-dependent. Overall, the parameters studied changed in the same way between the controlled (weeks 0–24) and open-label (weeks 24–48) treatment periods.

Study CL 203 was a single-arm, open-label study designed to investigate the long-term safety and efficacy of burosumab based on biological and pain and functional ability scores. Twenty patients who participated in one of the two phase I/II studies KRN23-INT-001 or KRN23-INT-002 were included and followed for a total duration of 154 to 184 weeks (mean duration: 3.17 years). The last dose of burosumab had been given at least 21 months before inclusion. The titration period was 12 weeks to determine the dose able to normalize

phosphatemia. Only one patient discontinued the study at 72 weeks. Serum phosphate values, when measured just between two doses, were normal in most subjects, whereas the proportion of normophosphatemic patients decreased to 45–74% when measurements were performed just before the following dose. TmP/GFR remained significantly higher than at baseline under treatment throughout the study. Burosumab transiently increased serum calcitriol concentrations (week 24), circulating PTH decreased significantly at week 72, compared with baseline and remained moderately elevated up to week 144. FGF23 serum concentrations increased under treatment. Burosumab induced a beneficial effect on bone remodeling markers with a transient increase in bone resorption (C-terminal telopeptide of type 1 collagen, CTX) and formation (N-terminal propeptide of type 1 pro-collagen, P1NP), up to weeks 72 and 96, respectively. The decrease in serum alkaline phosphatase reflected the improvement of bone mineralization. Assessment of pain, stiffness, and physical function showed significant and sustained improvement from baseline throughout the follow-up (WOMAC, BPI-SF, and SF-36v2), which reduced the impact of symptoms on daily life.⁵¹ On the one hand, this study was methodologically overall well conducted. On the other hand, a number of secondary endpoints were changed during the study and there was an erroneous stratification according to the initial pain, leading to an imbalance in pain intensity between the two arms of the study, which may have influenced the results concerning the pain and physical ability scores.

The open-label study CL304⁵² analyzed the evolution of bone histology on paired iliac crest biopsies before and after 48 weeks of burosumab treatment (without phosphate and vitamin D) in adult patients (mean age: 40 years, 25–52 years, six males) with XLH. Patients with a pain score higher than 4, evidence of histological osteomalacia on the first biopsy (accumulation of osteoid tissue due to lack of mineralization), and who had stopped conventional treatment for at least 2 years were included. Paired bone biopsies with quantitative histomorphometric analysis are the gold standard for histological bone remodeling and mineralization assessment. Nine pairs of biopsies were available at 48 weeks and 11 in total at 56 weeks. Static parameters defining osteomalacia decreased significantly under treatment: osteoid volume from 26% to 12% (primary endpoint), osteoid thickness from 17.2 to 11.6 μm , osteoid surface area from 92% to 26%. The mineralization lag time, which

characterizes the delay between bone apposition and mineralization, decreased by 83% (median). Only 1 patient had severe osteomalacia at the end of the study and 10 retained a moderate form. At 48 weeks, the biomarkers of bone remodeling (serum P1NP and CTX) were significantly increased (77% and 36%, respectively). It would have been interesting to mention the evolution of the various parameters at the individual level to better detect subgroups of highly or poorly responsive patients.

Comments and discussion

Validity and efficacy

Overall, one can conclude that these studies evaluating burosumab are methodologically sound. The decision not to conduct a study comparing the efficacy and safety of burosumab to conventional treatment is questionable. It can be justified by the fact that conventional treatment has not been evaluated in controlled studies, is not administered to all adult XLH patients and may induce side effects such as nephrocalcinosis which, in the long term, can lead to renal failure, one of the most severe complications described in the course of the disease. Burosumab exerts sustained significant efficacy on the biological parameters characterizing XLH phosphate renal leak and its consequences on skeletal mineralization disorders, including fractures/pseudofractures and related symptoms in clinically relevant proportions. However, no conclusions can be drawn regarding the effect of burosumab on dental damage or the clinical consequences of enthesopathy. The primary endpoints (correction of hypophosphatemia or histological evidence of osteomalacia) were relevant to the mode of action of the drug. They reflect the direct consequences of excess of circulating FGF23, but do not necessarily correlate with subjective clinical pain and physical ability endpoints. A study with a more clinically relevant primary endpoint in adults should be planned. Of note, the pain and impairment of physical ability are the result of both disorders potentially modifiable by burosumab, such as bone pain due to fractures or muscle symptoms, and irreversible complications namely osteoarthritis, or enthesopathies. The level of evidence for the efficacy of burosumab on pain and ability symptoms in adults is not optimal. However, the 24-week duration of the placebo-controlled study was probably too short, given the slow response of the bone to treatment as

evidenced by the bone histology study which reported the persistence of histological osteomalacia in 10 patients at 48 weeks. In addition, the mean improvement corresponding to the minimum clinically important difference (MCID) in stiffness score and physical function (WOMAC) was reached after weeks 36 and 96, respectively. The disappearance of modifiable disorders such as fractures/pseudofractures and walking disability, combined to the expected nonprogression of complications of conventional treatment (hyperparathyroidism and nephrocalcinosis) when present, should simplify the care pathway. In addition, one clinical trial is ongoing to evaluate the effects of burosumab on muscle function in children and adults (NCT04146935, clinicaltrials.gov). A pharmaco-economic comparison of Best Supportive Care (BSC) and burosumab was carried out by the sponsor-independent Canadian Agency for Drugs & Technologies in Health (CADTH).⁵³ In this report, the quality-adjusted incremental life year (QALYS) of burosumab *versus* BSC in adults ranged from 2.87 to 6.89 across the various scenario analyses (base case: 3.25, adult subgroup with prior fracture history: 6.89). Conversely, irreversible complications such as dental abscesses (linked to defects in dentine maturation), osteoarthritis, spinal stenosis, and pathologies linked to ossifying enthesopathies should not, in theory, be improved by burosumab. However, in time, those irreversible consequences of the disease currently seen in adults but which began in childhood, such as short stature and lower limb deformities or dystocia, should be seen less and less often in adults as this treatment is instituted in all children who need it. This should reduce the need for orthopedic surgery and physiotherapy.

Side effects

The clinical side effects reported under burosumab are mostly skin reactions at injection sites in 12% of the patients which never resulted in treatment discontinuation. Hypersensitivity events were experienced in 6% of burosumab and placebo recipient anti-burosumab antibodies occurred in less than 10% of patients and did not affect response to treatment. No neutralizing activity was detected.³¹ Restless leg syndrome (RLS) worsening or new-onset RLS was more common with burosumab than with placebo (11.8 *versus* 6.1% of patients) in one study, which led to discontinuation of burosumab in one patient, followed by resolution of the symptoms. The biologic risk that

remains is hyperphosphatemia (i.e. higher than the upper limit of normal level) which was observed in 18/176 patients (10.2%) on burosumab and required a 50% dose reduction in 7% of the patients. Monitoring of serum phosphate values and oral dose adjustment is recommended to achieve these objectives during the titration period and in the follow-up of the treatment. No patient experienced severe hyperphosphatemia (i.e. >2.1 mmol/l) in the studies. The marketing authorization document mentions that 'Burosumab has not been studied in patients with renal impairment. Burosumab should not be used in patients with severe renal impairment or end-stage renal disease'.³¹ CKD induces an overall reduction in urinary phosphate excretion which increases the phosphate load as early as CKD stage 3. This promotes an adaptive increase in serum FGF23 which in turn increases urinary phosphate excretion by the remaining nephrons, thus preventing a rise in serum phosphate levels for some time.⁵⁴ Blocking FGF23 with antibodies in CKD rats increased vascular calcification and mortality.⁵⁵ Therefore, the use of burosumab in patients with even moderate renal impairment (CKD stage 2) should be cautious and monitored more closely.

The dosage of 1 mg/kg every 4 weeks seems adequate and represents the best compromise between efficacy (i.e. sustained increase in serum phosphate values above the lower limit of normal levels) and safety (i.e. limiting the risk of hyperphosphatemia) and represents an average dose of 50 to 90 mg/injection with an approximate cost of 180 to 290k€ per year depending on body weight. At this dose, no worsening of hyperparathyroidism or ectopic calcifications, especially renal calcifications, has been observed. As the PHEX mutation induces biological disorders on a continuous basis, it is assumed that the duration of treatment should be adapted to the presence of symptoms. It should be noted that the patients included in study CL203 had discontinued their previous treatment 21 months before the next inclusion and showed at baseline symptoms of almost the same intensity and frequency as those of never-treated patients, showing the reversible character of the improvement.

Target population

Which adults with XLH should benefit from burosumab treatment? The therapeutic indications stated in the MA document are: 'Crysvita can be used in children and adolescents between

1 and 17 years of age when signs of bone disease are seen on X-rays, and in adults'.⁵⁶ The effects of burosumab administration have not been studied in asymptomatic patients (i.e. pain score < 4), nor in patients above 66 years of age, in pregnant women and in patients with impaired renal function (the highest GFR was 66 ml/min). The definition of the disease 'X-linked hypophosphatemia' needs to be clarified. Five percent of the patients included in the studies had no PHEX mutation and 12% had PHEX variants of uncertain significance.³¹ The (rare) patients not followed in childhood who present with all the biological signs of phosphate renal leak and sequelae of hypophosphatemic rickets in whom no PHEX mutation is found should be still considered eligible candidates for burosumab treatment.

Conclusion

The effects of the conventional treatment of XLH have not been correctly evaluated in adults. While it is recognized that phosphate and active vitamin D may improve some symptoms, it is also clear that this treatment results in side effects that affect compliance and may induce severe disorders if not strictly monitored. Overall, the benefit/risk ratio of burosumab is positive in adult XLH patients with clinical and/or biological complications of the disease. Burosumab corrects hypophosphatemia, a subgroup of markers of the disease, and promotes fracture healing due to its beneficial effects on bone mineralization. The studies show a modest but significant effect of burosumab on XLH-induced subjective pain and physical ability symptoms, which are clinically relevant. However, in adults, some of these symptoms may depend on irreversible lesions that cannot be modified by treatment. The risk of side effects related to hyperphosphatemia is moderate and requires regular biological monitoring. The tolerance profile of burosumab in the mid-term appears to be superior to that of conventional treatment. That said, the long-term efficacy and tolerance of burosumab need to be evaluated.

Author contributions

Marie-Hélène Lafage-Proust: Writing – original draft; Writing – review & editing.


Conflict of interest statement

The author declared no potential conflicts of interest with respect to the research, authorship, and/or publication of this article.

Funding

The author received no financial support for the research, authorship, and/or publication of this article.

ORCID iD

Marie-Hélène Lafage Proust  <https://orcid.org/0000-0002-2091-3961>

Ethical approval/patient consent

Ethical approval and informed consent were not required for this review.

References

1. Burnett CH, Dent CE, Harper C, *et al.* Vitamin D-resistant rickets. Analysis of 24 pedigrees with hereditary and sporadic cases. *Am J Med* 1964; 36: 222–232.
2. Martin A, David V and Quarles LD. Regulation and function of the FGF23/klotho endocrine pathways. *Physiol Rev* 2012; 92: 131–155.
3. Ratsma DMA, Zillikens MC and van der Eerden BCJ. Upstream regulators of fibroblast growth factor 23. *Front Endocrinol* 2021; 12: 588096.
4. Murali SK, Andrukhova O, Clinkenbeard EL, *et al.* Excessive osteocytic Fgf23 secretion contributes to pyrophosphate accumulation and mineralization defect in hyp mice. *PLoS Biol* 2016; 14: e1002427.
5. Che H, Roux C, Etcheto A, *et al.* Impaired quality of life in adults with X-linked hypophosphatemia and skeletal symptoms. *Eur J Endocrinol* 2016; 174: 325–333.
6. Skrinar A, Dvorak-Ewell M, Evins A, *et al.* The lifelong impact of X-linked hypophosphatemia: results from a burden of disease survey. *J Endocr Soc* 2019; 3: 1321–1334.
7. Marie PJ and Glorieux FH. Bone histomorphometry in asymptomatic adults with hereditary hypophosphatemic vitamin D-resistant osteomalacia. *Metab Bone Dis Relat Res* 1982; 4: 249–253.
8. Linglart A, Biosse-Duplan M, Briot K, *et al.* Therapeutic management of hypophosphatemic rickets from infancy to adulthood. *Endocr Connect* 2014; 3: R13–R30.
9. Chesher D, Oddy M, Darbar U, *et al.* Outcome of adult patients with X-linked hypophosphatemia caused by PHEX gene mutations. *J Inherit Metab Dis* 2018; 41: 865–876.

10. Reid IR, Hardy DC, Murphy WA, *et al.* X-linked hypophosphatemia: a clinical, biochemical, and histopathologic assessment of morbidity in adults. *Medicine* 1989; 68: 336–352.
11. Berndt M, Ehrich JH, Lazovic D, *et al.* Clinical course of hypophosphatemic rickets in 23 adults. *Clin Nephrol* 1996; 45: 33–41.
12. Beck-Nielsen SS, Brusgaard K, Rasmussen LM, *et al.* Phenotype presentation of hypophosphatemic rickets in adults. *Calcif Tissue Int* 2010; 87: 108–119.
13. Kato H, Koga M, Kinoshita Y, *et al.* Incidence of complications in 25 adult patients with X-linked hypophosphatemia. *J Clin Endocrinol Metab* 2021; 106: e3682–e3692.
14. Larson AN, Trousdale RT, Pagnano MW, *et al.* Hip and knee arthroplasty in hypophosphatemic rickets. *J Arthroplasty* 2010; 25: 1099–1103.
15. Smith R, Newman RJ, Radda GK, *et al.* Hypophosphatemic osteomalacia and myopathy: studies with nuclear magnetic resonance spectroscopy. *Clin Sci* 1984; 67: 505–509.
16. Steele A, Gonzalez R, Garbalosa JC, *et al.* Osteoarthritis, osteophytes and enthesophytes affect biomechanical function in adults with X-linked hypophosphatemia. *Clin Endocrinol Metab* 2020; 105: e1798–e1814.
17. Lee SH, Agashe MV, Suh SW, *et al.* Paravertebral ligament ossification in vitamin D-resistant rickets: incidence, clinical significance, and genetic evaluation. *Spine* 2012; 37: E792–E796.
18. Glass LR, Dagi TF and Dagi LR. Papilledema in the setting of x-linked hypophosphatemic rickets with craniosynostosis. *Case Rep Ophthalmol* 2011; 2: 376–381.
19. O'Malley SP, Adams JE, Davies M, *et al.* The petrous temporal bone and deafness in X-linked hypophosphatemic osteomalacia. *Clin Radiol* 1988; 39: 528–530.
20. Marin A, Morales P, Jiménez M, *et al.* Characterization of oral health status in Chilean patients with X-linked hypophosphatemia. *Calcif Tissue Int* 2021; 109: 132–138.
21. Biosse-Duplan M, Coyac BR, Bardet C, *et al.* Phosphate and vitamin D prevent periodontitis in X-linked hypophosphatemia. *J Dent Res* 2017; 96: 388–395.
22. Hardy DC, Murphy WA, Siegel BA, *et al.* X-linked hypophosphatemia in adults: prevalence of skeletal radiographic and scintigraphic features. *Radiology* 1989; 171: 403–414.
23. Veilleux LN, Cheung MS, Glorieux FH, *et al.* The muscle-bone relationship in X-linked hypophosphatemic rickets. *J Clin Endocrinol Metab* 2013; 98: E990–E995.
24. Aono Y, Hasegawa H, Yamazaki Y, *et al.* Anti-FGF-23 neutralizing antibodies ameliorate muscle weakness and decreased spontaneous movement of Hyp mice. *J Bone Miner Res* 2011; 26: 803–810.
25. Pesta DH, Tsirigotis DN, Befroy DE, *et al.* Hypophosphatemia promotes lower rates of muscle ATP synthesis. *FASEB J* 2016; 30: 3378–3387.
26. Liu ES, Thoonen R, Petit E, *et al.* Increased circulating FGF23 does not lead to cardiac hypertrophy in the male hyp mouse model of XLH. *Endocrinology* 2018; 159: 2165–2172.
27. Hernández-Frías O, Gil-Peña H, Pérez-Roldán JM, *et al.* Risk of cardiovascular involvement in pediatric patients with X-linked hypophosphatemia. *Pediatr Nephrol* 2019; 34: 1077–1086.
28. Takashi Y, Kinoshita Y, Hori M, *et al.* Patients with FGF23-related hypophosphatemic rickets/osteomalacia do not present with left ventricular hypertrophy. *Endocr Res* 2017; 42: 132–137.
29. Zhukouskaya VV, Rothenbuhler A, Colao A, *et al.* Increased prevalence of overweight and obesity in children with X-linked hypophosphatemia. *Endocr Connect* 2020; 9: 144–153.
30. Bacchetta J, Bardet C and Prié D. Physiology of FGF23 and overview of genetic diseases associated with renal phosphate wasting. *Metabolism* 2020; 103S: 153865.
31. European Medicines Agency. Committee for Medicinal Products for Human Use, assessment report CRYSVITA (EMA/423776/2020), July 2020, https://www.ema.europa.eu/en/documents/variation-report/crysvita-h-c-4275-ii-010-g-epar-assessment-report-variation_en.pdf
32. Haffner D, Emma F, Eastwood DM, *et al.* Clinical practice recommendations for the diagnosis and management of X-linked hypophosphatemia. *Nat Rev Nephrol* 2019; 15: 435–455.
33. Protocoles nationaux de diagnostic et de soins (PNDS), https://www.has-sante.fr/upload/docs/application/pdf/2018-05/hypophosphatemies_hereditaires_a_fgf23_eleve_dont_hypophosphatemies_liees_a_lx_-_pnds.pdf
34. West CD, Blanon JC, Silverman J, *et al.* Use of phosphate salts as an adjunct to vitamin D in the treatment of hypophosphatemic vitamin D refractory rickets. *J Pediatr* 1964; 64: 469–477.

35. Shanbhogue VV, Hansen S, Jørgensen NR, *et al.* Impact of conventional medical therapy on bone mineral density and bone turnover in adult patients with X-linked hypophosphatemia: a 6-year prospective cohort study. *Calcif Tissue Int* 2018; 102: 321–328.
36. Sullivan W, Carpenter T, Glorieux F, *et al.* A prospective trial of phosphate and 1,25-dihydroxyvitamin D3 therapy in symptomatic adults with X-linked hypophosphatemic rickets. *J Clin Endocrinol Metab* 1992; 75: 879–885.
37. Connor J, Olear EA, Insogna KL, *et al.* Conventional therapy in adults with X-linked hypophosphatemia: effects on enthesopathy and dental disease. *J Clin Endocrinol Metab* 2015; 100: 3625–3632.
38. Imel EA, DiMeglio LA, Hui SL, *et al.* Treatment of X-linked hypophosphatemia with calcitriol and phosphate increases circulating fibroblast growth factor 23 concentrations. *J Clin Endocrinol Metab* 2010; 95: 1846–1850.
39. Goodyer PR, Kronick JB, Jequier S, *et al.* Nephrocalcinosis and its relationship to treatment of hereditary rickets. *J Pediatr* 1987; 111: 700–704.
40. ColaresNeto GP, Ide Yamauchi F, Hueb Baroni R, *et al.* Nephrocalcinosis and nephrolithiasis in X-linked hypophosphatemic rickets: diagnostic imaging and risk factors. *J Endocr Soc* 2019; 3: 1053–1061.
41. Blydt-Hansen TD, Tenenhouse HS and Goodyer P. PHEX expression in parathyroid gland and parathyroid hormone dysregulation in X-linked hypophosphatemia. *Pediatr Nephrol* 1999; 13: 607–611.
42. Rafaelsen SH, Johansson S, Raeder H, *et al.* Hereditary hypophosphatemia in Norway; a retrospective population-based study of genotypes, phenotypes and treatment complications. *Eur J Endocrinol* 2016; 174: 125–136.
43. Firth RG, Grant CS and Riggs BL. Development of hypercalcemic hyperparathyroidism after long-term phosphate supplementation in hypophosphatemic osteomalacia. Report of two cases. *Am J Med* 1985; 78: 669–673.
44. Carpenter TO, Olear EA, Zhang JH, *et al.* Effect of paricalcitol on circulating parathyroid hormone in X-linked hypophosphatemia: a randomized, double-blind, placebo-controlled study. *J Clin Endocrinol Metab* 2014; 99: 3103–3111.
45. Vervloet MG, Sezer S, Massy ZA, *et al.* The role of phosphate in kidney disease. *Nat Rev Nephrol* 2017; 13: 27–38.
46. Alon US, Levy-Olomucki R, Moore WV, *et al.* Calcimimetics as an adjuvant treatment for familial hypophosphatemic rickets. *Clin J Am Soc Nephrol* 2008; 3: 658–664.
47. Imel EA, Zhang X, Ruppe MD, *et al.* Prolonged correction of serum phosphorus in adults with X-linked hypophosphatemia using monthly doses of KRN23. *J Clin Endocrinol Metab* 2015; 100: 2565–2573.
48. Carpenter TO, Imel EA, Ruppe MD, *et al.* Randomized trial of the anti-FGF23 antibody KRN23 in X-linked hypophosphatemia. *J Clin Invest* 2014; 124: 1587–1597.
49. Insogna KL, Briot K, Imel EA, *et al.* A randomized, double-blind, placebo-controlled, phase 3 trial evaluating the efficacy of burosumab, an anti-FGF23 antibody, in adults with X-linked hypophosphatemia: week 24 primary analysis. *J Bone Miner Res* 2018; 33: 1383–1393.
50. Portale AA, Carpenter TO, Brandi ML, *et al.* Continued beneficial effects of burosumab in adults with X-linked hypophosphatemia: results from a 24-week treatment continuation period after a 24-week double-blind placebo-controlled period. *Calcif Tissue Int* 2019; 105: 271–284.
51. Ruppe MD, Zhang X, Imel EA, *et al.* Effect of four monthly doses of a human monoclonal anti-FGF23 antibody (KRN23) on quality of life in X-linked hypophosphatemia. *Bone Rep* 2016; 5: 158–162.
52. Insogna KL, Rauch F, Kamenický P, *et al.* Burosumab improved histomorphometric measures of osteomalacia in adults with X-linked hypophosphatemia: a phase 3, single-arm, international trial. *J Bone Miner Res* 2019; 34: 2183–2191.
53. Pharmacoeconomic common drug review for burosumab, Canadian Agency for Drugs & Technologies in Health, CADTH, Common Drug Review on Crysvida, 2020, <https://www.cadth.ca/sites/default/files/cdr/pharmacoeconomic/sr0602-crysvida-pharmacoeconomic-review-report.pdf>
54. Isakova T, Wahl P, Vargas GS, *et al.* Fibroblast growth factor 23 is elevated before parathyroid hormone and phosphate in chronic kidney disease. *Kidney Int* 2011; 79: 1370–1378.
55. Shalhoub V, Shatzen EM, Ward SC, *et al.* FGF23 neutralization improves chronic kidney disease-associated hyperparathyroidism yet increases mortality. *J Clin Invest* 2012; 122: 2543–2553.
56. European Medicines Agency. Crysvida, product information, therapeutic indication, 2021, <https://www.ema.europa.eu/en/medicines/human/EPAR/crysvida#authorisation-details-section>