



OPEN ACCESS

Case report

Refractory in-stent stenosis after flow diverter stenting associated with delayed cobalt allergic reaction

Shoko Fujii,¹ Kyohei Fujita ,¹ Hiroto Yamaoka,¹ Kazunori Miki,¹ Sakyō Hirai,¹ Shigeru Nemoto,^{1,2} Kazutaka Sumita ¹

¹Department of Endovascular Surgery, Tokyo Medical and Dental University, Bunkyo-ku, Japan

²Department of Neurosurgery, Kanto Rosai Hospital, Yokohama, Japan

Correspondence to

Dr Kazutaka Sumita, Department of Endovascular Surgery, Tokyo Medical and Dental University, Bunkyo-ku, Tokyo, Japan; sumita.nsrj@tmd.ac.jp

Received 27 June 2021

Accepted 15 August 2021

Published Online First

25 August 2021

SUMMARY

In-stent stenosis (ISS) triggered by a metal-induced allergic reaction of Pipeline embolization device (PED) placement is extremely rare. The present report describes a patient who presented with delayed parent artery occlusion and refractory ISS after PED placement due to cobalt allergy. A patient in her 70s underwent PED placement for a right internal carotid artery (ICA) large aneurysm; 4 months later, the patient presented with left-sided hemiparesis, and MRI revealed right ICA occlusion even though antiplatelet therapy was optimal. She underwent mechanical thrombectomy, and successful recanalization was achieved. However, follow-up angiography 6 months after the thrombectomy revealed severe ISS, and the patch testing showed a positive reaction for cobalt. As a result of long-term administration of oral steroids and antihistamine, progression of ISS was suppressed. It was supposed that a delayed hypersensitivity reaction to cobalt might induce refractory ISS after PED placement.

BACKGROUND

Delayed ischemic events secondary to in-stent stenosis (ISS) are serious complications of intracranial stent implantation and have not been completely understood and characterized. Apart from the lack of antiplatelet effect or stent malposition, allergic reaction to the metal device might be associated with ISS.¹ However, to our knowledge, ISS and thrombosis associated with metal allergy after intracranial stent implantation have not yet been reported. We describe a case of in-stent thrombosis and refractory ISS after a Pipeline embolization device (PED, Medtronic/Covidien, Irvine, California, USA) placement for an internal carotid artery (ICA) large aneurysm, possibly associated with cobalt allergy.

CASE PRESENTATION

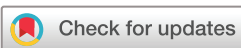A patient in her 70s was incidentally found to have a large right ICA aneurysm on MRI. She had dyslipidemia and osteoporosis. Her past medical history confirmed that she had no drug allergy; her metal allergy was not seen prior to PED placement. Digital subtraction angiography showed a right paraclinoid large ICA aneurysm, 15 mm in diameter (figure 1A–C). She elected to undergo endovascular treatment with a PED.

TREATMENT

She received dual antiplatelet therapy with acetylsalicylic acid (100 mg/day) and clopidogrel (75 mg/day), 2 weeks before the procedure. Antiplatelet activity was checked using VerifyNow assay (Accumetrics, San Diego, California, USA) the day before the procedure, and antiplatelet effects were confirmed to be optimal. The procedure was performed under general anesthesia and systemic heparinization. After deployment of PED, coil embolization was additionally performed using bare platinum coil (figure 1D–F). She was discharged on day 7 without any neurological deficits, and dual antiplatelet therapy was continued.

OUTCOME AND FOLLOW-UP

Four months postoperatively, she presented with acute onset of left-sided hemiparesis. Diffusion-weighted imaging showed hyperintense lesions in the corona radiata and MR angiography revealed ICA occlusion (figure 2A–C). Cerebral angiography confirmed the in-stent thrombosis with right ICA occlusion (figure 2D). Mechanical thrombectomy was performed using the stent-retriever device, and the clot was retrieved. Although recanalization was achieved, ISS remained. Next, percutaneous transluminal angioplasty was performed, and complete recanalization was achieved (figure 2D). Antiplatelet effects were confirmed to be optimal. Blood tests were normal. Following cerebral angiography, 1 week after the procedure, complete recanalization and stent patency was maintained (figure 3A). She was referred to a rehabilitation center owing to slight left-sided hemiparesis 4 weeks postoperatively, with a modified Rankin scale score of 3. Six months after thrombectomy, the modified Rankin scale score was 0. However, follow-up cerebral angiography demonstrated severe ISS (figure 3B). To investigate the cause of the ISS, her medical history was rechecked, revealing a flare reaction in the area of contact with metal jewelry, and a patch test was performed. Metals of PED (nickel, cobalt, platinum, chromium, etc) and powder of PED were included in the patch test. A positive result was seen for the cobalt reagent, and slightly positive results for PED stent reagents (figure 4). With cobalt-induced ISS suspected, oral administration of steroids (prednisolone; initial dose: 40 mg/day for 2 days, tapering for 7 days, maintenance dose: 2.5 mg/day) and antihistamines (fexofenadine 120 mg/day) was initiated.



© Author(s) (or their employer(s)) 2022. Re-use permitted under CC BY-NC. No commercial re-use. See rights and permissions. Published by BMJ.

To cite: Fujii S, Fujita K, Yamaoka H, et al. *J NeuroIntervent Surg* 2022;**14**:e4.

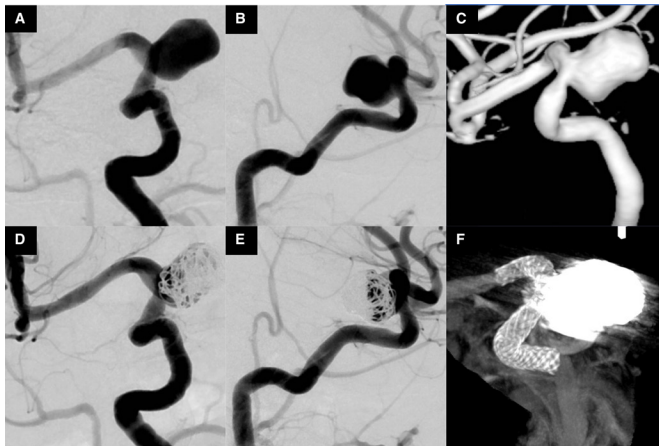

Figure 1 (A,B) Right carotid angiogram and (C) three-dimensional reconstruction demonstrating unruptured large aneurysm at the C2 portion. (D, E) Immediate postoperative angiography and (F) cone-beam computed tomography (CT) showing Pipeline embolization device across the internal carotid artery and coil insertion.

Cerebral angiography was performed 7, 9, and 14 months after thrombectomy (figure 3C–E). Fourteen months later, progression of ISS was confirmed to be suppressed. Oral administration of steroids and antihistamines was completed, and close observation has been continued.

DISCUSSION

Clinical symptoms of contact dermatitis are secondary to the inflammation caused by delayed-type hypersensitivity reaction (DTR) to the metal. With metal ions released into the circulation, intracranial metal device implantation might induce DTR, such as allergic dermatitis, encephalopathy, and reversible parenchymal changes.^{2–4} ISS is also reported as DTR to coronary stents, and inflammatory cell activation, and excessive proliferation occur within implanted metal stents.¹

We encountered delayed parent artery occlusion after PED placement and ISS recurrence. Antiplatelet activity was optimal, and patch testing showed a positive reaction for

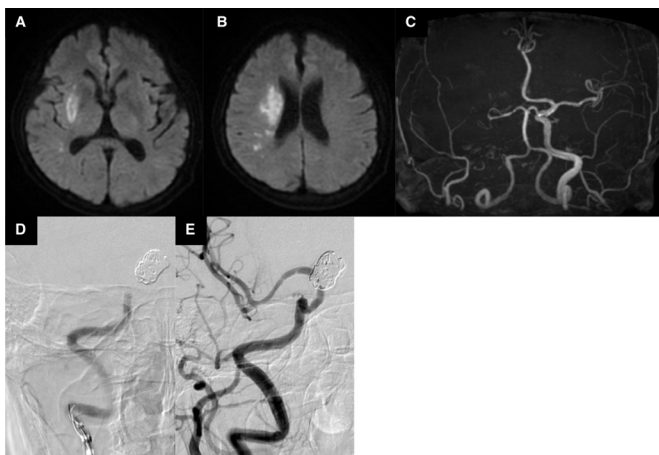


Figure 2 (A) Diffusion-weighted images showing hyperintense lesions at the right corona radiata. (C) Magnetic resonance (MR) angiography revealing the absence of the right carotid artery. (D) Right carotid angiography revealing the occlusion of proximal side of Pipeline embolization device. (E) The right internal carotid artery is completely recanalized.

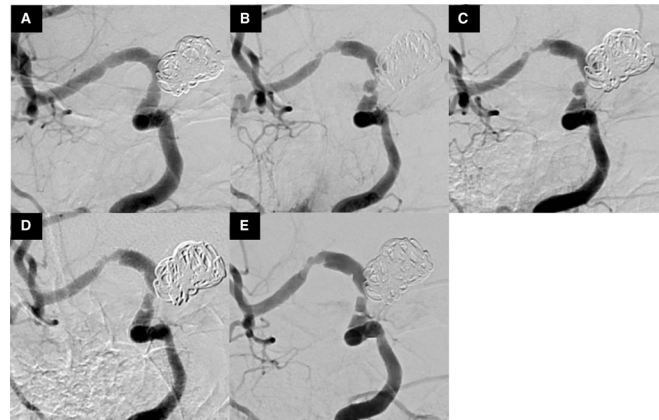

Figure 3 Right carotid angiography after thrombectomy. (A) At 1-week follow-up, (B) at 6-months' follow-up, (C) at 7-months' follow-up, (D) at 9-months' follow-up, and (E) at 14-months' follow-up.

cobalt in the PED. After administration of oral steroids and antihistamines, progression of ISS was suppressed, and no other findings suggested causative disease. Thus, we considered that delayed parent artery occlusion and ISS recurrence were associated with cobalt allergy. As there is no report of cobalt allergy with PED placement and no evidence for long-term outcomes for medical treatment of DTR to metal device implantation, close clinical and angiographic monitoring are warranted.

If unusual skin symptoms are observed in the area of contact with metal jewelry or precious metal, metal allergy is suspected, and patch testing is performed. Most reports that described the association between DTR and metal implants suggest that patch testing is positive for implanted metals and useful for diagnosis.^{1–3}

For metal allergy, removal of potential causes is the most effective treatment. However, removal of a metal device placed in the intracranial blood vessel was impractical, thus medical treatment was considered as first option for DTR to metal implants. Previous studies have shown that administration of oral steroids is effective and relieves various symptoms.^{2 3 5} We selected the dose of corticosteroid according to the dose of contact dermatitis. As the regimen, 5 to 7 days of prednisone, 0.5–1 mg/kg daily is recommended. After

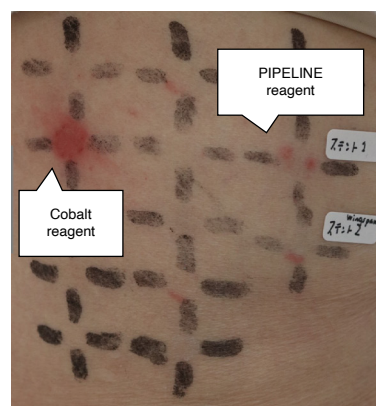


Figure.4

Figure 4 Clinical photograph showing positive patch test reaction for cobalt.

this initial therapy, the dose may be reduced by 50% for the next 5 to 7 days.⁶ Although antihistamines are generally not effective for contact dermatitis,⁶ some reports showed that oral administration of antihistamines was effective for DTR to metal implants,^{2,5} and therefore we initiated oral antihistamines. Additionally, because past study has shown that cilostazol prevents in-stent stenosis,⁷ a switch to, or addition of, cilostazol might be a treatment option.

Common metal substances that cause DTR include nickel and cobalt. PED and other flow diverter stents, such as Silk (Balt Extrusion, Montmorency, France), the flow redirection endoluminal device (FRED; MicroVention, Tustin, California, USA), the p64 flow-modulation device (Phoenix, Arizona, USA), and the Surpass flow diverter (Surpass; Stryker Neurovascular, Fremont, California, USA), contain either nickel or cobalt. Therefore, if ISS occurs after PED or other flow-diverter stent placement, and the cause is unidentified, medical history related to allergy should be examined and patch testing performed. Before endovascular surgery, if

the patient has a strong allergy to the metal in the stent, other treatment options should be considered.

Contributors I certify that neither this manuscript nor one with substantially similar content under my authorship has been published or is being considered for publication elsewhere. KS and SF planned this case report, and SF took the lead in writing the manuscript. SN, KM, SH, KF, and HY provided critical and important feedback.

Funding The authors have not declared a specific grant for this research from any funding agency in the public, commercial or not-for-profit sectors.

Competing interests None declared.

Patient consent for publication Obtained.

Provenance and peer review Not commissioned; externally peer reviewed.

Open access This is an open access article distributed in accordance with the Creative Commons Attribution Non Commercial (CC BY-NC 4.0) license, which permits others to distribute, remix, adapt, build upon this work non-commercially, and license their derivative works on different terms, provided the original work is properly cited, appropriate credit is given, any changes made indicated, and the use is non-commercial. See: <http://creativecommons.org/licenses/by-nc/4.0/>.

ORCID iDs

Kyohei Fujita <http://orcid.org/0000-0002-5240-6884>

Kazutaka Sumita <http://orcid.org/0000-0002-1348-1099>

Learning points

- ▶ We describe a rare case of delayed parent artery occlusion and in-stent restenosis after Pipeline embolization device (PED) placement associated with cobalt allergy; administration of oral steroids and antihistamines suppressed the progression of in-stent stenosis.
- ▶ Despite being rare, delayed-type hyper-reaction to metal device implantation may induce inflammatory cell activation and excessive proliferation and in-stent stenosis after PED placement.
- ▶ If in-stent stenosis after PED placement occurs, and the reason for this is unclear, we should suspect metal allergy and recheck past medical history related to allergy and perform patch testing.

REFERENCES

- 1 Köster R, Vieluf D, Kiehn M, *et al*. Nickel and molybdenum contact allergies in patients with coronary in-stent restenosis. *Lancet* 2000;356:1895–7.
- 2 Uwatoko T, Tsumoto T, Wada N, *et al*. Dermatitis caused by metal allergy after coil embolization for unruptured cerebral aneurysm. *J Neurointerv Surg* 2016;8:e42.
- 3 Park HS, Nakagawa I, Yokoyama S, *et al*. Nickel-associated delayed multiple white matter lesions after stent-assisted coil embolization of intracranial unruptured aneurysm. *J Neurointerv Surg* 2018;10:e1–5.
- 4 Ulus S, Yakupoğlu A, Kararslan E, *et al*. Reversible intracranial parenchymal changes in MRI after MCA aneurysm treatment with stent-assisted coiling technique; possible nickel allergy. *Neuroradiology* 2012;54:897–9.
- 5 Goto M, Hashikata H, Toda H, *et al*. Parent artery stenosis and visual disturbance after balloon-assisted coil embolization of an unruptured cerebral aneurysm: a case report. *Noushinkei Kekkannai Tiryō* 2019;13:376–81.
- 6 Usatine RP, Riojas M. Diagnosis and management of contact dermatitis. *Am Fam Physician* 2010;82:249–55.
- 7 Iftikhar O, Oliveros K, Tafur AJ, *et al*. Prevention of femoropopliteal in-stent restenosis with cilostazol: a meta-analysis. *Angiology* 2016;67:549–55.