



Anatomic Double-Bundle Reinsertion After Acute Proximal Anterior Cruciate Ligament Injury Using Knotless PushLock Anchors

Patrick Weninger, M.D., Florian Wepner, M.D., Florian Kissler, M.D.,
Michael Enenkel, M.D., and Christian Wurnig, M.D.

Abstract: Direct anterior cruciate ligament (ACL) repair has been described with different suture techniques after acute ACL injury, but these procedures showed high failure rates. Recent studies, however, led to a better understanding of the biology of primary ACL healing. This article describes a novel technique combining the “healing response technique” with primary anatomic double-bundle ACL reinsertion after an acute proximal ACL tear using nonabsorbable No. 2 FiberWire (Arthrex, Naples, FL) and PushLock knotless suture anchors (Arthrex). We recommend this technique for patients with acute proximal avulsion–type ACL injuries. Postoperatively, we recommend a knee brace locked in full extension for at least 4 weeks to ensure adequate immobilization and then to increase knee flexion slowly over the next 4 weeks for subsequent healing of the ACL repair. Our technique combines anatomic positioning and reinsertion of the ACL bundles with microfracturing of the region delivering stem cells and growth factors to the repaired ACL, creating optimal conditions for the healing period. In certain cases this technique might be an alternative to conventional ACL reconstruction with autograft or allograft tendons.

Lesions of the anterior cruciate ligament (ACL) are common orthopaedic injuries. In athletes and active patients, reconstruction of the torn ACL is recommended to avoid instability and subsequent meniscus and cartilage tears. The current gold standard for ACL reconstruction is anatomic ACL reconstruction with autograft or allograft.¹ This is because the intrinsic healing potential of the ACL is low compared with other knee ligaments, such as the medial collateral ligament.² Nevertheless, direct ACL repair with different suture techniques after acute ACL injury has been suggested but has been shown not to be effective in most cases.³ The “healing response technique” after acute ACL injuries as described by Steadman et al.^{4,5} has been shown to be effective in proximal ACL

avulsion–type injuries in a certain patient subpopulation.⁶ The rationale is to promote ligament healing by using bone marrow stem cells and to limit range of motion during the healing period. Another recent study with dynamic primary ACL repair of femoral avulsed ligaments showed promising results.⁷

This article highlights a combination of the healing response technique with primary anatomic double-bundle ACL reinsertion after an acute proximal ACL tear using PushLock knotless suture anchors (Arthrex, Naples, FL). We developed this procedure to ensure anatomic positioning of the ACL close to the femoral footprint. To create the best conditions for the healing period, we combined an ACL repair with the healing response technique (Table 1).

Operative Technique

General Recommendations

We generally recommend this technique for patients with acute proximal avulsion–type ACL injuries (Fig 1). Ideally, the synovial sheet is intact and 1 or both ACL bundles are avulsed from the medial wall of the lateral femoral condyle, leaving the ACL footprint intact (Fig 2). We do not recommend the technique for intraligamentous or tibial attachment ruptures. The patient is prepared and draped in the standard supine

From the First Orthopedic Department—Knee Unit, Orthopedic Hospital Vienna Speising, Vienna, Austria.

The authors report that they have no conflicts of interest in the authorship and publication of this article.

Received July 17, 2014; accepted September 12, 2014.

Address correspondence to Florian Wepner, M.D., First Orthopedic Department—Knee Unit, Orthopedic Hospital Vienna Speising, Speisingerstrasse 109, 1130 Vienna, Austria. E-mail: florian.wepner@oss.at

© 2015 by the Arthroscopy Association of North America. Open access

under CC BY-NC-ND license.

2212-6287/14620

<http://dx.doi.org/10.1016/j.eats.2014.09.007>

Table 1. Indications, Key Points, Tips, Pearls, Pitfalls, Risks, and Aftercare

| | |
|---|--|
| Indications | |
| Acute femoral avulsion—type ACL injury | |
| Subsynovial ACL tear/stretch injury | |
| Partial ACL tear (isolated AM/PL bundle injury) | |
| Contraindications | |
| Chronic ACL tear | |
| Intraligament ACL tear | |
| Tibial ACL avulsion | |
| Bony ACL avulsion | |
| Key points | |
| Early-stage surgery | |
| Anatomic refixation of AM and PL bundles | |
| Correct indication is mandatory | |
| Tips | |
| Thorough washout of fresh blood and blood clots | |
| Temporarily increase intra-articular pressure to enhance view | |
| 120° of flexion for PL bundle refixation | |
| Pearls | |
| Use a central portal for the arthroscope to better visualize the femoral footprint. | |
| Remove parts of the Hoffa fat pad under the medial portal to avoid soft-tissue bridges. | |
| Pull out both free ends of the FiberWire to avoid soft-tissue bridges. | |
| Pitfalls and risks | |
| Limited vision in 120° of knee flexion when drilling the hole for the PL bundle can result in nonanatomic refixation. | |
| Sutures may cut through the ACL bundle if only the synovial sheet is perforated. | |
| The blood supply may be compromised. | |
| Aftercare | |
| Extension brace for 4 wk | |
| 30° of knee flexion and full extension in weeks 5 and 6 | |
| Partial weight bearing, pain oriented | |
| Closed chain exercises starting after 4 wk | |
| Non-pivoting sports after 3 mo | |
| Pivoting sports after 6 mo | |

ACL, anterior cruciate ligament; AM, anteromedial; PL, posterolateral.

position for ACL repair. We use a leg holder and perform the operation with the patient under either general or spinal anesthesia. We apply but do not routinely inflate a tourniquet, and we recommend increasing the intra-articular pressure to up to 80 mm Hg to allow for clear vision. Care must be taken to allow knee flexion up to 120° to enable anteromedial (AM) portal drilling if necessary. Perioperative antibiotic prophylaxis consists of single-shot administration of cefazolin. We recommend a high anterolateral portal for the arthroscope and a suprameniscal AM portal that is created under vision. Once the ACL injury is assessed, the next step is to decide whether to reinsert or to replace the torn ACL. To determine this, we recommend a central portal that allows for better visualization of the medial wall of the lateral femoral condyle.

Diagnostic Arthroscopy

First, all blood clots are washed out after the acute ACL rupture. Then, diagnostic arthroscopy and meniscus

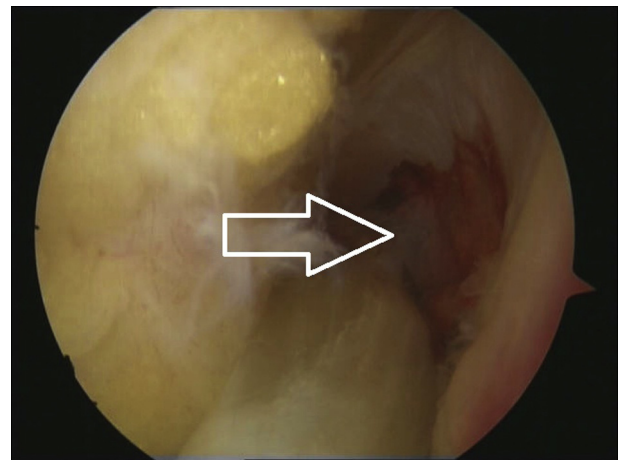


Fig 1. Acute proximal avulsion—type ACL injury (arrow) with blood clot in footprint (left knee, central-portal view, 90° of knee flexion).

repair are performed with a standard 30° optic device. The ACL is thoroughly examined at all flexion angles to determine the exact type of ACL injury and to verify that the ACL injury is amenable for reinsertion. Reinsertion is possible in proximal avulsion injuries with or without an intact synovial sheet (Fig 1).

Footprint Microfractures

A 30° or 45° microfracture awl is inserted from the medial suprameniscal portal. With the awl, multiple holes are made in the AM (Fig 3) and posterolateral (PL) (Fig 4) footprint of the ACL at 90° and 120° of knee flexion, respectively, to stimulate bone marrow extravasation. We recommend 2 to 3 microfractures in each footprint. Alternatively, microfractures in the notch can be performed after bundle sutures have been applied and before knotless anchors have been inserted to allow for a better view of the AM and PL footprints, as shown in Video 1.

Bundle Sutures

We use nonabsorbable No. 2 FiberWire sutures (Arthrex) to stitch through the ACL bundles. From the medial portal, 1 suture (blue) is passed through the PL bundle with a SutureLasso (Arthrex) (Fig 5). Alternatively, a FiberStick (Arthrex) can be used to stitch through each bundle and/or the lateral portal might be used for this (Video 1). The surgeon can repeat this maneuver 2 to 3 times, being attentive to avoid constriction of the ACL stump to maintain blood supply. In our cases we used 1 suture in each of the 2 ACL bundles. We recommend placing the sutures close to the femoral footprint to avoid an overstretched bundle after reinsertion. The FiberWire is temporarily passed outside through the lateral portal (Fig 6) using an arthroscopic grasper (e.g., KingFisher [Arthrex]). Then, a white No. 2 TigerWire (Arthrex) is passed through the

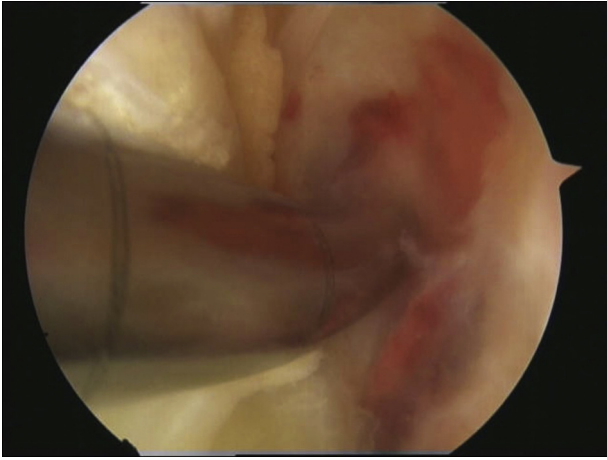


Fig 2. Microfracture awl in femoral footprint (left knee, central-portal view, 90° of knee flexion).

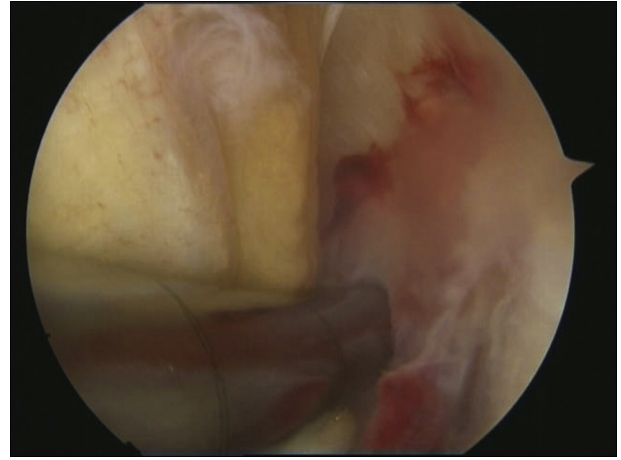


Fig 4. Setting 2 to 3 microfractures in femoral posterolateral footprint (left knee, central-portal view, 120° of knee flexion).

AM bundle from the medial portal (Fig 7). Again, this can be repeated 2 to 3 times if necessary. Finally, all free FiberWire ends are passed through the medial portal with the KingFisher (Figs 8 and 9).

Avoidance of Soft-Tissue Interposition

Care must be taken to avoid soft-tissue interposition during suture passage. We therefore recommend resecting parts of the Hoffa fat pad with a shaver in the anterior part of the knee and behind the medial portal. Furthermore, we recommend pulling both suture ends of 1 FiberWire through the medial portal with the KingFisher to avoid soft-tissue bridges (Video 1).

PushLock Insertion

The hole for the first knotless anchor is drilled in 120° of knee flexion for the PL bundle (Fig 10). Then, the surgeon inserts a 2.9-mm knotless PushLock anchor through the medial portal (Fig 11) to reattach the PL bundle first in 120° of knee flexion, being attentive not

to tighten the suture too much to preserve blood supply to the ACL bundle (Fig 12). The hole for AM bundle reinsertion is drilled in 90° of flexion. The 2.9-mm knotless PushLock anchor for the AM bundle is then inserted. After cutting the No. 2 FiberWire sutures, the surgeon assesses the reattached ACL with a probe (Figs 13 and 14). The sutures are used only to maintain the position of the ACL close to the femoral footprint. Full knee extension is documented arthroscopically. We do not recommend the routine use of an intra-articular suction drainage. After closure of the skin incisions, an extension brace is applied. A detailed description of the operative technique in a cadaveric specimen is provided in Video 1.

Postoperative Treatment

The stitches are removed 10 days after surgery. Partial weight bearing is recommended for 4 weeks. Every patient receives venous thromboembolism prophylaxis

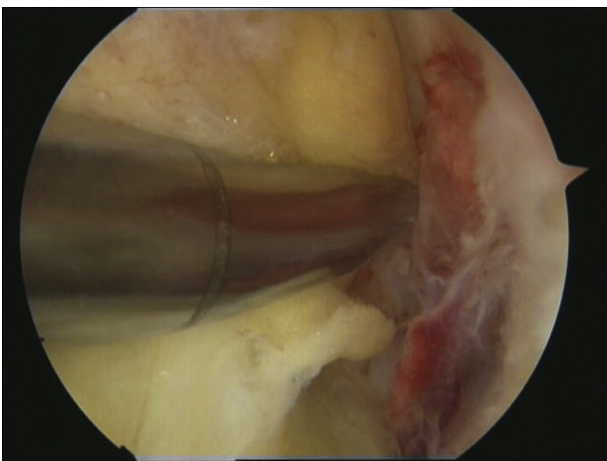


Fig 3. Setting 2 to 3 microfractures in femoral anteromedial footprint (left knee, central-portal view, 90° of knee flexion).

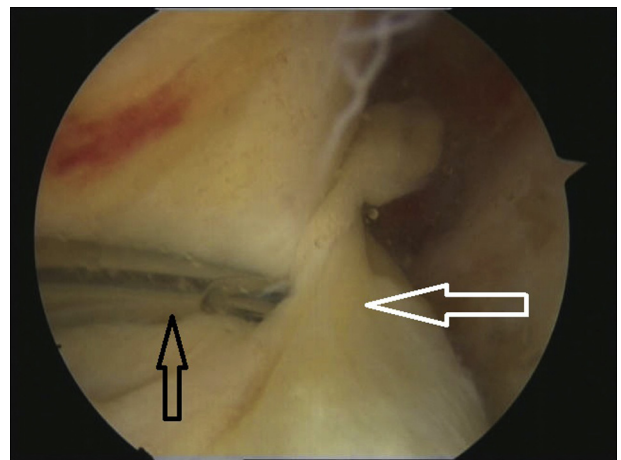


Fig 5. A SutureLasso (black arrow) is passed through the posterolateral bundle (white arrow) (left knee, central-portal view, 90° of knee flexion).

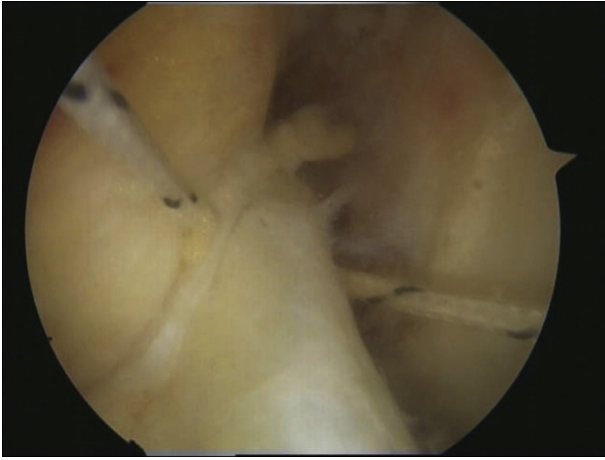


Fig 6. A TigerWire is passed through the posterolateral bundle (left knee, central-portal view, 90° of knee flexion).

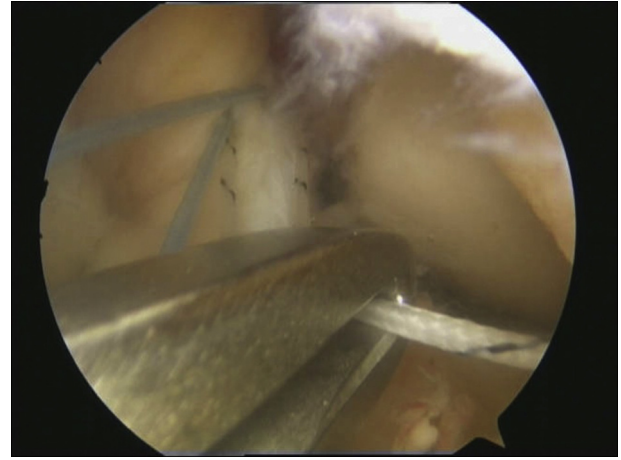


Fig 8. The free end of the TigerWire is passed through the anteromedial portal with a KingFisher (left knee, central-portal view, 90° of knee flexion).

with low-molecular-weight heparin. Our rehabilitation protocol includes isometric muscle activation starting on the first postoperative day. Every patient is seen by a staff physiotherapist once a day for the entire hospital stay. Patients are usually discharged on the first or second postoperative day. We apply a hinged knee brace in the locked position for 4 weeks. In weeks 5 and 6, we allow 30° of knee flexion, and in weeks 7 and 8, we allow 60° of knee flexion. Starting in week 5, closed chain exercises are performed under physiotherapist guidance. After 8 weeks, the brace is removed and range-of-motion exercises, combined with proprioceptive and muscular training, are started.

Non-pivoting sports (Nordic walking, jogging, swimming [except for breaststroke leg movements], and cycling) can be commenced 3 months postoperatively. Contact and pivoting sports can be started 6 months postoperatively.

Discussion

The described operative technique is an option in treating a certain subtype of ACL injury (femoral avulsion-type injury) with a primary repair. We believe the preservation of the patient's original ACL is the greatest advantage of this technique, avoiding many of the known surgical complications of an ACL replacement, such as graft failure or donor-site pain after harvesting autologous tendons. Proprioception deficits have also been well documented in patients who have undergone ACL reconstruction,⁸ highlighting the advantages of ACL preservation further.

We are aware that no long-term results are available and there is no evidence in the literature supporting this technique. As demonstrated by Steadman et al.,^{4,5} a successful healing response after ACL injury might be found in a certain subgroup of patients after proximal

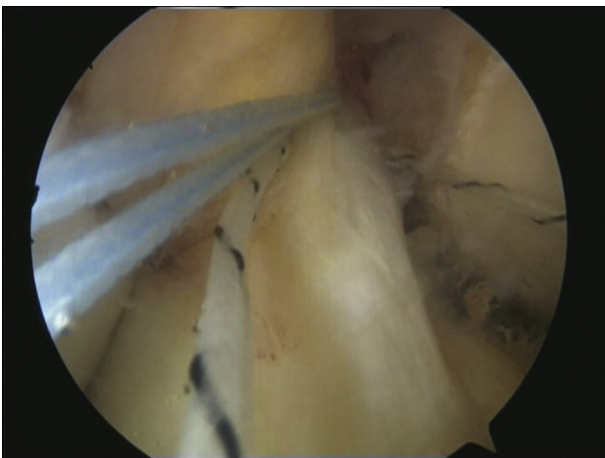


Fig 7. A FiberWire is passed through the anteromedial bundle, and both ends are passed through the medial portal with a KingFisher (left knee, central-portal view, 90° of knee flexion).

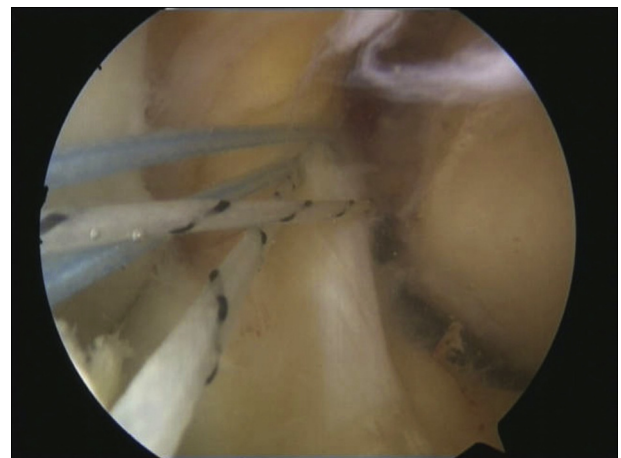


Fig 9. The FiberWire and TigerWire are both outside the anteromedial portal (left knee, central-portal view, 90° of knee flexion).

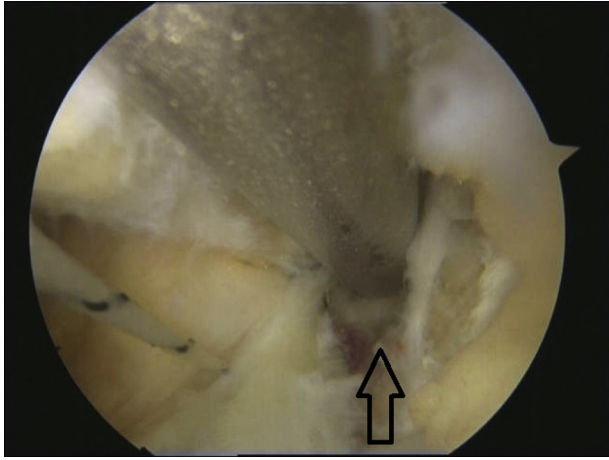


Fig 10. The hole for the PushLock anchor for posterolateral bundle reinsertion is drilled in the posterolateral footprint (arrow) (left knee, central-portal view, 120° of knee flexion).

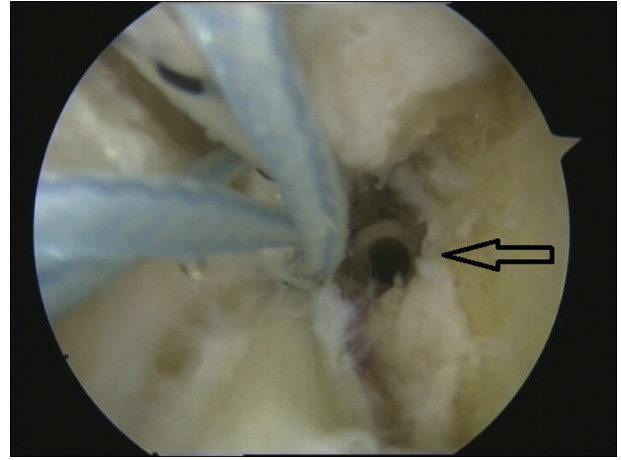


Fig 12. Inserted PushLock (arrow) and reattached posterolateral bundle (left knee, central-portal view, 120° of knee flexion).

ACL tears when bringing the stump close to the femoral footprint operatively, although there is conflicting evidence regarding this procedure. Steadman et al. only treated patients older than 40 years and skeletally immature athletes, with revision rates of 8.9% in the older patients and 23% in the immature patients. Wasmaier et al.⁹ compared the healing response technique versus conservative treatment. The study showed a secondary ACL reconstruction rate of 36% in the healing response group compared with 56% in the conservative treatment group, without a significant difference between the 2 groups. A German study by Jorjani et al.⁶ showed an initial revision rate of 15.1% after the healing response procedure and a secondary revision rate of 9.5% in the first 5 years because of a secondary traumatic event. In this study the post-operative treatment was different: 6 weeks of bracing in full knee extension compared with bracing with increasing the range of motion to up to 90° of knee

flexion in the first 6 weeks (Steadman et al. and Wasmaier et al.). A reason for the different outcomes might be dislocation of the ACL out of its anatomic position during the healing period in patients undergoing the healing response technique or the existence of a gap between the torn end and the femur.

The lack of functional healing of the ACL might also be because of the “hostile” environment the synovial fluid provides, alterations in the cellular metabolism after injury, and intrinsic cell deficiencies.² Murray and Fleming¹⁰ recently described the possibility of a “bio-enhanced” ACL repair to prevent the loss of a provisional scaffold (i.e., scar tissue). The study concluded that the placement of a substitute provisional scaffold and the delivery of growth factors to the scar can restore functional healing. In animal studies such techniques can prevent post-traumatic osteoarthritis

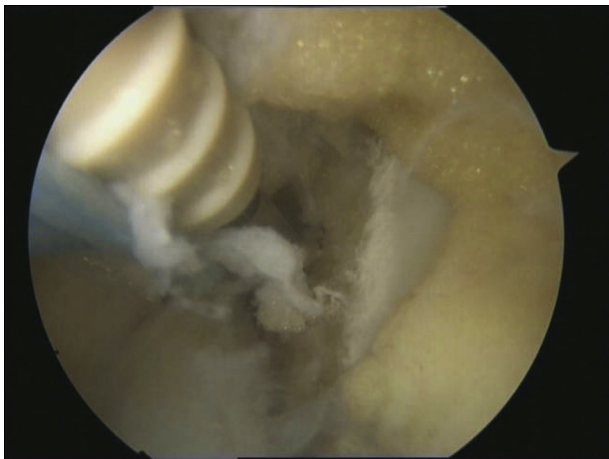

Fig 11. PushLock insertion for posterolateral bundle reinsertion (left knee, central-portal view, 120° of knee flexion).

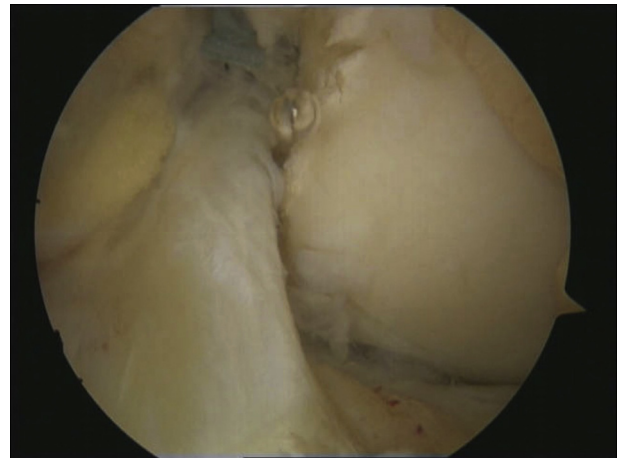


Fig 13. ACL after reinsertion of anteromedial bundle in 90° of knee flexion to femoral anteromedial footprint with additional PushLock anchor (left knee, central-portal view, 90° of knee flexion).

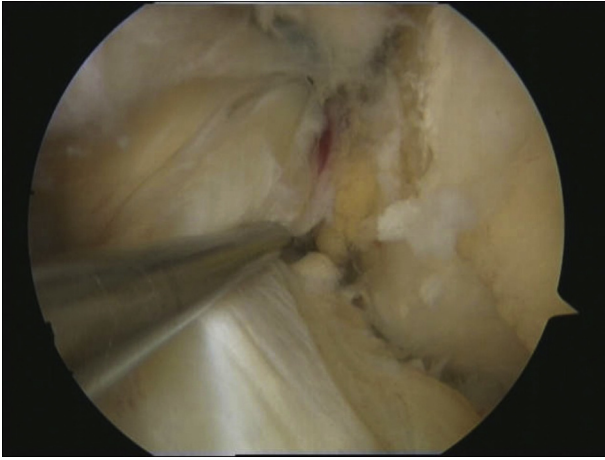


Fig 14. The stability of the reinserted ACL is tested (left knee, central-portal view, 90° of knee flexion).

and lead to equivalent stability and strength of the healed ACL compared with graft replacement. Reattachment of the torn ACL to the posterior cruciate ligament sometimes occurs after femoral avulsion or proximal tears. A recent histologic study using tissue from 5 patients who underwent reattachment of the tibial remnant to the posterior cruciate ligament confirmed the intrinsic healing response of the proximal one-third of the ACL.¹¹ The authors found characteristics of the attached tissue comparable with other spontaneous healing processes such as in the medial collateral ligament. Because only relatively long (approximately 3.5 cm) tibial remnants were reattached, the authors further concluded that contact between the ACL and its surrounding tissue may be a prerequisite for a healing response to occur.

In a clinical trial, Egli et al.¹² advocated a dynamic reinsertion technique combined with microfracturing for primary ACL repair. They reported stable clinical and radiologic healing in 9 of 10 patients. The superiority of dynamic ACL repair compared with the technique described in this article is still a matter of further research. Reattaching the proximal ACL stump to the footprints of the femoral insertion after microfracturing of the region to deliver stem cells and growth factors to the scaffold might be a way to create the best possible conditions to stimulate the healing process.

References

1. Murawski CD, van Eck CF, Irrgang JJ, Tashman S, Fu FH. Operative treatment of primary anterior cruciate ligament rupture in adults. *J Bone Joint Surg Am* 2014;96:685-694.
2. Murray MM. Current status and potential of primary ACL repair. *Clin Sports Med* 2009;28:51-61.
3. Strand T, Molster A, Hordvik M, Krukhaug Y. Long-term follow-up after primary repair of the anterior cruciate ligament: Clinical and radiological evaluation 15-23 years postoperatively. *Arch Orthop Trauma Surg* 2005;125:217-221.
4. Steadman JR, Matheny LM, Briggs KK, Rodkey WG, Carreira DS. Outcomes following healing response in older, active patients: A primary anterior cruciate ligament repair technique. *J Knee Surg* 2012;25:255-260.
5. Steadman JR, Cameron-Donaldson ML, Briggs KK, Rodkey WG. A minimally invasive technique ("healing response") to treat proximal ACL injuries in skeletally immature athletes. *J Knee Surg* 2006;19:8-13.
6. Jorjani J, Altmann D, Auen R, Koopmann C, Lyutenski B, Wirtz DC. Medium- to long-term follow-up after anterior cruciate ligament rupture and repair in healing response technique. *Z Orthop Unfall* 2013;151:570-579 [in German].
7. Kohl S, Evangelopoulos DS, Ahmad SS, et al. A novel technique, dynamic intraligamentary stabilization creates optimal conditions for primary ACL healing: A preliminary biomechanical study. *Knee* 2014;21:477-480.
8. Relph N, Herrington L, Tyson S. The effects of ACL injury on knee proprioception: A meta-analysis. *Physiotherapy* 2014;100:187-195.
9. Wasmaier J, Kubik-Huch R, Pfirrmann C, Grehn H, Bieg C, Eid K. Proximal anterior cruciate ligament tears: The healing response technique versus conservative treatment. *J Knee Surg* 2013;26:263-271.
10. Murray MM, Fleming BC. Biology of anterior cruciate ligament injury and repair: Kappa Delta Ann Doner Vaughn Award Paper 2013. *J Orthop Res* 2013;31:1501-1506.
11. Nguyen DT, Ramwadhoebe TH, van der Hart CP, Blankevoort L, Tak PP, van Dijk CN. Intrinsic healing response of the human anterior cruciate ligament: An histological study of reattached ACL remnants. *J Orthop Res* 2014;32:296-301.
12. Egli S, Kohlhof H, Zumstein M, et al. Dynamic intraligamentary stabilization: Novel technique for preserving the ruptured ACL. *Knee Surg Sports Traumatol Arthrosc* in press, available online 21 March, 2014. doi: 10.1007/s00167-014-2949-x.