

TRANSFER OF AN AUTOIMMUNE NEPHROSIS IN THE
RAT BY MEANS OF LYMPH NODE CELLS*[†]

By EVELYN V. HESS, M.D., CHARLES T. ASHWORTH, M.D., AND
MORRIS ZIFF, M.D.

(From the Departments of Internal Medicine, Rheumatic Diseases Unit, and Pathology,
The University of Texas Southwestern Medical School, Dallas)

PLATES 38 TO 44

(Received for publication, September 5, 1961)

The concept of nephritis as an immunologic disorder has received considerable attention (1). Elevated titers of circulating antibody to the kidney have been demonstrated in human glomerulonephritis (2-6), and low levels of serum complement have also been observed in this disease and in the nephrotic syndrome (7). Experimental glomerulonephritis has been produced by injection of heterologous serum proteins (8, 9), and Germuth (10) has shown a temporal correspondence between the removal of antigen from the circulation and the development of the renal lesion in this type of nephritis. The induction of the nephrotoxic nephritis of Masugi in the rat (11) by injection of anti-rat kidney serum has clearly demonstrated that experimental nephritis may be produced by an immune mechanism. Numerous investigations utilizing the fluorescent antibody method (12, 13) have indicated that the heterologous serum antibody utilized is largely directed at the glomerulus and especially the glomerular capillary wall. That the nephritis is produced by an immunological reaction has also been demonstrated by the parabiotic transfer of this disease (14, 15). It is not possible to conclude from such experiments, however, whether the transfer was dependent upon the effects of serum or cellular antibody.

Heymann and coworkers (16) have produced a nephrotic syndrome in rats by immunization with either autologous or homologous kidney extract in Freund's adjuvant. The disease was characterized by proteinuria, hypercholesterolemia, hyperlipemia and hypoalbuminemia, and histologically by the presence of glomerular epithelial swelling, increased basement membrane material, and protein droplets in the glomerular and tubular epithelium. Support for an immunological mechanism for this disease would be gained from its transfer either by serum or lymph node cells. This paper describes such a trans-

* This work was supported by Grant CRMC-165 from the National Foundation and Grant A-2071 (C3) from the National Institute of Arthritis and Metabolic Diseases.

† Presented in part at the American Rheumatism Association Meeting, December, 1960, (*Arth. and Rheum.*, 1961, 4, 114) and The American Society for Clinical Investigation, May, 1961 (*J. Clin. Inv.*, 1961, 40, 1048).

fer by the injection of lymph node cells into rats rendered immunologically tolerant by pretreatment neonatally with normal rat spleen cells. Attempts to transfer by means of serum were unsuccessful.

Materials and Methods

Animals.—Sprague-Dawley albino rats (Holtzman strain) from closed, random-bred colonies were used for all experiments. Friskies¹ and fresh tap water were provided daily. Preliminary urine determinations were performed on all animals.

Induction of Nephrosis.—Kidneys were removed aseptically from normal, healthy rats weighing 150 to 200 gm. These were washed free of blood and suspended in an equal weight of saline according to the method of Heymann and coworkers (16). Adult rats were injected intraperitoneally every second week with 0.5 ml of a thoroughly emulsified mixture containing 0.1 ml of a low speed supernate of the kidney suspension and 0.4 ml of Freund's adjuvant. Each 0.1 ml of kidney contained approximately 2.5 mg of kidney protein. The Freund's adjuvant was prepared using 8.5 ml bayol F, 1.5 ml aralcel A, and 20 mg killed mycobacteria. The total number of injections required to produce proteinuria varied between four and eight. Equivalent quantities of Freund's adjuvant were injected into control animals.

Chemical Determinations.—

1. Urinary protein was determined by the Shevsky-Stafford method (17). A concentration over 0.2 gm. per cent was considered abnormal.

2. Serum cholesterol was determined in fasting blood by a micro-modification of the Sperry-Webb method (18). The normal range in rats is 30 to 70 mg per cent.

3. Serum proteins were determined by the Ferro and Ham modification of the biuret method (19) and paper electrophoresis was performed using a Spinco electrophoresis apparatus, model R series D. Cholesterol and serum protein determinations listed in the tables were performed on sera obtained at sacrifice.

Serum Transfer.—Serum was obtained by tail vein bleedings from nephrotic rats, and pooled. Varying numbers of 0.5 ml aliquots were given over a 2 week period to nine rats. Serial urine and cholesterol determinations were obtained during the period of injection and for 2 weeks after the last injection.

Transfer Experiments.—The general plan of these experiments is given in Text-Fig. 1 and is similar to that used by Paterson (20) in his successful transfer of allergic encephalomyelitis. Litters of newborn 1-day-old rats were rendered immunologically tolerant by injecting them intraperitoneally with pooled spleen cells from their prospective donors. Kidney and adjuvant injections were started in the donors at 2 weeks postsplenectomy. When the latter had developed nephrosis, lymph nodes were obtained from them and from control donors simultaneously. Cell suspensions were prepared and injected into the recipient rats intravenously. The age of the recipients ranged between 8 and 12 weeks at this time. They were not sacrificed until 5 to 10 weeks after injection of the lymph node cells, however, in order to follow the urinary protein and serum cholesterol levels.

Induction of Tolerance.—Female rats were used as donors to avoid the Eichwald-Silmser phenomenon of sex-linked tissue incompatibility (21). Groups of four to six animals were anesthetized with nembutal. The spleen was delivered through an incision in the left costo-vertebral region, and two-thirds of this organ was removed. Terramycin was added to the drinking water for 10 days postsplenectomy.

The spleens were placed in a Petri dish containing chilled Tyrode-gelatin solution (22),

¹ Ralston Purina Co., St. Louis.

cut into small pieces, and kneaded in a cytosieve² as described by Snell (23). The resulting cell suspension was centrifuged at 1400 RPM for 5 minutes at 4°C and the cells washed with chilled complete Tyrode's solution, containing NaHCO₃. The washed cells were resuspended in a small volume of complete Tyrode's solution containing 7.5 per cent normal rat serum. Viability was tested by the eosin-Y vital staining method (24), and counts of the cell suspension were made. The suspension was then diluted to contain 20 million cells in 0.1 to 0.2 ml. Approximately 20 million cells were injected intraperitoneally into 1 day-old rats or, in some cases, 30 to 40 million cells into 2 to 3 day-old rats. In most experiments, spleen cells pooled from two to four donors were administered to eight to sixteen recipients. "Runting" was observed in four of a total of eighty rats who received spleen cells. These animals were rejected.

Injection of Lymph Node Cells.—Donor rats were exsanguinated, and the cervical, axillary, and popliteal lymph nodes were removed aseptically, trimmed and placed in chilled Tyrode's solution with gelatin. The nodes were teased with a dissecting needle, kneaded through the cytosieve, and the procedure described for the spleen cells carried out. The recipients were injected in the tail vein with 30 to 75 million cells in 0.5 to 1.5 ml.

Histologic Methods.—Tissues were fixed in neutral, buffered formalin. Sections were stained with hematoxylin and eosin, periodic acid-Schiff (PAS) (25), and in some cases with periodic acid-methenamine silver (PA-MS) (26) stain. For electron microscopy, small blocks of kidney cortex were fixed immediately after autopsy in Dalton's chrome osmium fixative (27), dehydrated in alcohol, embedded in methacrylate, and sectioned with a diamond knife at approximately $\frac{1}{40}$ μ . Sections were viewed on grids coated with formvar in an RCA EMU-3 microscope. One micron sections from the methacrylate block, stained with May-Grünwald, were studied comparatively.

Immunofluorescent Studies.—A high titer rabbit anti-rat gamma globulin serum was conjugated with fluorescein isothiocyanate by the method of Marshall and coworkers (28), and absorbed with rat liver and spleen powder. Tissues were rapidly frozen in a dry ice-benzene mixture and stored at -20°C. Sections were cut in a microtome cryostat at an indicated thickness of 4 to 6 microns, fixed on slides, washed with buffered saline, treated for 45 minutes with the conjugated antiserum, again washed, and mounted in buffered glycerin. Specificity was confirmed by the demonstration of inhibition of staining by prior treatment of the sections with unconjugated anti-rat gamma globulin serum. A Reichert fluorescence microscope with an Osram HBO-200 mercury arc lamp was used. Photographs were taken with a Polaroid land camera using Polaroid type 37 speed 3000 film. Exposure time varied from 1 second for positive slides to 20 seconds for negative slides.

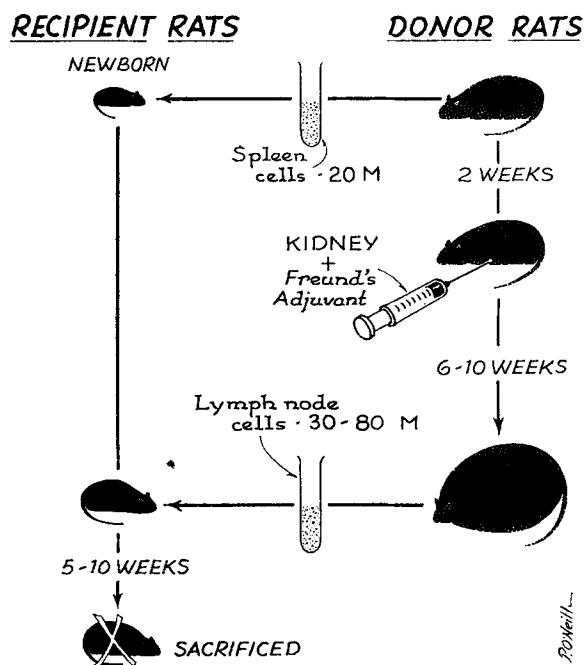
RESULTS

Nephrosis in Donor Animals.—Nephrosis, as evidenced by proteinuria, hypercholesterolemia, and histological renal abnormalities was induced in 80 per cent of the animals injected. Marked ascites developed during the course of the injections but usually subsided within a few weeks. All of thirteen animals followed for 8 months to 1 year continued to manifest marked proteinuria with generalized edema and hypoalbuminemia. Four who were sacrificed at the end of 8 months showed characteristic histological abnormalities. The average urine protein concentration was 0.46 gm per cent, and the mean fasting serum cholesterol level was 108 mg per cent (Table I). Serum albumin levels (Text-fig. 2)

² MacAlaster Bicknell Co., Cambridge, Massachusetts.

averaged 1.9 gm per cent (Table II). The beta globulin fraction was usually increased. The urinary sediment contained hyaline and granular casts. Applying the Student's *t* distribution test, the serum cholesterol and albumin levels and the urinary protein concentrations were significantly different from those obtained in the normal control group.

Twelve normal rats demonstrated no chemical or histological abnormalities except for minimal proteinuria in one animal (Table I). Serum albumin levels (Text-fig. 2) ranged between 2.5 and 3.4 gm per cent with an average of 2.9



TEXT-FIG. 1. Design of transfer experiments.

gm per cent (Table II). Ten rats injected repeatedly with Freund's adjuvant showed only minimal proteinuria in one animal and a cholesterol level over 70 mg per cent in two.

Transfer Experiments.—Potential donor rats were observed for evidence of nephrosis as indicated by proteinuria and hypercholesterolemia, and only those manifesting these changes were selected for the transfer experiments. Of the 12 donors selected, subsequent histological examination demonstrated the presence of marked kidney lesions in ten. The cells from the two animals in whom significant lesions were not found were in each case, however, pooled before injection with cells from two and three animals respectively, in whom lesions were present.

Four separate experiments were carried out (Table III). The number of cells injected varied between 30 and 75 million; at least 90 per cent of the cells were viable. Fourteen of the seventeen recipients survived; two died on the 8th day after transfer, and a third on the 12th day. Thirteen of the surviving fourteen animals manifested proteinuria beginning about 2 weeks after transfer which persisted until the time of sacrifice. At this time, 8 of 13 recipients tested had an increased serum cholesterol level. In eleven recipients examined, serum albumin levels ranged between 0.56 and 2.8 gm per cent with an average of 2.1 gm per cent (Table II; Text-fig. 2). These values correspond well with those of the nephrotic donors and are significantly less than those found in the control

TABLE I
Serum Cholesterol and Urinary Protein Values in Normal and Experimental Animals

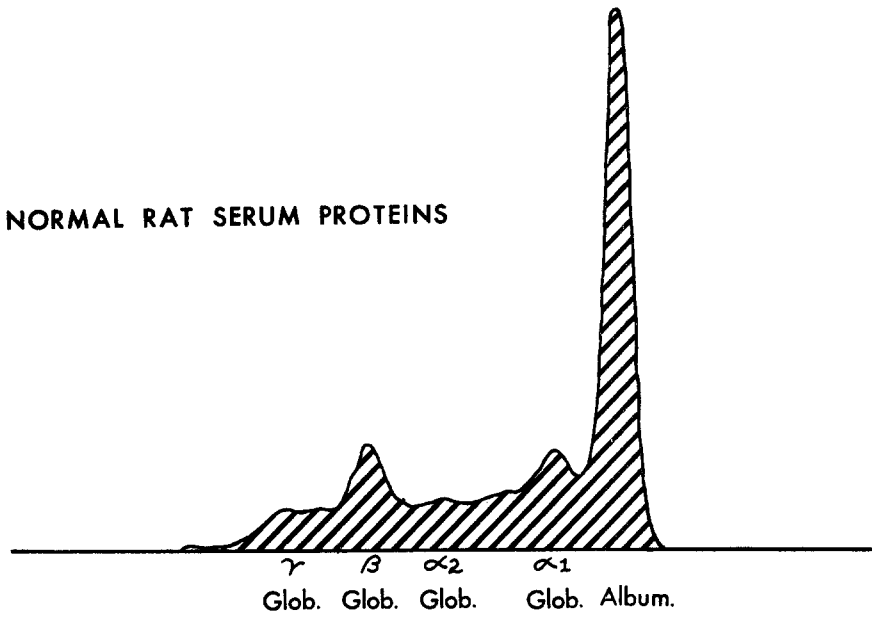
Group	No. of rats	Cholesterol	Urinary protein
		<i>mg per cent</i>	<i>gm per cent</i>
Normal	12	51 (25-64)	0.047 (0.007-0.1)
Kidney and adjuvant injected donors	31	108 (67-376)	0.46 (0.55-1.5)
Freund's adjuvant injected donors	10	65 (50-87)	0.03 (0.005-0.05)
Control recipients	39	55 (27-90)	0.026 (0.003-0.20)
Recipients	13	90 (58-150)	0.45 (0.2-0.8)

groups. Urinary sediments resembled those of the donor animals. Applying Student's *t* distribution test, the serum cholesterol and albumin levels and the urinary protein determinations were significantly different in the experimental and control recipients.

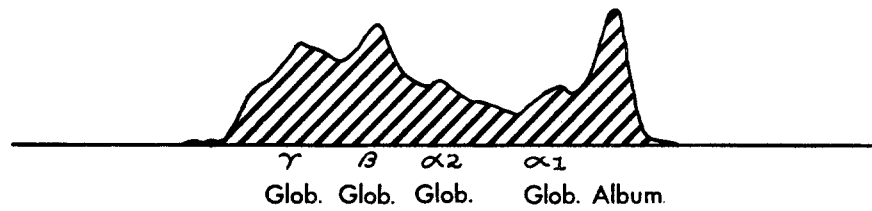
Kidney lesions were present in thirteen of the fifteen recipients examined (Figs. 2 and 4) and were similar to those in the donor animals except for the two rats that died on the 8th day. The latter showed an acute glomerulitis (Fig. 6) indicated by marked hypercellularity and capillary thrombi in the glomeruli and focal tubular necrosis. These lesions appeared to be of recent origin, in contrast to those of the remaining animals in which survival was longer. The severity of the individual glomerular and tubular lesions in the thirteen positive recipients is graded in Table IV.

Control Transfer Experiments.—Control recipients were observed for 5 to 10 weeks following transfer, parallel with the experimental groups. Of five animals

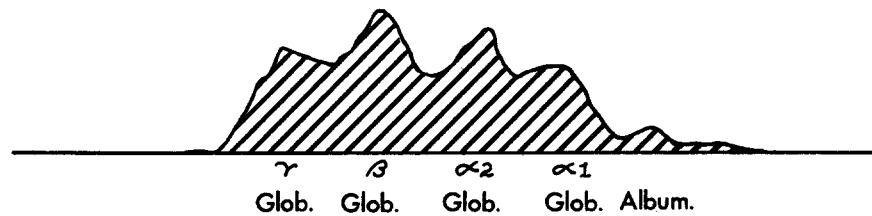
NORMAL RAT SERUM PROTEINS



NEPHROTIC DONOR SERUM PROTEINS



NEPHROTIC RECIPIENT SERUM PROTEINS



TEXT-FIG. 2. Serum electrophoretic patterns of normal, donor, and recipient rat sera.

injected with lymph node cells from normal rats to which they had been rendered tolerant, one showed a mild rise in serum cholesterol to 80 mg per cent (Table V). In six tolerant animals who had received cells from donors injected with adjuvant alone, no abnormal findings were noted. Five non-tolerant recipients had been injected with cells pooled from five nephrotic donors; one had a serum cholesterol of 85 mg per cent and another had scattered focal tubular degenerative changes. Ten animals rendered tolerant to *different* donors had been injected with lymph node cells from five nephrotic donors to which they were not tolerant. One animal had proteinuria, elevated cholesterol level, and mild focal glomerular changes. Two others had cholesterol levels of 72 and 90

TABLE II
Results of Serum Electrophoresis in Nephrotic and Control Rats

Group	No. of rats	Protein concentration, gm per cent			
		Total protein	Albumin	Beta globulin	Gamma globulin
Normal	10	7.3	2.9	1.2	1.1
		7.0-7.8	2.5-3.4	0.94-1.7	0.86-1.6
Control recipients	13	6.7	3.2	1.2	1.0
		5.8-7.4	2.4-4.8	1.0-1.5	0.54-1.3
Nephrotic donors	14	7.1	1.9	2.1	1.4
		5.6-7.8	0.36-2.8	1.0-3.0	0.68-2.5
Nephrotic recipients	11	7.0	2.1	1.6	1.1
		6.0-8.0	0.56-2.8	1.0-2.7	0.55-1.9

mg per cent, respectively. Thirteen rats were injected with spleen cells neonatally but did not receive lymph node cells subsequently. When sacrificed 8 to 12 weeks later, a mild glomerular lesion was observed in one animal.

Serum Transfer Experiments.—Two batches of pooled serum were obtained by serial bleeding from groups of four and five donors, respectively, in whom histological evidence of renal disease was subsequently demonstrated. These were injected in 0.5 ml volumes into 5 and 4 recipients, respectively, over a 2 week period. A total of 4.5 ml was administered to two recipients, 4 ml to four, 3.5 ml to two, and 2 ml to one. Neither proteinuria, hypercholesterolemia, nor histological evidence of disease was found in any of the nine recipients at the end of a 2 week period following the last injection.

Histological Studies

Kidney Lesions.—The renal lesions observed in the kidney and Freund's adjuvant-injected donors and in the nephrotic recipients were similar. The

following description applies to both groups, although in general the glomerular lesions were slightly more marked in the donors.

Light microscopy showed decreased patency of the glomerular capillaries, and an increase in the axillary arranged PAS-positive basement membrane material (Figs. 1 and 2). The degree of involvement was variable, being barely perceptible in some instances, while in others it was sufficiently marked to obliterate the normal capillary network. In PA-MS preparations, the increased basement membrane material was readily observed, and the deposit in these was finely fibrillary rather than homogeneous as with the PAS stain. PAS and

TABLE III
Transfer of Lymph Node Cells from Nephrotic Donors to Prospective Prepared Recipients

Experiment	No. of donors	No. cells injected $\times 10^{-6}$	No. of recipients	No. with proteinuria	No. with hypercholesterolemia	No. of weeks post-transfer	No. with histologic change
1	3	75	5	5	5	10*	4/4‡
2	4	42-60	5	5	3/4‡	10	5
3	1	30	1	1	0	5	0
4	4	45§	3 3	2	0 Died 8-12 day	6	2 2
Total . . .	12	—	17	13	8	—	13

* One animal autopsied 5 weeks post-transfer.

‡ Specimen lost.

§ One animal received 30×10^6 cells.

|| Tissue autolyzed in third animal.

PA-MS-positive droplets of 2 to 4 μ size were also frequently found in the cytoplasm of the glomerular and proximal tubular epithelial cells.

A frequent tubular lesion consisted of atrophy of the lining epithelium, occurring in small groups of proximal convoluted tubules. In these cells, the brush borders were decreased in prominence and the cytoplasm was dark and compact. The nuclei were slightly enlarged, vesicular, and contained prominent nucleoli. Binucleated cells were also more frequent than normal. Hyaline droplets were often encountered in the epithelium of the proximal convoluted tubules (Figs. 3 and 4). Like those in the glomeruli, they were PAS- and PA-MS-positive, varying in size up to 4 μ . In some animals, the proximal convoluted tubules revealed patchy, cystic dilatation, most marked near the corticomedullary junction. In such cases, the tubular lumens were occupied by homogeneous, eosinophilic, PAS-positive material, forming tubular casts. In

these dilated tubules, the lining epithelium was markedly flattened and atrophic. No alterations were observed in the interstitial tissue of the kidneys nor in the blood vessels.

In two animals, sacrificed after two injections of kidney extract with Freund's adjuvant, and in the two recipient animals who died 8 days after transfer,

TABLE IV
Findings in Tolerant Rats Injected with Lymph Node Cells from Prospective Nephrotic Donors

Rat No.	Weeks after transfer sacrificed	Urinary proteins	Serum cholesterol	Severity of kidney lesions (grades 1 to 4+)	
				Glomerular	Tubular
		<i>gm. per cent</i>	<i>mg per cent</i>		
1	5	0.36	96	++	++
2	10	0.50	88	+++	++
3	10	0.72	117	++++	++
4	10	0.54	83	+++	++
5	10	0.72	108	*	*
6	10	0.20	58	++	+
7	10	0.20	*	+++	+
8	10	0.57	92	+	+
9	10	0.36	150	++	0
10	10	0.21	77	+++	+++
11	5	0.80	70	±	0
12	1‡	—	—	+++	++
13	1‡	—	—	+++	++
14	1½§	—	—		
15	6	0.24	61	+	0
16	6	0.21	Qns.	+	0
17	6	N.D.	70	0	0

N.D., not done.

* Specimen lost.

‡ Rat died on 8th day.

§ Rat died on 12th day

|| Tissue autolyzed.

earlier glomerular lesions were seen. These consisted of glomerular epithelial and endothelial swelling and proliferation, rendering the capillaries ischemic. Occasional intracapillary thrombotic deposits were also seen (Figs. 5 and 6). It would appear that these lesions represented an early acute form of the disease leading to death.

In ten animals who received Freund's adjuvant alone, a slight increase in glomerular cellularity was noted in one and moderate glomerular and tubular change was observed in another.

The liver, spleen, and lymph nodes were also examined in the donor and

recipient rats. In animals injected with kidney and Freund's adjuvant, and in others injected with adjuvant alone, granulomatous inflammatory changes were noted on the surface of the liver and occasionally the spleen. Other tissues were normal.

Immunofluorescent Studies.—Staining with conjugated anti-rat gamma globulin showed the presence of gamma globulin localized in the capillary walls of the abnormal glomeruli (Fig. 7), both of donors and recipients. Fluorescence was not noted in the kidneys of the control recipients (Fig. 8).

Electron Microscopy.—Study of the kidneys of five nephrotic donors and five nephrotic recipients revealed changes in the glomeruli and proximal convoluted tubules. These were essentially similar in the two groups. The glomerular capillary loops were partially obliterated by collapse, swelling of

TABLE V
Transfer of Nephrosis by Means of Lymph Node Cells—Controls

Type of control		No. donors	No. cells injected $\times 10^{-6}$	No. recipients	No. with proteinuria	No. with hypercholesterolemia	No. with histologic changes
Donor	Recipient						
Non-injected	Tolerant	6	80	5	0	1	0
F.A. alone	Tolerant	5	45	6	0	0	0
None	Tolerant	0	—	13	0	0/7	1
Kidney + F.A.	Tolerant to different donor	5	35-40	10	1	3/8	1
Kidney + F.A.	Non-tolerant	5	32-75	5	0	1	1
Total.....		21		39	1	5	3

endothelial cells, and excessive folding of the basement membrane (Figs. 9 and 10). The increased PAS-positive material seen in the glomeruli appeared partially to be due to the excessive basement membrane folding. In many areas, however, an actual thickening of this membrane was present. This was sometimes due to nodular projections of its outer surface which formed deposits between the epithelial cell cytoplasmic processes. In other areas, a more diffuse thickening was observed, to as much as two or three times normal.

Some of the glomerular epithelial cells continued to manifest relatively narrow zones of compact and electron-dense cytoplasm, as in the normal state, while others were overtly swollen by light, watery appearing cytoplasm in which mitochondria and endoplasmic reticulum were widely dispersed and scanty.

The pedicels were structurally normal in some areas, but in others they were obliterated and replaced by a continuous sheet of epithelial cytoplasm. Focal cytoplasmic densities were often present within the epithelial cytoplasm,

apparently representing the original sites of the normally dense trabeculae and pedicels. Round or oval, electron-dense bodies measuring up to $2\ \mu$ were also found within the swollen cytoplasm of the epithelial cells (Figs. 11 and 12). These corresponded in distribution, size, and shape with the PAS-positive droplets seen by light microscopy.

In the proximal convoluted tubules, dilated tubules lined by small cells were occasionally observed. Microvilli were sparse or absent in these tubules. The atrophic cells contained scanty mitochondria and endoplasmic reticulum, and the basal infolding of the cytoplasmic membranes was less prominent than normal. Dense oval bodies up to $2\ \mu$ in diameter were found in the cytoplasm of many of the proximal convoluted tubular epithelial cells. They varied from a finely clumped to almost homogeneous appearance and were uniformly dispersed throughout the tubular epithelial cell cytoplasm, although they were occasionally present in the lumen (Fig. 13). In some instances, several of these bodies were grouped to form larger masses, up to $5\ \mu$ in diameter. These bodies are believed to correspond to the hyaline droplets seen in the proximal convoluted tubular epithelium with light microscopy. No semblance of mitochondrial structure was seen in these bodies.

DISCUSSION

The similarity of the recipient and donor lesions and the presence of proteinuria, hypercholesterolemia, and hypoalbuminemia in the recipients is good evidence that a renal lesion was transferred. Control animals, on the other hand, to which cells were transferred from normal donors or from donors injected with Freund's adjuvant alone, did not develop significant proteinuria or histologic abnormalities, and when cells were transferred from nephrotic donors to recipients who had been rendered tolerant to different donors, only one of ten animals developed proteinuria and histologic changes. Since long-term closed colony bred rats were used, it is not surprising that this occurred in one instance.

Although two of ten donor animals injected with Freund's adjuvant alone had renal lesions, these were mild, and there was no significant evidence of nephrosis in these animals. This is in agreement with the experience of Heymann and coworkers (16). Transfer of cells from this group to tolerant recipients produced no abnormalities in the latter. It would appear, therefore, that the effects of Freund's adjuvant alone are not communicated to the recipients.

The injection of 20 million spleen cells for induction of tolerance resulted in an insignificantly low incidence of the "runting" syndrome. Animals in which this occurred were not used as recipients. No clinical or pathological evidence of runting was observed in any of the experimental or control recipients. There was no evidence, either, that partial splenectomy inhibited the capacity of the donors to develop nephrosis.

The renal lesions developed in the recipient animals were similar on light and electron microscopy to those of the nephrotic donors and correspond to the lesions described by Heymann and coworkers (16). The primary alteration appeared to be in the glomerulus where endothelial swelling and presumably increased permeability to protein occurred. Concomitantly, the glomerular epithelial cells became swollen, resulting in obliteration of the foot processes in some areas. Tubular degenerative changes were present, apparently a result of glomerular injury and decreased blood flow.

The nephrosis induced by repeated injections of kidney extract with Freund's adjuvant is essentially a membranous glomerulonephritis. Although animals sacrificed after two injections showed acute proliferative lesions, the disease appeared to be chronic in nature since histological changes and proteinuria were present up to 9 months after the last injection of antigen in animals receiving the full course of injections. Since the disease can be induced by injection of autologous kidney (16), it may be considered autoimmune in type. The small quantity of kidney protein required supports the argument that an immune mechanism is involved, but the identity of the specific component of kidney tissue responsible for the antigenicity is unknown. That the process is relatively specific for kidney tissue is evident from the work of Heymann and coworkers, who showed that lesions were not produced when lung and muscle extracts were injected, and that only a small percentage of mild lesions was observed when a liver extract was used (16).

A number of observations suggest that the antigen may be derived from basement membrane. Steblay (29) has shown that a renal lesion may be produced in the sheep by injection of glomerular basement membranes from a variety of species. Renal changes have also been produced by injection of antisera to renal basement membrane (30), as well as to lung (31) and placenta (32). According to Krakower and Greenspon (33), however, the relative concentration of nephrotoxic antigens was 10 to 20 times greater in the capillaries of the renal glomerulus than in those of other organs.

In contrast to the nephrotoxic nephritis of Masugi and the foreign protein nephritis most recently studied by Dixon, Feldman, and Vasquez (9) in which serum antibody appears to play a major role, the part played by this type of antibody in the development of the autoimmune nephrosis in the rat is not clear. In the case of the nephrotoxic nephritis, heterologous anti-kidney antibody has been shown to react with an antigen associated with the basement membrane (12, 13, 36). The resulting complex is believed to generate a second antibody in the host which presumably induces the nephritis (15, 34). The foreign protein nephritis, according to Dixon and coworkers (9), depends on the formation of antibody complexes with the foreign protein antigen, in which kidney antigen does not participate. These are taken up by the glomerular endothelial cells (35) and deposited along the capillary basement membrane coin-

cident with the development of subacute and chronic glomerulonephritis. Lange, Wachstein, and McPherson (15) and Ortega and Mellors (36) have demonstrated the localization of gamma globulin on the basement membrane in both of these conditions by the fluorescent antibody technique and have interpreted this to be a consequence of the binding of serum antibody at the site of injury.

Though we have also observed the presence of gamma globulin in the glomerular capillary walls in the kidney and adjuvant-induced nephrosis, the importance of serum antibody in the pathogenesis of this disease is not clear. The occurrence of serum antibody in this condition has been studied by Hunter, Hackel, and Heymann (37). Though many sera produced bands of precipitation with rat kidney extract by the agar double diffusion technique, there was no strict correspondence between the appearance of antibody and the time of onset of the disease. In addition, agglutination of erythrocytes sensitized with kidney antigen was observed with only a minority of nephrotic rat sera and when present, titers were low in magnitude.

The failure of attempts to transfer the disease by means of serum, as reported in this paper and previously by Hunter (38), is further evidence against the significant role of serum antibody in mediating the renal lesion. In our attempts to transfer the disease by means of serum, neither proteinuria nor histological abnormalities were observed after a 2 week period following the last injection of serum from nephrotic donors. The effects of nephrotoxic sera, on the other hand, have usually been manifest within several days.

A precedent for the transfer of autoimmune disease by means of lymph node cells is offered by the successful transfer of allergic encephalomyelitis in the rat by Paterson (20). Since, as pointed out by this author, extended survival of the donor cell line in the recipients is a key factor in the transfer, the recipients in the present experiments were rendered tolerant to the prospective donors by injection neonatally with spleen cells from these animals. Subsequent injection of lymph node cells from nephrotic donors achieved successful transfer presumably because of survival of the donor cell line. It would seem unlikely that another mechanism was operative, such as the transfer of an infectious agent or antigen, since control recipients of cells from kidney and Freund's adjuvant-injected donors, who were either not tolerant or tolerant to other donors, did not develop nephrosis. The extended survival of a donor cell line in irradiated animals has recently been demonstrated (39).

The method of production of kidney and Freund's adjuvant induced nephrosis and its transfer by means of lymph node cells provide good evidence that this disease has an immunological basis. Paterson (20), in considering this type of mechanism with respect to allergic encephalomyelitis, has found it difficult to decide whether cellular or conventional circulating antibody produced by the transferred cells is responsible for the induction of disease in the recipients.

There exists, however, a considerable body of evidence relating transfer by means of lymph node cells to a cellular antibody or delayed hypersensitivity mechanism.

Beginning with the work of Chase (40) and Lawrence (41) on the transfer of tuberculin hypersensitivity, it has been clear that delayed hypersensitivity may be transmitted by transfer of cells. In recent years, also, the availability of Freund's adjuvant has made possible the production of a number of experimental autoimmune diseases in which serum antibody, when present, has not been shown to play a significant role. These diseases, which appear to have their counterparts in man, are thyroiditis (42), allergic encephalomyelitis (43), aspermatogenesis (44), adrenalitis (45), uveitis (46), and most recently, nephrosis in the rat (16). Though serum antibody has been identified in a number of the aforementioned states, attempts to transfer them by means of serum have failed in the case of allergic encephalomyelitis (47), thyroiditis (48), aspermatogenesis (49), and in the present experiments, in the case of nephrosis in the rat. With respect to allergic encephalomyelitis, it has been reported by Paterson that the development of the central nervous system lesion is actually inhibited by the presence of a significant titer of serum antibody (50). The transfer of this disease by means of parabiosis (51) does not, of course, distinguish between the effects of serum antibody and cells.

In a study of allergic thyroiditis in the guinea pig, McMaster, Lerner, and Exum (52) found a better correlation of the occurrence of thyroiditis with a delayed skin reaction to thyroid extract than with the titer of thyroid antibody, and concluded from this that the development of the thyroiditis was related to the presence of delayed hypersensitivity. This interpretation has recently been supported by Felix-Davies and Waksman (53) who transferred experimental thyroiditis in inbred guinea pigs by means of lymph node cells and concluded from this that the early lesions of immune thyroiditis represent a delayed hypersensitivity state.

Since the ability to synthesize conventional antibody may also be transferred by lymph node cells (22), it cannot be concluded with certainty that delayed hypersensitivity, rather than a reaction mediated by serum antibody, is responsible for the development of the experimental diseases mentioned. The possibility exists, to be sure, that the transferred cells may synthesize antibody in high concentration locally in the target organ with resulting injury. It would appear, however, that the weight of evidence favors the hypothesis that serum antibody in the usual sense is not responsible for the pathological changes observed.

The experimental autoallergic diseases mentioned, of which autoimmune nephrosis appears to be an example, constitute a well defined group. As pointed out by Waksman (54), they are induced by a common technique which utilized Freund's adjuvant; they involve specialized tissues, in which the parenchyma is separated from the circulation by well defined physiological barriers; and their lesions conform to a common pattern which may, in fact, represent an immunologic reaction of the delayed type. Clinically and histologically, they appear to offer experimental models for a number of human diseases. If the autoimmune nephrosis here studied in the rat has a parallel in human disease, it would appear, on the basis of the proteinuria, hypercholesterolemia, hypo-

albuminemia, and histologic evidence of basement membrane thickening observed, to be best correlated with membranous glomerulonephritis in man (55). If such an assumption is valid, it seems reasonable that immunological investigation of the latter condition should take into account the role of delayed hypersensitivity in its pathogenesis.

SUMMARY

An autoimmune nephrosis produced in rats by repeated injections of kidney extract with Freund's adjuvant has been transferred by means of lymph node cells to recipient animals rendered tolerant by neonatal injection with spleen cells from prospective donors. Transfer of the disease was manifested in the recipients by the development of proteinuria, hypoalbuminemia, hypercholesterolemia, and histological changes. The latter consisted of glomerular epithelial swelling, increase in basement membrane material and the presence of protein droplets in the glomerular and tubular epithelium. Appropriate control experiments were negative. Attempts to transfer with serum were unsuccessful. The transfer described is believed to provide evidence for an immunological mechanism for kidney and adjuvant induced nephrosis in the rat.

The authors are grateful to Mr. F. Douglas and Mr. E. Saunders for expert technical assistance.

BIBLIOGRAPHY

1. Peters, J. H., and Freedman, P., Immunologic aspects of renal disease, *New England J. Med.*, 1959, **261**, 1166.
2. Lange, K., Gold, M. M. A., Weiner, D., and Simon, V., Auto-antibodies in human glomerulonephritis, *J. Clin. Inv.*, 1949, **28**, 50.
3. Liu, C. T., and McCrory, W. W., Auto-antibodies in human glomerulonephritis and nephrotic syndrome, *J. Immunol.*, 1958, **81**, 492.
4. Brod, J., Pavkova, L., Fencl, V., Hejl, Z., and Kratkova, E., Influence of fasting on immunological reactions and course of acute glomerulonephritis, *Lancet*, 1958, **1**, 760.
5. Kramer, N. C., Watt, M. F., Howe, J. H., and Parrish, A. E., Circulating anti-human kidney antibodies in human renal disease, *Am. J. Med.*, 1961, **30**, 39.
6. Chudomel, V. and Jezkova, Z., Determination of antibodies to kidney tissue, *Lancet*, 1961, **1**, 965.
7. Lange, K., Wasserman, E., and Slobody, L. B., The significance of serum complement levels for the diagnosis and prognosis of acute and subacute glomerulonephritis and lupus erythematosus disseminatus, *Ann. Int. Med.*, 1960, **53**, 636.
8. McLean, C. R., Fitzgerald, J. D. L., Younghusband, O. Z., and Hamilton, J. D., Diffuse glomerulonephritis induced in rabbits by small intravenous injections of horse serum, *Arch. Path.*, 1951, **51**, 1.
9. Dixon, F. J., Feldman, J. D. and Vazquez, J. J., Experimental glomerulonephritis; Pathogenesis of laboratory model resembling spectrum of human glomerulonephritis, *J. Exp. Med.*, 1961, **113**, 899.

10. Germuth, F. G., Jr., Comparative histologic and immunologic study in rabbits of induced hypersensitivity of serum sickness type, *J. Exp. Med.*, 1953, **97**, 257.
11. Masugi, M., Über das Wesen der spezifischen Veränderungen der Niere und der Leber durch das Nephrotoxin bzw. das Hepatotoxin: Zugleich ein Beitrag zur Pathogenese der Glomerulonephritis und der eklampthischen Lebererkrankung, *Beitr. Z. Path. Anat.*, 1933, **91**, 82; Über die experimentelle Glomerulonephritis durch das spezifische Antinierenserum, *Beitr. path. Anat. u. allg. Path.*, 1934, **92**, 429.
12. Hill, A. G. S., and Cruickshank, B., Study of antigenic components of kidney tissue, *Brit. J. Exp. Path.*, 1953, **34**, 27.
13. Mellors, R. C., Siegel, M., and Pressman, D., Analytic pathology: histochemical demonstration of antibody localization in tissues, with special reference to antigenic components of kidney and lung, *Lab. Invest.*, 1955, **4**, 69.
14. Pfeiffer, E. F., Schöffling, K., Sandritter, W., Schroeder, J., Steigerwald, H., and Wolf, L., Studien zur "Übertragung" der Masugi-Nephritis der Ratte: die "Übertragung" durch kurzdauernde Parabiose, *Z. ges. exp. Med.*, 1954, **124**, 471.
15. Lange, K., Wachstein, M., and McPherson, S. E., Immunologic mechanism of transmission of experimental glomerulonephritis in parabiotic rats, *Proc. Soc. Exp. Biol. and Med.*, 1961, **106**, 13.
16. Heymann, W., Hackel, D. B., Harwood, S., Wilson, S. G. F., and Hunter, J. L. P., Production of nephrotic syndrome in rats by Freund's adjuvants and rat kidney suspensions, *Proc. Soc. Exp. Biol. and Med.*, 1959, **100**, 660.
17. Shevky, M. C., and Stafford, D. D., A clinical method for the estimation of protein in urine and other body fluids, *Arch. Int. Med.*, 1932, **32**, 222.
18. Sperry, W. M., and Webb, M., Revision of Schoenheimer-Sperry method for cholesterol determination, *J. Biol. Chem.*, 1950, **187**, 97.
19. Ferro, P. V., and Ham, A. B., "Improved" biuret method for total protein and A/G ratio, *Lab.-Trol. Bull.*, 1955, 101.
20. Paterson, P. Y., Transfer of allergic encephalomyelitis in rats by means of lymph node cells, *J. Exp. Med.*, 1960, **111**, 119.
21. Eichwald, E. J., and Silmsler, C. R., Communication, *Transpl. Bull.*, 1955, **2**, 148.
22. Harris, S., Harris, T. N., and Farber, M. B., Studies on the transfer of lymph node cells, *J. Immunol.*, 1954, **72**, 148.
23. Snell, G. O., A cytosieve permitting sterile preparation of suspensions of tumor cells for transplantation, *J. Nat. Cancer Inst.*, 1953, **13**, 1511.
24. Hanks, J. H., and Wallace, J. H., Determination of cell viability, *Proc. Soc. Exp. Biol. and Med.*, 1958, **98**, 188.
25. McManus, J. F. A., Histological and histochemical uses of periodic acid, *Stain Technol.*, 1948, **23**, 99.
26. Jones, D. B., Glomerulonephritis, *Am. J. Path.*, 1953, **29**, 33.
27. Dalton, A. G., A chrome osmium fixative for electron microscopy, (Abstract), *Anat. Record*, 1955, **12**, 281.
28. Marshall, J. D., Eveland, W. C., and Smith, C. W., Superiority of fluorescein isothiocyanate (Riggs) for fluorescent-antibody technique with a modification of its application, *Proc. Soc. Exp. Biol. and Med.*, 1958, **98**, 898.

29. Steblay, R. W., Nephritis in sheep induced by injection of heterologous glomerular basement membrane and Freund's adjuvant (Abstract), *Fed. Proc.*, 1901, **20**, 37A.
30. Steblay, R. W., and Lepper, M. H., The nephrotoxic properties of rabbit anti-serum prepared by immunizing rabbits with purified human basement membrane or dog basement membrane, *J. Lab. Clin. Med.*, 1955, **46**, 956.
31. CHIKAMITSU, H., Experimentelle studien uber immuncytotoxische glomerulonephritis: 1) Serologische Untersuchungsergebnisse des pneumotoxischen entenimmenserums, *Folia Endocrinol. Japan.*, 1940, **16**, 85.
32. Seegal, B. C., and Loeb, E. N., Production of chronic glomerulonephritis in rats by injection of rabbit anti-rat-placenta serum, *J. Exp. Med.*, 1946, **84**, 211.
33. Krakower, C. A., and Greenspon, S. A., Localization of "nephrotoxic" antigen(s) in extraglomerular tissues: observations including measure of its concentration in certain locales, *Arch. Path.*, 1958, **66**, 364.
34. Kay, C. F., Mechanism of form of glomerulonephritis: nephrotic nephritis in rabbits, *Am. J. Med. Sc.*, 1942, **204**, 483.
35. McCluskey, R. T. and Benacerraf, B., Localization of colloidal substances in vascular endothelium. A mechanism of tissue damage, *Am. J. Path.*, 1959, **35**, 275.
36. Ortega, L. G., and Mellors, R. C., Analytical pathology. IV. Role of localized antibodies in pathogenesis of nephrotoxic nephritis in rat, *J. Exp. Med.*, 1956, **104**, 151.
37. Hunter, J. L. P., Hackel, D. B., and Heymann, W., Nephrotic syndrome in rats produced by sensitization to rat kidney proteins: Immunologic studies, *J. Immunol.*, 1960, **85**, 319.
38. Hunter, J. L. P., Communication, *Proc. Eleventh Annual Conf. Nephrotic Syndrome*, 1959, 149.
39. Porter, K. A., Graft-versus-host reactions in the rabbit, *Brit. J. Cancer*, 1960, **14**, 66.
40. Chase, M. W., The cellular transfer of cutaneous hypersensitivity to tuberculin, *Proc. Soc. Exp. Biol. and Med.*, 1945, **59**, 134.
41. Lawrence, H. S., The cellular transfer of cutaneous hypersensitivity to tuberculin in man, *Proc. Soc. Exp. Biol. and Med.*, 1949, **71**, 516.
42. Rose, N. R., and Witebsky, E., Studies on organ specificity. V. Changes in the thyroid glands of rabbits following active immunization with rabbit thyroid extracts, *J. Immunol.*, 1956, **76**, 417.
43. Kabat, E. A., Wolf, A., and Bezer, A. E., The rapid production of acute disseminated encephalomyelitis in rhesus monkeys by injection of heterologous and homologous brain tissue with adjuvants, *J. Exp. Med.*, 1947, **85**, 117.
44. Freund, J., Lipton, M. M., and Thompson, G. E., Aspermatogenesis in the guinea pig induced by testicular tissue and adjuvants, *J. Exp. Med.*, 1953, **97**, 711.
45. Colover, J., and Glynn, L. E., Experimental iso-immune adrenalitis, *Immunology*, 1958, **1**, 172.
46. Collins, R. C., Experimental studies on sympathetic ophthalmia, *Am. J. Ophth.*, 1949, **32**, 1687.

47. Chase, M. L., A critique of attempts at passive transfer of sensitivity to nervous tissue, in "Allergic" Encephalomyelitis, (M. W. Kies, and E. C. Alvord, Jr., editors), Springfield, Illinois, Charles C. Thomas, 1959, 348.
48. Roitt, I. M., and Doniach, D., Human auto-immune thyroiditis: serological studies, *Lancet*, 1958, **2**, 1027.
49. Freund, J., Thompson, G. E., and Lipton, M. M., Aspermatogenesis, anaphylaxis, and cutaneous sensitization induced in the guinea pig by homologous testicular extract, *J. Exp. Med.*, 1955, **101**, 591.
50. Paterson, P. Y., Harlin, S. M., and Didakow, N. C., Acquired resistance to allergic encephalomyelitis and the role of a serum factor, (abstract), *J. Clin. Inv.*, 1961, **40**, 1069.
51. Lipton, M. M., and Freund, J., The transfer of experimental allergic encephalomyelitis in the rat by means of parabiosis, *J. Immunol.*, 1953, **71**, 380.
52. McMaster, P. R. B., Lerner, E. M., and Exum, E. D., The relationship of delayed hypersensitivity and circulating antibody to experimental allergic thyroiditis in inbred guinea pigs., *J. Exp. Med.*, 1961, **113**, 611.
53. Felix-Davies, D., and Waksman, B. H., Passive transfer of experimental immune thyroiditis in the guinea pig, *Program Am. Rheumatism Assn. Meeting*, New York, June, 1961.
54. Waksman, B. H., Experimental Allergic Encephalomyelitis and the Auto-Allergic Diseases, New York, S. Karger, 1959.
55. Movat, H. Z., and McGregor, D. D., The fine structure of the glomerulus in membranous glomerulonephritis (lipoid nephrosis) in adults, *Am. J. Clin. Path.*, 1959, **32**, 109.

EXPLANATION OF PLATES

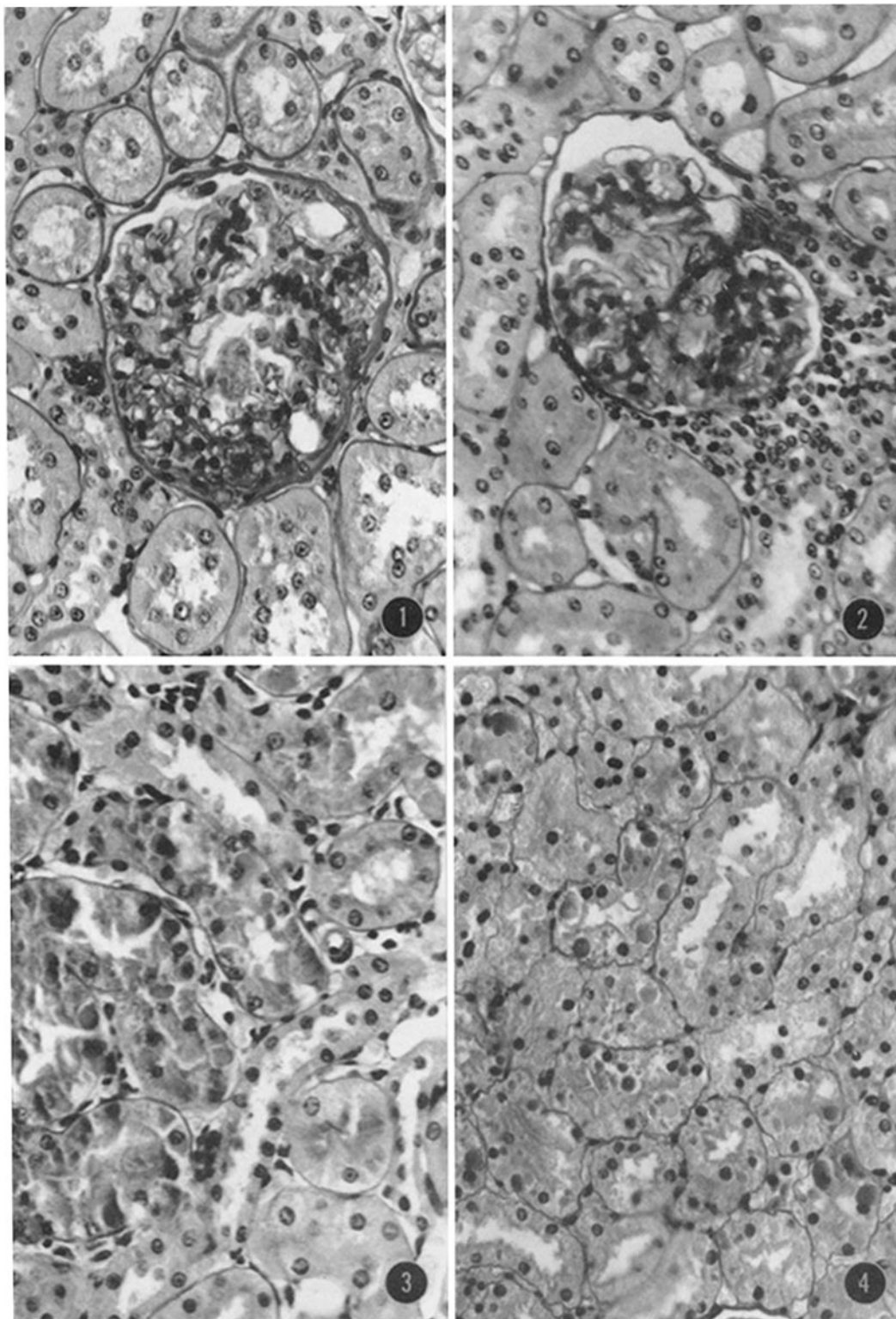
PLATE 38

FIG. 1. Photomicrograph of kidney of donor animal. The glomerulus reveals marked increase in PAS-positive material in the capillary walls; the capillary lumens are decreased in prominence. Periodic acid-Schiff stain. $\times 350$.

FIG. 2. Glomerulus of recipient animal. The glomerular capillary walls are thickened owing to deposition of PAS-positive material; many of the capillary lumens are obliterated. PAS stain. $\times 350$.

FIG. 3. Kidney of donor animal showing proximal convoluted tubules. Numerous large hyaline droplets are present in the epithelial cells. PAS stain. $\times 350$.

FIG. 4. Proximal convoluted tubules in recipient rat. PAS-positive hyaline droplets are present in the tubular epithelial cells. PAS stain. $\times 275$.



(Hess *et al.*: Transfer of nephrosis by lymph node cells)

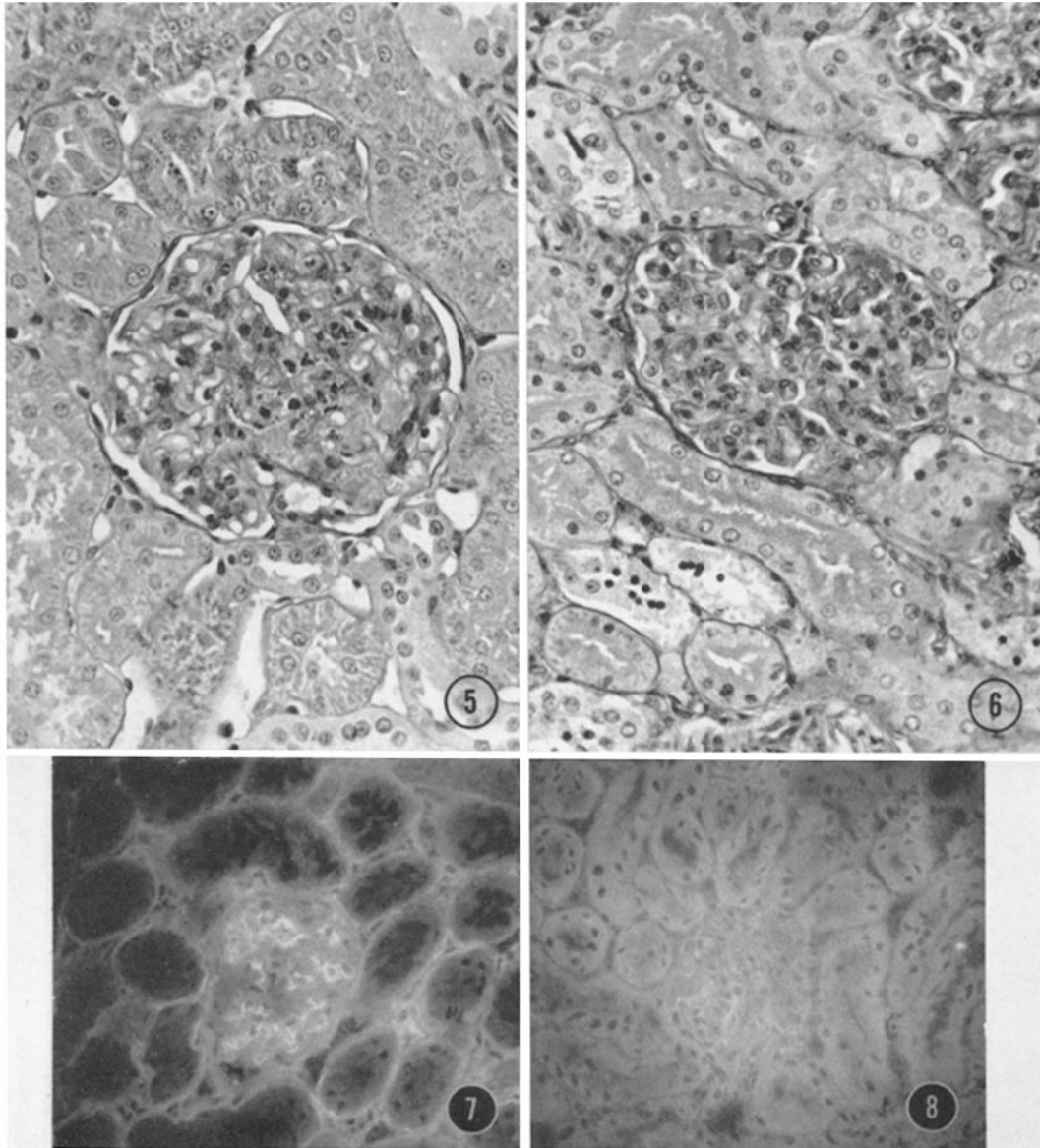
PLATE 39

FIG. 5. Early glomerular lesion in donor animal after injections of kidney and adjuvant. There is hypercellularity of the glomerulus; epithelial and endothelial cells are swollen. The capillary loops show decreased patency. PAS stain. $\times 295$.

FIG. 6. Early glomerular lesion in recipient animal, 8 days after transfer. There is swelling of the glomerular epithelial and endothelial cells. A few neutrophilic leucocytes and small hyaline thrombi are seen in the capillary loops. The patency of the capillary loops is reduced. PAS stain. $\times 295$.

FIG. 7. Kidney section from a nephrotic recipient rat stained with fluorescein-conjugated antibody to rat globulin. Fluorescence is localized in the glomerular capillary wall. There is also a faint fluorescence of the tubular basement membrane. $\times 240$.

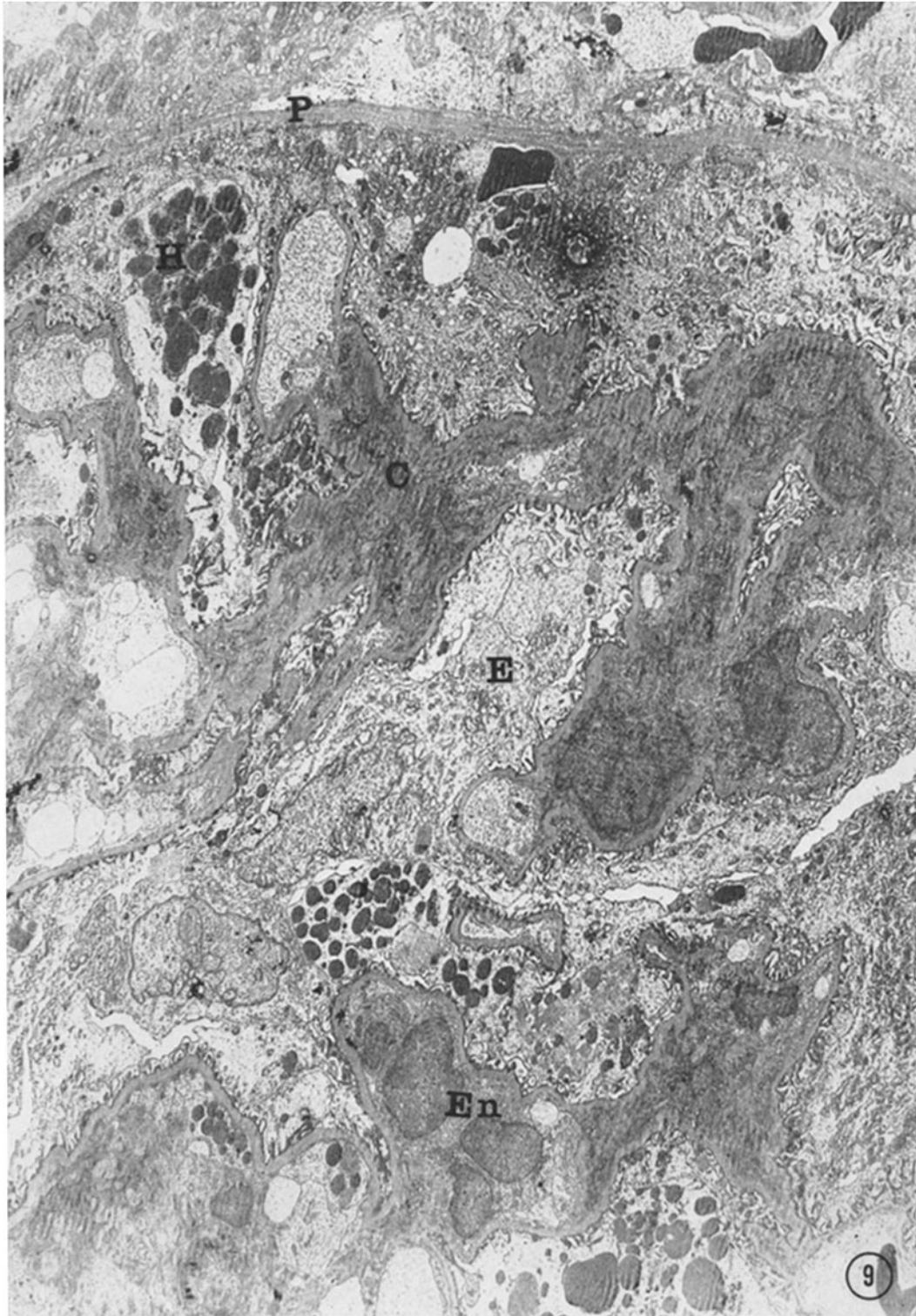
FIG. 8. Kidney section from a control recipient rat showing lack of specific fluorescence. The light appearance is due to the longer exposure time. $\times 240$.



(Hess *et al.*: Transfer of nephrosis by lymph node cells)

PLATE 40

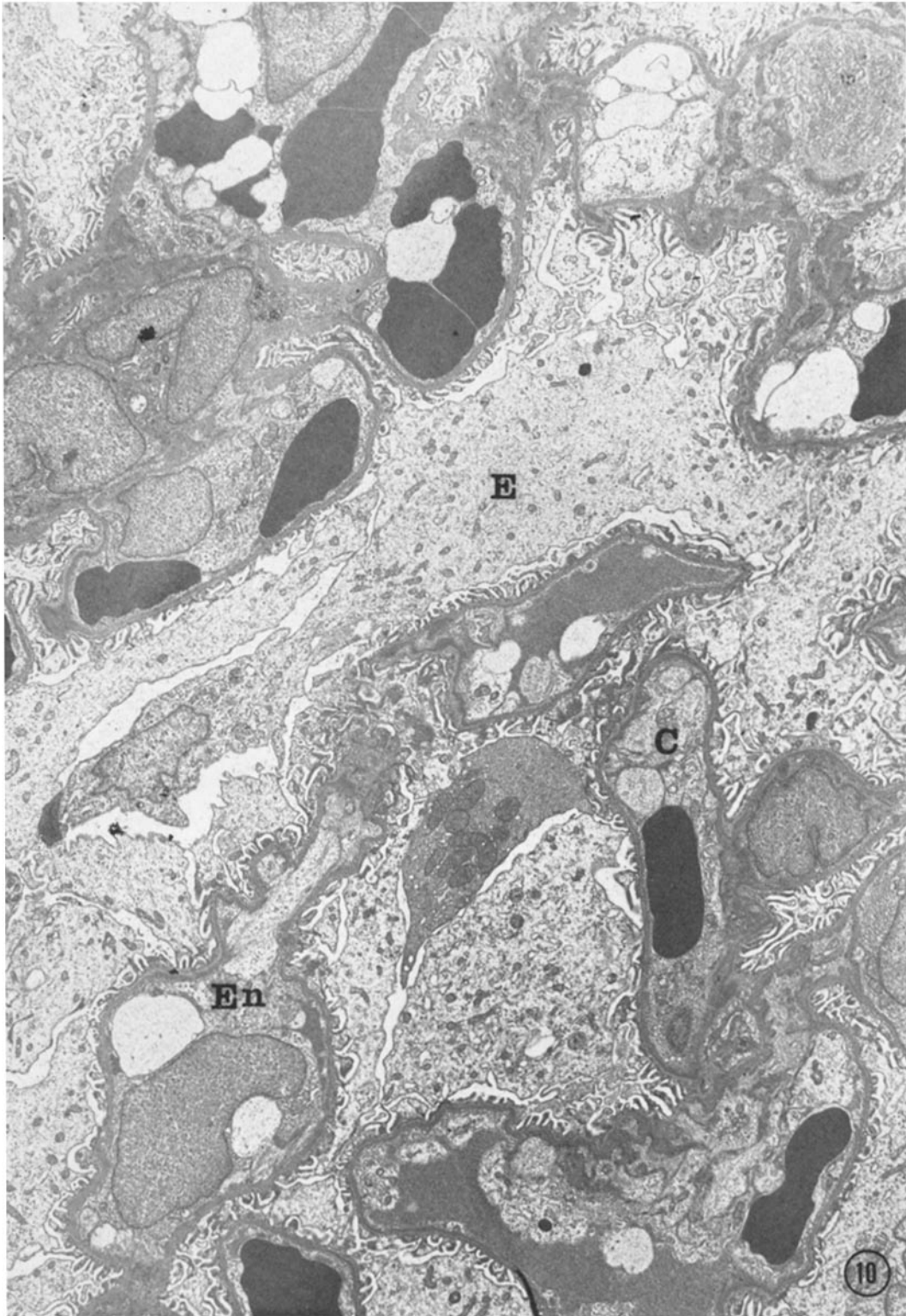
FIG. 9. Electron micrograph of glomerulus from donor animal. The parietal basement membrane (*P*) is shown. Capillary loops (*C*) are collapsed and occupied by swollen endothelial cells (*En*). The epithelial cells (*E*) are swollen, containing watery cytoplasm and many hyaline droplets (*H*). $\times 3500$.



(Hess *et al.*: Transfer of nephrosis by lymph node cells)

PLATE 41

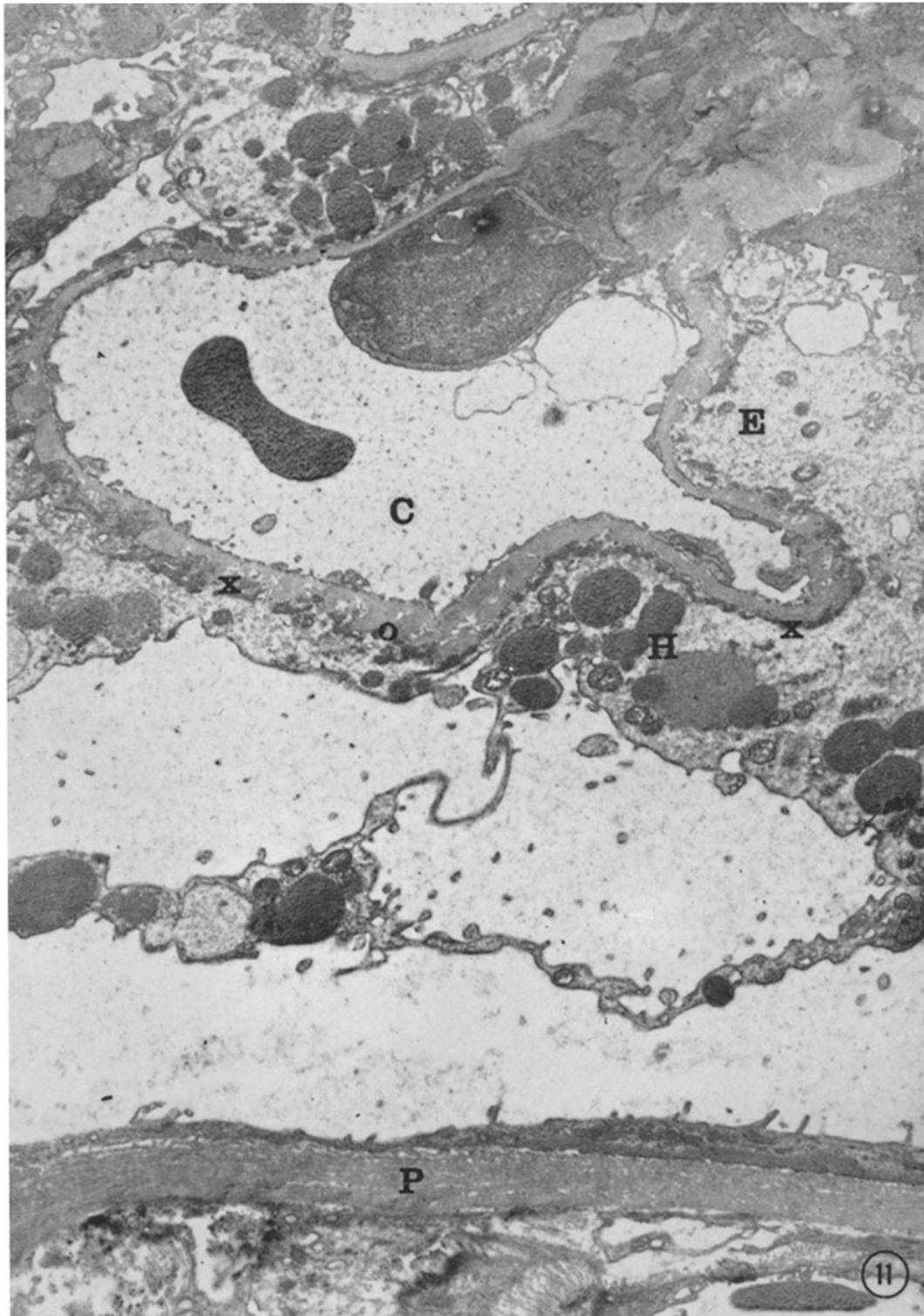
FIG. 10. Glomerulus of recipient animal. There is marked watery swelling of the glomerular epithelial cells (*E*). The endothelial cells (*En*) are also swollen, and the patency of capillary loops (*C*) is reduced. $\times 4300$.



(Hess *et al.*: Transfer of nephrosis by lymph node cells)

PLATE 42

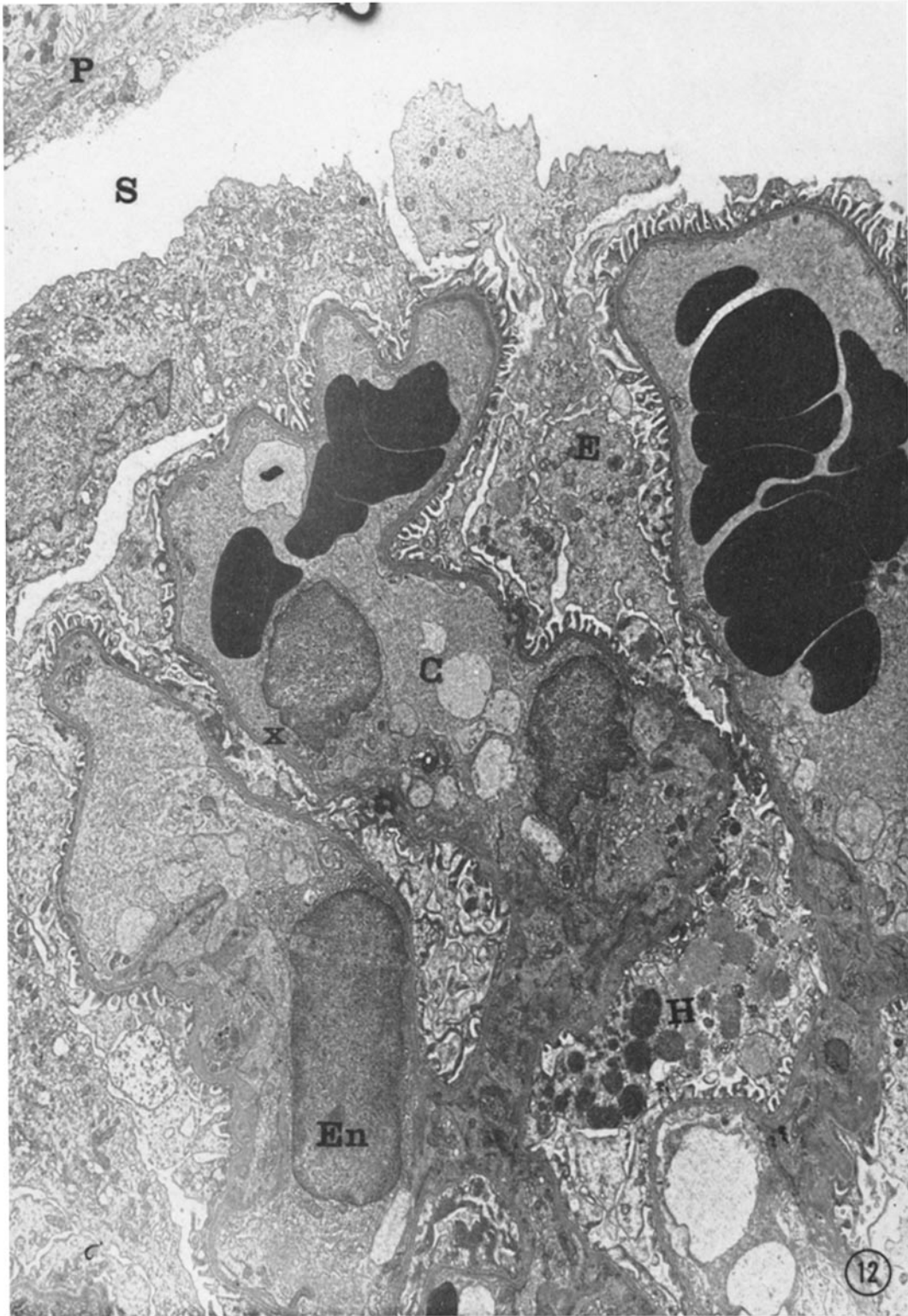
FIG. 11. Glomerulus of donor animal. A portion of the parietal basement membrane (*P*) is present. Glomerular capillaries (*C*) are patent. The epithelial cells (*E*) are swollen, containing watery cytoplasm and many hyaline droplets (*H*) of variable size. The foot processes of the epithelial cells are fused (*X*) in many areas. The basement membrane of the capillary wall is thickened in several areas. On the outer surface are many nodular protrusions extending between the cytoplasmic processes of the epithelial cells (*O*). $\times 8200$.



(Hess *et al.*: Transfer of nephrosis by lymph node cells)

PLATE 43

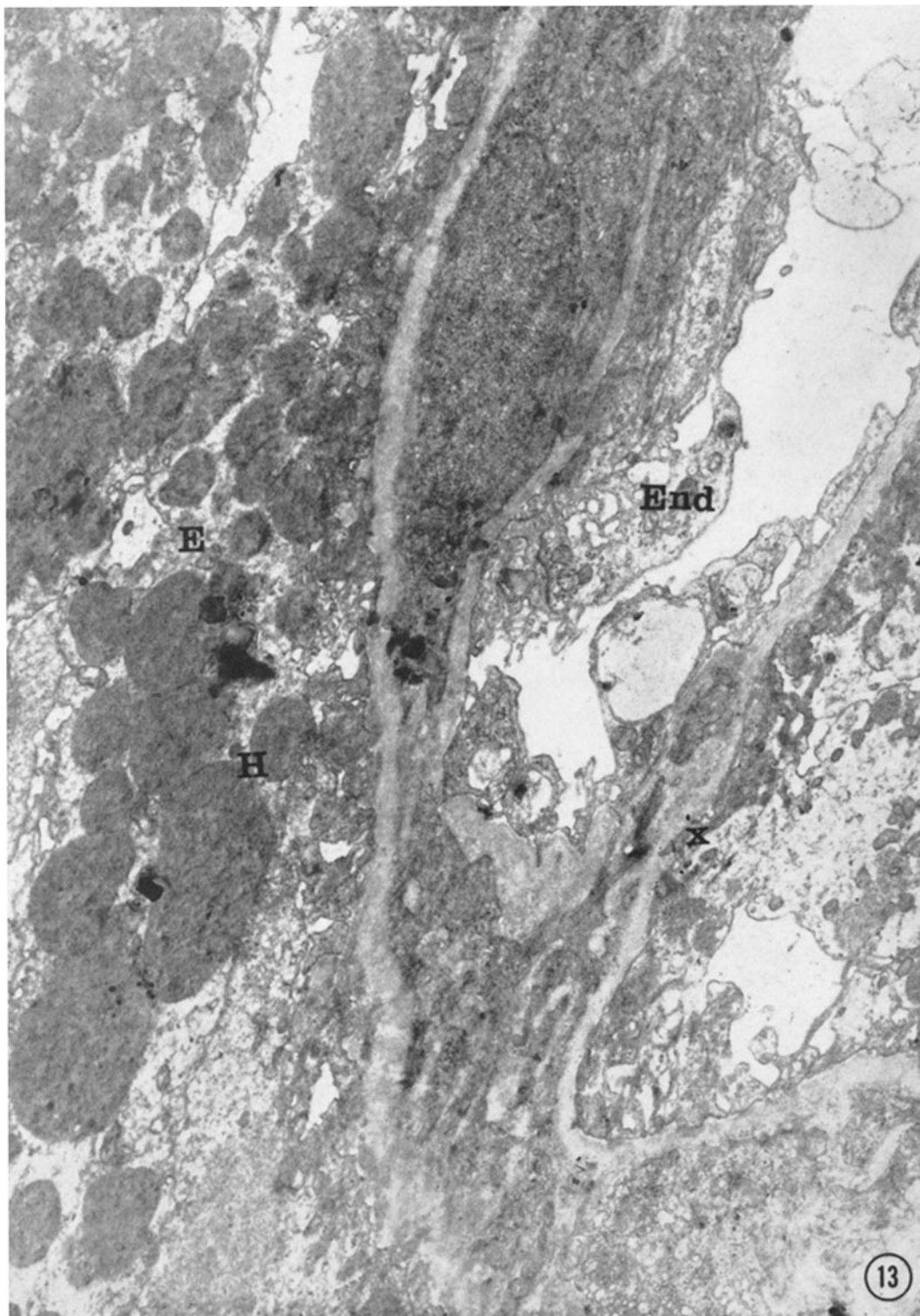
FIG. 12. Glomerulus of recipient animal. The parietal basement membrane (*P*) and glomerular space (*S*) are partially shown. The glomerular epithelial cells (*E*) are swollen and contain pale cytoplasm. In focal areas (*X*) the foot processes are fused. Some swelling of endothelial cells (*En*) is observed. Hyaline droplets (*H*) in different stages of formation can be observed in the cytoplasm of one of the swollen epithelial cells. $\times 4800$.



(Hess *et al.*: Transfer of nephrosis by lymph node cells)

PLATE 44

FIG. 13. Glomerulus of recipient animal. A swollen endothelial cell (*En*) of a tangentially sectioned capillary is present. The glomerular epithelial cells (*E*) are markedly swollen and contain numerous hyaline droplets (*H*). The epithelial cell foot processes are fused in several areas (*X*), although they still contain dense cytoplasmic material. $\times 14,400$.



(Hess *et al.*: Transfer of nephrosis by lymph node cells)