

Received: 2018.10.23
Accepted: 2018.12.17
Published: 2019.02.28

An Unusual Presentation of Nasopharyngeal Carcinoma as Lemierre Syndrome

Authors' Contribution:
Study Design A
Data Collection B
Statistical Analysis C
Data Interpretation D
Manuscript Preparation E
Literature Search F
Funds Collection G

ABCDEF 1 **Tsuyoshi Ito**
ABCD 1 **Hisakazu Majima**
ABCD 2 **Taijiro Ozawa**
ABCD 3 **Matsuyoshi Maeda**
ABCD 4 **Shotaro Iwamoto**
ABCD 4 **Masahiro Hirayama**
ABCDEF 5 **Eiichi Azuma**

1 Department of Pediatrics, Toyohashi Municipal Hospital, Toyohashi, Aichi, Japan
2 Department of Otolaryngology, Toyohashi Municipal Hospital, Toyohashi, Aichi, Japan
3 Department of Pathology, Toyohashi Municipal Hospital, Toyohashi, Aichi, Japan
4 Department of Pediatrics, Mie University Graduate School of Medicine, Tsu, Mie, Japan
5 Department of Clinical Engineering, Suzuka University of Medical Science, Suzuka, Mie, Japan

Corresponding Author: Tsuyoshi Ito, e-mail: ito0112@ss.ij4u.or.jp
Conflict of interest: None declared

Patient: Female, 14
Final Diagnosis: Nasopharyngeal carcinoma
Symptoms: Fever • neck swelling • trismus
Medication: —
Clinical Procedure: Biopsy
Specialty: Oncology

Objective: Challenging differential diagnosis





Background: Clinical presentation of nasopharyngeal carcinoma (NPC) is correlated with the extent of primary and nodal disease. Hence, depending on the anatomical structures affected, the clinical presentation varies accordingly, ranging from non-specific symptoms of epistaxis, unilateral nasal obstruction, and auditory complaints, to cranial nerve palsies. Nodal metastasis in the neck is a frequent clinical finding in nasopharyngeal carcinoma.

Case Report: A female was admitted to the hospital because of fever and trismus with painful swelling in the right neck. Computed tomography (CT) revealed a mass in the nasopharynx with heterogeneous enhancement and multiple swollen lymph nodes in the corresponding neck. Initial biopsies of nasopharyngeal mass and lymph node of the neck revealed nonspecific lymphoid hyperplasia; we administered antibiotics with the provisional diagnosis of bacterial infection, including Lemierre syndrome that is typically defined by the constellation of septic internal jugular vein thrombophlebitis, pulmonary and other septic emboli, and sterile site bacterial infection. However, the patient was refractory to antibiotics over a month of treatments. The third biopsy of the throat lesion revealed NPC and bacterial cultures using the biopsy specimen were negative. She received intensity-modulated radiation therapy and chemotherapy for NPC stage II (TNM staging: T2N1M0). She never developed Lemierre syndrome-like symptoms after chemoradiotherapy.

Conclusions: We report a unique case of NPC presenting with Lemierre syndrome-like symptoms, including prior sore throat, trismus, painful swollen neck, and high fever. Since these symptoms have not been reported in NPC, we included NPC as a differential diagnosis.

MeSH Keywords: Lemierre Syndrome • Nasopharyngeal Neoplasms • Trismus

Full-text PDF: <https://www.amjcaserep.com/abstract/index/idArt/913755>

 1487   2  12



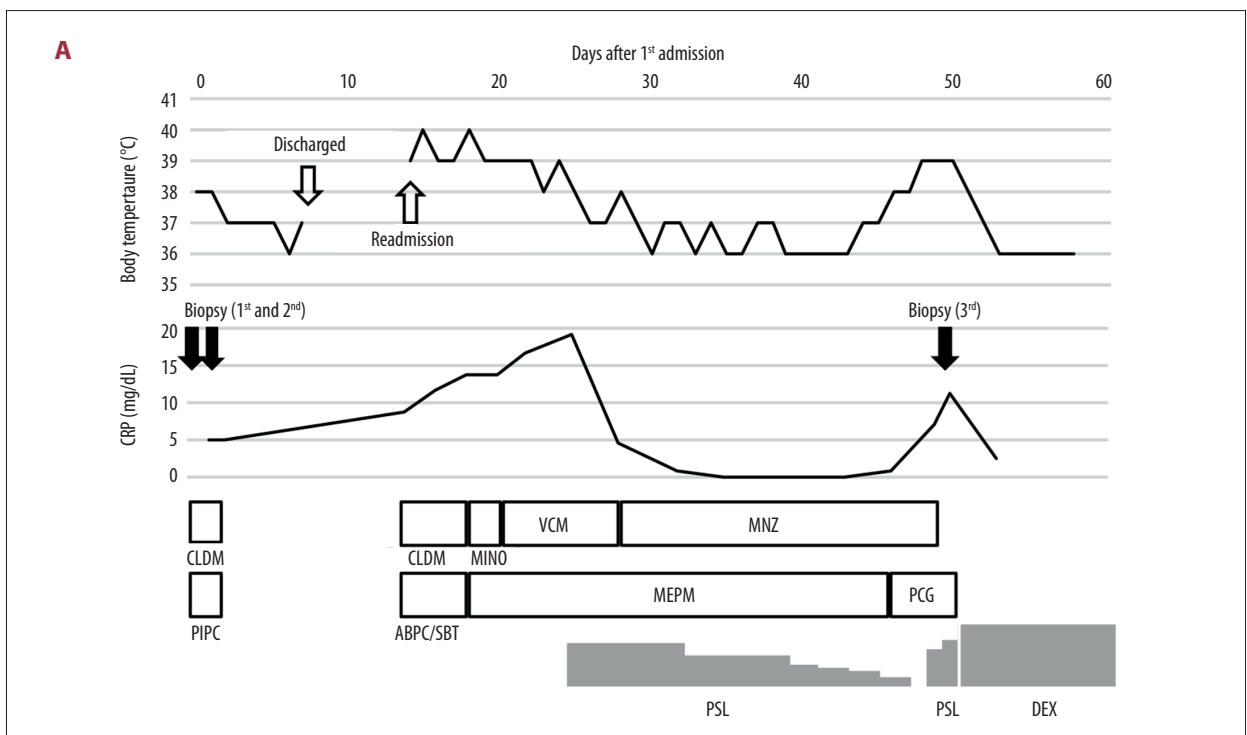
Background

Nasopharyngeal carcinoma (NPC) is a non-lymphomatous, squamous-cell carcinoma that occurs in the epithelial lining of the nasopharynx [1]. Compared with other cancer types, NPC is uncommon, albeit with a very unique pattern of geographical distribution. Worldwide, 86 500 cases of NPC were reported in 2012, accounting for only 0.6% of all cancers diagnosed in that year [2]. Outside of endemic areas in southeast Asia, this tumor is rare. Only 4 children with NPC were reported in 5962 childhood cancers in Japan in a 3-year period (2009–2011, Japan Society of Pediatric Hematology/Oncology). NPC is associated with many etiologic factors, especially Epstein-Barr virus (EBV) infection. Most patients with NPC complain of a lump or mass in the neck and the lumps are usually not tender or painful. A retrospective analysis of 4768 NPC patients identified symptoms at presentation as follows: neck mass (76%), nasal dysfunction (73%), aural dysfunction (62%), headache (35%), diplopia (11%), facial numbness (8%), weight loss (7%), and trismus (3%) [1]. Here, we report a case of NPC with Lemierre syndrome including high fever, sore throat, trismus, and painful cervical swelling. Lemierre syndrome-like symptoms have not been reported so far.

Case Report

A 14-year-old Japanese girl was admitted to the hospital because of fever and trismus with painful swelling in the right neck.

The patient had been well until 2 months before the admission, when she noticed right-sided cervical swelling. A month later, a sore throat and swallowing difficulty developed. She visited a neighboring hospital where cervical lymphadenitis was diagnosed, and she returned home with an oral antibiotic. Computed tomography (CT) revealed a mass in the nasopharynx with heterogeneous enhancement and multiple swollen lymph nodes in the corresponding area of the neck. She was referred to the hospital because of high fever and persistent right-sided painful swelling of the pharynx and soft palate. Her clinical course after admission is shown in Figure 1A. Physical examination was normal except for the mass in the neck and oral cavity. There were no signs of sinusitis or mastoiditis. Laboratory findings were unremarkable except for inflammatory responses; white cell count was $11.1 \times 10^9/L$ with neutrophilia and highly increased C-reactive protein 5.28 mg/dL (reference range 0.00–0.30 mg/dL). The results of serological tests for Epstein-Barr virus were anti-VCA IgG positive, anti-VCA IgM and anti-EBNA IgG positive, suggesting a previous EBV infection. Repeated blood cultures were negative. CT scan of the neck revealed a mass (Figure 1B, 1C). A likely diagnosis on admission was a malignancy, including lymphoma. However, biopsies of the nasopharyngeal mass and lymph node of the right neck revealed nonspecific lymphoid hyperplasia. Therefore, we administered piperacillin and clindamycin with the provisional diagnosis of anaerobic/aerobic bacterial infections. On day 3 of her hospital stay, her fever went down and the trismus was abating. On day 5 of her hospital stay, screening CT scan of the chest demonstrated several nodules in the right



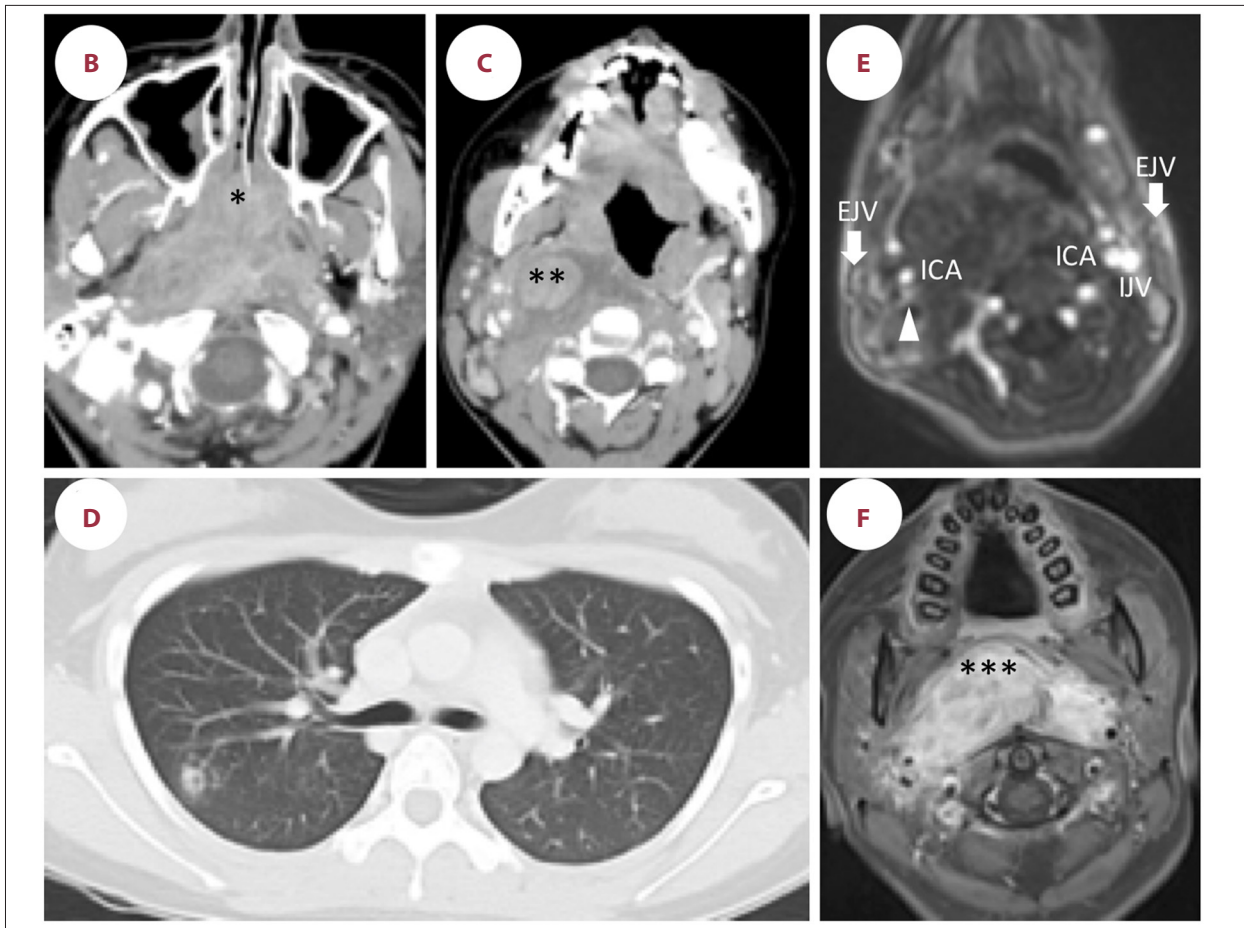


Figure 1. Clinical course and imaging studies. (A) Clinical course. (B, C) Contrast-enhanced axial computed tomography (CT) scan on admission demonstrated a large mass lesion filling the nasopharynx with extension into the right parapharyngeal space and marked swelling of the right deep cervical lymph nodes. (D) CT scan obtained on day 5 after first admission shows a nodule with central cavitation in the right lung. Other nodules are not shown in this slice. (E) Magnetic resonance angiography on hospital day 12 after second admission demonstrated the stenotic right internal jugular vein (arrowhead) and internal carotid artery. (F) Axial T1-weighted contrast material-enhanced magnetic resonance imaging (MRI) at the level of the nasopharynx on hospital day 34 after second admission demonstrated a well-enhanced massive tumor infiltrating into the right and left parapharyngeal space. An asterisk, double asterisks, and triple asterisks indicate the site of first biopsy, second biopsy, and third biopsy, respectively. ICA – internal carotid artery; IJV – internal jugular vein; EJV – external jugular vein; CRP – C-reactive protein; PSL – prednisolone; DEX – dexamethasone; CLDM – clindamycin; PIPC – piperacillin; MINO – minocycline; MNZ – metronidazole; ABPC/SBT – ampicillin/sulbactam; MEPM – meropenem; PCG – benzylpenicillin.

lung (Figure 1D). On day 7 of her hospital stay, magnetic resonance imaging (MRI) of the neck demonstrated a mass encompassing the nasopharynx and deep throat with enlarged lymph nodes. On day 8 of her hospital stay, her symptoms much improved and she was discharged with close follow-up.

A week later, she was readmitted to the hospital because of the recurrence of the initial symptoms with additional sore throat, malaise, and poor appetite. She had neither cough nor chest pain. Laboratory findings revealed inflammatory responses and coagulation assays were normal. Blood cultures were again negative. MRI demonstrated exacerbation of the lesion. A provisional diagnosis of Lemierre syndrome was made

based on the following findings: high fever, sore throat, neck pain, trismus, inflammatory responses in blood, pulmonary nodules suggesting septic emboli, and obstructed internal jugular vein (Figure 1E). There were several pulmonary nodules, and one nodule had a central cavitation (Figure 1E). Ampicillin-sulbactam and clindamycin were started for a possible infection with *Fusobacterium necrophorum* and other aerobic/anaerobic bacteria. Antibiotics were changed from ampicillin-sulbactam and clindamycin to meropenem, minocycline, vancomycin, metronidazole, and penicillin G during the subsequent 3 weeks because the symptoms did not improve (Figure 1A). Meropenem was discontinued after the patient started spiking fevers again. A repeated MRI revealed the stenotic right internal jugular vein

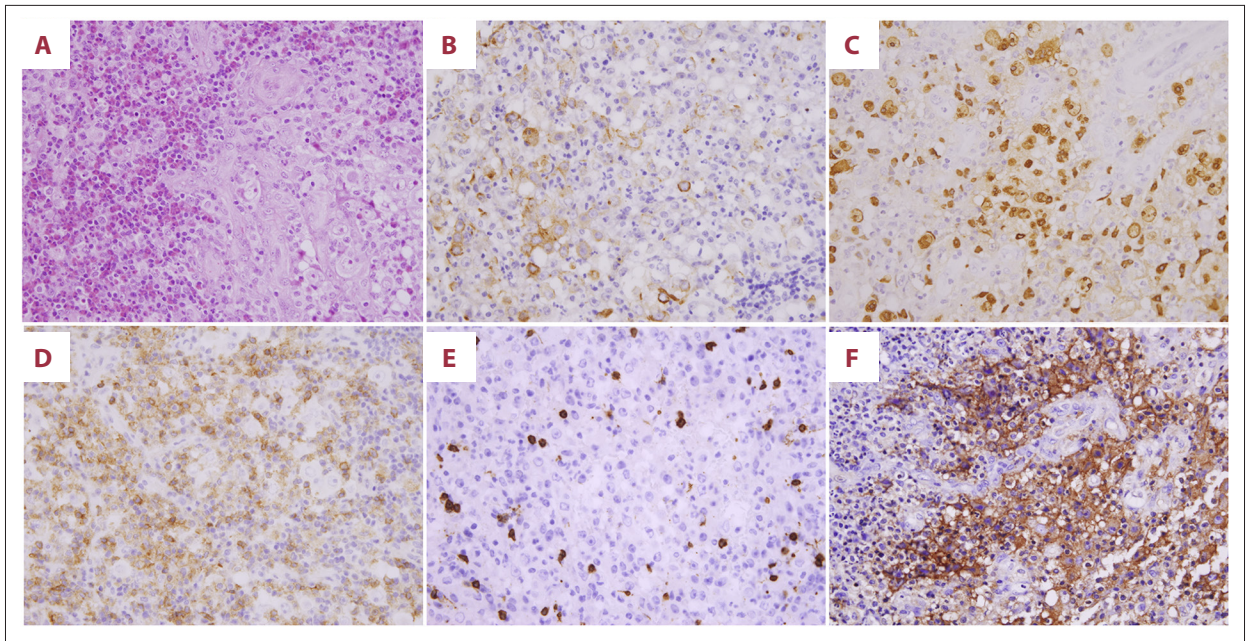


Figure 2. Immunohistochemistry of undifferentiated nasopharyngeal carcinoma. (A) Hematoxylin and eosin staining, (B) cyokeratin, (C) positive *in-situ* hybridization for Epstein-Barr virus-encoded ribonucleic acid, Tumor cells were surrounded by CD4+ T-lymphocytes (D) and CD8+ T-lymphocytes (E), and tumor cells were positive for MHC class I (F) (400× magnification).

and internal carotid artery. All pulmonary nodules disappeared on a follow-up chest CT scan with antibiotics. Since general condition was getting worse, prednisolone was added to decrease the severe systemic inflammatory responses. The patient's fever went down, and the trismus disappeared. A repeated MRI demonstrated mild shrinkage of the lesion. Prednisolone was tapered off at day 33 of her hospital stay. Shortly after the cessation of prednisolone, symptoms and abnormal MRI recurred (Figure 1F). The patient gradually became refractory to prednisolone (Figure 1A). It was possible that the initial negative biopsies might have been due to sample error. On day 37 of her hospital stay, a third biopsy of the throat lesion revealed NPC (cytokeratin-positive, nonkeratinizing, undifferentiated type), that were infiltrated by CD4+ T-lymphocytes, and CD8+ T-lymphocytes (Figure 2). Based on the intraoperative rapid pathological diagnosis and touch preparations of the sample, malignant lymphoma was considered unlikely. Bacterial cultures using the third biopsy sample were negative. On day 47 of her hospital stay, she was referred to another hospital to receive intensity-modulated radiation therapy and chemotherapy for NPC stage II (TNM staging: T2N1M0). She never developed Lemierre syndrome-like symptoms after chemoradiotherapy. She has been in complete remission for the past 3 years.

Discussion

Painless enlargement due to upper cervical lymph node metastases is the most common presenting feature of NPC [3].

The clinical presentation with painful lymph nodes and high fever may be rare in NPC. Our initial diagnosis on admission was Lemierre syndrome, which was based on the patient's clinical symptoms and on imaging studies after obtaining the negative results of biopsies to rule out malignancies.

Lemierre syndrome is a septic thrombophlebitis of the internal jugular vein that typically begins with an oropharyngeal infection. Most cases are caused by fusobacterium, which are normal human microflora of the oropharynx, genitourinary tract, and gastrointestinal tract. Common signs and symptoms of internal jugular vein thrombosis are pain, swelling, or induration at the ipsilateral angle of the mandible of the neck extending along the sternocleidomastoid muscle along with high fevers and trismus. Pulmonary involvement is common because patients can present with bilateral necrotic pleuropulmonary emboli, pleural effusions, empyema, or abscesses [4]. Our patient had a history of sore throat, evidence of septic emboli-like lesions in the lungs (pulmonary nodules), and possible internal-jugular-vein thrombophlebitis, consistent with the diagnosis of Lemierre syndrome. Differential diagnosis of pulmonary nodules includes benign neoplasms, malignant tumors, metastatic lesions, infectious or inflammatory granulomas, vascular lesions, and various infections. The disappearance of pulmonary nodules after administration of antibiotics may suggest Lemierre syndrome. This syndrome is a rare disease in children. Only 5 children out of 124 000 inpatient admissions in the Children's Hospital of Wisconsin had Lemierre syndrome [5].

Nonkeratinizing NPC of the undifferentiated type is histologically distinctive tumors characterized by syncytia of large malignant cells. The cells are frequently intermingled with lymphoid cells in the nasopharynx, giving rise to the introduction of the term lymphoepithelioma [1]. Therefore, it is not surprising that this patient was refractory to antibiotics. Although prednisolone was effective for symptomatic relief in this patient, symptoms recurred instantly without prednisolone. How does prednisolone work in NPC? NPC cells may produce cytokines and chemokines [6], recruiting T-lymphocytes and inflammatory cells [7–9]. In fact, many CD4 and CD8 T-lymphocytes were observed in our patient case (Figure 2). Therefore, it is likely that activated immune cells produced proinflammatory cytokines resulting in high fever that could be suppressed by prednisolone. We also considered the possibility of a paraneoplastic syndrome (PNS) in association with NPC. Diagnostic criteria for PNS have not been well defined and the mechanisms of PNS are not well known. Treating the underlying cancer is generally the most effective therapy for PNS [10]. Recently, Graus et al. recommended diagnostic criteria for paraneoplastic neurological syndromes [11]. We have reviewed the literature of the various cases of PNS related to NPC [12], and Lemierre syndrome-like symptoms had been not reported in NPC. In this case, the mass effect of the tumor and the lymphadenopathy in the neck might have caused neck pain, trismus, and increased the risk

of superimposed infection. This might be why the initial antibiotic treatment was effective transiently. After chemoradiotherapy, the tumor shrinkage might have reduced the mass effect, leading to improvement of symptoms. So, the possibility of PNS might be unlikely because Lemierre syndrome-like symptoms might be more directly related to the local mass effect rather than distant associated symptoms.

Conclusions

When refractory to antibiotic therapy in clinical symptoms of high fever and painful cervical swelling, we should include NPC as a differential diagnosis. In this regard, repeated biopsies may be helpful to make a definitive diagnosis.

Name of Department and Institution where work was done

Department of Pediatrics, Toyohashi Municipal Hospital, Toyohashi, Aichi, Japan

Conflicts of interest

None.

References:

1. Wei WJ, Sham JS: Nasopharyngeal carcinoma. *Lancet*, 2005; 365: 2041–54
2. Chua MLK, Wee JTS, Hui EP, Chan ATC: Nasopharyngeal carcinoma. *Lancet*, 2016; 387: 1012–24
3. Lee AW, Foo W, Law SC et al: Nasopharyngeal carcinoma: Presenting symptoms and duration before diagnosis. *Hong Kong Med J*, 1997; 3: 355–61
4. Kuppalli K, Livorsi D, Talati NJ, Osborn M: Lemierre's syndrome due to *Fusobacterium necrophorum*. *Lancet Infect Dis*, 2012; 12: 808–15
5. Ramirez S, Hild TG, Rudolph CN et al: Increased diagnosis of Lemierre syndrome and other *Fusobacterium necrophorum* infections at a Children's Hospital. *Pediatrics*, 2003; 112: e380
6. Beck A, Pazolt D, Grabenbauer GG et al: Expression of cytokine and chemokine genes in Epstein-Barr virus-associated nasopharyngeal carcinoma: Comparison with Hodgkin's disease. *J Pathol*, 2001; 194: 145–51
7. Chong PY, Chew CT, Chan KC, Ow CK: Tumour infiltrating lymphocytes in nasopharyngeal carcinoma. *Ann Acad Med Singapore*, 1988; 17: 238–42
8. Herait P, Ganem G, Lipinski M et al: Lymphocyte subsets in tumour of patients with undifferentiated nasopharyngeal carcinoma: Presence of lymphocytes with the phenotype of activated T cells. *Br J Cancer*, 1987; 55: 135–39
9. Thomas JA, Iliescu V, Crawford DH et al: Expression of HLA-DR antigens in nasopharyngeal carcinoma: An immunohistological analysis of the tumour cells and infiltrating lymphocytes. *Int J Cancer*, 1984; 33: 813–19
10. Kanaji N, Watanabe N, Kita N et al: Paraneoplastic syndromes associated with lung cancer. *World J Clin Oncol*, 2014; 5: 197–223
11. Graus F, Delattre JY, Antoine JC et al: Recommended diagnostic criteria for paraneoplastic neurological syndromes. *J Neurol Neurosurg Psychiatry*, 2004; 75: 1135–40
12. Toro C, Rinaldo A, Silver CE et al: Paraneoplastic syndromes in patients with nasopharyngeal cancer. *Auris Nasus Larynx*, 2009; 36: 513–20