

Abnormal uterine bleeding in a female with Klippel Trenaunay syndrome

Ashiq Pramchand*

Department of Obstetrics and Gynecology, University of kwaZulu Natal, South Africa.

*Corresponding address: Nelson R. Mandela School of Clinical Medicine, 719 Umbilo Road Congella 4013, South Africa. Email: ashiqpramchand12@gmail.com

How to cite this article: Pramchand A. Abnormal uterine bleeding in a female with Klippel Trenaunay syndrome. Arch Clin Cases. 2022; 9(3):89-93. doi: 10.22551/2022.36.0903.10209

ABSTRACT

Klippel-Trenaunay syndrome is a rare syndrome that is defined by capillary, venous, and lymphatic malformations associated with limb overgrowth. The author describes a 33-year-old SARS-CoV-2 positive South African Black Zulu female known with Klippel Trenaunay syndrome in this case report. Her presentation with abnormal uterine bleeding and multiple cystic lymphangiomas has been rarely described in existing literature, which provides further understanding of the gynecological manifestations of this syndrome.

KEYWORDS: uterine bleeding; Klippel Trenaunay syndrome; SARS-CoV-2 positive

INTRODUCTION

In this case report, the author describes a patient with Klippel-Trenaunay Syndrome (KTS) and abnormal uterine bleeding. Genitourinary symptoms in patients with this syndrome are uncommonly described in the existing literature and are considered rare or extremely rare [1,2]. The patient's improvement in her genitourinary symptoms following the administration of ibuprofen suggests that NSAIDs and conservative medical management may be effective long-term treatment options for abnormal uterine bleeding in patients with this syndrome.

CASE REPORT

A 33-year-old SARS-CoV-2-positive South African Black Zulu female known with Klippel Trenaunay Syndrome since birth was transferred to a tertiary hospital in KwaZulu Natal, Durban, on May 6, 2022, from the main quaternary hospital in the region for isolation as well as step down care (blood transfusion for hemoglobin optimization) owing to chronic abnormal uterine bleeding with continuous, dull lower abdominal pain in the suprapubic region which started at menarche (in 2002). Her usual menstrual bleeding lasts 5-6 days and is described as heavy. She often requires 7-8 vaginal pads for each day of bleeding. Surgical history reveals a previous cervical polypectomy in 2002 for abnormal uterine bleeding and multiple right breast cysts excisions in 2008. She also reports occasional hematuria and urinary hesitancy since 2018 (Figure 1). She is a known patient at the quaternary hospital urogynecology clinic, where she was diagnosed with cervical-uterine prolapse grade III and rupture of the left anterolateral wall of the

cervix with draining pus. These findings were confirmed with CT angiography and pelvic MRI, done in 2018. Chronic medications included tramadol for abdominal pain, hematinics (FeSO₄ and folic acid) for chronic anemia, and ibuprofen (which reportedly alleviated abdominal pain and decreased the volume of her abnormal uterine bleeding such that she now uses 2-3 fewer vaginal pads during each menstrual cycle). She is allergic to paracetamol and morphine. She has no other comorbidities. She is nulligravid, not sexually active, and does not take any contraception. Her family history is unremarkable. She is an unemployed non-smoker of sober habits. She reported no symptoms of COVID-19 infection but tested positive by rapid antigen testing. (Figure 1)

CLINICAL FINDINGS

On physical examination, she was stable with a blood pressure of 142/84mmHg, regular normal volume pulse of 95bpm, temperature of 37.3 degrees Celsius, and respiratory rate of 20bpm. She had multiple classic features of Klippel Trenaunay syndrome (Figure 2). These features include bony hypertrophy of the fingers, occipital bone, and toes; port-wine stains on the right forearm and right anterior thigh; musculoskeletal abnormalities (severe scoliosis and limb-length discrepancy, with an enlarged right lower limb); tortuous left leg veins with evidence of deep vein thrombosis and cystic lymphatic collections in the anterior triangle of the neck as well as the right breast (with evidence of previous surgery).

DIAGNOSTIC ASSESSMENT

Blood results on admission of the patient to the tertiary level hospital revealed a hemoglobin level of 8.7g/dL, a mean corpuscular volume of 66.8fL, and hematocrit of 0.291 L/L following transfusion with one unit of red packed cells reflecting microcytic anemia from chronic per vaginal

Received: June 2022; **Accepted after review:** August 2022; **Published:** September 2022.



1991-02-14	Born in a quaternary hospital in KwaZulu Natal where she was diagnosed with Klippel Trenaunay syndrome.
2002-06-15	Age 13-start of menarche and abnormal uterine bleeding. Cervical polypectomy was done in June. Chronic treatment with hematinics and tramadol was started.
2008-05-08	Excision of multiple right breast cysts
2018-03-19	The patient presented to the urogynaecology clinic at her quaternary hospital with hematuria and urinary hesitance. She was diagnosed with cervical-uterine prolapse grade III and cervical anterolateral wall rupture with draining pus.
2018-03-20	Chronic treatment with ibuprofen 400mg 8 hourly per os was started with reported improvement in abnormal uterine bleeding

Fig. 1. A timeline of the patient's relevant past medical history.

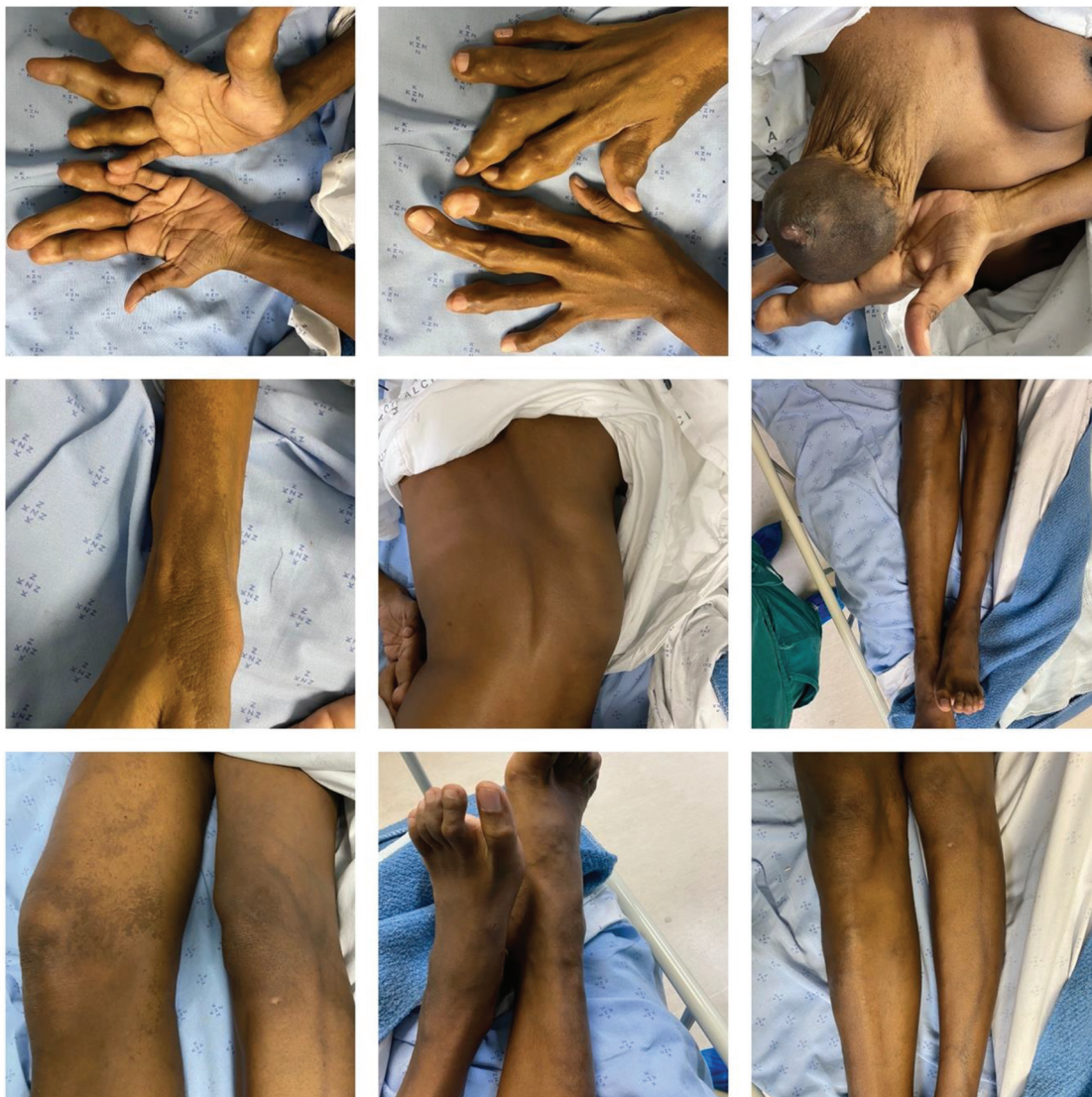

Fig. 2. Characteristic clinical features of Klippel Trenaunay Syndrome identified in the patient (from top left corner to bottom right corner): bony hypertrophy of digits; right breast (post-surgery for excision of cystic lymphangiomas, port wine stains on the right wrist, kyphoscoliosis; limb-length discrepancy; port-wine stain on inner thigh; evidence of deep vein thrombosis on the left leg.

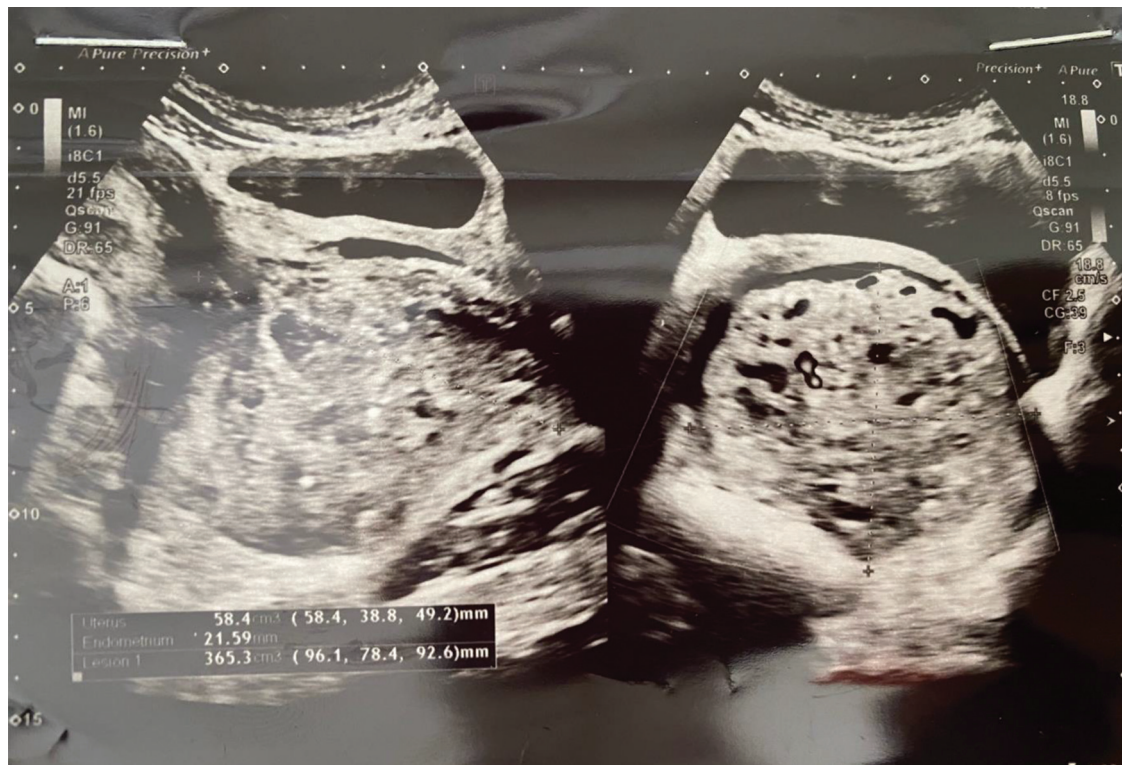


Fig. 3. Ultrasound of the pelvis revealed an anteverted heterogenous uterus +/- 5.8 x 3.9 x 4.9cm with a thickened echogenic endometrium of +/- 2.2cm and a large solid-cystic mass with vascularity (main supply from the endometrial cavity) within the cervix and vagina (+/- 9.6 x 7.8 x 9.3cm). Multiple cysts (<1cm each) were noted in the left ovary (which measured 5.6 x 3.3 x 5.1cm). No cysts were noted in the right ovary which was otherwise normal (size: 3.4 x 3 x 3.1cm).

bleeding and macroscopic hematuria. The platelet count was $350 \times 10^9/L$. The white cell count was $5.50 \times 10^9/L$.

Ultrasound of the pelvis (Figure 3) done in April 2022 revealed an anteverted heterogeneous uterus +/- 5.8 x 3.9 x 4.9cm with a thickened echogenic endometrium of +/- 2.2cm and a large solid-cystic mass with vascularity (main supply from the endometrial cavity) within the cervix and vagina (+/- 9.6 x 7.8 x 9.3cm). The patient refused to undergo another CT angiography/pelvic scan owing to concerns about her multiple medication allergies and the risks of kidney pathology that could be caused by the contrast dye required for the study. Owing to provincial resource limitations, an MRI could only be booked for the patient in March 2023. Multiple cysts (<1cm each) were noted in the left ovary (which measured 5.6 x 3.3 x 5.1cm). No cysts were noted in the right ovary, which was otherwise normal (size: 3.4 x 3 x 3.1cm). A breast ultrasound done during the same month revealed multiple cystic lymphangiomas of varying sizes with homogenous internal echoes and debris. The cystic lymphangiomas were found to communicate with each other and the breast ducts. Multiple enlarged left axillary nodes were identified, with the largest measuring 0.7cm in its short axis. Complicated breast cysts were initially suspected.

■ THERAPEUTIC INTERVENTION

Ibuprofen 400mg 8 hourly per os was a pharmacological intervention administered to the patient in 2018 to alleviate her abdominal pain. The drug also decreased the reported volume of abnormal uterine bleeding during each menstrual cycle.

■ FOLLOW-UP AND OUTCOMES

The patient's hemoglobin was optimized at her district tertiary hospital. After her 2-week isolation in the hospital COVID-19 ward, she was transferred back to her quaternary hospital for follow-up management at her urogynecology clinic. Adherence to ibuprofen use was monitored daily at her tertiary hospital. The patient reported consistent use of ibuprofen during her previous outpatient urogynecology clinic visits.

■ PATIENT PERSPECTIVE

The patient was satisfied that ibuprofen helped improve her abnormal uterine bleeding. She understands that her syndrome is rare, and little is known about it. She still desires a definitive treatment for her abnormal uterine bleeding someday but was hesitant about undergoing surgery and invasive procedures again after being counseled about surgical complications.

■ DISCUSSION

According to the classification published by the ISSVA (International Society for the Study of Vascular Anomalies), KTS was first described in 1900 by French physicians Maurice Klippel and Paul Trenaunay and is defined as capillary, venous, and lymphatic malformations associated with limb overgrowth. Another name for the syndrome is capillary-lymphatic-venous malformation (CLVM), reflecting the changes in those vessels. This syndrome is rare, with an incidence of 1:100000 live births [3,4]. Clinical diagnosis of

the condition is made by the presence of at least 2 of the three classic findings of localized cutaneous capillary malformations, venous abnormalities, and limb hypertrophy [3,4]. All three of these features are present in the patient described in this report. The etiology of this syndrome is linked to somatic mutations in the phosphatidylinositol-4-5-bisphosphate 3 kinase catalytic subunit (PIK3CA) gene, with resulting activation of phosphatidylinositol-3-kinase (PI3K)/protein kinase and cell overgrowth by dysregulation of the mTOR1 pathway [5]. These mutations tend to occur in the embryological stage of development that affects angiogenesis, which is a possible explanation for the vascular and genitourinary malformations seen in this syndrome.

Genitourinary manifestations of this syndrome (such as uterine prolapse, cervical wall rupture, or chronic heavy abnormal uterine bleeding as in the patient described) are uncommonly reported in approximately 9-30% of case reports of KTS. These genitourinary manifestations are considered rare and even extremely rare in patients with KTS and can be severe and potentially life-threatening in KTS patients (such as chronic heavy menstrual bleeding requiring multiple blood transfusions as described in our patient) or a giant uterus in another case report [1,2]. This justifies increasing reporting about genitourinary manifestations of KTS and recommended treatment options so that appropriate interventions can be initiated early to reduce the risk of life-threatening complications of these manifestations. Urogenital involvement in patients with KTS, according to Nam G et al., must be suspected in the presence of significant cutaneous deformity of the external genitalia or hematuria, such as the patient described in this case report.

Interestingly, Nam G et al. reported that patients with cutaneous abnormalities over the trunk or perineum are three times more likely to have visceral vascular anomalies, suggesting that port-wine stains of the perineum are predictive of visceral genitourinary involvement [1]. One case report of heavy menstrual bleeding in patients with KTS showed that the bleeding is controlled mainly by hormonal therapy (e.g., luteinizing hormone-releasing hormone analogs and progestogen) [6]. However, another case report described a patient who was unresponsive to hormonal therapy [7]. In the management of KTS, Jacob et al. reported that 9 of 252 patients with KTS had a pulmonary embolism associated with invasive procedures, pelvic surgical procedures, oral contraceptives, and pregnancy [8]. The use of oral contraceptives and antifibrinolytic agents in treating heavy menstrual bleeding is therefore discouraged in these patients, according to this report. However, a literature review of treatment options for abnormal uterine bleeding in KTS patients by Cucinella et al. revealed that progestogens such as levonorgestrel, antithrombin III, and heparin could be effective in managing this symptom [2]. NSAIDs are a potential preferred medical treatment for heavy menstrual bleeding in KTS patients as endometrium with heavy menstrual bleeding has more prostaglandins than patients with regular menstruation [1,9]. Husmann et al. suggest that most KTS patients with genitourinary malformations will eventually require invasive interventional therapy (e.g., cautery, angioembolization, or surgery) [10]. Surgery is a definitive treatment for heavy menstrual bleeding in KTS patients [8]. Despite these numerous treatment options and the rarity of urogynaecological manifestations of KTS, no clear guidelines for managing urogynaecological manifestations of KTS exist, which provides additional justification for

further reporting about urogynaecological manifestations of KTS [2]. Considering the numerous risks mentioned, as well as stock shortages of hormonal treatment (e.g., luteinizing hormone-releasing hormone analogs, levonorgestrel, heparin, and antithrombin III) at the patient's local clinic, district hospital, and quaternary hospital, NSAIDs were chosen as a more cost-effective and convenient long-term alternative for managing the patient's menstrual bleeding. The patient was hesitant to undergo further invasive procedures after extensive counseling about possible life-threatening bleeding and thus preferred to continue medical management.

Multiple endometrial, cervical, breast and ovarian cystic lymphangiomas in conjunction with genitourinary tract involvement (namely heavy menstrual bleeding and hematuria) in patients with KTS are extremely infrequent in the existing literature [4,11]. These numerous cystic malformations in different parts of the body and urogynaecological clinical features in the patient described in this report provide further evidence for the protean clinical manifestations of KTS, in particular, the potentially life-threatening complications of urogynaecological manifestations of KTS. The pathogenesis of the described cysts may be related to the capillary malformations (port-wine stains) or venous malformations that are characteristically associated with this syndrome. The patient's hematuria and uterine prolapse are suspected to be linked to her cervical rupture or possibly an unidentified vascular malformation in the bladder, which is similar to the case reports described by Husmann et al. [10] Further CT angiography/CT pelvic scans, which the patient refused, may have helped clarify the underlying cause of the patient's hematuria.

■ CONCLUSION

Uro-gynecological manifestations of Klippel Trenaunay syndrome, such as abnormal uterine bleeding, are described as rare in most of the existing literature, with severe complications for patients that may be life-threatening. Urogynaecological manifestations of KTS are numerous and protean in the few of these cases described. Conservative and medical treatment (such as NSAIDs) measures may be preferred in most cases of treating abnormal uterine bleeding in patients with KTS as they are more cost-effective and readily accessible than many hormonal treatments and surgical interventions in developing countries such as South Africa. However, surgical measures are still definitive treatments for abnormal uterine bleeding in patients with KTS. Further reporting of patients with such urogynaecological manifestations and recommended treatment options can improve the limited knowledge base about the clinical features of this syndrome and guide early intervention of the potentially life-threatening complications.

Acknowledgments

Dr. Lee Naidoo, King Edward Hospital, for proofreading and editing

Declaration of interest

The authors have no competing interests to declare.

Informed consent

Written informed consent was obtained from the patient for publication of this case report and accompanying images.

A copy of the written consent is available for review by the Editor-in-Chief of this journal.

Formatting of funding sources

This research did not receive any specific grant from funding agencies in the public, commercial, or not-for-profit sectors.

■ BIBLIOGRAPHY

1. Nam G, Lee SR, Choi S. Clitoromegaly, Vulvovaginal Hemangioma Mimicking Pelvic Organ Prolapse, and Heavy Menstrual Bleeding: Gynecologic Manifestations of Klippel-Trénaunay Syndrome. *Medicina (Kaunas)*. 2021; 57(4). doi: 10.3390/medicina57040366.
2. Cucinella G, Di Buono G, Geraci G, et al. Uterine Involvement in Klippel-Trenaunay Syndrome: A Rare But Relevant Event. Review of the Literature. *Front Surg*. 2022; 9:893320. doi: 10.3389/fsurg.2022.893320.
3. International Society for the Study of Vascular Anomalies©. Classification of vascular anomalies Milwaukee, WI, US: ISSVA; 2014 [cited 2017 abr 18. Available from: <http://www.issva.org/classification>].
4. Srividya Naganathan PT. Klippel Trenaunay Weber Syndrome Stat-Pearls [Internet]. Treasure Island (FL): StatPearls Publishing; 2022 [updated July 19 2022; Available from: <https://www.ncbi.nlm.nih.gov/books/NBK558989/>].
5. Vahidnezhad H, Youssefian L, Uitto J. Klippel-Trenaunay syndrome belongs to the PIK3CA-related overgrowth spectrum (PROS). *Exp Dermatol*. 2016; 25(1):17-19. doi: 10.1111/exd.12826.
6. Rodriguez Peña M, Ovando E. [Klippel-Trenaunay-Weber syndrome with vesical and uterine involvement treated by endoscopic and endovascular routes]. *Medicina (B Aires)*. 2020; 80(1):84-86.
7. Milman T, Murji A, Papillon-Smith J. Abnormal Uterine Bleeding in a Patient with Klippel-Trenaunay Syndrome. *J Minim Invasive Gynecol*. 2019; 26(5):791-793. doi: 10.1016/j.jmig.2018.11.004.
8. Jacob AG, Driscoll DJ, Shaughnessy WJ, et al. Klippel-Trénaunay syndrome: spectrum and management. *Mayo Clin Proc*. 1998; 73(1): 28-36. doi: 10.1016/S0025-6196(11)63615-X.
9. Willman EA, Collins WP, Clayton SG. Studies in the involvement of prostaglandins in uterine symptomatology and pathology. *Br J Obstet Gynaecol*. 1976; 83(5):337-341. doi: 10.1111/j.1471-0528.1976.tb00839.x.
10. Husmann DA, Rathburn SR, Driscoll DJ. Klippel-Trenaunay Syndrome: Incidence and Treatment of Genitourinary Sequelae. *J Urol*. 2007; 177(4):1244-1249. doi: 10.1016/j.juro.2006.11.099.
11. Mneimneh S, Tabaja A, Rajab M. Klippel-Trenaunay Syndrome with Extensive Lymphangiomas. *Case Rep Pediatr*. 2015; 2015:581394. doi: 10.1155/2015/581394.