

# Hiatal hernia uptake of iodine-131 mimicking mediastinal metastasis of papillary thyroid carcinoma

Mahdi Haghghatafshar, Farnaz Khajehrahimi

Department of Nuclear Medicine and Molecular Imaging Research Center, Shiraz University of Medical Sciences, Shiraz, Iran

## ABSTRACT

There are a few case reports of hiatal hernia demonstrating thoracic uptake on I-131 scintigraphy. In this case, high thyroglobulin levels in combination with misinterpretation of I-131 uptake in the mediastinum, led to mismanagement of the patient. Here we present a case of focal I-131 uptake within a hiatal hernia initially mimicking an isolated mediastinal metastasis. There are many potential causes of false-positive I-131 scan result. In this case, adjunctive chest computed tomography and gastroesophageal barium study helped to elucidate the true nature of this I-131 uptake. False-positive findings may be caused by a wide variety of nonthyroidal carcinomas, which can concentrate radioiodine or from skin contamination. Several organs, such as the gastric, salivary glands, renal cyst, pericardial effusion, and ovarian can accumulate I-131. It should be borne in mind as a potential source of false-positive whole-body I-131 imaging.

**Keywords:** False-positive, hiatal hernia, iodine-131, thyroid carcinoma

## INTRODUCTION

Although there are a few case reports about thoracic uptake due to hiatal hernia, but still some patients are mismanaged. In this case, high thyroglobulin (TG) levels in combination with I-131 absorption in mediastinum, led to misvaluation of the patient. Thyroid carcinoma is usually managed by total or near-total thyroidectomy followed by I-131 ablation of any remnant thyroid tissue.<sup>[1]</sup> For this purpose, whole body I-131 scintigraphy has been used for the follow-up of differentiated thyroid carcinoma (DTC) for several decades. A wide spectrum of potentially misleading artifacts can arise in I-131 whole body scans from various anatomical variants and physiological processes as well as several unrelated nonthyroidal disease processes.<sup>[2]</sup> The present case report described a false positive uptake in simultaneous hiatal hernia on postablative iodine-131 scan in a patient with papillary thyroid carcinoma. Considering potential false-positive

iodine-131 scans are critical to avoid the unnecessary exposure to repeated therapeutic doses of radioactive iodine.

## CASE REPORT

A 75-year-old female presented with a history of high risk papillary thyroid carcinoma (T4a, N1, M0, stage IVA) for which she had undergone near total thyroidectomy and received ablative dose of 175 mCi I-131 1 year ago. In posttreatment, whole body scan thyroid remnant tissue without any evidence of regional or distant metastasis was noted. Six months after ablative therapy diagnostic whole body I-131 scan was performed. Forty-eight hours after the oral administration of 5 mCi I-131 scan showed a suspicious zone of radioiodine uptake in the lower mediastinum more prominent on posterior projection. The remainder of the scan was otherwise unremarkable [Figure 1]. Blood analyses revealed TG = 20 ng/ml and 19.5 µ/ml of anti-TG antibody. Baseline TG before ablative therapy was not available. After a 4-week period of thyroid hormone withdrawal and limited ingestion of iodine containing foods, he was hospitalized for the radioiodine therapy for the suspicious mediastinal metastasis and TG = 20 ng/ml. Posttreatment whole body scan showed sustained activity in the same region. Six months later another diagnostic whole body scan was performed and a zone of radioiodine increased uptake was noted in the lower mediastinum that in comparison with the previous whole body scans showed more

### Access this article online

#### Quick Response Code:



Website:  
www.ijnm.in

DOI:  
10.4103/0972-3919.164020

### Address for correspondence:

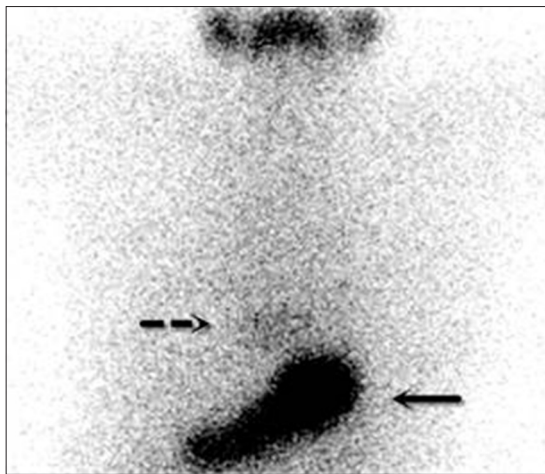
Dr. Mahdi Haghghatafshar, Nuclear Medicine and Molecular Imaging Research Center, Shiraz University of Medical Sciences, Shiraz, Iran.  
E-mail: afsharm@sums.ac.ir

intensity [Figure 2]. Blood analyses revealed TG = 7.3 ng/ml and 7.1  $\mu$ /ml of anti-TG antibody. Further evaluation was done and chest computed tomography scan showed sliding hiatal hernia accompany with a lymph node measuring 9 mm  $\times$  5 mm in paratracheal space and a few small lymph nodes that the largest one is 9 mm  $\times$  6 mm in posterior mediastinum around herniated part of stomach [Figure 3]. Gastroesophageal barium study was done. Significant sliding hiatal hernia and tertiary wave was seen in distal esophagus otherwise there was normal appearance of the mucosa with no filling defect or significant narrowing [Figure 4].

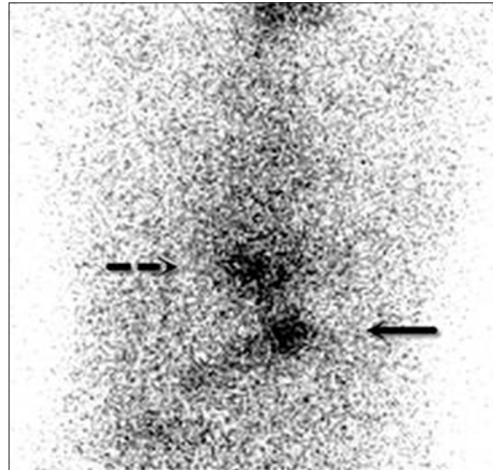
## DISCUSSION

In patients with DTC, the whole-body radioiodine scan is an important part of their follow-up algorithm. The specificity of this exploration for detecting residual or recurrent local and metastatic disease is generally reported to be <90%.<sup>[3]</sup> However, there are many potential causes of false-positive I-131 scan findings.<sup>[4,5]</sup> Radioiodine uptake is not specific for thyroid tissue. It can also be seen in healthy tissues, including contamination,

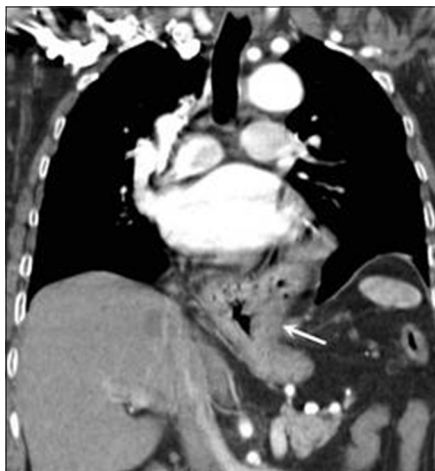
nasal activity, pooling of swallowed saliva, Zenker's diverticulum, Meckel's diverticulum, lactating breasts, inflammatory lung disease, sialadenitis, thymus, liver, and gastrointestinal tract, or in benign diseases, such as cysts and inflammation, or in a variety of benign and malignant nonthyroidal tumors, which could be mistaken for thyroid carcinoma.<sup>[6]</sup> There are occasional reports of a hiatal hernia demonstrating thoracic uptake on I-131 scintigraphy.<sup>[7,8]</sup> This is a cause of a potential false-positive appearance mimicking a pulmonary or mediastinal metastasis. The etiology of this finding is justified by the retention of radioiodinated body fluids (saliva, tears, blood, urine, exudate,



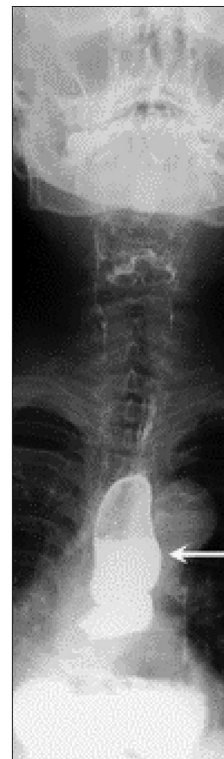**Figure 1:** Iodine-131 whole body scan 6 month after ablative therapy shows suspicious radioiodine accumulation in the lower mediastinum (dashed arrow) and stomach (closed arrow)



**Figure 2:** Iodine-131 whole body scan 6 month after second I-131 therapy shows radioiodine accumulation in the lower mediastinum (dashed arrow) and stomach (closed arrow) in comparison with previous whole body scan shows more intensity



**Figure 3:** Chest computed tomography scan shows sliding hiatal hernia (arrow)



**Figure 4:** Gastroesophageal barium study reveals sliding hiatal hernia

transudate, gastric, mucosal secretions, etc.)<sup>[6]</sup> that is, responsible for false-positive I-131 scan findings. In lower mediastinal region, retention of gastric juice in herniated stomach or gastric volvulus can lead to false-positive I-131 scanning results.<sup>[9-11]</sup> Therefore, recognition of potential false-positive iodine-131 scans especially in the lower mediastinal region is critical to avoid additional costly investigations and unnecessary exposure to repeated therapeutic doses of radioactive iodine.

## CONCLUSION

In this case, high TG level (20 ng/ml) accompanied by mediastinal uptake, misled to unnecessary iodine therapy to the patient. Hence, it is highly important to consider hiatal hernia as a differential diagnosis of mediastinal uptake and also keep in mind that we should check a baseline TG level for patients before and after initiating iodine therapy for comparison.

## REFERENCES

- Vini L, Harmer C. Radioiodine treatment for differentiated thyroid cancer. *Clin Oncol (R Coll Radiol)* 2000;12:365-72.
- Shapiro B, Rufini V, Jarwan A, Geatti O, Kearfott KJ, Fig LM, *et al*. Artifacts, anatomical and physiological variants, and unrelated diseases that might cause false-positive whole-body 131-I scans in patients with thyroid cancer. *Semin Nucl Med* 2000;30:115-32.
- McDougall IR. Whole-body scintigraphy with radioiodine-131. A comprehensive list of false-positives with some examples. *Clin Nucl Med* 1995;20:869-75.
- Freeman M, Roach P, Robinson B, Shields M. Hiatal hernia in iodine-131 scintigraphy: A potential cause of false-positive midline thoracic uptake. *Clin Nucl Med* 2003;28:709-10.
- You DL, Tzen KY, Chen JF, Kao PF, Tsai MF. False-positive whole-body iodine-131 scan due to intrahepatic duct dilatation. *J Nucl Med* 1997;38:1977-9.
- Oh JR, Ahn BC. False-positive uptake on radioiodine whole-body scintigraphy: Physiologic and pathologic variants unrelated to thyroid cancer. *Am J Nucl Med Mol Imaging* 2012;2:362-85.
- Ceylan Gunay E, Erdogan A. Mediastinal radioiodine uptake due to hiatal hernia: A false-positive reason in 131I scan. *Rev Esp Med Nucl* 2010;29:95.
- Willis LL, Cowan RJ. Mediastinal uptake of I-131 in a hiatal hernia mimicking recurrence of papillary thyroid carcinoma. *Clin Nucl Med* 1993;18:961-3.
- Giuffrida D, Garofalo MR, Cacciaguerra G, Freni V, Ippolito A, Regalbutto C, *et al*. False positive 131I total body scan due to an ectasia of the common carotidis. *J Endocrinol Invest* 1993;16:207-11.
- Husmann L, Scheffel H, Stumpe K, Schmid S, Alkadhi H, Goerres GW. Pyelocaliceal diverticulum as a rare pitfall in I-131 post-therapy scanning. *Clin Nucl Med* 2010;35:443-4.
- Wolff H, Breda DJ, Da Silva N, Hartmann AA. False-positive I-131 deposition in a parotid gland duct ectasia. *Clin Nucl Med* 1998;23:257-9.

**How to cite this article:** Haghighatafshar M, Khajehrahimi F. Hiatal hernia uptake of iodine-131 mimicking mediastinal metastasis of papillary thyroid carcinoma. *Indian J Nucl Med* 2015;30:347-9.

**Source of Support:** Nil. **Conflict of Interest:** None declared.