

# Case Report: Oblique Fracture of the Ulnar Sesamoid Bone of the Metacarpophalangeal Joint, a Rare Pathology

Dauwe Jan<sup>1</sup>, Van der Cruyssen Frédéric<sup>1</sup>, De Smet Luc<sup>1</sup>

## What to Learn from this Article?

In this case report we underline the importance of early and correct diagnosis of a thumb sesamoid bone fracture since a benign course can be expected after nonoperative treatment.

## Abstract

**Introduction:** Fractures of the sesamoid bones of the metacarpophalangeal joint (MCPJ) are a rare pathology in hand trauma. Only a few case reports and case series were found in literature. The diagnosis of an ulnar sesamoid bone fracture of the MCPJ is difficult and can pose a differential diagnostic problem with Stener lesions or ulnar collateral ligament (UCL) instability. This pathology is frequently missed with subsequent poor functional outcomes. Correct and early diagnosis is important as this will allow for correct treatment with full recovery of function without sequelae.

**Case Presentation:** We report a case of a 35-year-old male Caucasian patient after a thumb injury due to a fall with his mountain bike. X-ray showed a fracture of the ulnar sesamoid of the MCPJ of the pollex, which is rarely reported in this literature. Anamnesis, clinical examination, and X-ray evaluation contributed to our diagnosis. The ulnar sesamoid bone fracture of the MCPJ of the right pollex was initially treated conservatively with immobilization, rest and ice application. After 3-4 weeks, physiotherapy with thenar muscles exercises was started. 10 weeks after the injury, our patient reported a total recovery of function and pain-free thumb movement during daily activities.

**Conclusion:** Ulnar sesamoid fractures are rarely reported in current literature. This type of injury should be recognized as early as possible since it can be easily missed. Then a benign course can be expected after short immobilization of the MCPJ of the thumb during circa 2 weeks. UCL instability or a Stener lesion should be excluded at the emergency department by performing an ultrasound. With this case report, we underline the importance of early diagnosis and exclusion of an unstable Stener lesion.

**Keywords:** Metacarpophalangeal joint, pollex, sesamoid bone, skier's thumb, thumb, ulnar collateral ligament.

## Introduction

Fractures of the sesamoid bones of the metacarpophalangeal joint (MCPJ) are a rare pathology in hand trauma. Only a few case reports and case series were found in literature [1, 2, 3, 4] (Table 1). To our knowledge, the diagnosis is difficult and can pose a differential

diagnostic problem with Stener lesions or ulnar collateral ligament (UCL) instability. This pathology is frequently missed with subsequent poor functional outcomes. Correct and early diagnosis is important as this will allow for correct treatment with full recovery of function without sequelae. We describe the case of a young male who incurred

### Access this article online

Website:  
www.jocr.co.in

DOI:  
2250-0685.736

### Author's Photo Gallery



Dr. Dauwe Jan



Dr. Van der Cruyssen Frédéric



Dr. Desmet Luc

<sup>1</sup>Department of Medicine, Catholic University of Leuven, KU Leuven, Belgium.

### Address of Correspondence:

Dr. Dauwe Jan,  
Weligerveld 1, 3212 Pellenberg, Belgium.  
E-mail: jan.dauwe@student.kuleuven.be

Copyright © 2017 by Journal of Orthopaedic Case Reports

Journal of Orthopaedic Case Reports | pISSN 2250-0685 | eISSN 2321-3817 | Available on www.jocr.co.in | doi: 10.13107/jocr.2250-0685.736

This is an Open Access article distributed under the terms of the Creative Commons Attribution Non-Commercial License (<http://creativecommons.org/licenses/by-nc/3.0>) which permits unrestricted non-commercial use, distribution, and reproduction in any medium, provided the original work is properly cited.

**Table 1: Summary overview of the most recent cases concerning a fractured ulnar sesamoid bone of the thumb compared to this study**

Author	Cases (sex/age)	Accident type	Mechanism of injury	Treatment	Follow-up	Outcome
Van der Lei [1]	Male/35	Fall on outstretched hand	Forced hyperextension	Nonoperative (splint for 2 weeks)	12 months	Full ROM, no pain
	Female/32	Fall on outstretched hand	Forced hyperextension	Nonoperative (splint for 10 days)	6 months	Full ROM, no pain
	Female/33	Fall on outstretched hand	Forced hyperextension	Nonoperative (splint for 3 weeks)	3 months	Full ROM, no pain
Fotiadis et al. [4]	Male/35	Fall during football	Hyperabduction and - extension	Nonoperative (Elastic bandage for 2 weeks)	6 weeks and 6 months	Full ROM, no pain
Present study	Male/35	Fall with bike	Hyperabduction and - extension	Nonoperative (brace and splint for 2 weeks)	10 weeks	Full ROM, no pain

ROM: Range of motion

this fracture after a bike accident. Correct differential diagnosis was put forward with following technical investigations to exclude our differentials and start guided treatment with full recovery. The aim of this case report is to clarify the importance of early and correct diagnosis of a thumb sesamoid bone fracture and to report a case of a rare fracture.

We conducted a large literature review and further supported our article using the CARE-guidelines.

### Case Report

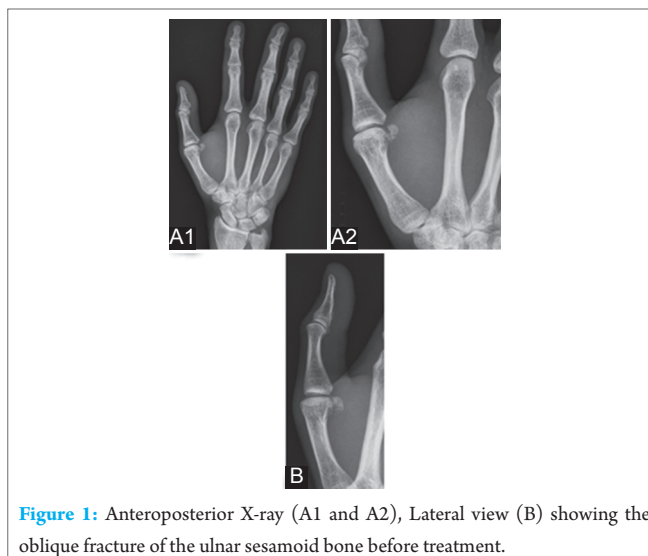
A 35-year-old male patient presented at the emergency department complaining of persisting pain and *functio laesa* of his right thumb since the day before. During a fall with his mountain bike, our patient hyperabducted and - extended his right thumb violently. The patient described a (sub) luxation of the MCPJ of the pollex which he reduced himself, no analgesics or ice application were applied by the patient.

Clinical examination at the emergency department showed a swollen MCPJ (MCPJ) with ecchymosis at the base of the thumb. Painful palpation was noted at the MCPJ, no pain could be provoked at the interphalangeal joint or after pressure on the scaphoid bone. Passive and active movements (abduction, adduction, opposition, flexion, and extension) of the thumb were normal. No crepitations were objectivized. Peripheral movements, blood circulation, and sensitivity were intact.

An anteroposterior X-ray demonstrated an oblique fracture of the ulnar sesamoid of the *caput metacarpalis* of the right thumb (Fig. 1). A Stener lesion or partial rupture of the UCL was excluded after an ultrasound examination.

The patient was treated with immobilization (wrist brace with thumb splint), rest and ice application on the right pollex for 2 weeks after which a follow-up appointment was planned. 12 days after the injury the patient experienced no pain at rest. Clinical examination demonstrated no instability at the MCPJ. The only adverse effect we withheld was a relative stiff wrist caused by our immobilization therapy. Physiotherapy with the mobilization of the thenar muscles was advised.

10 weeks after the injury the patient was re-evaluated. Examination demonstrated a full recovery of the function of the pollex and pain-free movement. No complaints were withheld. Therefore, no radiographic evaluation was needed at this stadium anymore.



**Figure 1:** Anteroposterior X-ray (A1 and A2), Lateral view (B) showing the oblique fracture of the ulnar sesamoid bone before treatment.

### Discussion

In the adult hand, two sesamoid bones (radial and ulnar) are present at the MCPJ of the pollex. These two bones are present in more than 99% of the reported cases [5]. Literature contains little information on the origin and function of sesamoids in the human body. Their function in the hand is probably to act as protectors and stabilizers of the flexor tendons and intrinsic muscles [1]. The two heads of the flexor pollicis brevis muscle are attached to the radial sesamoid, whereas the two heads of the adductor pollicis are attached to the ulnar sesamoid [6].

Pathognomonic signs of sesamoid fractures are a history of a hyperextension trauma to the MCPJ of the pollex, ecchymosis on the flexor side and local tenderness of the MCPJ. Clinically, it is of great importance that sesamoid fractures of the thumb are differentiated from (ulnar) collateral ligament disruption, or that collateral ligament injury can be excluded. Palmar plate disruption and direct trauma to a bipartite sesamoid are other differential diagnoses. Furthermore, a Stener lesion should be excluded. Stener described a lesion produced by forced thumb abduction in which the distal attachment of the UCL was traumatically avulsed from the proximal phalanx of the thumb. The severed end would become caught under the adductor aponeurosis and therefore be unable to return to its anatomic position. Consequently, the severed ligament would fold on itself and thus be prevented from healing and restoring stability to the MCPJ. With a Stener lesion, a situation exists in which the

MCPJ of the thumb is rendered permanently unstable because the UCL is prevented from healing by the interposed adductor aponeurosis. The resultant chronic instability significantly impairs function in the injured hand [7].

If a Stener lesion is recognized early, the UCL may be reduced operatively and secured in its anatomic position. Early recognition and anatomic reduction can result in an excellent functional outcome in the vast majority of cases. Late presentation or a delayed diagnosis of a Stener lesion may produce a need for more involved surgery, with less desirable results.

Anatomically, the UCL of the MCPJ-I provides stability against valgus stress to the thumb. The UCL of the MCPJ-I consists of two parts: The proper collateral ligament and the accessory collateral ligament. In addition to those static stabilizers, extrinsic and intrinsic muscles act as dynamic stabilizers. Extrinsic muscles include the extensor pollicis brevis, extensor and flexor pollicis longus. Intrinsic muscles include the adductor pollicis, abductor and flexor pollicis brevis [8, 9].

Fractures of the ulnar and radial sesamoid bone of the MCPJ of the pollex are very uncommon and can be easily missed to diagnose. Those fractures are treated with immobilization of the thumb for a short period of time. Operative treatment is not indicated unless the fracture is complicated with the instability of the MCPJ. In most cases, it results in a quick recovery [2, 3, 10].

The most common mechanism of a fracture of the ulnar sesamoid bone of the pollex is a violent hyperextension or - abduction after a fall on the outstretched hand, causing avulsion of the ulnar sesamoid bone that is embedded in the tendon of the adductor pollicis and flexor pollicis brevis or less frequently after direct trauma [1, 4, 10, 11].

Due to its higher prevalence among skiers, it was first named by Gerber *et al.* accordingly [10]. In the case of a forced abduction of the thumb, the practitioner should be aware for a "skier's thumb." It is the second most common injury sustained while skiing. Reported injury rates vary from 7% to 9% of all skiing injuries [12]. Due to the forced abduction a (partial) rupture of the UCL can occur. This injury is notorious for frequently being missed by inexperienced health care personnel in emergency departments [8, 13]. Musharafieh *et al.* reported that an UCL rupture was missed in 64% of the 28 patients who consulted for a second opinion [14].

Madan *et al.* concluded in 2014 that tears of the UCL can be diagnosed best clinically by experience doctors, however magnetic resonance imaging (MRI) is the imaging modality of choice [8].

Since our patient presented at the emergency department, MRI was no option to exclude an UCL injury, so an ultrasound was taken. Ultrasound is an excellent and cost-effective modality because it allows direct visualization of the entire UCL and surrounding structures. It locates the torn end of the UCL in almost 90% of cases [8].

X-ray examination contributes in our opinion the most in diagnosing the fracture. Fractures of the sesamoid bones of the pollex are classified into two types according to Patel *et al.* [2]. In Type 1 fractures the palmar plate and the flexor ability of the MCPJ of the thumb remain intact. Type 2 fractures include a rupture of the palmar plate and the pollex in a hyperextension position. It is clear that our case shows a Type 1 fracture.

The goal of treatment in case of a fractured ulnar sesamoid bone of the pollex is to regain complete functionality. We treated conservatively with immobilization using a wrist brace with thumb splint since instability of the MCPJ was excluded. Further was rest and ice application advised. Mobilization exercises were permitted 12 days after the injury which was also the treatment advised in other similar cases [1].

### Conclusion

Ulnar sesamoid fractures are rarely reported in current literature. This type of injury should be recognized as early as possible since it can be easily missed. Then a benign course can be expected after short immobilization of the MCPJ of the thumb during circa 2 weeks. UCL instability or a Stener lesion should be excluded at the emergency department by performing an ultrasound.

With this case report, we underline the importance of early diagnosis and exclusion of an unstable Stener lesion.

### Clinical Message

Sesamoid fractures of the pollex are rare fractures and can easily be missed to diagnose. In the presence of an ulnar sesamoid bone fracture, UCL instability or a Stener lesion should be excluded. Overall, an uncomplicated course can be expected after short immobilization of the MCPJ-I for 2 weeks followed by thenar physiotherapy to regain complete function of the thumb.

## References

1. van der Lei B, van der Linden E, Mooyaart EL, Klasen HJ. Fracture of the thumb sesamoid bone: A report of three cases and a review of the English-language literature. *J Trauma* 1995;38(5):836-840.
2. Patel MR, Pearlman HS, Bassini L, Ravich S. Fractures of the sesamoid bones of the thumb. *J Hand Surg Am* 1990;15(5):776-781.
3. Hansen CA, Peterson TH. Fracture of the thumb sesamoid bones. *J Hand Surg Am* 1987;12(2):269-270.
4. Fotiadis E, Samoladas E, Akritopoulos P, Chatzimeon A, Akritopoulou K. Ulnar sesamoid's fracture of the thumb: An unusual injury and review of the literature. *Hippokratia* 2007;11(3):154-156.
5. Hubay CA. Sesamoid bones of the hands and feet. *Am J Roentgenol Radium Ther* 1949;61(4):493-505.
6. Yammine K. The prevalence of the sesamoid bones of the hand: A systematic review and meta-analysis. *Clin Anat* 2014;27(8):1291-1303.
7. Stener B. Hyperextension injuries to the metacarpophalangeal joint of the thumb: Rupture of ligaments, fracture of sesamoid bones, rupture of flexor pollicis brevis. An anatomical and clinical study. *Acta Chir Scand* 1963;125:275-293.
8. Madan SS, Pai DR, Kaur A, Dixit R. Injury to ulnar collateral ligament of thumb. *Orthop Surg* 2014;6(4):1-7.
9. Mahajan M, Rhemrev SJ. Skier's thumb. *Ned Tijdschr Geneesk* 2013;157(49):A6398.
10. Gibeault JD, Saba P, Hoenecke H, Graham A. The sesamoids of the metacarpo-phalangeal joint of the thumb: An anatomical and clinical study. *J Hand Surg Br* 1989;14(2):244-247.
11. Shaw M, Lyburn ID, Torreggiani WC, Watura R. Comminuted fracture of the ulnar sesamoid of the metacarpophalangeal joint of the thumb: An uncommon injury. *J Emerg Med* 2003;24(4):437-439.
12. Harding P, McKeag L. Skier's thumb: A literature review. *Aust J Physiother* 1995;41(1):29-33.
13. Gerber C, Senn E, Matter P. Skier's thumb: Surgical treatment of recent injuries to the ulnar collateral ligament of the thumb's metacarpophalangeal joint. *Am J Sports Med* 1981;9(3):171-177.
14. Musharafieh RS, Bassim YR, Atiyeh BS. Ulnar collateral ligament rupture of the first metacarpophalangeal joint: A frequently missed injury in the emergency department. *J Emerg Med* 1997;15(2):193-196.

Conflict of Interest: Nil  
Source of Support: None

## How to Cite this Article

Dauwe J, Van der Cruyssen F, De Smet L. Oblique Fracture of the Ulnar Sesamoid Bone of the Metacarpophalangeal Joint, a Rare Pathology. *Journal of Orthopaedic Case Reports* 2017 Mar-Apr;7(2):29-32.