

The role of magnetic resonance imaging in the diagnostic work-up of fetal ventriculomegaly

L. CARDOEN¹, L. DE CATTE², P. DEMAEREL¹, R. DEVLIEGER², L. LEWI², J. DEPREST², F. CLAUS¹

¹Department of Radiology and ²Department of Woman and Child, University Hospitals Leuven, Leuven, Belgium.

Correspondence at: filip.claus@uzleuven.be

Abstract

The indication for fetal magnetic resonance imaging (MRI) remains a subject of debate, partly because of questions concerning its diagnostic accuracy compared to ultrasound, partly because of practical factors such as accessibility, high costs and available expertise. Most studies advocate an added value for MRI in cases diagnosed with central nervous system pathology. MRI is a good modality to detect small foci of brain hemorrhage, to depict callosal anomalies, to add information about normal and pathological cortical development, and is a more sensitive imaging method to detect white matter pathology. This manuscript discusses the role of MRI as an adjunct to ultrasound for cases diagnosed with cerebral ventriculomegaly.

Key words: fetal, hydrocephaly, magnetic resonance imaging, ventriculomegaly.

Introduction

Ultrasound is the imaging modality of choice to screen for fetal anomalies. The accuracy to detect fetal pathology depends on the expertise of the sonographer and some limitations inherent to this imaging technique. Descent of the fetal head and progressive ossification of the skull bones towards the end of the pregnancy, maternal obesity and oligohydramnios are all well-known limitations affecting the sensitivity to detect central nervous system pathology. The first reported use of fetal magnetic resonance imaging (MRI) dates from 1989. Advances in MRI technology during the last 2 decades and better knowledge of fetal pathology, have both led to an increasing role for MRI in the diagnostic work-up of prenatal anomalies. Most fetal MRI studies reported so far, have addressed the additional role of MRI in the diagnosis and characterization of fetal anomalies detected on ultrasound, with emphasis on central nervous system pathology. In this manuscript we discuss the role of MRI as an adjunct to ultrasound for cases diagnosed with ventriculomegaly.

Ventriculomegaly

The descriptive term cerebral ventriculomegaly is used when the maximal diameter of the atrium of the lateral ventricles – measured in a plane perpendicular to the midsagittal section of the brain – exceeds 10 mm. The prevalence of ventriculomegaly ranges between 0.3-1.5‰ and the severity can be classified in mild (10-12 mm), moderate (12-15 mm) and severe (> 15 mm), as illustrated in Fig. 1 (Valsky *et al.*, 2004; Gagliot *et al.*, 2005; Ouahba *et al.*, 2006). Another classification system is based on measuring the thickness of the overlying brain parenchyma in the category with an atrial diameter of > 15 mm, i.e. > 3 mm thickness indicates a moderate ventriculomegaly and ≤ 3 mm a severe form (Levine *et al.*, 2003). Measurement of the lateral ventricle is subject to errors owing to an off-axis image plane of a section, an angled measurement, or improper choice of ventricular boundary giving risk to false-positive test results. Therefore, a precise definition of the reference planes and anatomical landmarks is important to avoid inaccurate measurements and facilitate imaging follow-up comparisons

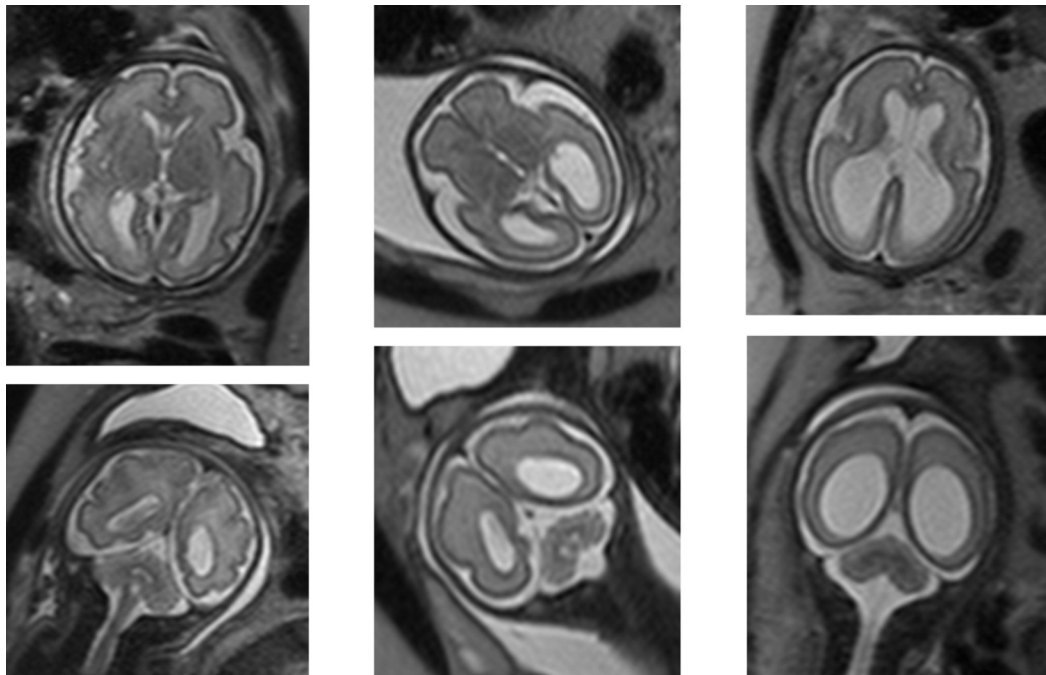


Fig. 1. — T2-weighted axial and coronal images: mild (first column), moderate (middle column) and severe (last column) ventriculomegaly. The atrial diameters and gestational ages are respectively 11, 13 and 24 mm and 29, 27 and 28 weeks.

(Levine *et al.*, 2008). Ventriculomegaly has a wide range of causes and can roughly be divided in three categories: (1) an imbalance between the production and absorption of cerebrospinal fluid, of which the obstructive form is most frequently observed, (2) abnormal cerebral development such as partial or complete agenesis of the corpus callosum and neuronal proliferation / migration disorders and (3) destructive disease processes leading to loss of neuronal tissue by vascular insults or infectious pathogens. Unilateral ventriculomegaly is more often seen in destructive processes, whereas developmental anomalies are more characterized by bilateral broadening of the ventricles (Girard *et al.*, 2003). The reported incidence of additional anomalies goes up to 70-85%, strongly depending on the number of fetuses included in the study and the distribution of the severity of the cerebral ventriculomegaly observed in the study population (Huisman *et al.*, 2002; Ouahba *et al.*, 2006). The term isolated ventriculomegaly is used in case no other structural anomalies are seen at the time of diagnosis. Isolated and/or unilateral ventriculomegaly, in particular the mild form, has a lower incidence of peri- and postnatal morbidity and mortality (Senat *et al.*, 1999; Mehta and Levine, 2005; Ouahba *et al.*, 2006).

Fetal MRI

Fetal MRI is mainly performed on 1.5 Tesla scanners. To date, no adverse health effects have been

demonstrated – neither fetal nor maternal – after short term exposition to electromagnetic fields as used in clinical MRI. The HASTE sequence (half Fourier acquired single shot turbo spin echo) is nowadays most used and combines short acquisition times (1 image in less than 1 second) with a good signal-to-noise ratio, good T2 contrast and an acceptable spatial resolution (slice thickness of 3 mm). T1 weighted imaging is often used to detect hemorrhages or calcifications. T1-weighted imaging sequences have a lower signal to noise ratio, require longer scanning times (up to 18 seconds per slice) and are hence much more susceptible to fetal and maternal motion. Novel scanning sequences include the use of diffusion weighted imaging and diffusion tensor imaging for a more functional analysis of the developing brain (Guimiot *et al.*, 2008; Vazquez *et al.*, 2008). MRI scans have a big field of view and can be obtained in any given plane. The major limitations of fetal MRI are the impact of fetal motion on the image acquisition and its relatively low spatial resolution, in particular compared to ultrasound. Contra-indications for MRI are the same as for non-pregnant patients (claustrophobia, metallic brain clips, pacemaker implant, ...). Opposed to ultrasound, MRI has an excellent contrast resolution which enables to differentiate easily between gray and white matter. MRI also allows to directly visualize the cortical region and the fossa posterior, without sonographic limiting factors such as maternal obesity, the amount of amniotic fluid, fetal head

position or the acoustic shadows of the skull bones. Knowledge of the normal appearance and maturation of the developing cerebral gyri and sulci is helpful in the appropriate diagnosis and counseling of anomalous fetuses. At 14 weeks the cerebral convexities are smooth. The Sylvian fissure and callosal sulcus are respectively visible at 16 and 18 weeks, and the central sulcus is not reliably seen until 24-25 weeks of gestation. The pre- and postcentral gyri appear at 26 weeks. By 28-30 weeks, numerous new sulci and gyri develop and by the age of 32-35 weeks secondary gyri are visible throughout the cerebral cortex (Levine and Robson, 2005).

The role of fetal MRI in fetuses diagnosed with ventriculomegaly

An important role in the prenatal diagnostic work-up of ventriculomegaly is the detection and characterization of additional cerebral anomalies (Kubik-Huck *et al.*, 2000; Simon *et al.*, 2000; Huisman *et al.*, 2002; Launay *et al.*, 2002; Levine *et al.*, 2003; Valsky *et al.*, 2004; Mehta and Levine, 2005; Zimmerman and Bilaniuk, 2005; Glenn and Barkovich, 2006; Benacerraf *et al.*, 2007; Morris *et al.*, 2007; Reddy *et al.*, 2008). The incidence of additional malformations detected on MRI following normal ultrasound findings varies greatly between several reported studies and depends on the severity of ventriculomegaly, the expertise of the sonographer and the selected patient population. Percentages of detection range between 5% for mild ventriculomegaly and up to 50% for moderate and severe cases (Valsky *et al.*, 2004; Salomon *et al.*, 2006). Numbers should be interpreted with caution, because of the systematic lack of postnatal/postmortem (imaging) correlates, the uncertainty between the time span between prenatal ultrasound and MRI in several studies, the a priori knowledge of ultrasound findings by the fetal MRI specialist and the lack of data investigating the sonographic detection/confirmation of the fetal anomalies following the MRI scan. Maligner *et al.* address several items why the added value of MRI is difficult to statistically demonstrate: an overenthusiastic attitude towards new technologies, comparing a first line routine ultrasound exam with a MRI exam in a tertiary centre, the lack of description of the ultrasound technique and checklist, suboptimal or insufficient ultrasound images in the reported studies and no information with respect to the time span between the ultrasound and MRI exam (Maligner *et al.*, 2004). At last, it is very important to stress that the interobserver agreement, i.e. the interpretation agreement between 2 observers using the same modality, for both imaging modalities can vary greatly. In a

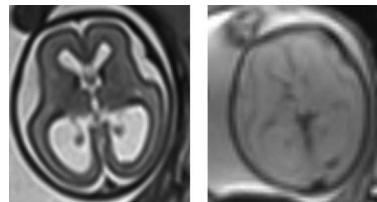


Fig. 2. — Severe ventriculomegaly, gestational age 24 weeks: small blood remnant adherent to the posterior wall of the occipital horn of the left lateral ventricle, barely detectable on the standard T2-weighted images (left), but clearly visible as a black spot on the dedicated sequence on the right.

study of Levine *et al.*, in which the agreement between experts using the same imaging modality was investigated, overall consensus was reached with respect to normal and abnormal findings in only 60% of the cases for ultrasound and in 53% for MRI (Levine *et al.*, 2008). The numbers even drop below 50% for the detection of cerebellar and gyral anomalies. Important to note is that the readers in this study could not indicate their uncertainty in each finding, but were only allowed to indicate the presence or absence of an anomaly. Given the often subtle findings of fetal central nervous pathology, such as cerebellar or gyral anomalies, this probably has led to an overestimate of the discrepancies. Another important finding is that the level of subspecialty training of the individuals interpreting the MRI examination, in particular the involvement of pediatric neuroradiologists, significantly improved the interobserver agreement.

Below, we will discuss some disease entities often associated with ventriculomegaly, with emphasis on the added value of MRI (Launay *et al.*, 2002; Glenn and Barkovich, 2006 part 2; Benacerraf *et al.*, 2007). MRI is a very sensitive technique to detect small deposits of intraventricular blood, which may suggest an intraventricular hemorrhage as cause of the hydrocephaly (Fig. 2). MRI has also a high accuracy to detect corpus callosum dysgenesis and allows to screen for additional malformations such as cortical anomalies, periventricular or subependymal

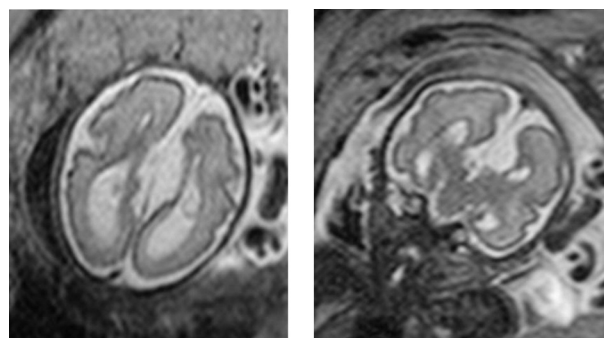


Fig. 3. — T2-weighted images, gestational age 28 weeks: corpus callosum agenesis with colpocephaly in axial (left) and coronal plane (right) with associated interhemispheric cyst.

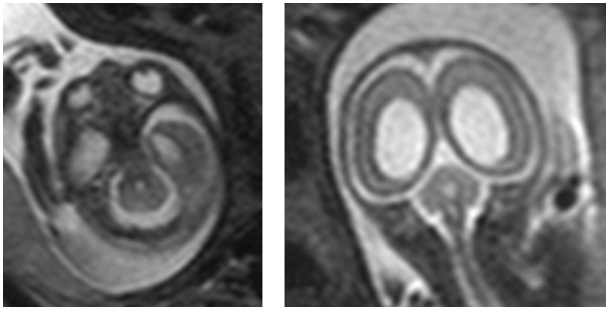


Fig. 4. — T2-weighted images, gestational age 23 weeks: ventriculomegaly with cerebellar hypoplasia, agenesis of the vermis and fusion of the cerebellar hemispheres (rhombencephalosynapsis), shown in axial (left) and coronal (right) plane.

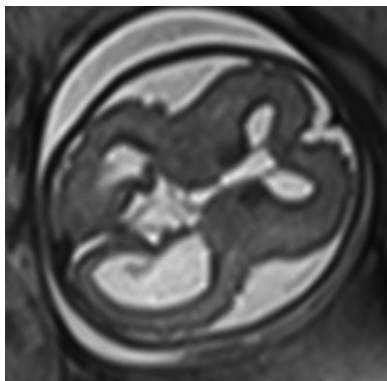


Fig. 5. — T2-weighted axial image, gestational age 27 weeks, showing severe ventriculomegaly, megalencephaly (> P97) and polymicrogyria, the latter characterized by the spicular, irregular outlining of the cerebral surface. Tentative diagnosis of MPPH (megalencephaly – perisylvian polymicrogyria - post-axial polydactyly - hydrocephalus) syndrome based on the additional finding of bilateral post-axial polydactyly.

nodular heteropia and interhemispheric cysts (Fig. 3). Accurate characterization of those additional anomalies is important in terms of prognosis and parental counseling. MRI is equally good for a morpho- and volumetric assessment of the fossa posterior in case of suspicious ultrasound findings. It allows a good evaluation of the vermis, the cerebellar hemispheres, the pedunculi, the brainstem, the 4th ventricle, the tentorium cerebelli and the retrocerebellar space, which enables to detect developmental anomalies such as vermis hypoplasia, Dandy Walker malformations, Chiari malformations and other fossa posterior malformations (Fig. 4). A recurring indication for ventriculomegaly reported in the literature, is the detection of cortical malformations, such as polymicrogyria (Fig. 5), lissencephaly, schizencephaly and (subependymal) heteropia. The excellent tissue contrast of MRI and the absence of bony interference, makes this technique ideal for cortical evaluation. Congenital infections such as Cytomegalovirus and Toxoplasmosis, are also good candidates to refer for MRI, in particular to detect pathological white

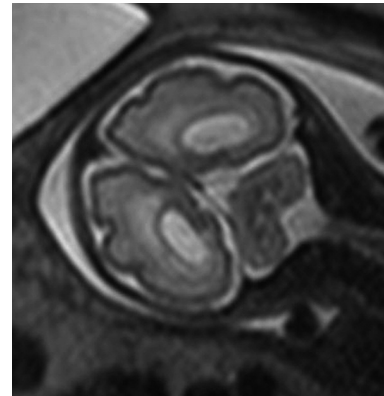


Fig. 6. — T2-weighted axial image (gestational age 30 weeks) in a proven case of congenital Cytomegalovirus showing borderline ventriculomegaly (atrial diameter 10 mm) and periventricular leucomalacia (marked hyperintense signal of the white matter tissue around the ventricular borders).

matter changes and cortical malformations (Fig. 6). Focal loss of brain tissue, hemorrhages and sequelae of ventriculitis can also easily be detected on MRI.

On the basis of reported studies, fetal MRI has a limited role over ultrasound in assessing the size of the cerebral ventricles, except for cases where fetal position and calvarial ossification cause problems. In the second trimester, in particular the 20-24 weeks' group, MRI is useful to detect small foci of brain hemorrhage or callosal anomalies in fetuses diagnosed with cerebral ventriculomegaly (Griffiths *et al.*, 2010). Later in pregnancy (over 25 weeks), MRI adds information about normal and pathological cortical development and maturation, depicts fossa posterior anomalies and is a more sensitive imaging modality to detect white matter pathology (Griffiths *et al.*, 2010; Yi *et al.*, 2010).

Summary

Referring prenatal cases of ventriculomegaly for fetal MRI is a topic of debate, not only due to questions related to the diagnostic accuracy of MRI and its added value, but also because of practical issues such as the availability of MRI, the cost and available expertise of fetal radiologists. Most studies reported in the literature advocate the added value of MRI in cases of moderate and severe ventriculomegaly, not only to confirm the severity, but mainly to further detect and characterize additional anomalies. In cases of mild unilateral ventriculomegaly, MRI might demonstrate additional findings which are difficult to detect with sonography such as leucomalacy and neuronal migration disorders. In both categories, MRI has added value in terms of diagnosis, prognosis and treatment planning.

References

- Benacerraf BR, Shipp TD, Bromley B *et al.* What does magnetic resonance imaging add to the prenatal sonographic diagnosis of ventriculomegaly? *J Ultrasound Med.* 2007;26(11): 1513-22.
- Gagliot P, Danelon D, Bontempo S. Fetal cerebral ventriculomegaly: outcome in 176 cases. *Ultrasound Obstet Gynecol.* 2005;25(4):372-7.
- Girard N, Ozanne A, Chaumoitre K *et al.* IRM et ventriculomegalie in utero. *J Radiol.* 2003; 84:1933-44.
- Glenn OA, Barkovich AJ. Magnetic Resonance Imaging of the fetal brain and spine: an increasing important tool in prenatal diagnosis, part 1. *AJNR Am J Neuroradiol.* 2006;27(8): 1604-11.
- Glenn OA, Barkovich J. Magnetic Resonance Imaging of the fetal brain and spine: an increasing important tool in prenatal diagnosis, part 2. *Am J Neuroradiol.* 2006;27(9): 1807-14.
- Griffiths PD, Reeves MJ, Morris JE *et al.* A prospective study of fetuses with isolated ventriculomegaly investigated by antenatal sonography and in utero MR imaging. *Am J Neuroradiol.* 2010;31(1):106-11.
- Guimiot F, Garel C, Fallet-Bianco C *et al.* Contribution of diffusion-weighted imaging in the evaluation of diffuse white matter ischemic lesions in fetuses: correlations with fetopathologic findings. *AJNR Am J Neuroradiol.* 2008; 29(1): 110-5.
- Huisman TA, Wissner J, Martin E *et al.* Fetal magnetic resonance imaging of the central nervous system. *Eur Radiol.* 2002; 12(8):1952-61.
- Kubik-Huck RA, Huisman TA, Wissner J *et al.* Ultrafast MR imaging of the fetus. *Am J Roentgenol.* 2000;174(6):1599-1606.
- Launay S, Robert Y, Valat AS *et al.* IRM cérébrale foetale et ventriculomegalie. *J Radiol.* 2002; 83:723-30.
- Levine D, Barnes PD, Robertson RR *et al.* Fast MR imaging of fetal central nervous system abnormalities. *Radiology.* 2003; 229(1):51-61.
- Levine D, Robson C. MR imaging of normal brain in the second and third trimesters. In: Levine D (ed). *Atlas of fetal MRI.* Taylor & Francis Group, Boca Raton, USA 2005, 7-23.
- Levine D, Feldman HA, Tannus JFK *et al.* Frequency and cause of disagreements in diagnoses for fetuses referred for ventriculomegaly. *Radiology.* 2008;247(2):516-27.
- Malinger G, Ben-Sira L, Lev D *et al.* Fetal brain imaging: a comparison between magnetic resonance imaging and dedicated neurosonography. *Ultrasound Obstet Gynecol* 2004; 23(4): 333-340.
- Mehta TS, Levine D. Imaging of fetal cerebral ventriculomegaly: a guide to management and outcome. *Semin Fetal Neonatal Med.* 2005;10(5):421-8.
- Morris JE, Rickard S, Paley MN *et al.* The value of in-utero magnetic resonance imaging in ultrasound diagnosed foetal isolated cerebral ventriculomegaly. *Clin Radiol.* 2007;62(2): 140-4.
- Ouahba J, Luton D, Vuillard E *et al.* Prenatal isolated mild ventriculomegaly: outcome in 167 cases. *BJOG.* 2006; 113(9):1072-9.
- Reddy UM, Filly RA, Copel JA. Prenatal imaging: ultrasonography and magnetic resonance imaging. *Obstet Gynecol.* 2008;112(1):145-57.
- Salomon L, Ouahba J, Delezoide A *et al.* Third-trimester fetal MRI in isolated 10- to 12 mm ventriculomegaly: is it worth it? *BJOG.* 2006;113(8):942-7.
- Senat MV, Bernard JP, Schwärzler P *et al.* Prenatal diagnosis and follow-up of 14 cases of unilateral ventriculomegaly. *Ultrasound Obstet Gynecol.* 1999;14(5):327-32.
- Simon EM, Goldstein RB, Coakley FV *et al.* Fast MR imaging of fetal CNS anomalies in utero. *Am J Neuroradiol.* 2000; 21(9):1688-98.
- Valsky DV, Ben-Sira L, Porat S *et al.* The role of magnetic resonance imaging in the evaluation in isolated mild ventriculomegaly. *J Ultrasound Med.* 2004;23(4):519-23.
- Vazquez E, Marcaya A, Mayolas N *et al.* Neonatal Alexander Disease: MR imaging prenatal diagnosis. *AJNR Am J Neuroradiol.* 2008;29(10):1973-5.
- Yi L, Estroff JA, Mehta TS *et al.* Ultrasound and MRI of fetuses with ventriculomegaly: can cortical development be used to predict postnatal outcome? *Am J Roentgenol.* 2010;196(6): 1457-67.
- Zimmerman RA, Bilaniuk LT. Magnetic resonance evaluation of fetal ventriculomegaly-associated congenital malformations and lesions. *Semin Fetal Neonatal Med.* 2005;10(5): 429-43.