

Ectopic atrial tachycardia originating from right atrial appendage aneurysms in children: Three case reports



Tomomitsu Kanaya, MD,^{*} Kyoichi Nishigaki, PhD,[†] Yoko Yoshida, MD,[‡]
Yoshihide Nakamura, MD,[‡] Yosuke Murakami, MD,[‡] Tsugutoshi Suzuki, PhD[‡]

From the ^{*}Department of Cardiovascular Surgery, Osaka University Graduate School of Medicine, Suita, Japan, [†]Department of Cardiovascular Surgery, Osaka City General Hospital, Osaka, Japan, and [‡]Department of Pediatric Cardiology, Osaka City General Hospital, Osaka, Japan.

Introduction

Ectopic atrial tachycardia occurs at a rate of 5%–20% among children with supraventricular tachycardia.¹ Atrial appendages are the most frequent focus in children, differing from the situation in adults.² However, ectopic atrial tachycardia originating from aneurysms of the right atrial appendage is very rare and in fact has not yet been clearly defined. We describe 3 cases of children with ectopic atrial tachycardia resulting from right atrial appendage aneurysms that proved refractory to radiofrequency catheter ablation. All 3 children were treated surgically. Written consent from the legal guardians of the patients was received for publication of the details of these cases.

Case report

Case 1

A 4-year-old boy weighing 18 kg was referred to our hospital for management of symptomatic tachycardia. Physical examination revealed facial edema, hypopnea, and vomiting. Electrocardiography showed atrial tachycardia with a ventricular rate of 240 beats per minute. Transthoracic echocardiography revealed an ejection fraction of 56% and a sac-like structure in the right atrium. Electrophysiological study and radiofrequency catheter ablation were then performed under general anesthesia. Arteriography showed 2 aneurysms at the right atrial appendage (Figure 1). These structures were mapped during ectopic atrial tachycardia using the CARTO3 system (Biosense Webster, Diamond Bar, CA) and the earliest activation sites were ablated using a temperature-controlled ablation catheter and an irrigation catheter. We suspected these aneurysms as the origin of the ectopic atrial tachycardia. A catheter was inserted into the anterior aneurysm, but not

into the posterior aneurysm. Radiofrequency ablation was performed with a 3.5-mm-tip irrigated catheter (SmartTouch ThermoCool; Biosense Webster). Ablation power was restricted to 25 W with irrigation flow rate titrated to 17 mL/s. Radiofrequency catheter ablation proved temporarily successful, but ectopic atrial tachycardia recurred within 60 seconds. We could not confirm whether the posterior aneurysm was the origin of ectopic atrial tachycardia and completed the procedure. The patient was then treated with oral propranolol (3 mg/kg/day) and flecainide (100 mg/m²/day) and ventricular heart rate was controlled to within 120 beats/min after radiofrequency catheter ablation. A second radiofrequency catheter ablation was performed 1 month later. In this second session, the target was the posterior aneurysm. We tried to insert the catheter into the posterior aneurysm, but we could not insert into it. We therefore decided to resect the aneurysms constituting the presumed origin of ectopic atrial tachycardia.

Two aneurysms with diameters of 8 and 4 mm were visualized on the right atrial appendage via median sternotomy. Clamping these aneurysms immediately stopped the tachycardia. We then resected the aneurysms without cardiopulmonary bypass. Electrocardiography thereafter showed sinus rhythm with a ventricular heart rate of 80 beats/min. This sinus rhythm has persisted for 6 years without medication.

Histologic examination of the resected specimens showed very thin aneurysm walls (about 5.0 μm) and replacement of the myocardium with fibrous tissue.

Case 2

In the fetal period, the patient showed tachycardia on the electrocardiogram. After birth, atrial tachycardia with a wide QRS complex was detected and giant atrial aneurysms were identified on echocardiography. The first session of ablation for tachycardia was performed at 5 years old, but proved unsuccessful. The patient had been treated with propranolol and flecainide. At 8 years old, he was admitted to our institution for an attempt at a second radiofrequency

KEYWORDS Ectopic atrial tachycardia; Right atrial appendage; Radiofrequency catheter ablation; Surgery; Child
(Heart Rhythm Case Reports 2018;4:2–5)

Address reprint requests and correspondence: Dr Tsugutoshi Suzuki, Osaka City General Hospital, 2-13-22 MiyakojimaHonDori, Osaka, 534-0021, Japan. E-mail address: t-kanaya@surg1.med.osaka-u.ac.jp.

KEY TEACHING POINTS

- Ectopic atrial tachycardia originating from aneurysms of the right atrial appendage is very rare among children.
- Aneurysms having structural abnormalities such as the pectinate muscles and saccular form would prevent catheter insertion and radiofrequency catheter ablation.
- Surgical treatment is often effective for the patients with aneurysm of right atrial appendage having multiple atrial tachycardia; however, location or size of aneurysm is important for the surgical treatment.
- A combination of medications, surgery, and ablation should be considered for patients with multiple foci originating from aneurysms.

catheter ablation. Multiple aneurysms of the right atrial appendage were diagnosed from contrast-enhanced computed tomography. Multiple highly echoic diverticular structures were revealed on transthoracic echocardiography of the right atrium. Heart rate during tachycardia was 140 beats/min. Radiofrequency catheter ablation was applied to treat the atrial tachycardia, using the same settings as in case 1. The aneurysms were assessed by angiography. However, because they were recognized as the focus of the ectopic atrial tachycardia, we could not insert catheters. Ectopic atrial tachycardia proved refractory to radiofrequency catheter ablation and we decided to surgically excise the tachycardia foci when the patient reached 9 years old. At that time, the aneurysms did not have a stalk and the right atrium had degenerated owing to the presence of the aneurysms. The degenerated area was too large to allow excision of all ectopic atrial tachycardia foci without cardiopulmonary bypass. We immediately established cardiopulmonary bypass and applied cardioplegic arrest. The large (50 × 30 mm) aneurysms and degenerated atrial wall were excised and the remaining right atrium was directly closed. After releasing of cardiac arrest, heart rate was 170 beats/min with atrial tachycardia. Clamping the small residual aneurysmal lesion immediately decreased the heart rate to sinus rhythm. Cardiac arrest was again established and we replaced the defective area of the atrium with a pericardial patch. Sinus rhythm continued after resection of the residual lesion. Although tachycardia temporarily relapsed thereafter, the patient remains symptom-free under persistent sinus rhythm and has not required any antiarrhythmic medication for 6 years postoperatively.

Case 3

The patient was diagnosed with ectopic atrial tachycardia through school-based cardiovascular screening at 7 years

old. He was an outpatient, but tachycardia-induced cardiomyopathy was suspected at 11 years old, and he was referred to our hospital for treatment. Electrocardiography showed atrial tachycardia with a ventricular rate of 150 beats/min during tachycardia. Arteriography revealed a small aneurysm of the right atrial appendage. The earliest activation site wandered in the right atrium and radiofrequency catheter ablation proved ineffective. Repeat radiofrequency catheter ablation using Ensite NavX (St. Jude Medical, St. Paul, MN) isolated 2 foci of ectopic atrial tachycardia recognized in the free wall of the right atrium. The earliest activation site wandered at 1 aneurysm of the atrial appendage. Ablation of this site was ineffective. Ablation of the earliest activation site that wandered at the superior vena cava–right atrium junction also failed, so we discontinued the second session. However, sinus rhythm continued under oral propranolol (2.6 mg/kg/day) and flecainide (100 mg/m²/day) and we decided to perform surgical resection. Tachycardia was induced under general anesthesia to a heart rate of 180 beats/min and median partial sternotomy was performed. Not only the ventricle but also the right and left atria were pale and degenerated in a manner resembling cardiomyopathy. Small aneurysms were found essentially all over the right atrium. Clamping the tips of the aneurysms of the right atrial appendage decreased the heart rate to 130 beats/min, but atrial tachycardia persisted. Further excision was difficult because the aneurysms were located near the sinoatrial node and the right coronary artery and no other foci of ectopic atrial tachycardia were identified. After the procedure, ectopic atrial tachycardia continued with a heart rate of 130 beats/min. Sinus rhythm has been maintained in this patient, who started on oral propranolol (2.6 mg/kg/day) and flecainide (100 mg/m²/day). He has experienced no attacks of tachycardia in the 2 years since surgery and is now an outpatient without any antiarrhythmic drugs. Histologic examination showed an atrophic right atrial wall that had degenerated into vacuoles or fibrous cells (Figures 2 and 3).

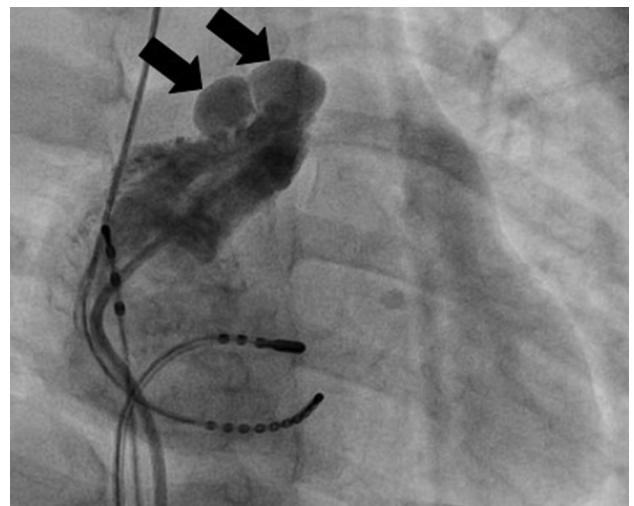


Figure 1 Case 1. Arteriography shows 2 large right atrial aneurysms (arrows). The catheter could not be inserted into the posterior aneurysm.

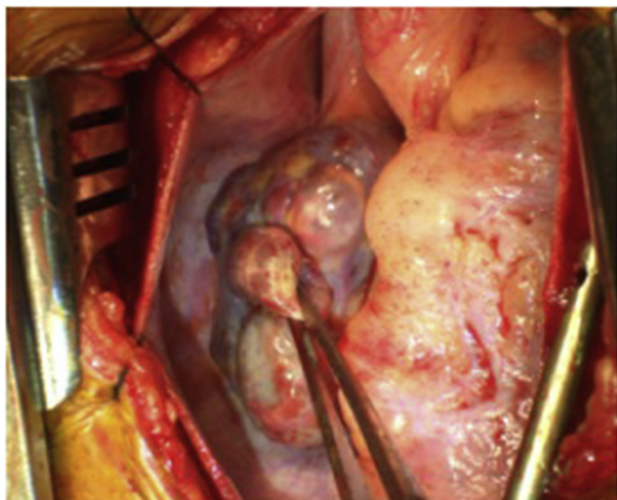


Figure 2 Intraoperative image of multiple right atrial appendage aneurysms in case 2.

Discussion

Ectopic atrial tachycardia most often arises in children with supraventricular tachycardia.^{1,2} However, the right atrial appendage in children is often the site of origin of ectopic atrial tachycardia,³ and ectopic atrial tachycardia arising from right atrial appendage aneurysms does not appear to have been described previously.

Aneurysm of the right atrial appendage is a rare anomaly. Etiologies of the “acquired type” have been reported as long-standing elevated right atrial pressure and increased right atrial volume resulting from pulmonary hypertension and congenital cardiac defects. The “congenital type” is often diagnosed in neonates and during the fetal stage, and is caused by dysplasia of the muscular wall of the atrium. Echocardiography offers poor sensitivity for diagnosing right atrial aneurysm and such aneurysms may be asymptomatic initially, but arrhythmia and palpitations may appear as the aneurysm grows. Risk factors for right appendage aneurysm include arrhythmia and thrombosis. Conservative management has been recommended for asymptomatic patients, but resection should be performed depending on aneurysm size and associated congenital cardiac defects. Symptomatic patients should undergo surgical resection, which would decrease the risks of arrhythmia and thrombosis.^{4,5}

Regarding abnormal anatomic features of atrial appendage aneurysms, Ho and colleagues⁶ described the apex of the right atrial appendage as tubular and narrow owing to the pectinate muscles, and a saccular form would probably prevent catheter insertion. Aneurysms represent structural abnormalities and irrigation catheters are thought to be essential because of the impaired catheter maneuverability imposed by the pectinate muscles and high interface temperatures owing to minimal cooling caused by blood flow in the right atrial appendage, all of which are associated with difficulties in achieving adequate power.⁷

The present histologic findings revealed degenerate and very thin right atrial walls that could easily be perforated by attempts to insert catheters or perform ablation. Several

groups^{8,9} have described perforation and tamponade arising during catheter ablation to treat atrial fibrillation. This would explain why most perforations arise in the atrium. The risk of perforation would be higher during ablation of right atrial appendage aneurysms than of those involving ventricles or normal atrium.

For asymptomatic patients with good cardiac function such as in case 2, treatment for arrhythmia may be controversial. Persistent atrial tachycardia including atrial fibrillation or flutter could be exacerbated by enlargement of both atria as a consequence of disturbed compliance of the ventricular myocardium, in what is called tachycardia-induced cardiomyopathy. In such cases, pathologic degeneration of the wall of the atrium or ventricle could occur. Worsened cardiac function or enlargement of the ventricle could be irreversible. Treatment of refractory arrhythmia by radiofrequency ablation or surgical excision would prevent progression toward cardiomyopathy.^{4,5} We decided to perform ablation for tachycardia in an asymptomatic patient with good cardiac function for these reasons.

We surgically excised aneurysms in 3 patients who proved refractory to ablation therapy. No operative deaths or complications were encountered. Surgical techniques included partial excision of the suspected foci (aneurysms) and replacement of atrial defects with a pericardial patch, which is relatively straightforward and minimally invasive. Binder and colleagues¹⁰ suggested that the low operative mortality rate and high success rate justified a surgical approach for patients with multiple or single diverticula of the atria and supraventricular tachycardia. In particular, surgery should be performed when patients are symptomatic or require anticoagulation.

Crawford and Gillette¹¹ reported that such arrhythmias gradually become more aggressive, and described surgical treatment for multiple foci causing ectopic atrial tachycardia as successful in 7 of 11 patients (64%). We surgically treated the arrhythmia in 2 of 3 patients (67%). Small and large ranges of foci causing ectopic atrial tachycardia were completely excised without and with cardiopulmonary bypass, respectively. Total excision completely treated the arrhythmias and these patients are not

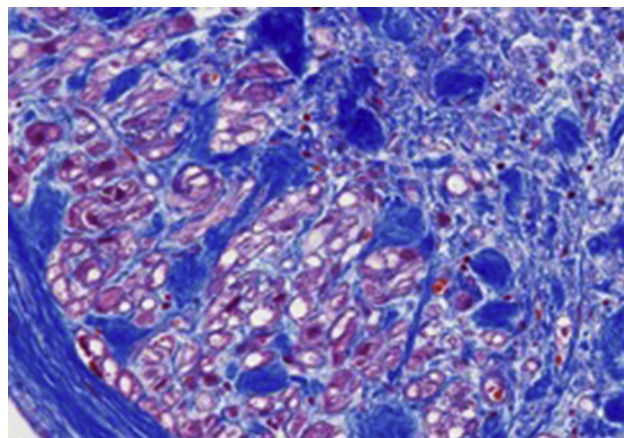


Figure 3 The right atrial wall has degenerated into vacuoles or fibrous cells. This area is considered the substrate of arrhythmia.

currently under medication. The foci of ectopic atrial tachycardia cannot be completely excised once they have spread to almost all the right atrium or to areas near the right coronary artery or sinoatrial node. The foci remained in the right atrium of 1 patient in the present study and treatment proved unsuccessful. Additional medications and ablation were required to treat ectopic atrial tachycardia in this patient.

We recommend surgical treatment for ectopic atrial tachycardia arising from the right atrial appendage because, although arrhythmia carries risk for perforation, thrombosis, and being refractory to ablation, surgery is low-risk and minimally invasive.

Conclusions

When ectopic atrial tachycardia arising from a right atrial appendage aneurysm proves refractory to ablation, we recommend surgical treatment of the arrhythmia as safe and effective. A combination of medications, surgery, and ablation should be considered for patients with foci that are difficult to excise.

References

1. Naganuma T, Miura M, Tamame T, Chinen S, Matsuoka M, Yokoyama S, Ooki H, Sibuya K. A study on different clinical manifestation of ectopic atrial tachycardia in infants and children. *Nihon Shoni Junkanki Gakkai Zasshi* 2011; 27:199–205.
2. Toyohara K, Fukuhara H, Yoshimoto J, Ozaki N, Nakamura Y. Electrophysiologic studies and radiofrequency catheter ablation of ectopic atrial tachycardia in children. *Pediatr Cardiol* 2011;32:40–46.
3. Zhang T, Li XB, Wang YL, Zhang P, Zhang HC, Xu Y, Guo JH. Focal atrial tachycardia arising from the right atrial appendage: electrophysiologic and electrocardiographic characteristics and catheter ablation. *Int J Clin Pract* 2009; 63:417–424.
4. Aryal MR, Hakim FA, Giri S, Ghimire S, Pandit A, Bhandari Y, Acharya YP, Pradhan R. Right atrial appendage aneurysm: a systematic review. *Echocardiography* 2014;31:534–539.
5. Ishii Y, Inamura N, Kayatani F. Congenital aneurysm of the right atrial appendage in a fetus. *Pediatr Cardiol* 2012;33:1227–1229.
6. Ho SY, Anderson RH, Sanchez-Quintana D. Atrial structure and fibres: morphologic bases of atrial conduction. *Cardiovasc Res* 2002;54:325–336.
7. Furushima H, Chinushi M, Hosaka Y, Aizawa Y. Focal atrial tachycardia refractory to radiofrequency catheter ablation originating from right atrial appendage. *Europace* 2009;11:521–522.
8. Patel NJ, Deshmukh A, Pau D, Goyal V, Patel SV, Patel N, Agnihotri K, Asirvatham S, Noseworthy P, Di Biase L, Natale A, Viles-Gonzalez JF. Contemporary utilization and safety outcomes of catheter ablation of atrial flutter in the United States: analysis of 89,638 procedures. *Heart Rhythm* 2016;13:1317–1325.
9. Bertaglia E, Zoppo F, Tondo C, Colella A, Mantovan R, Senatore G, Bottoni N, Carreras G, Coro L, Turco P, Mantica M, Stabile G. Early complications of pulmonary vein catheter ablation for atrial fibrillation: a multicenter prospective registry on procedural safety. *Heart Rhythm* 2007;4:1265–1271.
10. Binder TM, Rosenhek R, Frank H, Gwechenberger M, Maurer G, Baumgartner H. Congenital malformations of the right atrium and the coronary sinus: an analysis based on 103 cases reported in the literature and two additional cases. *Chest* 2000; 117:1740–1748.
11. Crawford FA, Gillette PC. Surgical treatment of cardiac dysrhythmias in infants and children. *Ann Thorac Surg* 1994;58:1262–1268.